

**DEPARTMENT OF ORAL AND MAXILLOFACIAL PATHOLOGY & MICROBIOLOGY**

**E-LEARNING CLASS RECORDS**

**COURSE: BACHELOR OF DENTAL SURGERY**

**YEAR: INTERNS**

**SUBJECT: ORAL AND MAXILLOFACIAL PATHOLOGY**

**DATE: 06.04.2020 to 11.04.2020**


CIRCULAR NO	DATE	TIMING	TOPIC	PRESENTING FACULTY	NO OF INTERNS ATTENDED
CDCRI/OP/2020/034	06.04.2020	08.30 am - 10.00 am	Malignant Salivary Gland Neoplasms - Mucoepidermoid Carcinoma	Dr. Merlin Jayaraj	3
CDCRI/OP/2020/041	11.04.2020	08.30am - 09.30 am	Malignant Salivary Gland Neoplasms - Polymorphous Low-Grade Adeno Carcinoma, Carcinoma Ex Pleomorphic Adenoma	Dr. Merlin Jayaraj	3
CDCRI/OP/2020/043	11.04.2020	02.00 pm -03.00 pm	Malignant Salivary Gland Neoplasms - Acinic Cell Carcinoma	Dr. Merlin Jayaraj	3

CDCRI/OP/2020/034

06.04.2020

DEPARTMENT OF ORAL AND MAXILLOFACIAL PATHOLOGY AND MICROBIOLOGY

RECORD OF e-CLASS

PLATFORM	 <a href="https://us04web.zoom.us/j/9586815047?pwd=MnJKWWdWd3BMdk5XcUlxOEGvTUxCdz09">https://us04web.zoom.us/j/9586815047?pwd=MnJKWWdWd3BMdk5XcUlxOEGvTUxCdz09</a>
SESSION	WEBINAR - MALIGNANT SALIVARY GLAND NEOPLASM - MUCOEPIDERMOID CARCINOMA
PRESENTING FACULTY	DR. MERLIN JAYARAJ
DATE	06.04.2020
TIMING	08.30 am to 10.00am
INTERNS PARTICIPANTS	Dr. Raavi Sriharika, Dr. Revanth Kumar, Dr. Shanmuga Velu
FACULTY ATTENDED	Dr. R. Sathish Muthukumar

**FACULTY: DR. MERLIN JAYARAJ PRESENTATION**

**SHARED SCREEN**





**MALIGNANT SALIVARY GLAND  
NEOPLASM-  
MUCOEPIDERMOID CARCINOMA**

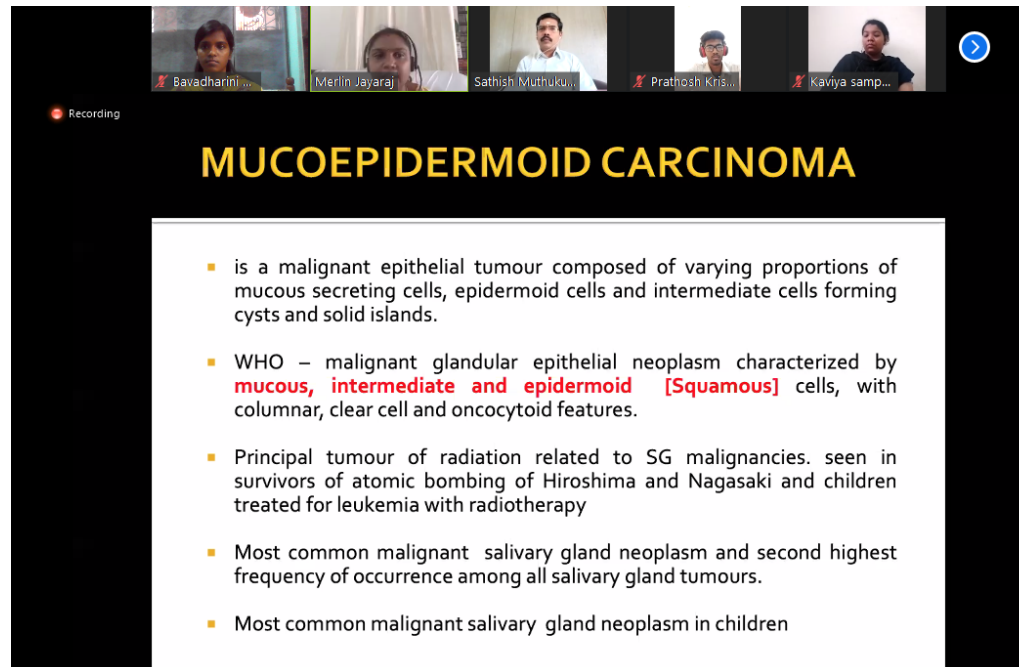
DR.MERLIN JAYARAJ MDS  
DEPT OF ORAL PATHOLOGY  
04.04.2020

Video call participants:

- Kaviya sampath
- Deeptika.B
- Gayathri S A
- dhwarka mai jagathe...

**FACULTY: DR. MERLIN JAYARAJ PRESENTATION**

**SHARED SCREEN**



**MUCOEPIDERMOID CARCINOMA**

- is a malignant epithelial tumour composed of varying proportions of mucous secreting cells, epidermoid cells and intermediate cells forming cysts and solid islands.
- WHO – malignant glandular epithelial neoplasm characterized by **mucous, intermediate and epidermoid** [Squamous] cells, with columnar, clear cell and oncocytoïd features.
- Principal tumour of radiation related to SG malignancies. seen in survivors of atomic bombing of Hiroshima and Nagasaki and children treated for leukemia with radiotherapy
- Most common malignant salivary gland neoplasm and second highest frequency of occurrence among all salivary gland tumours.
- Most common malignant salivary gland neoplasm in children



**FACULTY: DR. MERLIN JAYARAJ PRESENTATION**


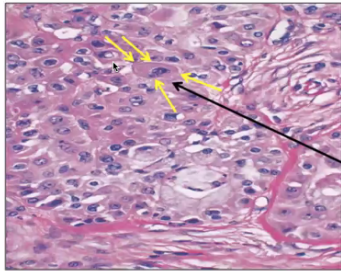
**SHARED SCREEN**

Recording

Bavadharini... Merlin Jayaraj Sathish Muthuku... Manigandan T Barathi kumar Shanmugavel...

## Microscopic features of MEC

Epidermoid or Squamoid cells



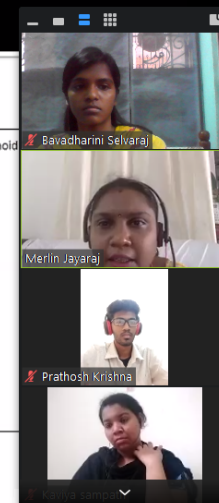
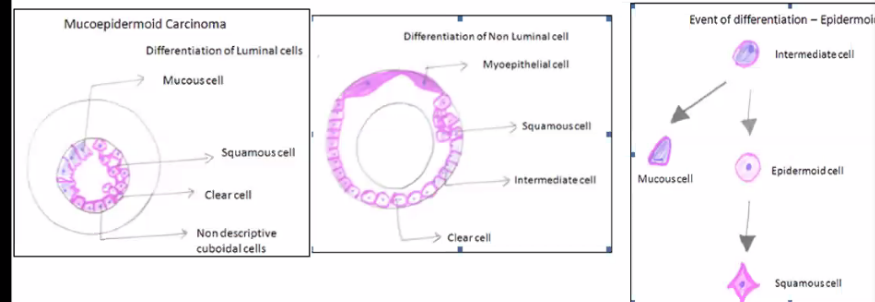
- ✓ Epidermoid/squamous cells predominate
- ✓ Scanty mucous cells
- ✓ Extremely less cystic areas

Epidermoid or squamous cells

FACULTY: DR. MERLIN JAYARAJ PRESENTATION

SHARED SCREEN

## HISTOGENESIS OF MEC

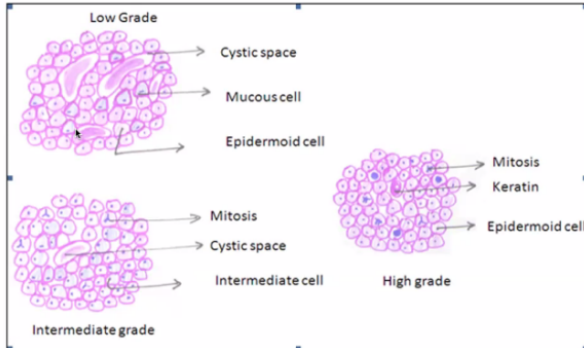


**FACULTY: DR. MERLIN JAYARAJ PRESENTATION**

**SHARED SCREEN**

Recording

## H/P- GRADING

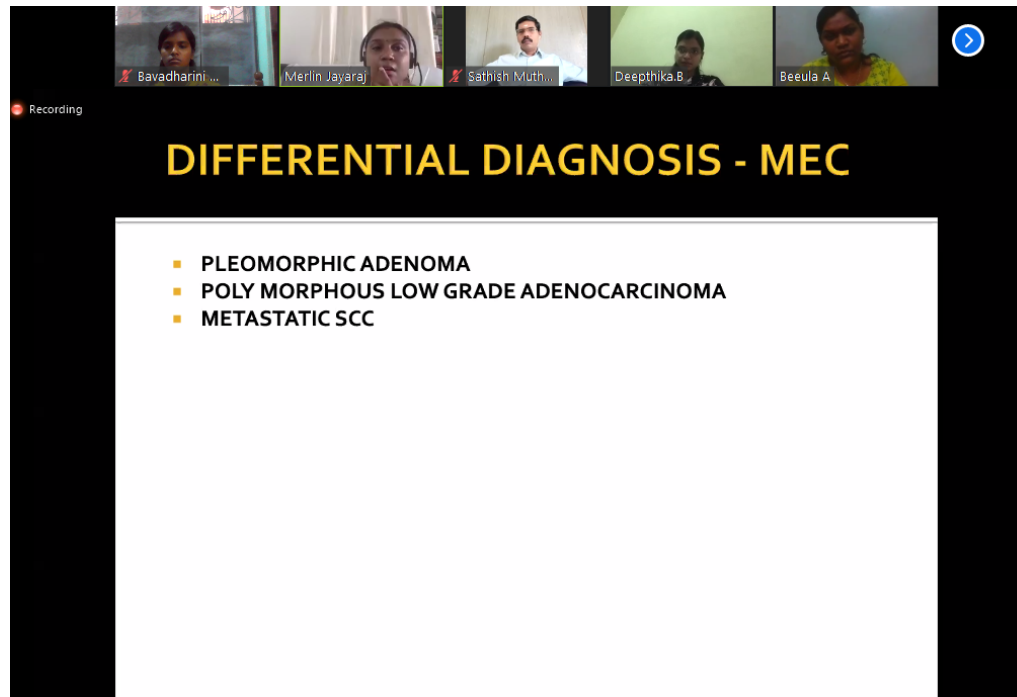


The diagram illustrates the H/P-Grading of dental tissue, showing three distinct grades of cellular organization:

- Low Grade:** Characterized by a well-organized structure with a central **Cystic space**, **Mucous cell**, and **Epidermoid cell**.
- Intermediate grade:** Shows a more disorganized structure with **Mitosis**, **Cystic space**, and **Intermediate cell**.
- High grade:** Displays a highly disorganized structure with **Mitosis**, **Keratin**, and **Epidermoid cell**.

**FACULTY: DR. MERLIN JAYARAJ PRESENTATION**

**SHARED SCREEN**



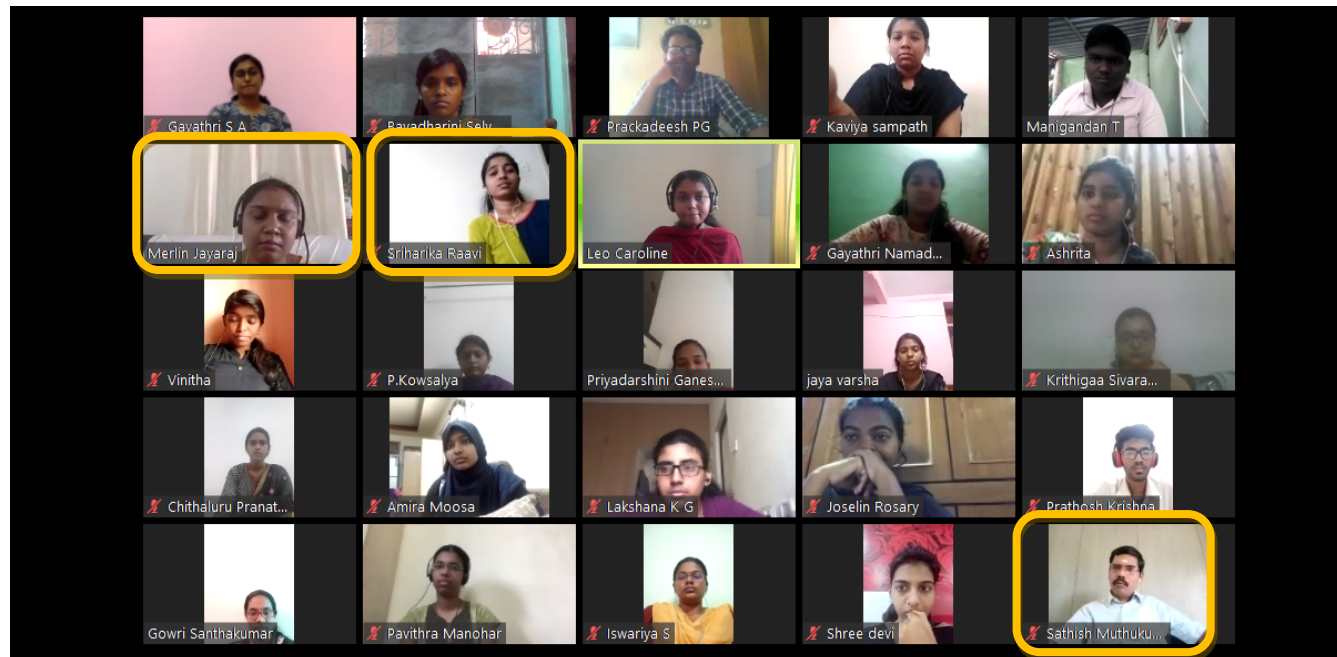
Recording

**DIFFERENTIAL DIAGNOSIS - MEC**

- PLEOMORPHIC ADENOMA
- POLY MORPHOUS LOW GRADE ADENOCARCINOMA
- METASTATIC SCC


















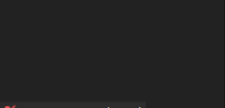

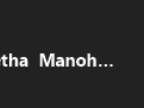


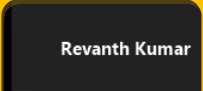


**FACULTY: DR. MERLIN JAYARAJ PRESENTATION**

**PARTICIPANT VIDEO TILES**



**FACULTY: DR. MERLIN JAYARAJ PRESENTATION**

**PARTICIPANT VIDEO TILES**

 Niklesh Raj	 Sirpika Arunachalam	 Mothi Rajathi	 Devadarshini	 akshaya Bhupalan
 Anupriya.D	 Dr. Prisilla	 Nithyashi	 S.Vignesh	 Priyadarshini A
 S.Santhini	 Sakthi Mani Murugesan	 Swathi M	 RAKSHA RAMKUMAR	 Divya Dharshini
 Savitha S	 P.Kowsalya	 Bency Joseph Raj	 kamalisha Anbalagan	 Suvetha Manoharan
 Pavithra G	 Logeshwari M	 Revanth Kumar	 Kanishka Nandhini	 Saranya Jayashankar



**Chettinad**  
Dental College & Research Institute

**FACULTY: DR. MERLIN JAYARAJ PRESENTATION**

**PARTICIPANTS ATTENDANCE**


<b>LV</b> LaUreL VijiTha	<del>/</del> <input type="checkbox"/>	<b>P</b> P.ABIRAMI	<del>/</del> <input type="checkbox"/>	Sriram Mahesh	<del>/</del> <input type="checkbox"/>	Sakthi Mani Murugan P	<del>/</del> <input type="checkbox"/>
Leo Caroline	<del>/</del> <input type="checkbox"/>	<b>P</b> P.Kowsalya	<del>/</del> <input type="checkbox"/>	<b>SR</b> Srividhya Rajesh	<del>/</del> <input type="checkbox"/>	<b>SS</b> Savitha S	<del>/</del> <input type="checkbox"/>
Logeshwari M	<del>/</del> <input type="checkbox"/>	Pavithra G	<del>/</del> <input type="checkbox"/>	<b>SJ</b> Srivishnu Janakiraman	<del>/</del> <input type="checkbox"/>	<b>SS</b> Shanmugavelu S	<del>/</del> <input type="checkbox"/>
<b>MA</b> Mahamudha Ameerulla	<del>/</del> <input type="checkbox"/>	Pavithra Manohar	<del>/</del> <input type="checkbox"/>	<b>S</b> Subhathi.B	<del>/</del> <input type="checkbox"/>	<b>SD</b> Shree devi	<del>/</del> <input type="checkbox"/>
Mahesh Mahesh	<del>/</del> <input type="checkbox"/>	Prackadeesh PG	<del>/</del> <input type="checkbox"/>	Supriya Sri Lakshmi	<del>/</del> <input type="checkbox"/>	Sirpika Arunachalam	<del>/</del> <input type="checkbox"/>
<b>MT</b> Manigandan T	<del>/</del> <input type="checkbox"/>	Prathosh Krishna	<del>/</del> <input type="checkbox"/>	<b>SM</b> Suvetha Manoharan	<del>/</del> <input type="checkbox"/>	Sneha S	<del>/</del> <input type="checkbox"/>
mathan rajan	<del>/</del> <input type="checkbox"/>	<b>PG</b> Priyadarshini Ganesan	<del>/</del> <input type="checkbox"/>	<b>SM</b> Swathi M	<del>/</del> <input type="checkbox"/>	<b>SS</b> Sona Sri	<del>/</del> <input type="checkbox"/>
<b>MR</b> Mothi Rajathi	<del>/</del> <input type="checkbox"/>	<b>PA</b> Priyadharshini A	<del>/</del> <input type="checkbox"/>	<b>SN</b> Swetha nidhi	<del>/</del> <input type="checkbox"/>	<b>SS</b> Soofiya Snobor	<del>/</del> <input type="checkbox"/>
Mukilan S C	<del>/</del> <input type="checkbox"/>	<b>R</b> RAKSHA RAMKUMAR	<del>/</del> <input type="checkbox"/>	<b>V</b> Vaishali	<del>/</del> <input type="checkbox"/>	<b>SR</b> Sriharika Raavi	<del>/</del> <input type="checkbox"/>
<b>NN</b> Nandini Nagarajan	<del>/</del> <input type="checkbox"/>	<b>RK</b> Revanth Kumar	<del>/</del> <input checked="" type="checkbox"/>	<b>V</b> Vaishnavi	<del>/</del> <input type="checkbox"/>	<b>S.</b> Srinidhi .P	<del>/</del> <input type="checkbox"/>
Narendhar Sreedhran	<del>/</del> <input type="checkbox"/>	<b>RK</b> Rohithchandru K	<del>/</del> <input type="checkbox"/>	Vignesh Mk	<del>/</del> <input type="checkbox"/>	Sriram Mahesh	<del>/</del> <input type="checkbox"/>
Niklesh Raj	<del>/</del> <input type="checkbox"/>	<b>S</b> S.Santhini	<del>/</del> <input type="checkbox"/>	<b>V</b> Vinitha	<del>/</del> <input type="checkbox"/>	<b>SR</b> Srividhya Rajesh	<del>/</del> <input type="checkbox"/>
<b>NB</b> Nithyasri B R	<del>/</del> <input type="checkbox"/>	<b>S</b> S.Vignesh	<del>/</del> <input type="checkbox"/>	<b>BJ</b> Bency Joseph Raj	<del>/</del> <input type="checkbox"/>	<b>SJ</b> Srivishnu Janakiraman	<del>/</del> <input type="checkbox"/>
<b>NR</b> Niveditha R	<del>/</del> <input type="checkbox"/>	<b>SM</b> SAHANASHREE M	<del>/</del> <input type="checkbox"/>	Saranya Jayashankar	<del>/</del> <input type="checkbox"/>	<b>S</b> Subhathi.B	<del>/</del> <input type="checkbox"/>

CDCRI/OP/2020/041

11.04.2020

DEPARTMENT OF ORAL PATHOLOGY AND MICROBIOLOGY


RECORD OF e CLASS

PLATFORM	 <a href="https://us04web.zoom.us/j/942442047">https://us04web.zoom.us/j/942442047</a>
SESSION	WEBINAR - MALIGNANT SALIVARY GLAND NEOPLASM - POLYMORPHOUS ADENOCARCINOMA & CARCINOMA EX PLEOMORPHIC ADENOMA
PRESENTING FACULTY	DR. MERLIN JAYARAJ
DATE	11.04.2020
TIMING	8.30 pm to 10.30 pm
INTERNS PARTICIPANTS	Dr. Raavi Sriharika, Dr. Revanth Kumar, Dr. Shanmuga Velu
FACULTY ATTENDED	Dr. R. Sathish Muthukumar



**FACULTY: DR. MERLIN JAYARAJ PRESENTATION**

**SHARED SCREEN**



The screenshot shows a Zoom meeting interface with five participants in the top bar: Bavadharini, Merlin Jayaraj, Gokul S, Sathish Muthu, and Srinivas N. The main window displays a shared screen of a presentation slide. The slide features the Chettinad Dental College & Research Institute logo and the title "MALIGNANT SALIVARY GLAND NEOPLASMS - 3". Below the title, the presenter's name "DR. MERLIN JAYARAJ MDS" is listed, followed by his title "SENIOR LECTURER" and department "DEPARTMENT OF ORAL PATHOLOGY AND MICROBIOLOGY". The date "11.04.2020" is at the bottom. The presentation software interface (likely Beamer) is visible around the slide, showing a table of contents on the left with five slides, the first of which is the current slide.

**MALIGNANT SALIVARY GLAND NEOPLASMS - 3**

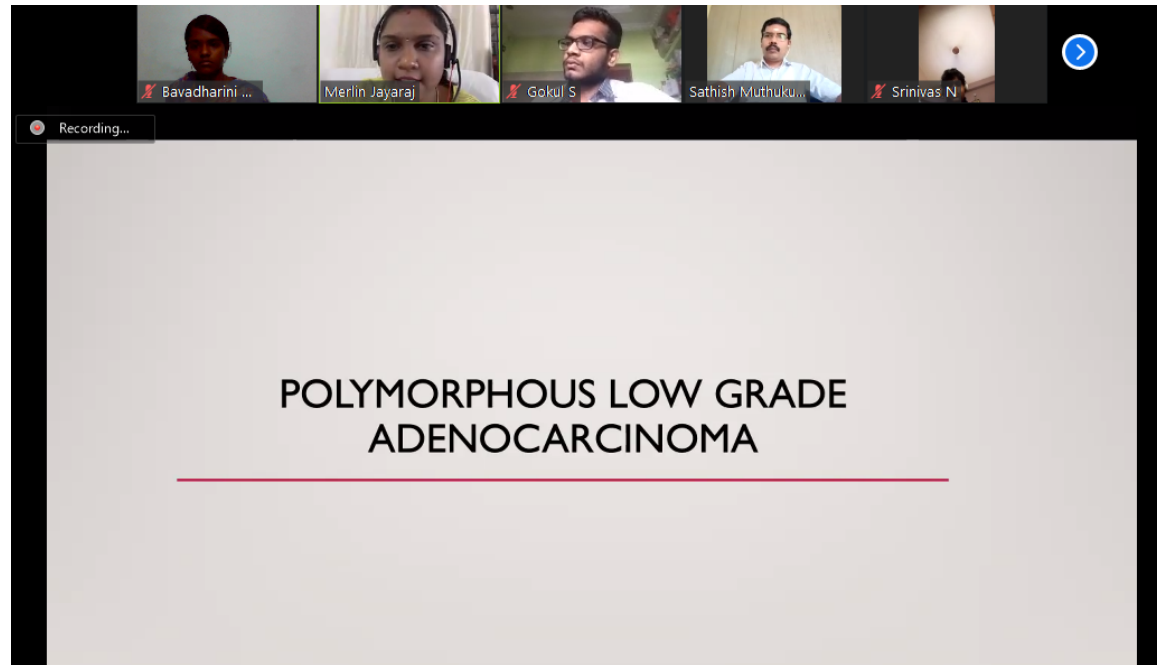
Chettinad  
Dental College & Research Institute  
Department of Oral & Maxillofacial Pathology

**MALIGNANT SALIVARY GLAND NEOPLASMS - 3**

DR. MERLIN JAYARAJ MDS  
SENIOR LECTURER  
DEPARTMENT OF ORAL PATHOLOGY AND MICROBIOLOGY  
11.04.2020

**FACULTY: DR. MERLIN JAYARAJ PRESENTATION**

**SHARED SCREEN**



Recording...

**POLYMORPHOUS LOW GRADE  
ADENOCARCINOMA**

The image shows a Zoom meeting interface. At the top, there is a row of participant thumbnails. From left to right, the participants are: Bavadharini, Merlin Jayaraj (who is wearing a headset), Gokul S, Sathish Muthuku, and Srinivas N. To the right of these thumbnails is a blue circular button with a white arrow pointing right. Below the thumbnails, there is a 'Recording...' status bar. The main part of the screen is a large, light gray rectangle displaying the title 'POLYMORPHOUS LOW GRADE ADENOCARCINOMA' in bold, black, uppercase letters. A thin red horizontal line is positioned below the text.



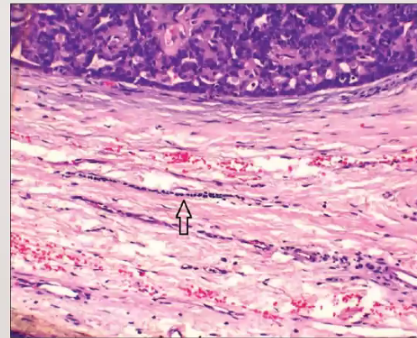
**Chettinad**  
Dental College & Research Institute

**FACULTY: DR. MERLIN JAYARAJ PRESENTATION**

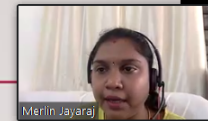**SHARED SCREEN**

## POLYMORPHOUS LOW GRADE ADENOCARCINOMA

- In areas, usually at the periphery of the tumor, there are cells aligned in single files – SINGLE FILE PATTERN/INDIAN FILE PATTERN

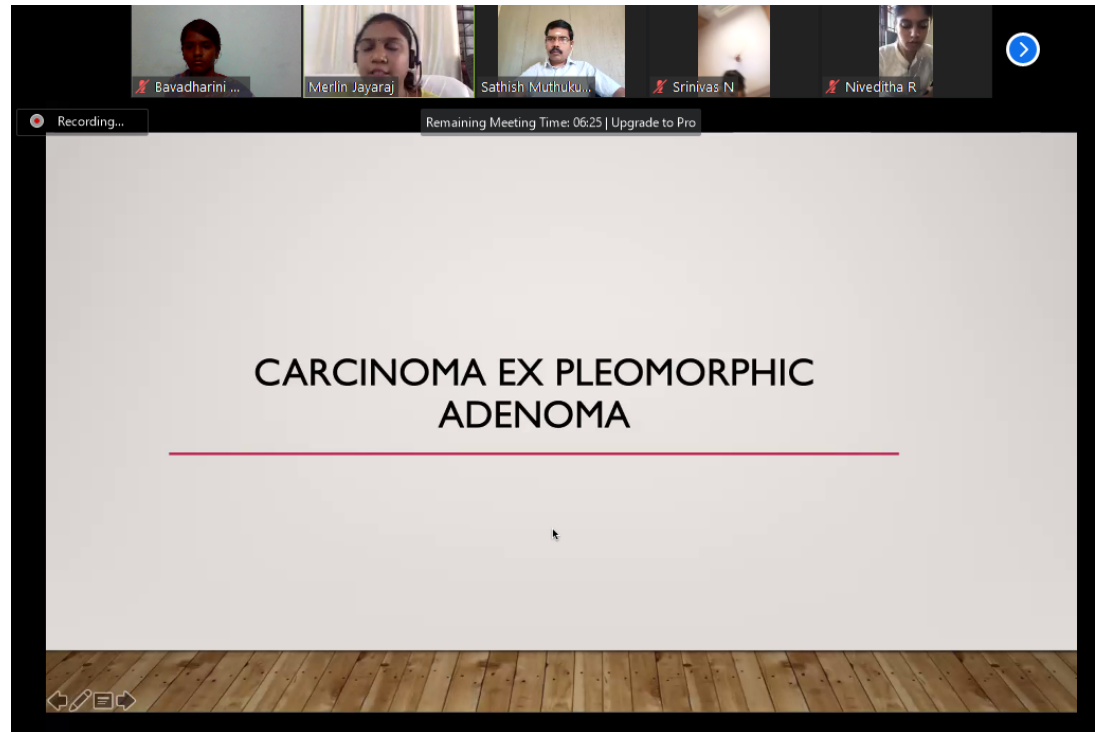


At the tumor periphery, the cells are arranged in a linear, single cell pattern resembling "Indian file" or beads on a string pattern of infiltration (H&E stain,  $\times 100$ )



**FACULTY: DR. MERLIN JAYARAJ PRESENTATION**

**SHARED SCREEN**



Recording...

Remaining Meeting Time: 06:25 | Upgrade to Pro

**CARCINOMA EX PLEOMORPHIC  
ADENOMA**

Navigation icons: back, forward, search, etc.

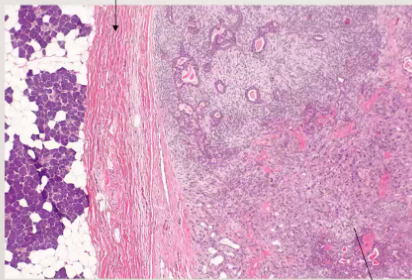
The image shows a Zoom meeting interface. At the top, there are five participant video thumbnails with names: Bavadharini, Merlin Jayaraj, Sathish Muthuku, Srinivas N, and Niveditha R. Below the thumbnails is a status bar with 'Recording...' and 'Remaining Meeting Time: 06:25 | Upgrade to Pro'. The main area is a shared screen displaying a presentation slide with the title 'CARCINOMA EX PLEOMORPHIC ADENOMA' in bold black text, underlined. The bottom of the screen shows a wooden floor texture and navigation icons.

**FACULTY: DR. MERLIN JAYARAJ PRESENTATION**

**SHARED SCREEN**

Recording... Less than 1 minute | Upgrade to Pro

**CARCINOMA EX PLEOMORPHIC ADENOMA**



The carcinoma component is on the lower right of the image. Benign parotid gland is seen at the left and pleomorphic adenoma is seen at the upper right.

The image is a histological slide showing a transition from benign parotid gland tissue on the left to a malignant carcinoma component on the lower right. A central band of pleomorphic adenoma is visible, separating the benign and malignant areas. Arrows point to the carcinoma component and the pleomorphic adenoma.

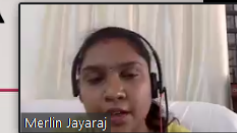
**FACULTY: DR. MERLIN JAYARAJ PRESENTATION**

**SHARED SCREEN**

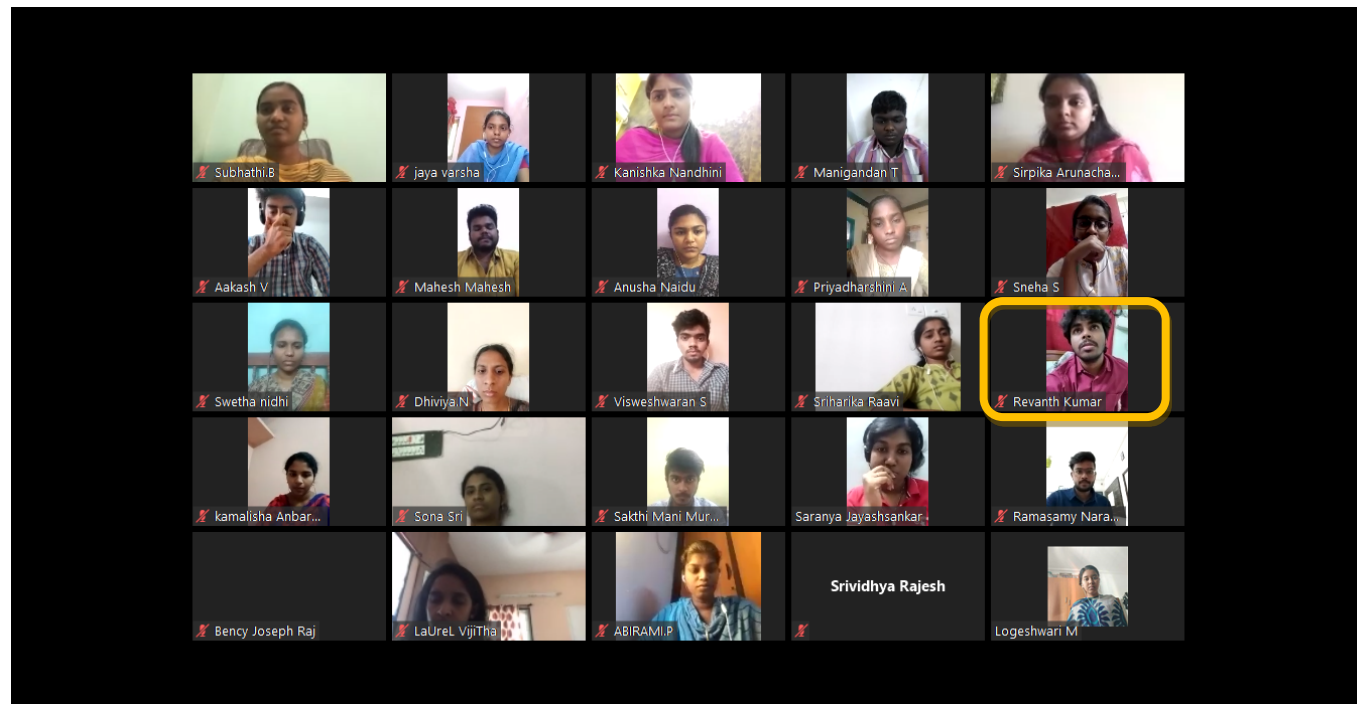
## CARCINOMA EX PLEOMORPHIC ADENOMA

### DIFFERENTIAL DIAGNOSIS

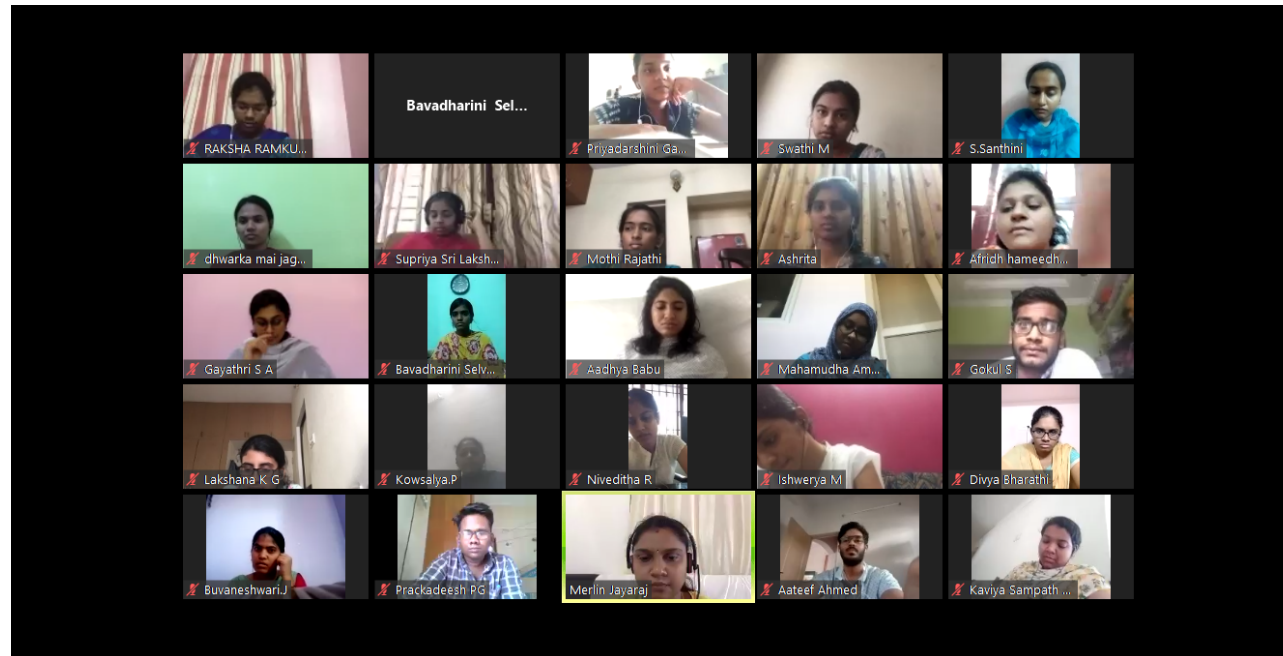
- A Ca ex PA can be mistaken for a benign PA.
- It can also be misdiagnosed as other benign and malignant salivary gland tumours.
- Metastatic mixed tumour is less common than Ca ex PA and is differentiated from Ca ex PA by having no carcinomatous component.



**FACULTY: DR. MERLIN JAYARAJ PRESENTATION  
PARTICIPANTS VIDEO TILES**




















**FACULTY: DR. MERLIN JAYARAJ PRESENTATION  
PARTICIPANTS VIDEO TILES**





**FACULTY: DR. MERLIN JAYARAJ PRESENTATION**

**PARTICIPANTS ATTENDANCE**


<b>KS</b> Kaviya Sampath Kumar	<del>/</del> <input type="checkbox"/>	<b>NN</b> Nandini Nagarajan	<del>/</del> <input type="checkbox"/>	<b>RK</b> Revanth Kumar	<del>/</del> <input type="checkbox"/>
<b>KM</b> Kavya Maran	<del>/</del> <input checked="" type="checkbox"/>	 Narendhar Sreedharan	<del>/</del> <input type="checkbox"/>	<b>RK</b> Rohithchandru K	<del>/</del> <input type="checkbox"/>
<b>K</b> Kowsalya.P	<del>/</del> <input type="checkbox"/>	 Nikilesh Raj	<del>/</del> <input type="checkbox"/>	<b>S</b> S.Santhini	<del>/</del> <input type="checkbox"/>
<b>KS</b> Krithigaa Sivaraman	<del>/</del> <input type="checkbox"/>	<b>N</b> Nithyasri	<del>/</del> <input type="checkbox"/>	<b>SM</b> SAHANASHREE M	<del>/</del> <input type="checkbox"/>
<b>LK</b> Lakshana K G	<del>/</del> <input type="checkbox"/>	<b>NR</b> Niveditha R	<del>/</del> <input type="checkbox"/>	 Sakthi Mani Murugan P	<del>/</del> <input type="checkbox"/>
<b>LV</b> LaUreL VijiTha	<del>/</del> <input type="checkbox"/>	 Pavithra G	<del>/</del> <input type="checkbox"/>	<b>SS</b> Savitha S	<del>/</del> <input type="checkbox"/>
 Leo Caroline	<del>/</del> <input type="checkbox"/>	 Pavithra Manohar	<del>/</del> <input type="checkbox"/>	 Shanmugavelu S	<del>/</del> <input type="checkbox"/>
 Logeshwari M	<del>/</del> <input type="checkbox"/>	 Prackadeesh PG	<del>/</del> <input checked="" type="checkbox"/>	 Shree devi Elangovan	<del>/</del> <input type="checkbox"/>
<b>MA</b> Mahamudha Ameerulla	<del>/</del> <input type="checkbox"/>	 Prackadeesh PG	<del>/</del> <input type="checkbox"/>	 Sirpika Arunachalam	<del>/</del> <input type="checkbox"/>
 Mahesh Mahesh	<del>/</del> <input type="checkbox"/>	 Prathosh Krishna	<del>/</del> <input type="checkbox"/>	 Sneha S	<del>/</del> <input type="checkbox"/>
<b>MT</b> Manigandan T	<del>/</del> <input type="checkbox"/>	<b>PG</b> Priyadarshini Ganesan	<del>/</del> <input type="checkbox"/>	<b>SS</b> Sona Sri	<del>/</del> <input type="checkbox"/>
 mathan rajan	<del>/</del> <input type="checkbox"/>	<b>PA</b> Priyadharshini A	<del>/</del> <input type="checkbox"/>	<b>SS</b> Soofiya Snober	<del>/</del> <input type="checkbox"/>
<b>MR</b> Mothi Rajathi	<del>/</del> <input type="checkbox"/>	<b>R</b> RAKSHA RAMKUMAR	<del>/</del> <input type="checkbox"/>	<b>SR</b> Sriharika Raavi	<del>/</del> <input checked="" type="checkbox"/>
<b>MS</b> Mukilan S C	<del>/</del> <input type="checkbox"/>	 Ramasamy Narayanan	<del>/</del> <input type="checkbox"/>	<b>S.</b> Srinidhi .P	<del>/</del> <input type="checkbox"/>

CDCRI/OP/2020/043

11.04.2020

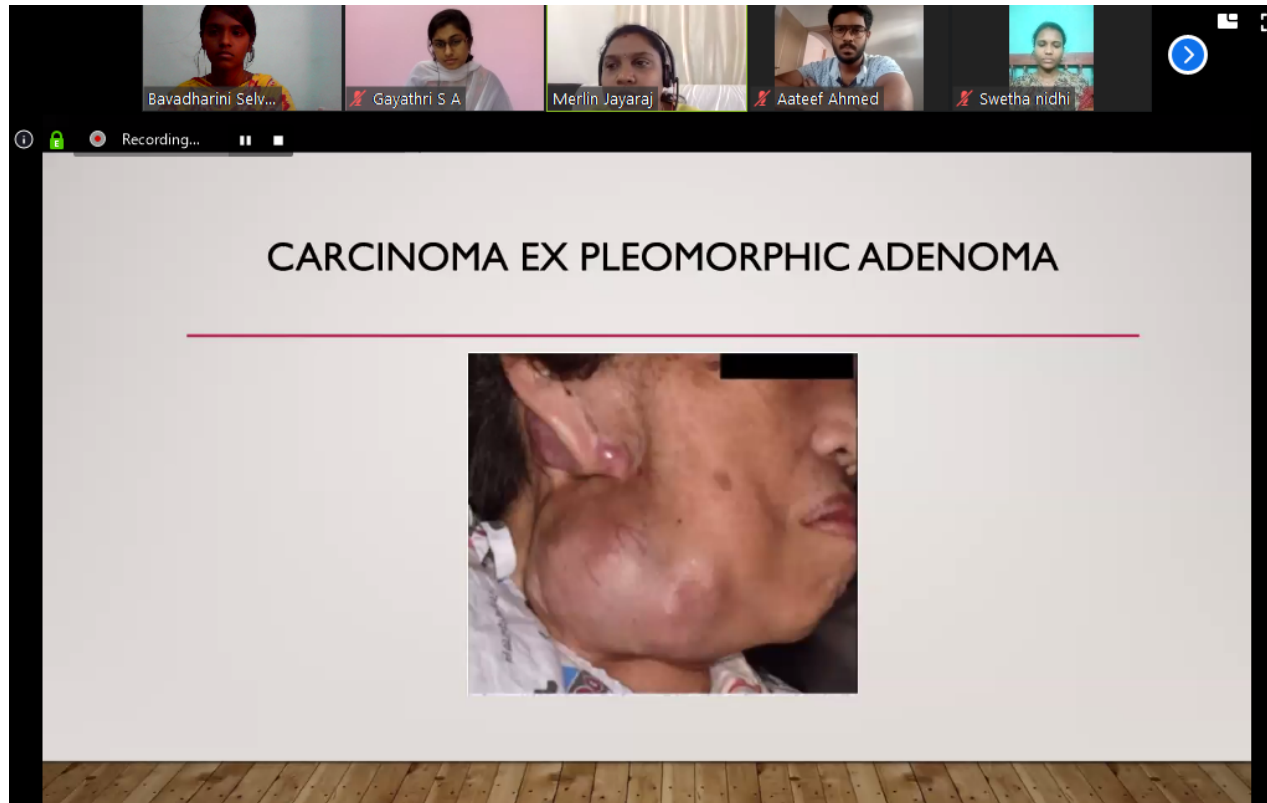
DEPARTMENT OF ORAL PATHOLOGY AND MICROBIOLOGY

RECORD OF e CLASS

PLATFORM	 <a href="https://us04web.zoom.us/j/942442047">https://us04web.zoom.us/j/942442047</a>
SESSION	MALIGNANT SALIVARY GLAND NEOPLASM - ACINIC CELL CARCINOMA
PRESENTING FACULTY	Dr. MERLIN JAYARAJ
DATE	11.04.2020 AN
TIMING	02.00 pm to 03.30 pm
INTERNS PARTICIPANTS	Dr. Raavi Sriharika, Dr. Revanth Kumar, Dr. Shanmuga Velu


**FACULTY: DR. MERLIN JAYARAJ PRESENTATION**

**SHARED SCREEN**



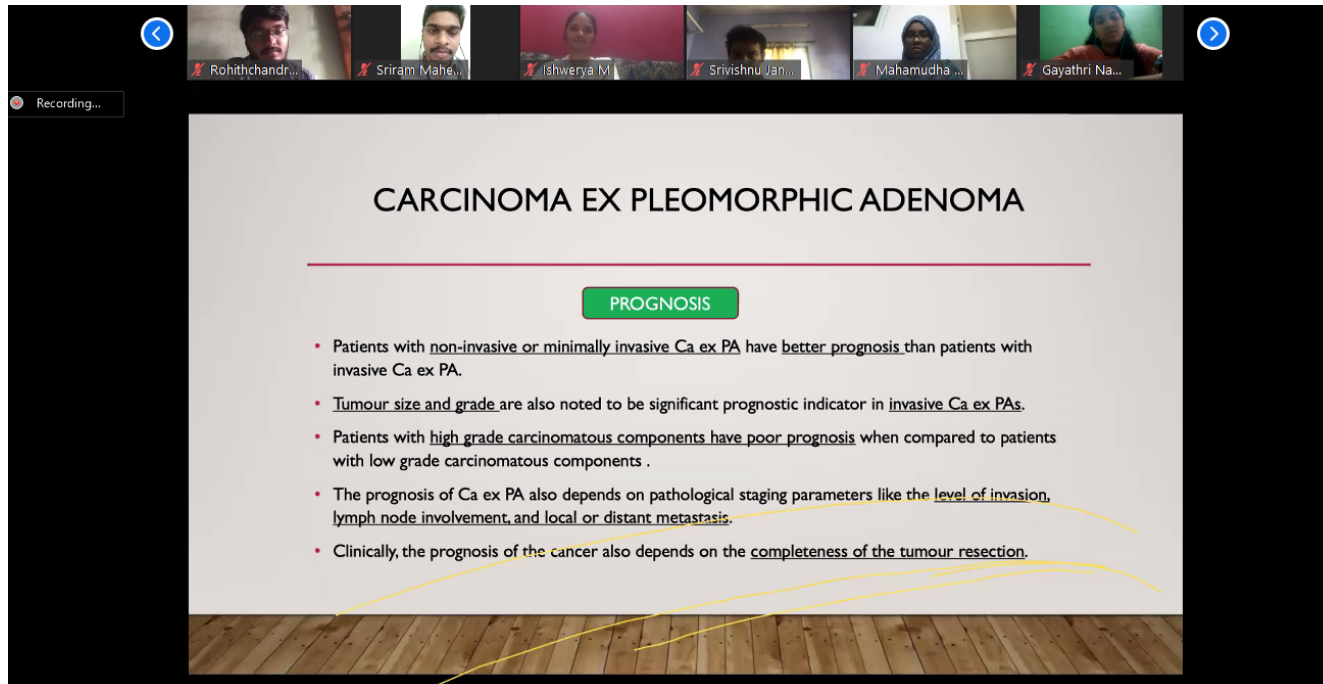
The image shows a Zoom meeting interface. At the top, there is a row of five participant video thumbnails. From left to right, they are labeled: 'Bavadharini Selv...', 'Gayathri S A', 'Merlin Jayaraj', 'Aateef Ahmed', and 'Swetha nidhi'. Below the thumbnails is a toolbar with icons for chat, mute, video, and a 'Recording...' status indicator. The main area of the screen is a shared presentation slide. The slide has a light gray background and the title 'CARCINOMA EX PLEOMORPHIC ADENOMA' in bold, black, uppercase letters. Below the title is a horizontal pink line. Underneath the line is a clinical photograph of a person's face, showing a large, rounded, reddish-pink mass on the lower cheek and jaw area. The bottom of the Zoom window shows a wooden floor texture.

**CARCINOMA EX PLEOMORPHIC ADENOMA**



**FACULTY: DR. MERLIN JAYARAJ PRESENTATION**

**SHARED SCREEN**



Recording...

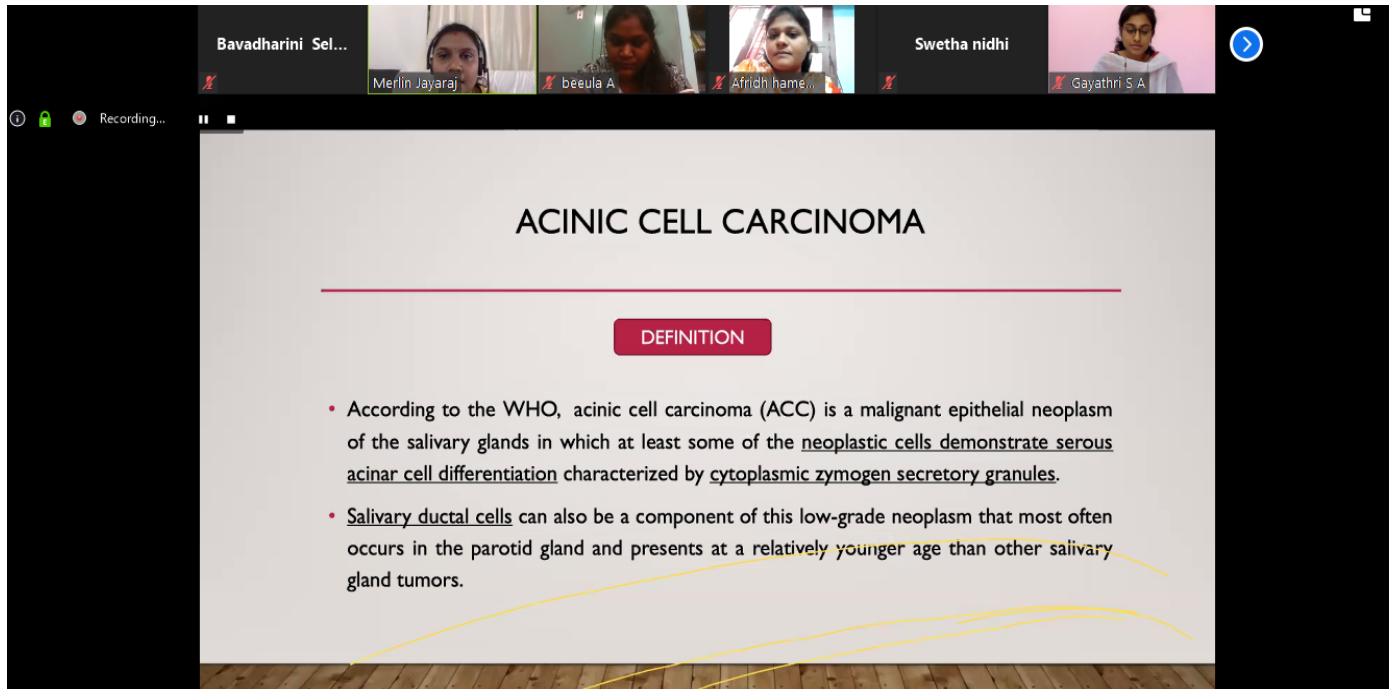
**CARCINOMA EX PLEOMORPHIC ADENOMA**

**PROGNOSIS**

- Patients with non-invasive or minimally invasive Ca ex PA have better prognosis than patients with invasive Ca ex PA.
- Tumour size and grade are also noted to be significant prognostic indicator in invasive Ca ex PAs.
- Patients with high grade carcinomatous components have poor prognosis when compared to patients with low grade carcinomatous components .
- The prognosis of Ca ex PA also depends on pathological staging parameters like the level of invasion, lymph node involvement, and local or distant metastasis.
- Clinically, the prognosis of the cancer also depends on the completeness of the tumour resection.

**FACULTY: DR. MERLIN JAYARAJ PRESENTATION**

**SHARED SCREEN**



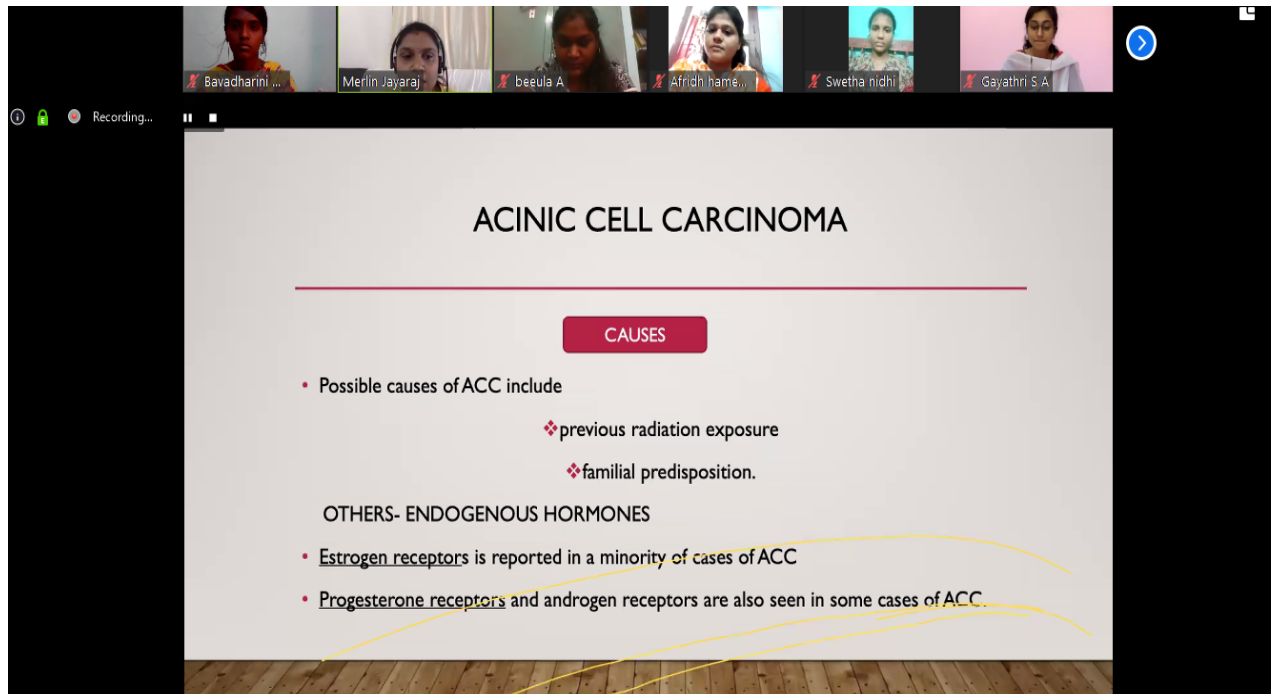
The image shows a Zoom meeting interface. At the top, there is a video gallery with five participants: Bavadharini Sel..., Merlin Jayaraj, beeula A, Afridi hame..., Swetha nidhi, and Gayathri S A. Below the gallery, the main screen displays a presentation slide titled "ACINIC CELL CARCINOMA". The slide has a pink header bar with the word "DEFINITION" in white. The content of the slide is as follows:

- According to the WHO, acinic cell carcinoma (ACC) is a malignant epithelial neoplasm of the salivary glands in which at least some of the neoplastic cells demonstrate serous acinar cell differentiation characterized by cytoplasmic zymogen secretory granules.
- Salivary ductal cells can also be a component of this low-grade neoplasm that most often occurs in the parotid gland and presents at a relatively younger age than other salivary gland tumors.

There are yellow handwritten lines at the bottom of the slide.

**FACULTY: DR. MERLIN JAYARAJ PRESENTATION**

**SHARED SCREEN**



Recording...

**ACINIC CELL CARCINOMA**

**CAUSES**

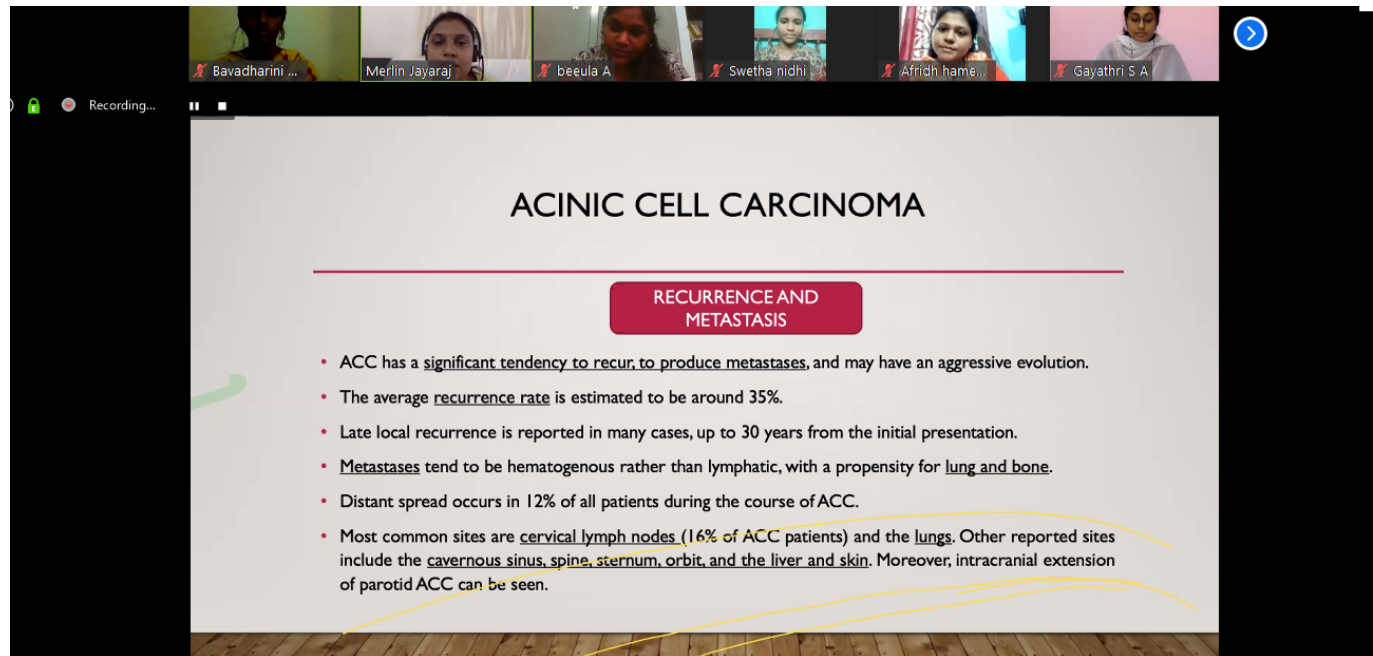
- Possible causes of ACC include
  - ❖ previous radiation exposure
  - ❖ familial predisposition.

**OTHERS- ENDOGENOUS HORMONES**

- Estrogen receptors is reported in a minority of cases of ACC
- Progesterone receptors and androgen receptors are also seen in some cases of ACC.

**FACULTY: DR. MERLIN JAYARAJ PRESENTATION**

**SHARED SCREEN**



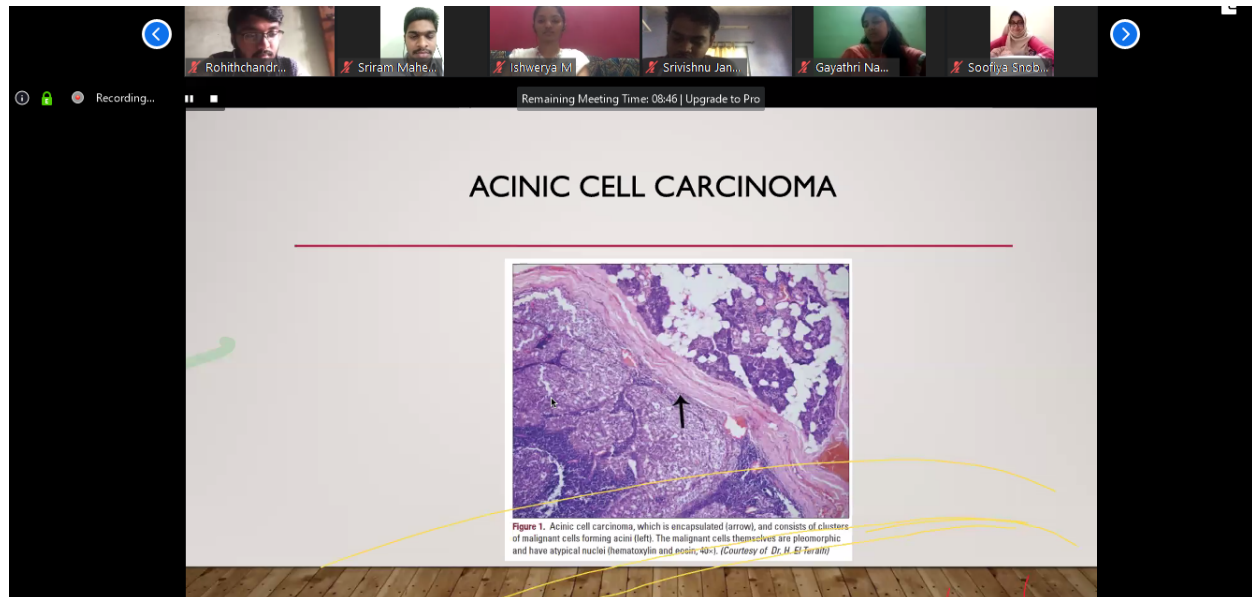
**ACINIC CELL CARCINOMA**

**RECURRENCE AND METASTASIS**

- ACC has a significant tendency to recur, to produce metastases, and may have an aggressive evolution.
- The average recurrence rate is estimated to be around 35%.
- Late local recurrence is reported in many cases, up to 30 years from the initial presentation.
- Metastases tend to be hematogenous rather than lymphatic, with a propensity for lung and bone.
- Distant spread occurs in 12% of all patients during the course of ACC.
- Most common sites are cervical lymph nodes (16% of ACC patients) and the lungs. Other reported sites include the cavernous sinus, spine, sternum, orbit, and the liver and skin. Moreover, intracranial extension of parotid ACC can be seen.

**FACULTY: DR. MERLIN JAYARAJ PRESENTATION**

**SHARED SCREEN**

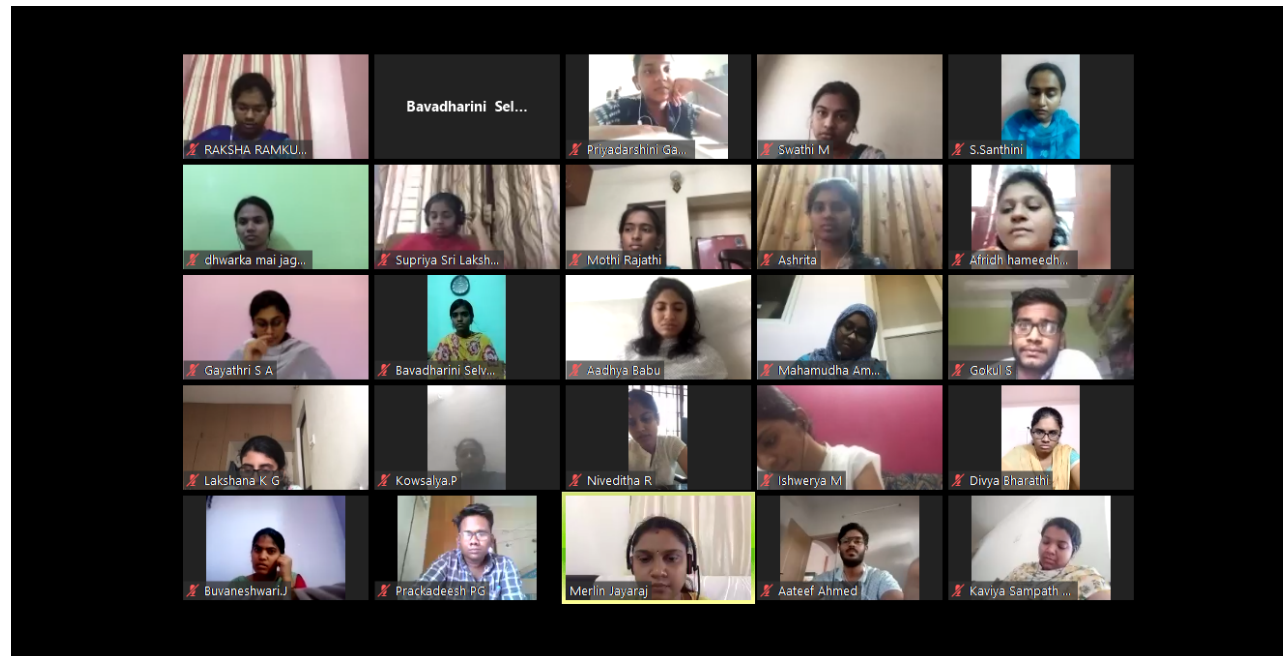


The screenshot shows a Zoom meeting interface. At the top, there is a row of participant video thumbnails with names: Rohithchandr..., Sriram Mahe..., Ishwerya M..., Srivishnu Jan..., Gayathri Na..., and Soofiya Shobi... Below the thumbnails, a status bar indicates 'Recording...' and 'Remaining Meeting Time: 08:46 | Upgrade to Pro'. The main screen displays a presentation slide titled 'ACINIC CELL CARCINOMA'. The slide features a histological image of a tissue section stained with hematoxylin and eosin (H&E). A black arrow points to a cluster of malignant cells forming an acinus, which is encapsulated. The caption below the image reads: 'Figure 1. Acinic cell carcinoma, which is encapsulated (arrow), and consists of clusters of malignant cells forming acini (left). The malignant cells themselves are pleomorphic and have atypical nuclei (hematoxylin and eosin; 40x). [Courtesy of Dr. H. B. Terrell]'



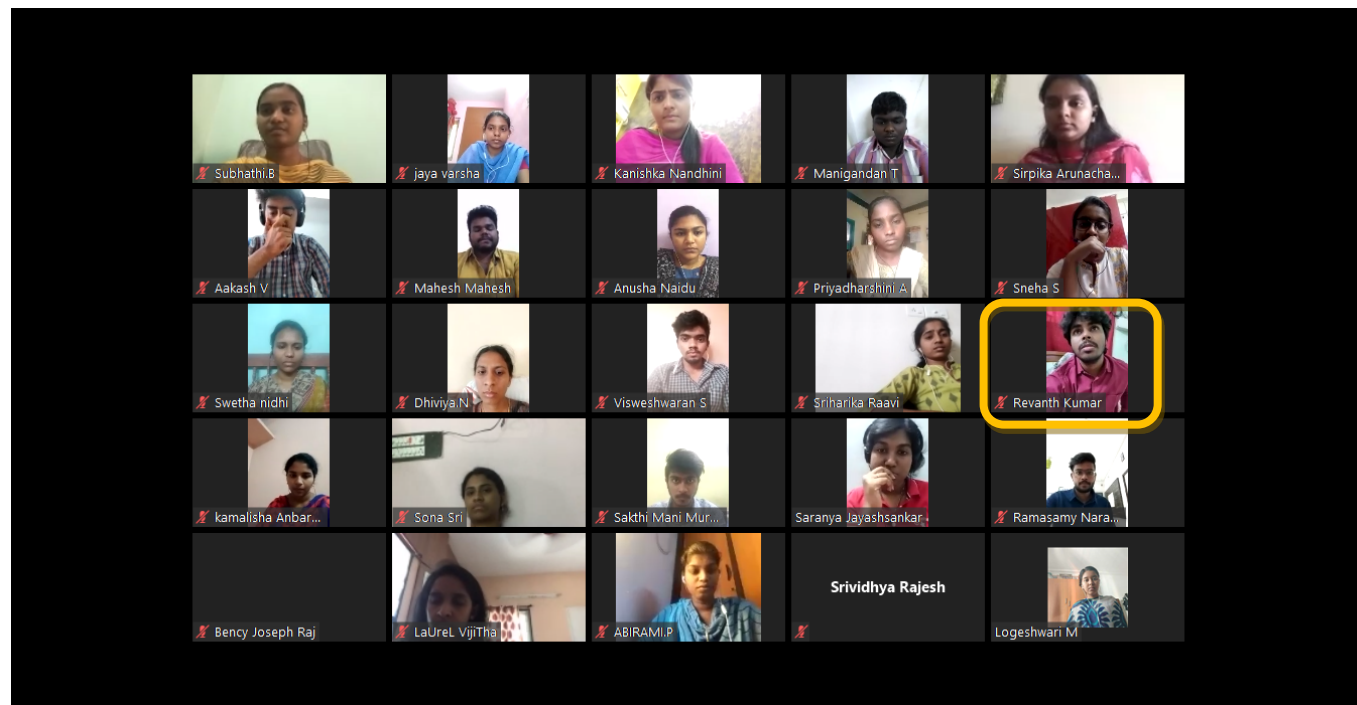
**FACULTY: DR. MERLIN JAYARAJ PRESENTATION**

**PARTICIPANT VIDEO TILES**



**FACULTY: DR. MERLIN JAYARAJ PRESENTATION**

**PARTICIPANT VIDEO TILES**
























































































**Chettinad**  
Dental College & Research Institute

**FACULTY: DR. MERLIN JAYARAJ PRESENTATION**

**PARTICIPANTS ATTENDANCE**

 S.Santhini		 Nikilesh Raj		 Kowsalya.P	
 SAHANASHREE M		 Nithyasri		 Krithigaa Sivaraman	
 Sakthi Mani Murugan P		 Niveditha R		 Lakshana K G	
 Savitha S		 Pavithra G		 LaUreL VijiTha	
 Shanmugavelu S		 Pavithra Manohar		 Leo Caroline	
 Shree devi Elangovan		 Prackadeesh PG		 Logeshwari M	
 Sirpika Arunachalam		 Prathosh Krishna		 Mahamudha Ameerulla	
 Sneha S		 Priyadarshini Ganesan		 Mahesh Mahesh	
 sonashree105@gmail.com		 Priyadarshini A		 Manigandan T	
 Soofiya Snober		 RAKSHA RAMKUMAR		 mathan rajan	
 Sriharika Raavi		 Ramasamy Narayanan		 Mothi Rajathi	
 Srinidhi .P		 Revanth Kumar		 Mukilan S C	
 Sriram Mahesh		 Rohithchandru K		 Nandini Nagarajan	
 Srividhya Rajesh		 S.Santhini		 Narendhar Sreedhran	