



Chettinad

Dental College & Research Institute

**CHETTINAD DENTAL COLLEGE
AND RESEARCH INSTITUTE**

**Affiliated to the Tamil Nadu Dr. M.G.R. Medical
University, Chennai**

CASE ALBUM

**Dr. VENKATESHWAR.S.A
2020-2023**

**PROSTHODONTICS
AND
CROWN & BRIDGE**

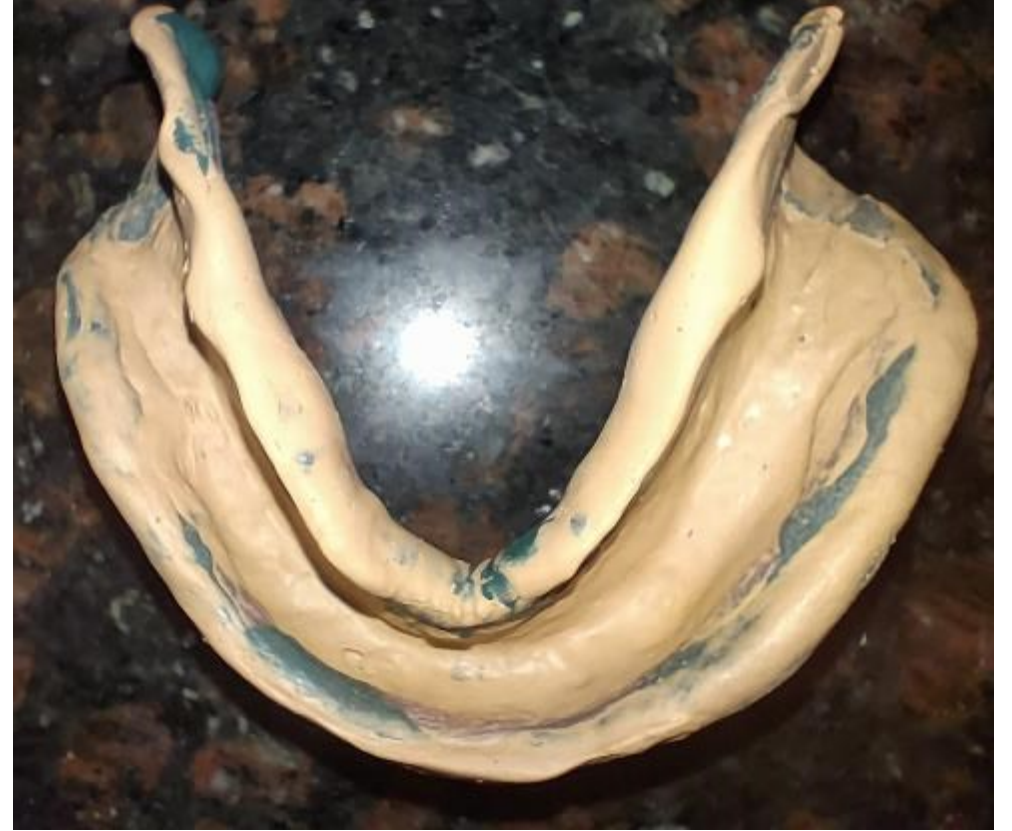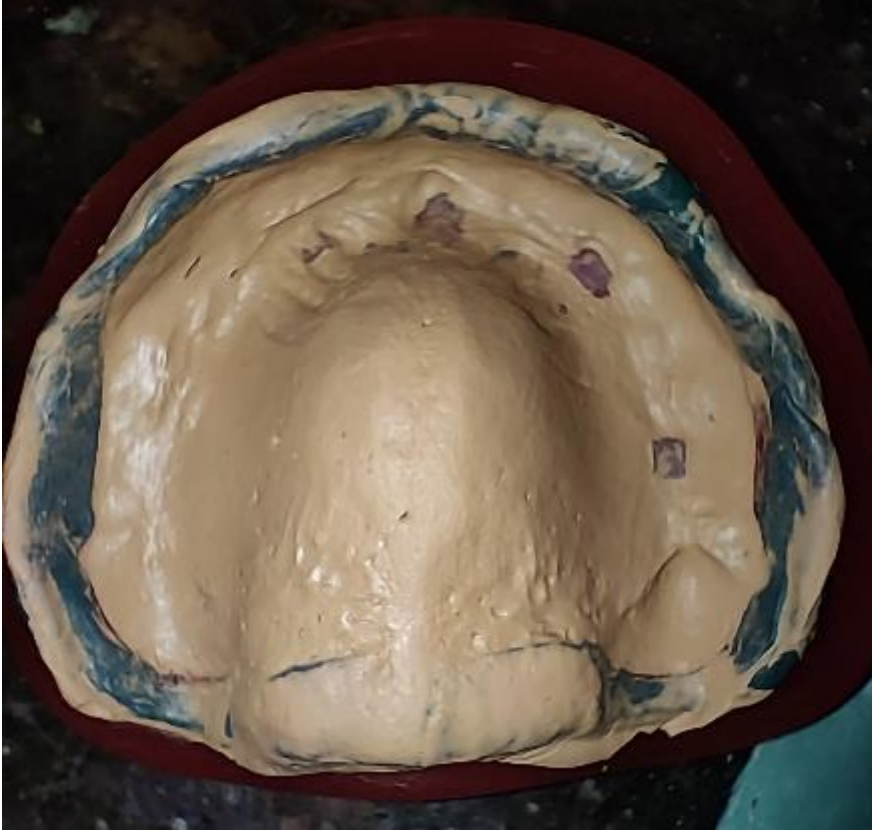S.No	PATIENT NAME	RMCT	PROCEDURE
1.	MR.PREMKUMAR	474030	BALANCED COMPLETE DENTURE
2.	MR.KALAISELVAN	485088	ANTERIOR IMPLANTS REHABILITATION WITH MALO-BRIDGE
3.	MRS. MALA	422834	IMPLANT SUPPORTED OVERDENTURE
4.	MR.MUTHUKADAIKAPPAN	398574	BIOFUNCTIONAL PROSTHETIC SYSTEM
5.	MR.PUGALENDHI	448562	IMMEDIATE IMPLANT PLACEMENT WITH L-PRF AND BONE GRAFT
6.	MRS. LAKSHMI SRINIVASAN	427891	COMPLETE DENTURE IN NEUTRAL ZONE TECHNIQUE
7.	MR.SANJEEVI	472312	SINGLE METAL COMPLETE DENTURE
8.	MR. DEVARAJAN	294852	HYBRID DENTURE
9.	MR.JEBABALAN	462391	PRECISION ATTACHMENT WITH CAST PARTIAL DENTURE
10.	MRS. THILAGAVATHY	465891	TOOTH SUPPORTED OVERDENTURE

BALANCED COMPLETE DENTURE



PATIENT NAME: MR. PREMKUMAR

RMCT: 474030

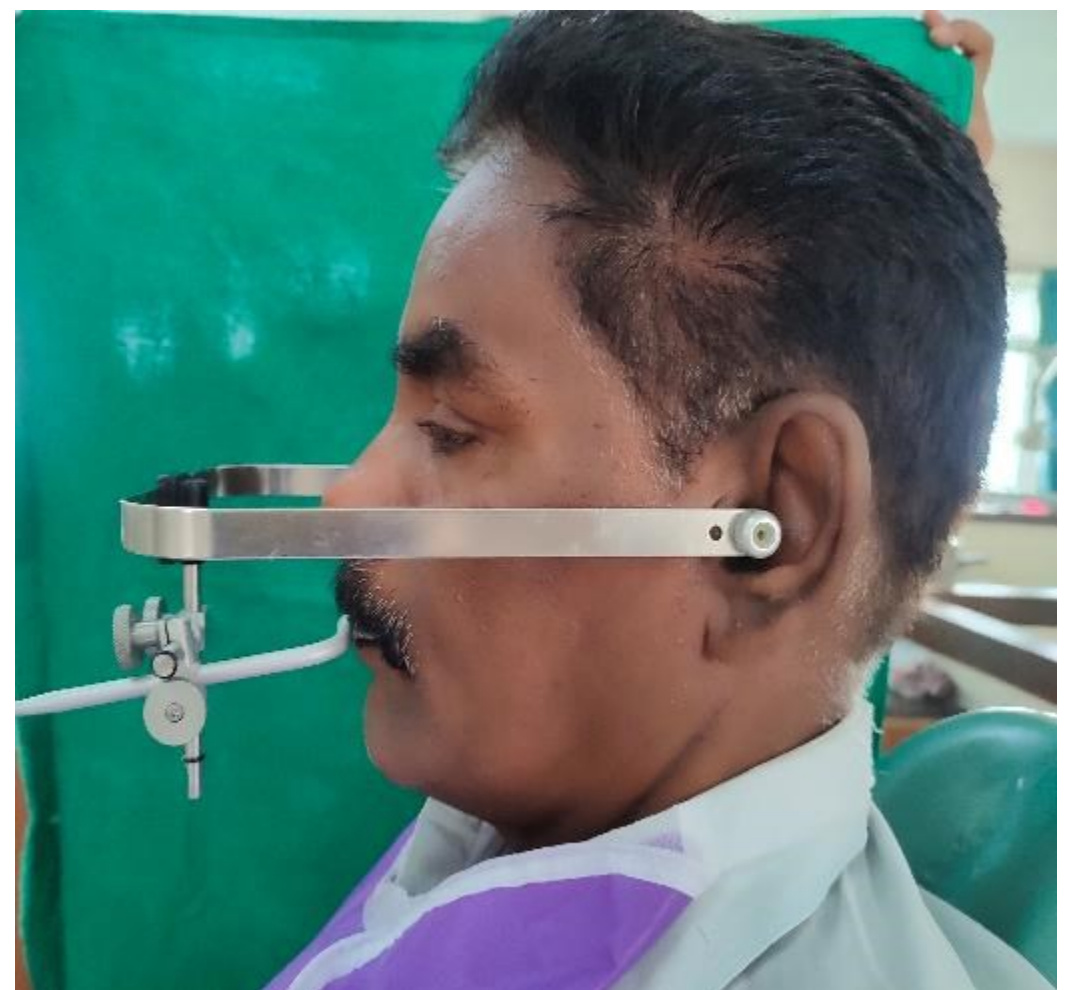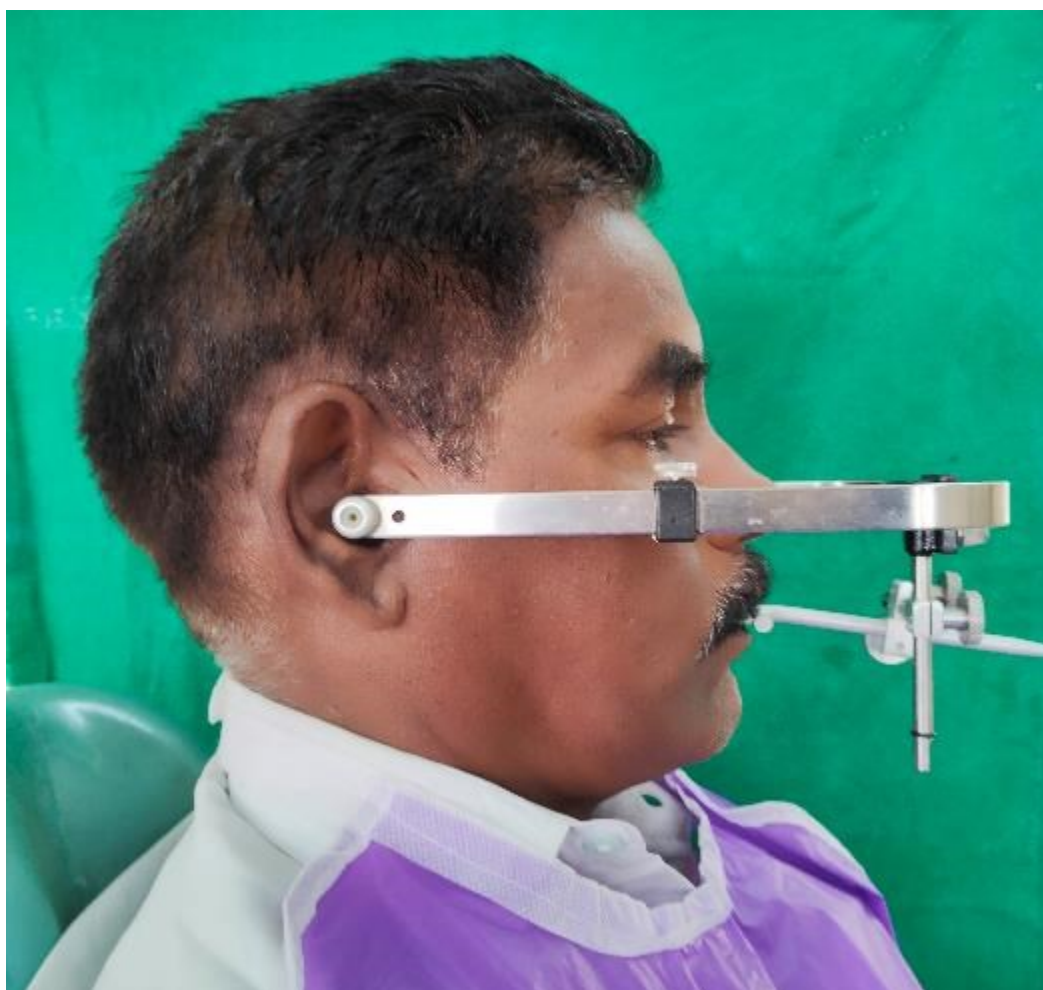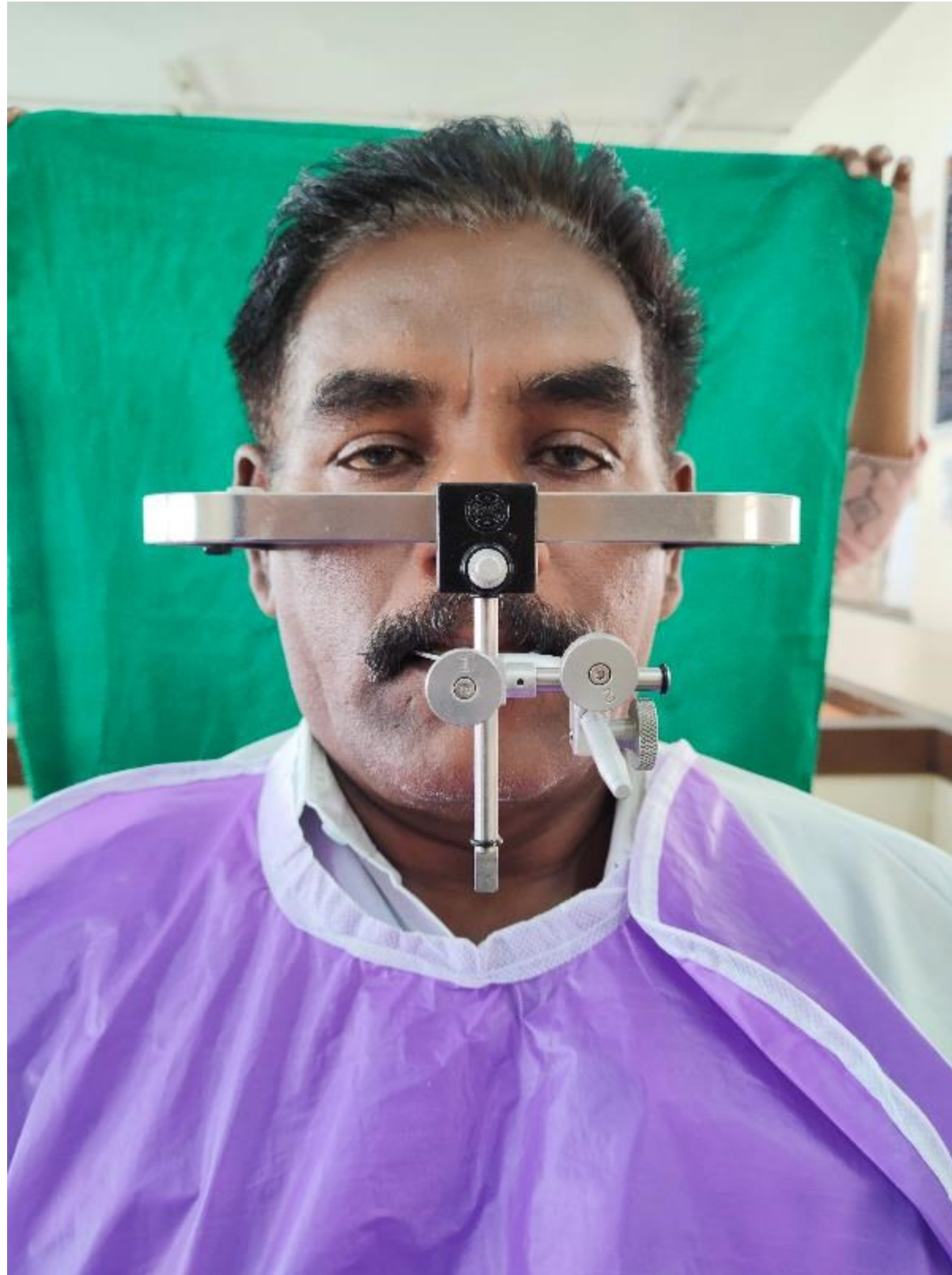BORDER MOULDING AND SECONDARY IMPRESSION



MASTER CAST



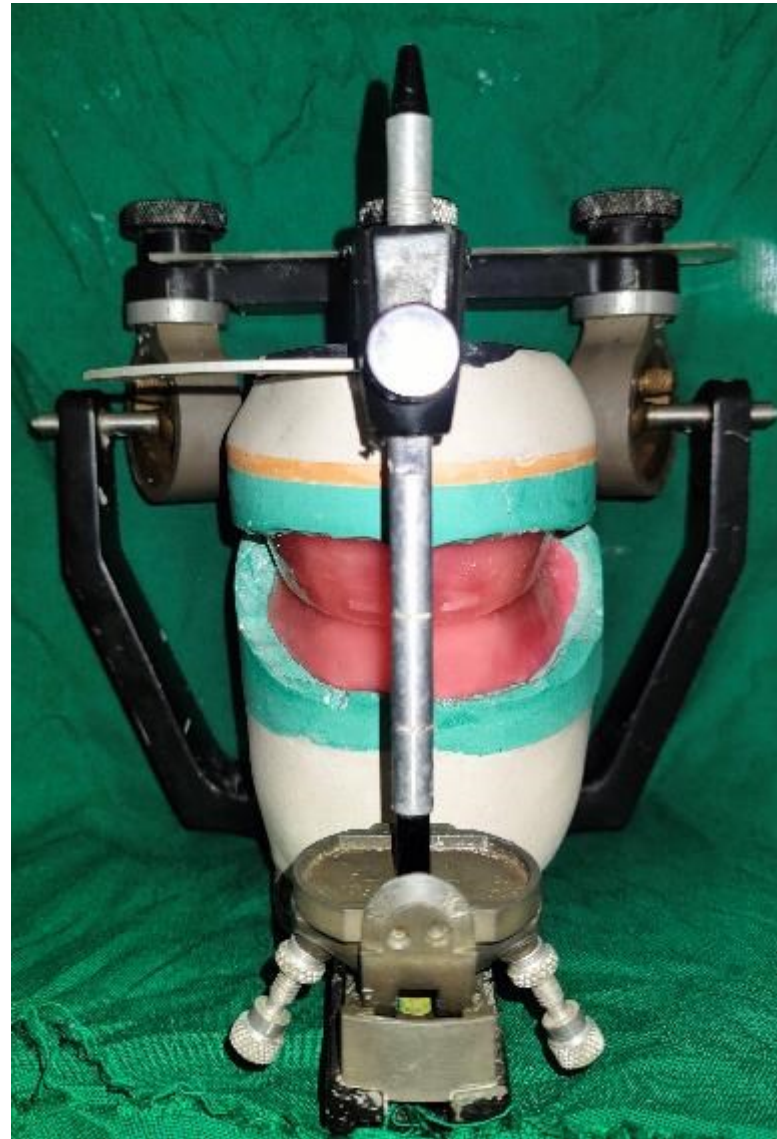FACE BOW





FACEBOW TRANSFER IN HANAU ARTICULATOR



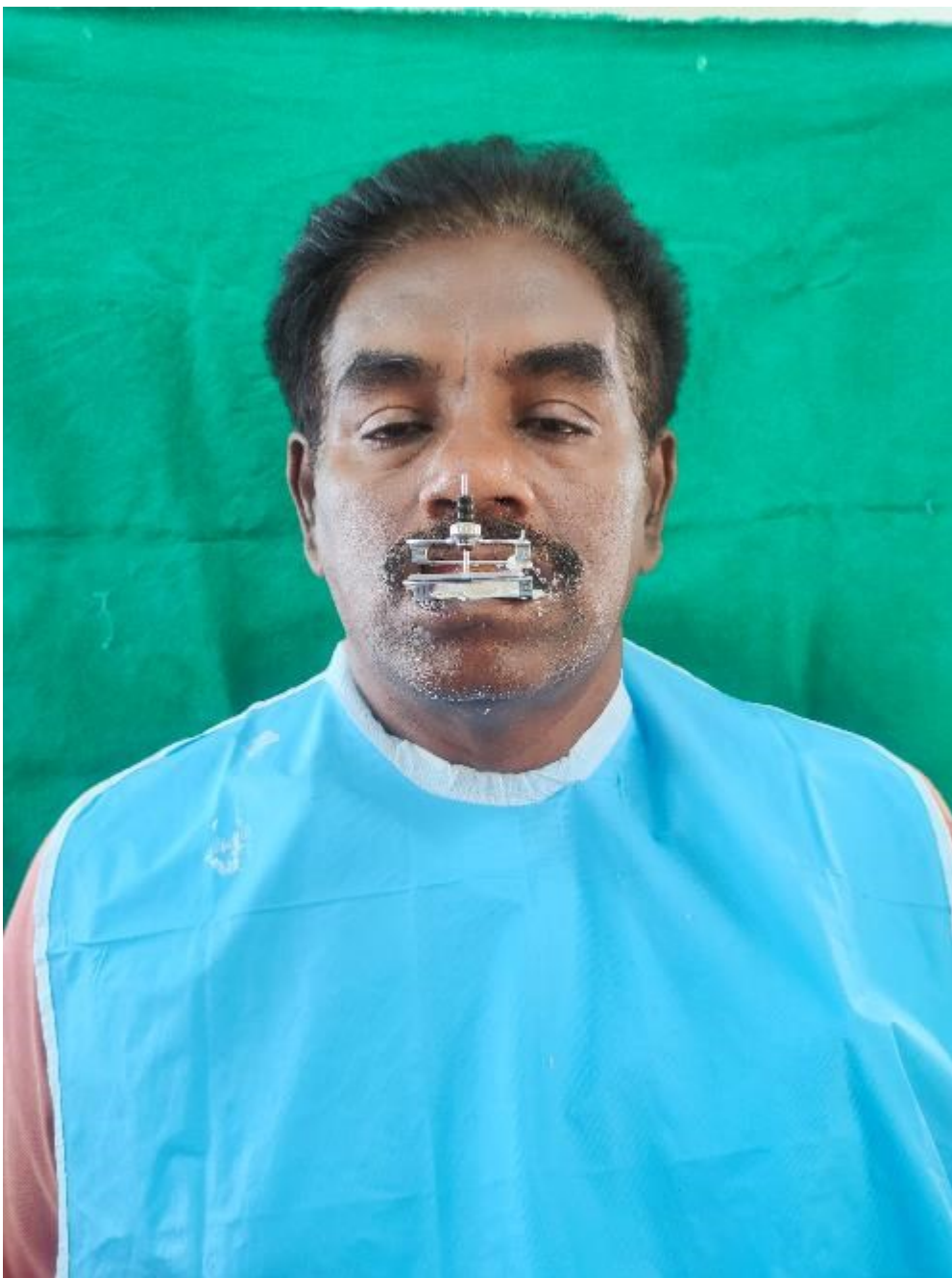
ARTICULATION DONE WITH SPLIT CAST



TRACERS ATTACHED TO THE OCCLUSAL RIMS

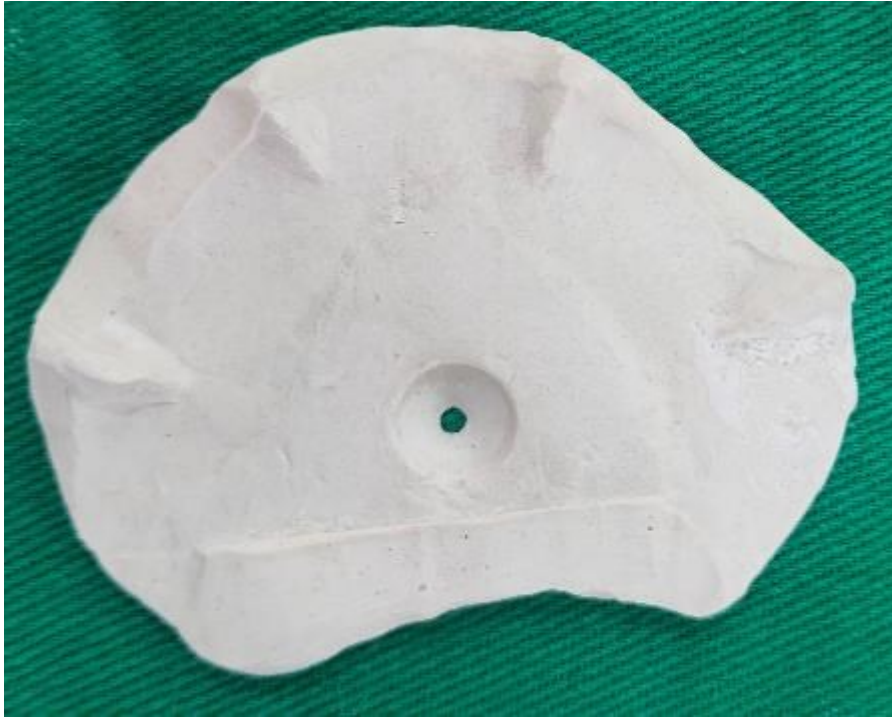

GOTHIC ARCH TRACING AND INTEROCCLUSAL RECORDS TAKEN

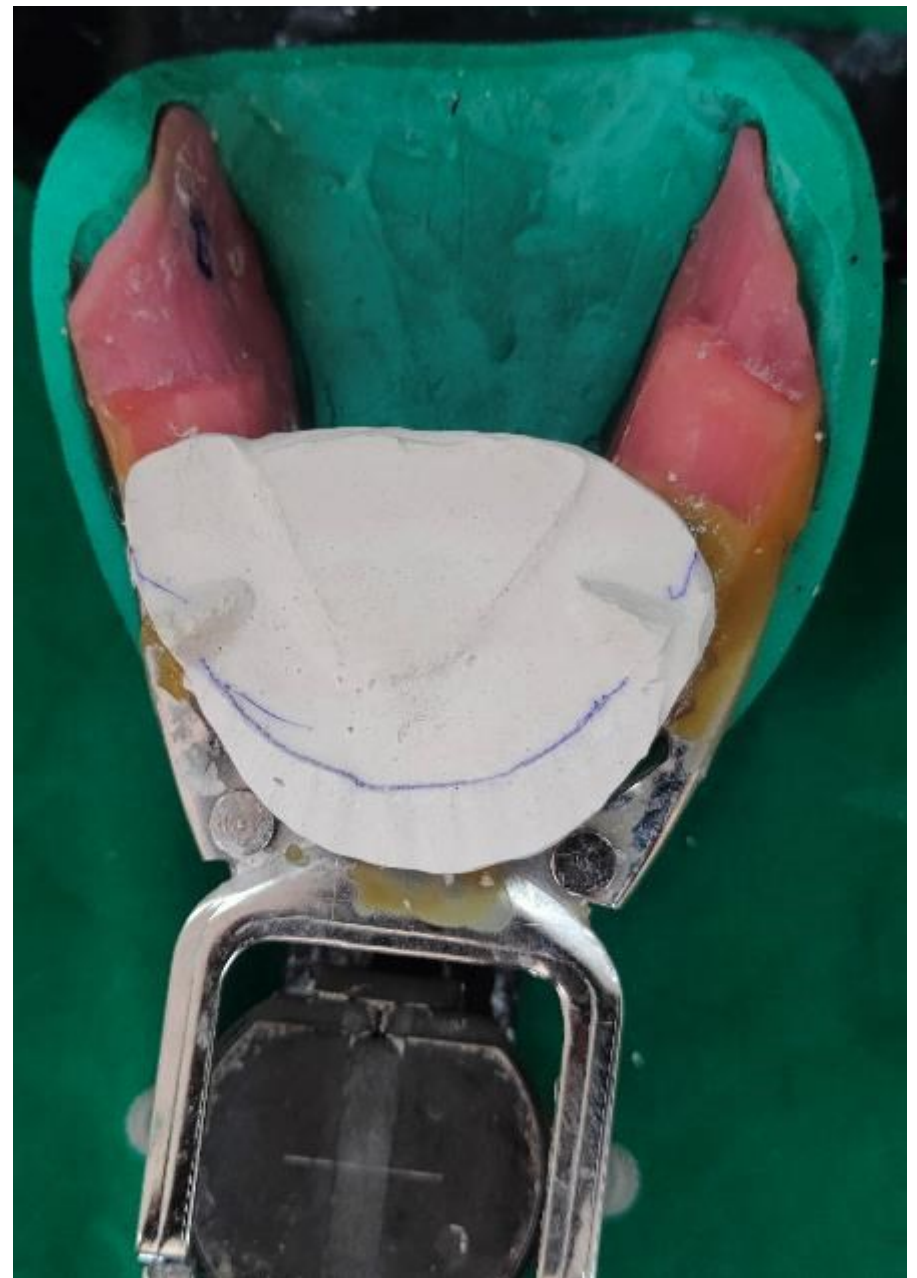
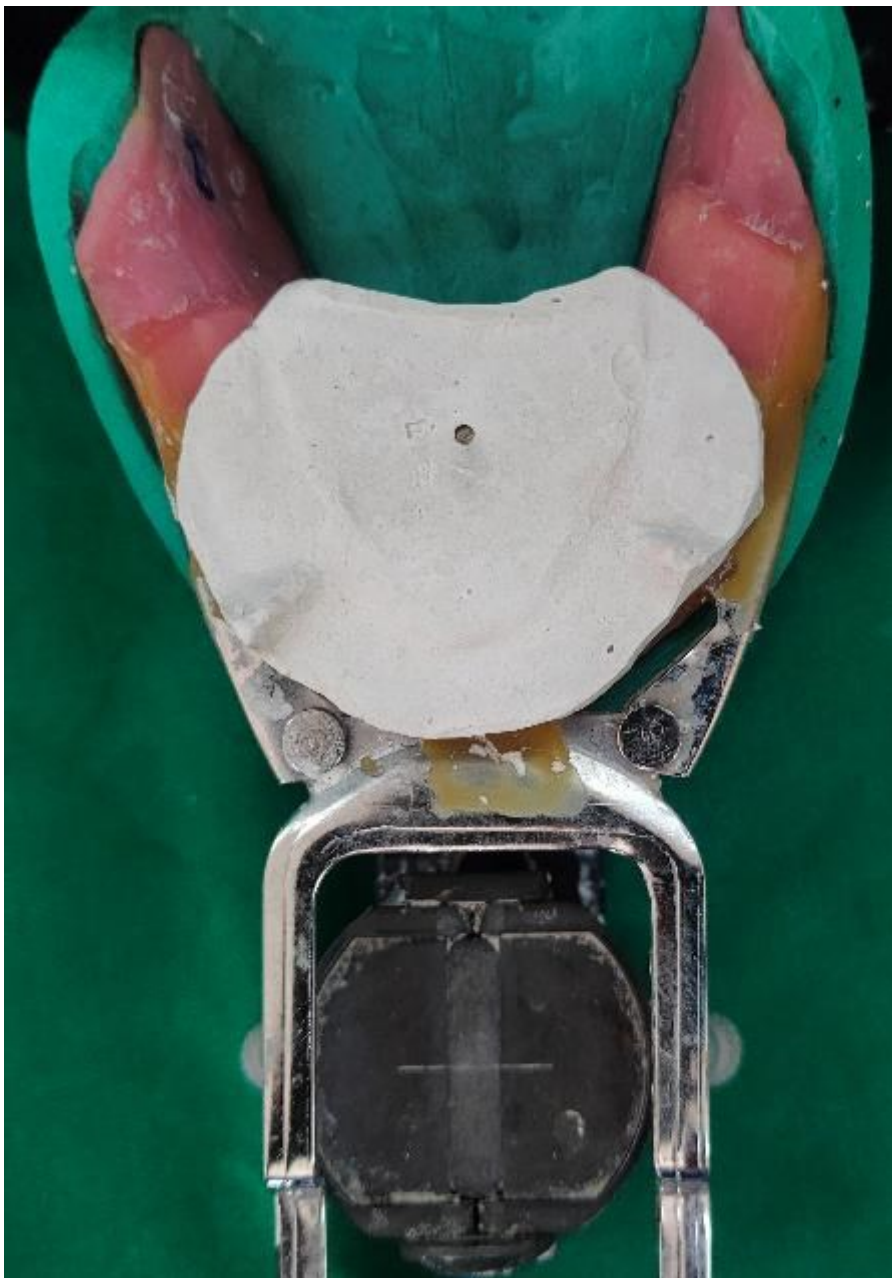
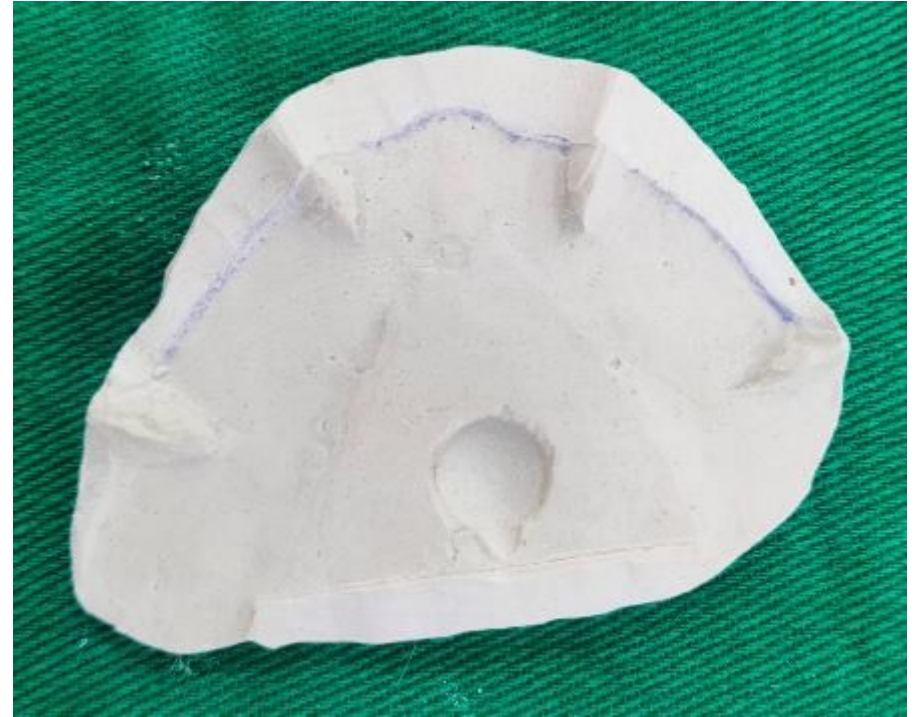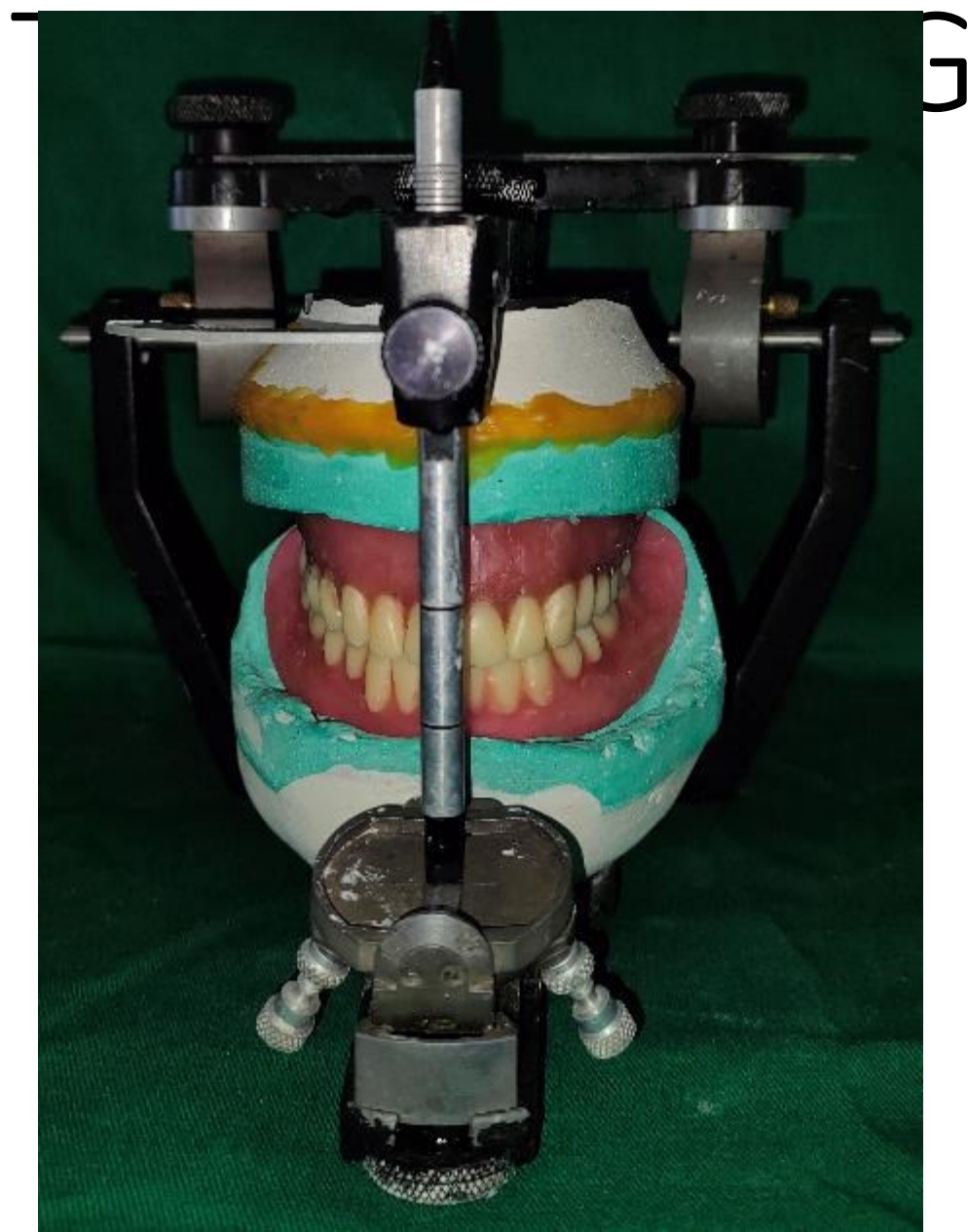INTEROCCLUSAL RECORDS

CENTRIC RECORD



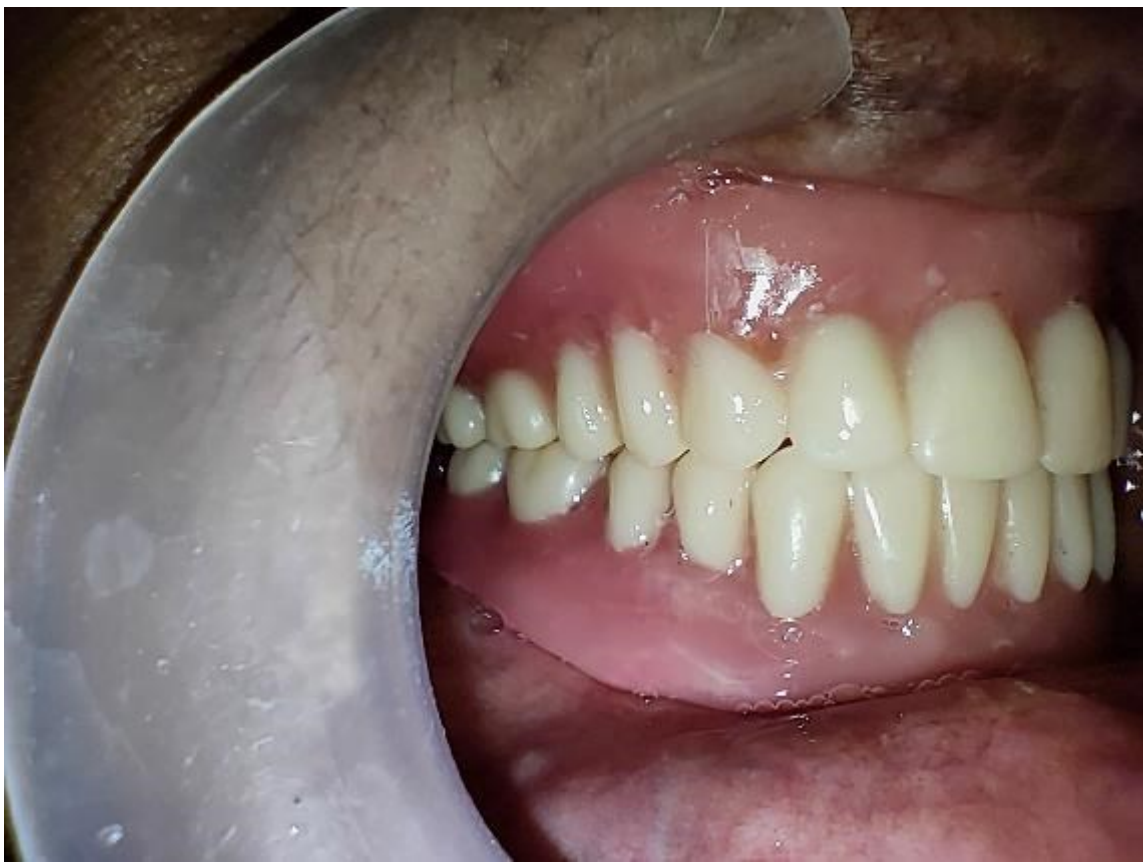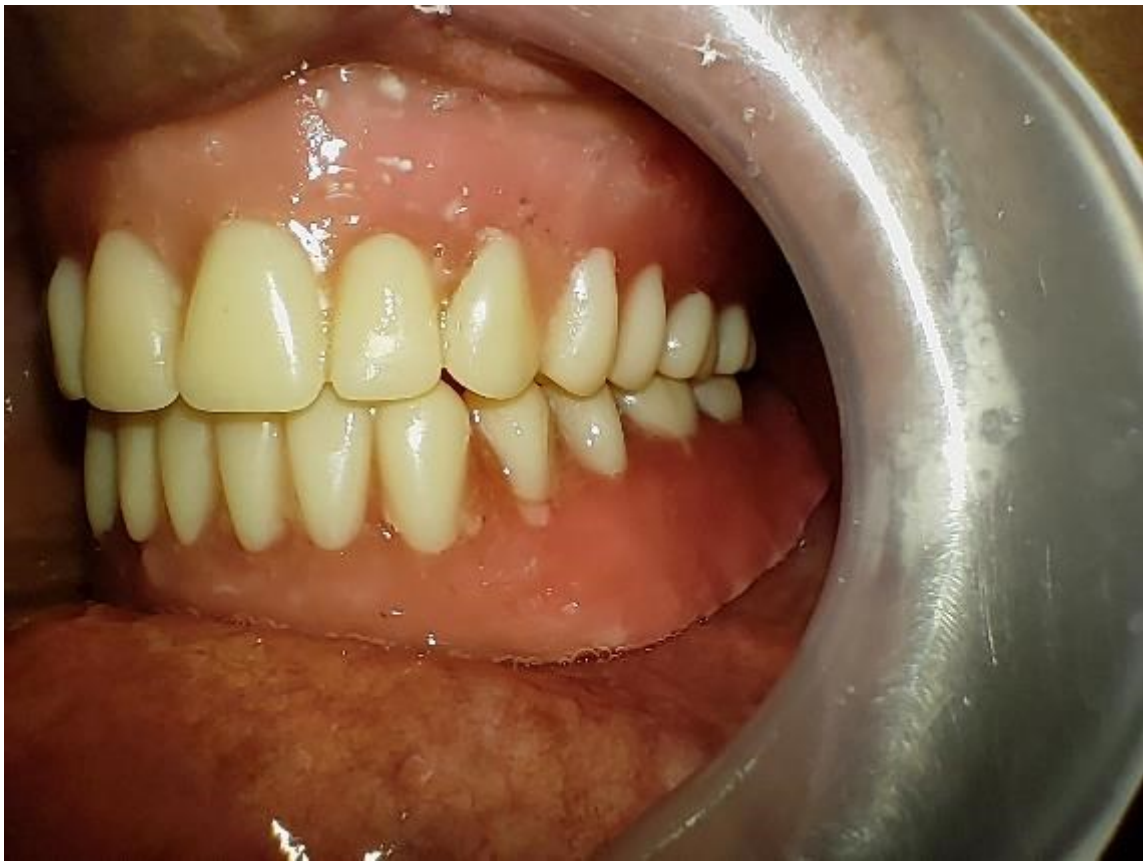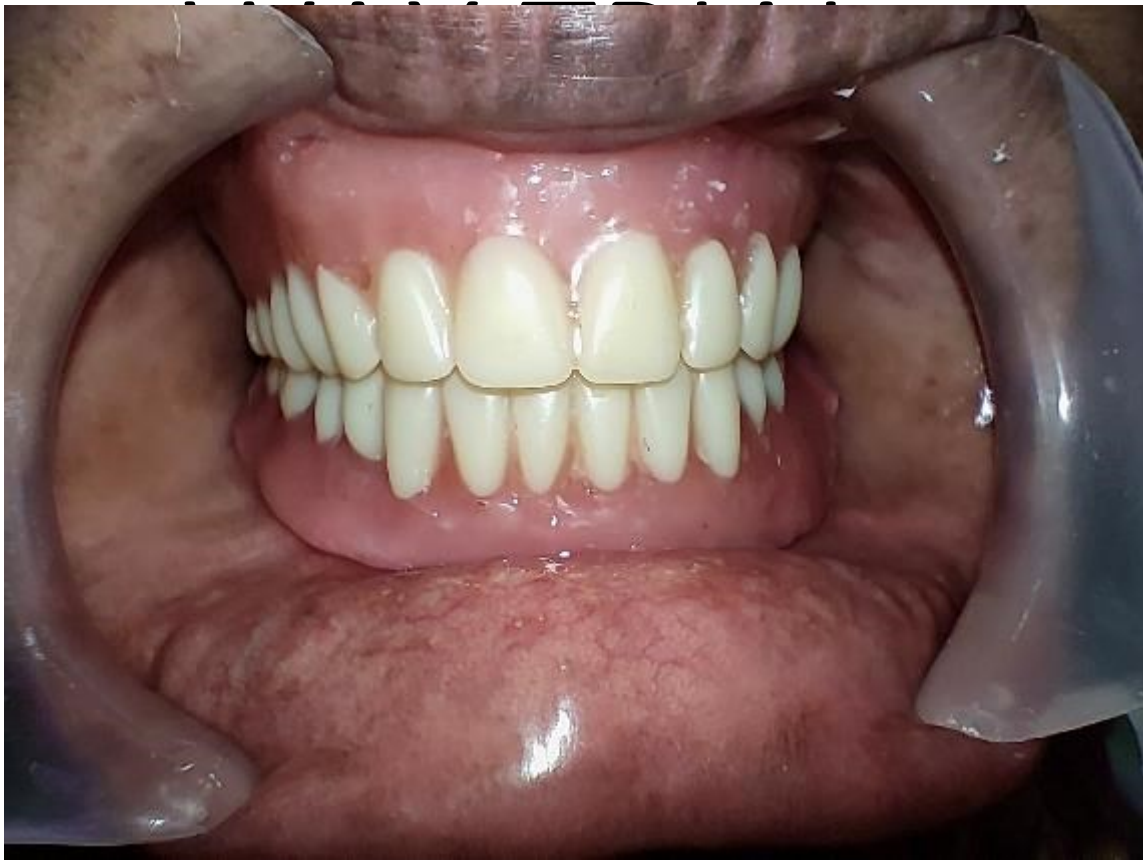PROTRUSIVE RECORD





G



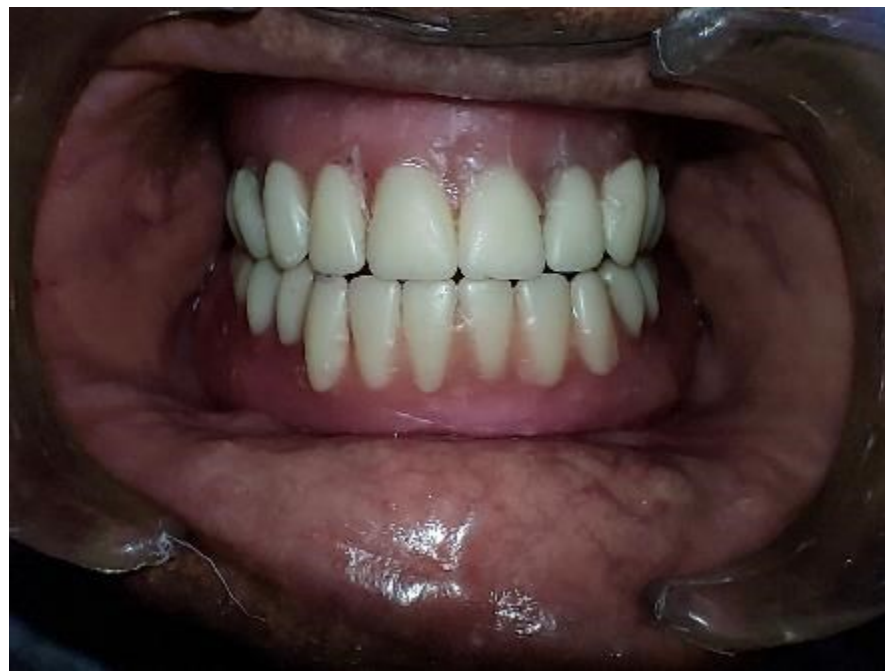

BALANCING

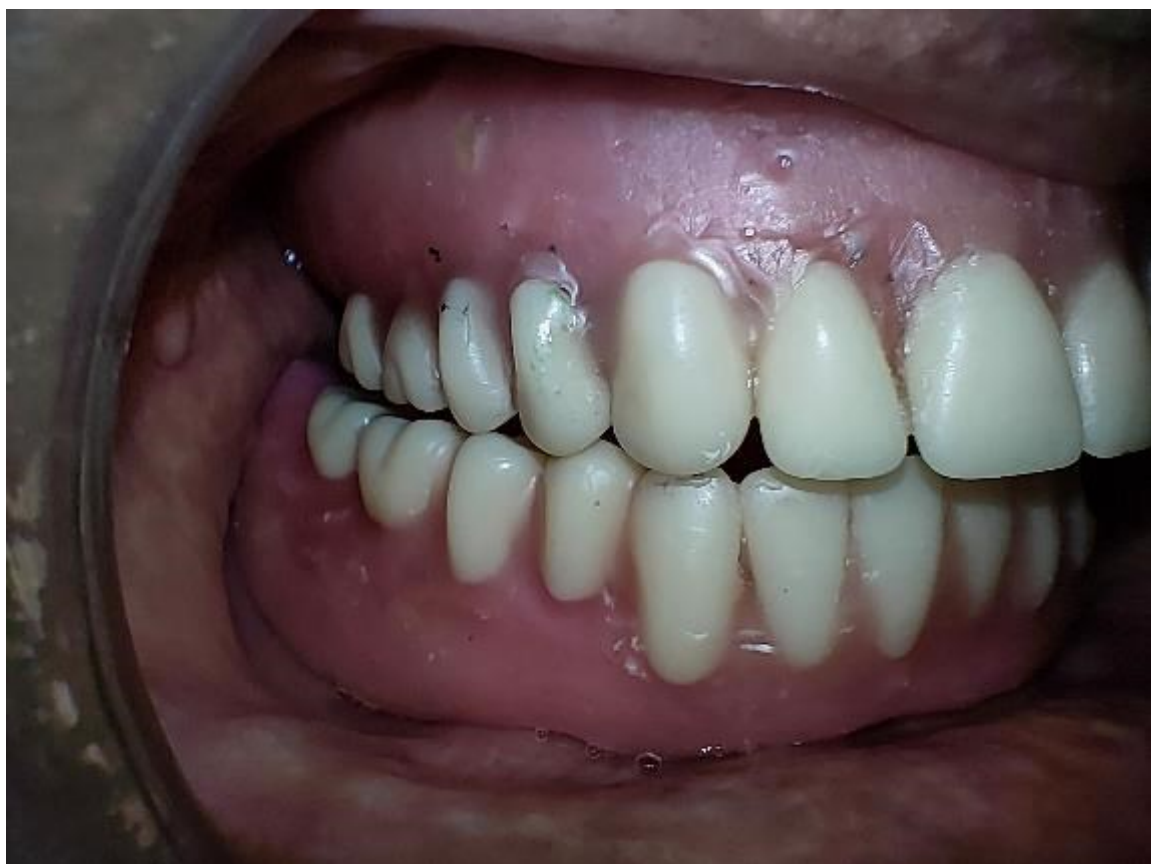BALANCING CONTACTS IN ARTICULATOR



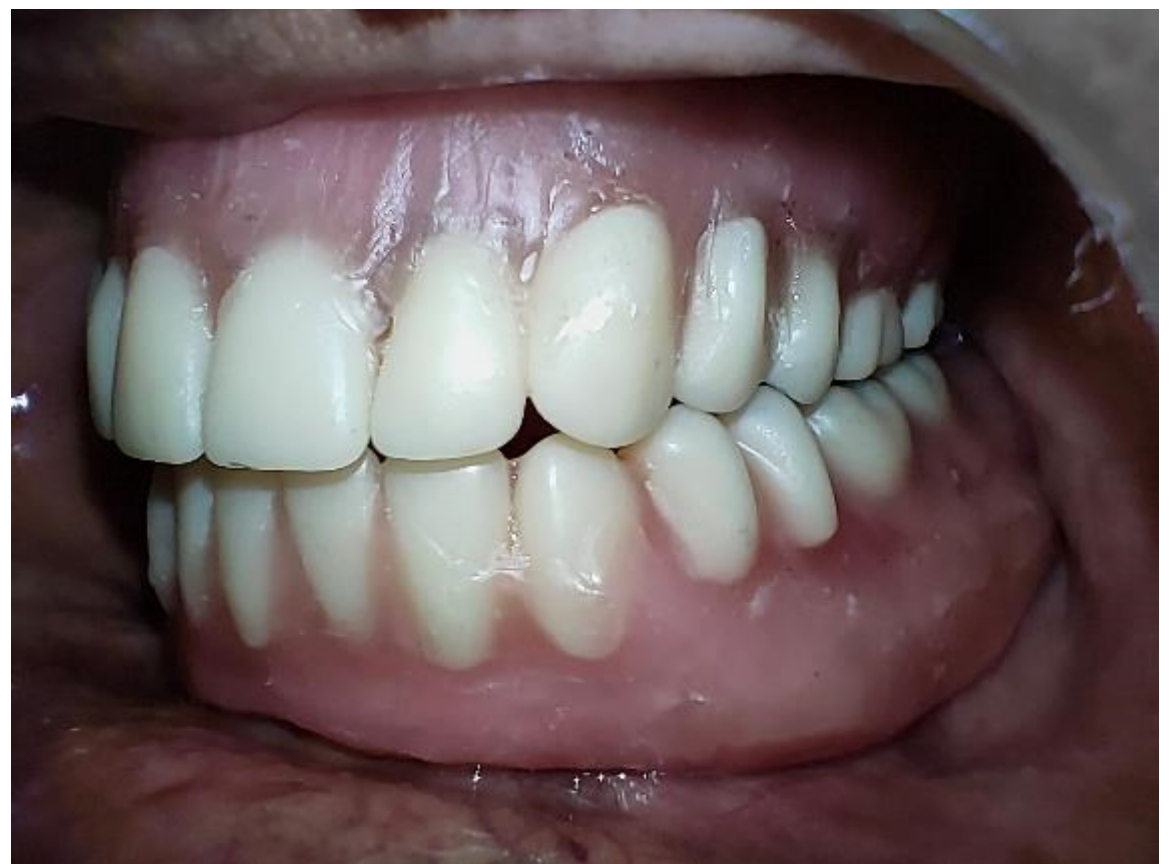PROTRUSIVE BALANCE



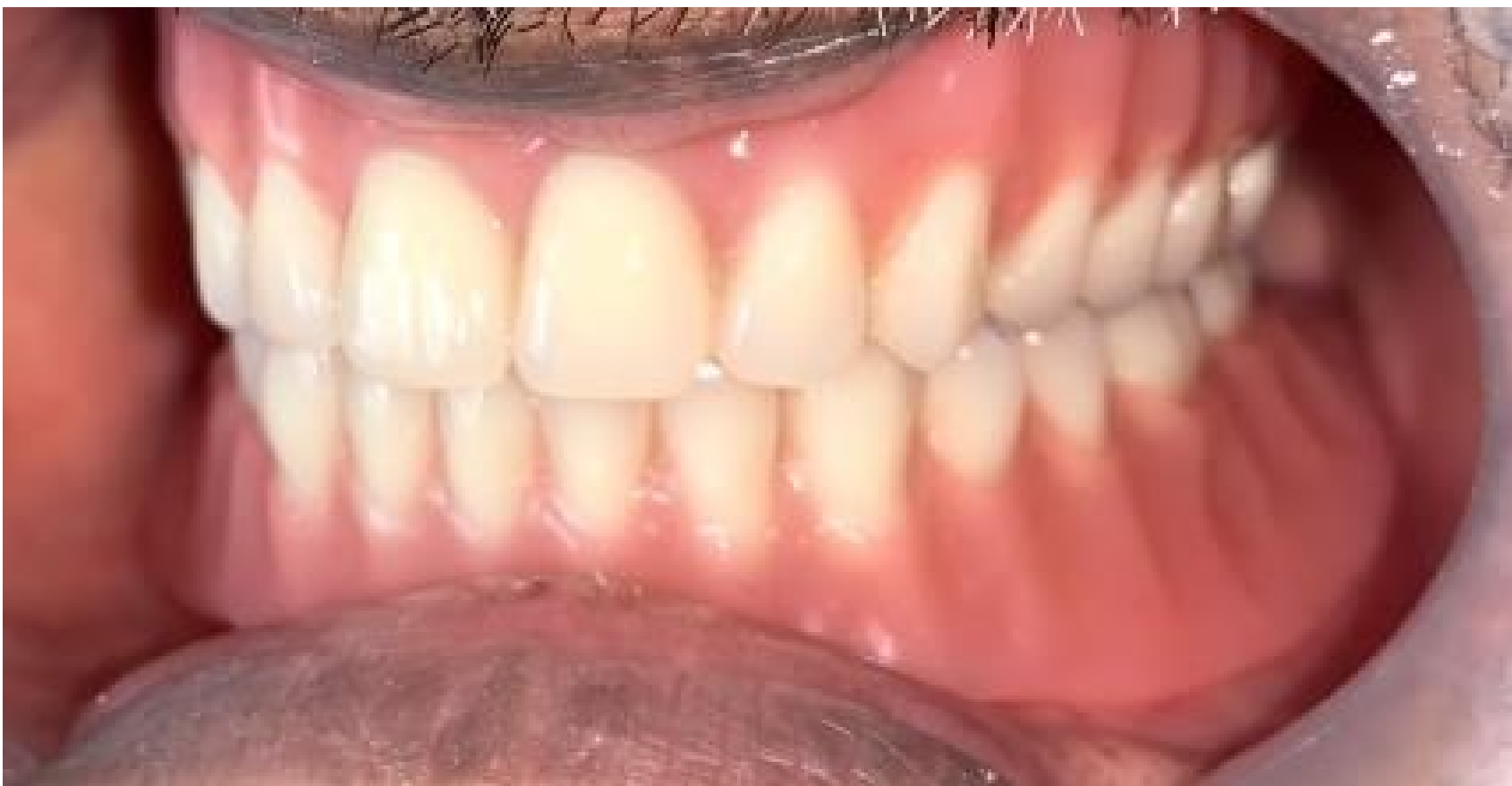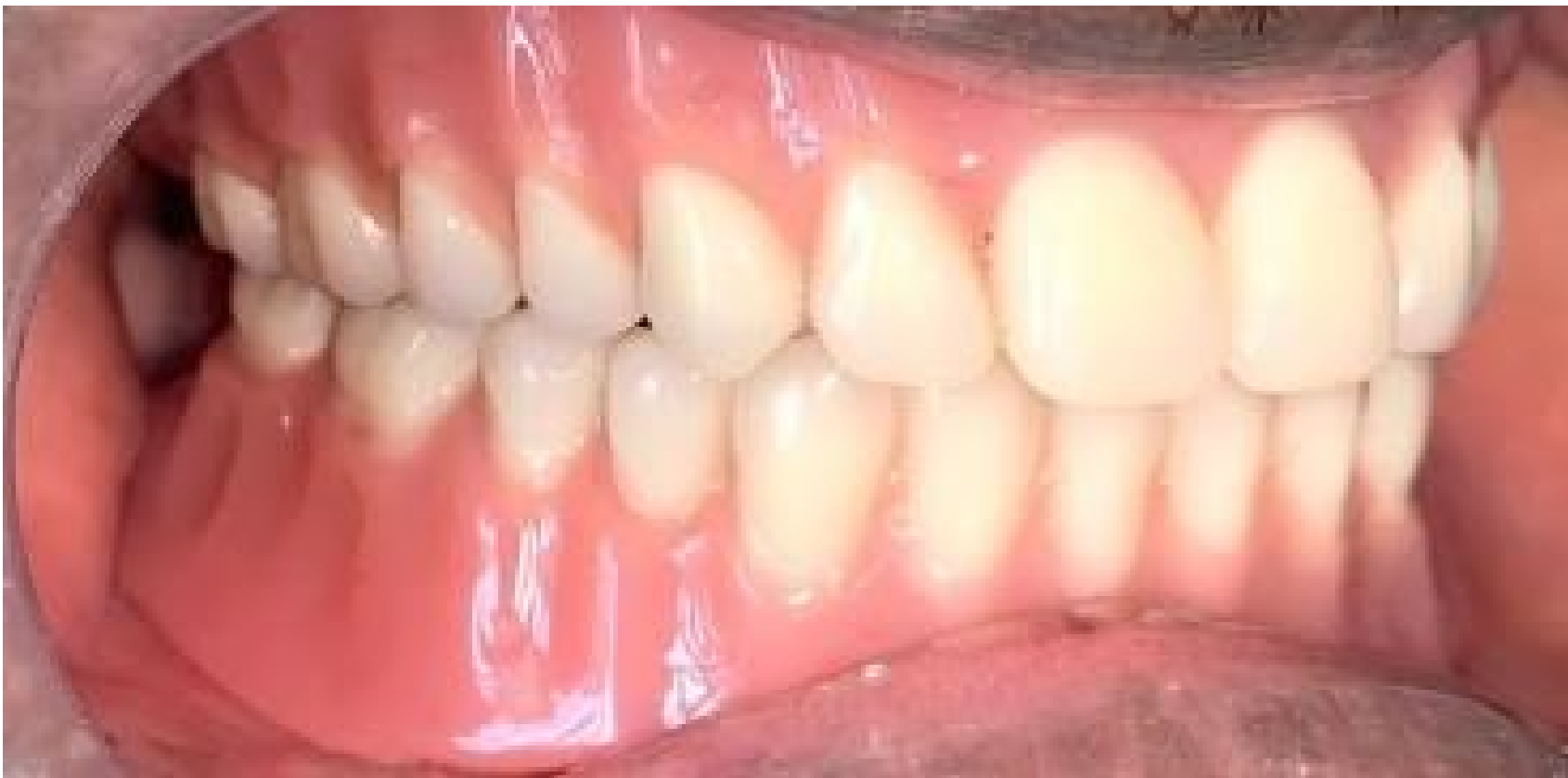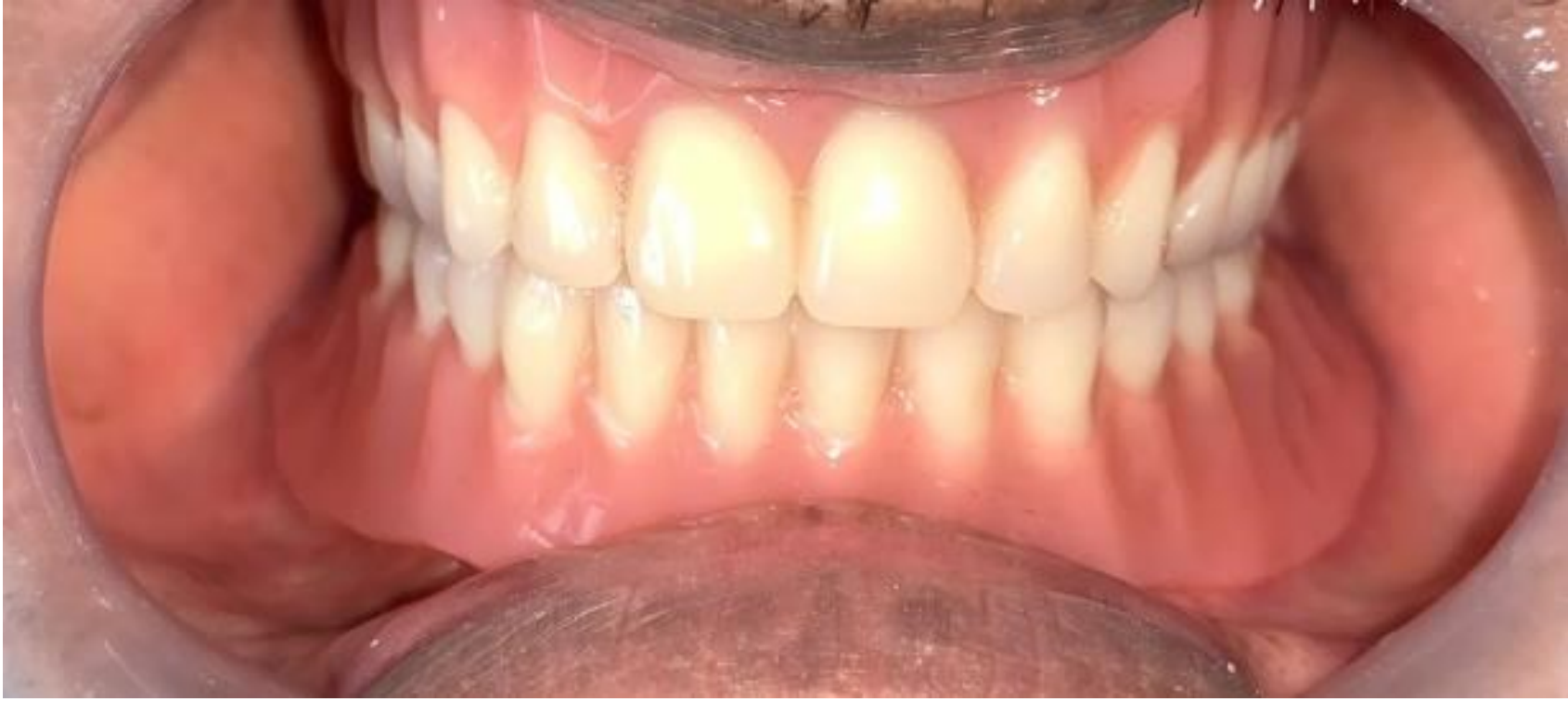RIGHT LATERAL BALANCE



LEFT LATERAL BALANCE



INSERTION

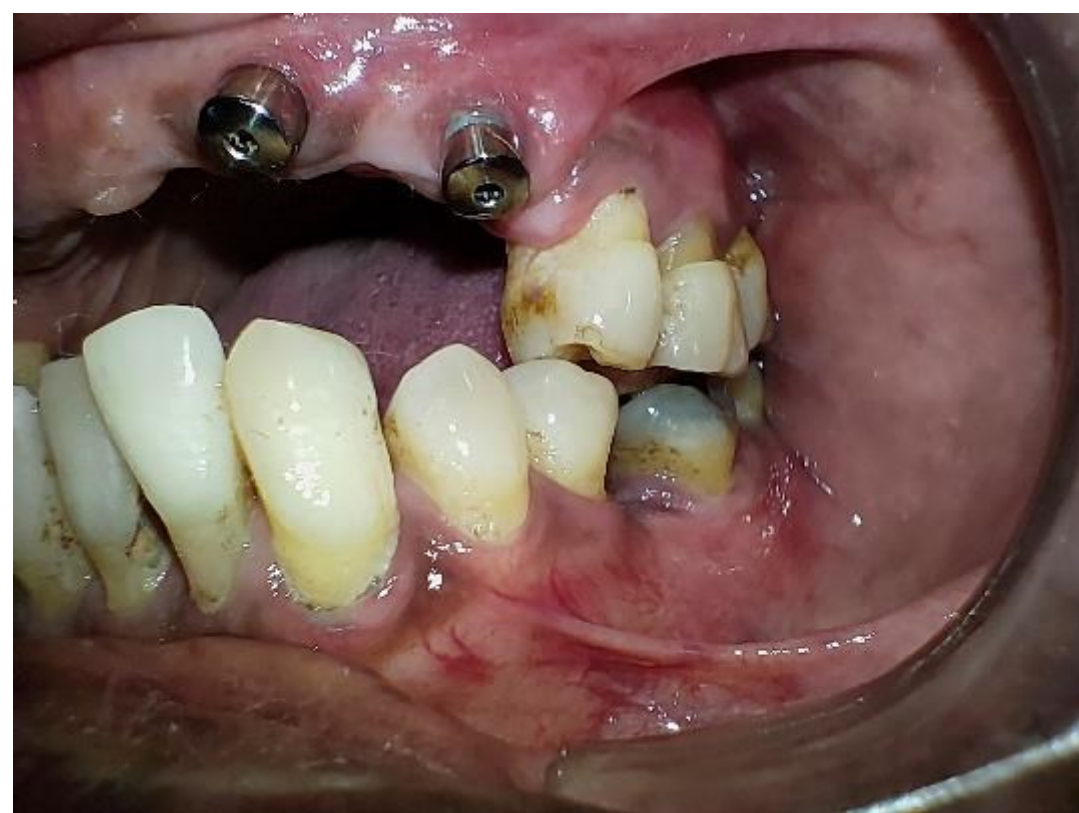
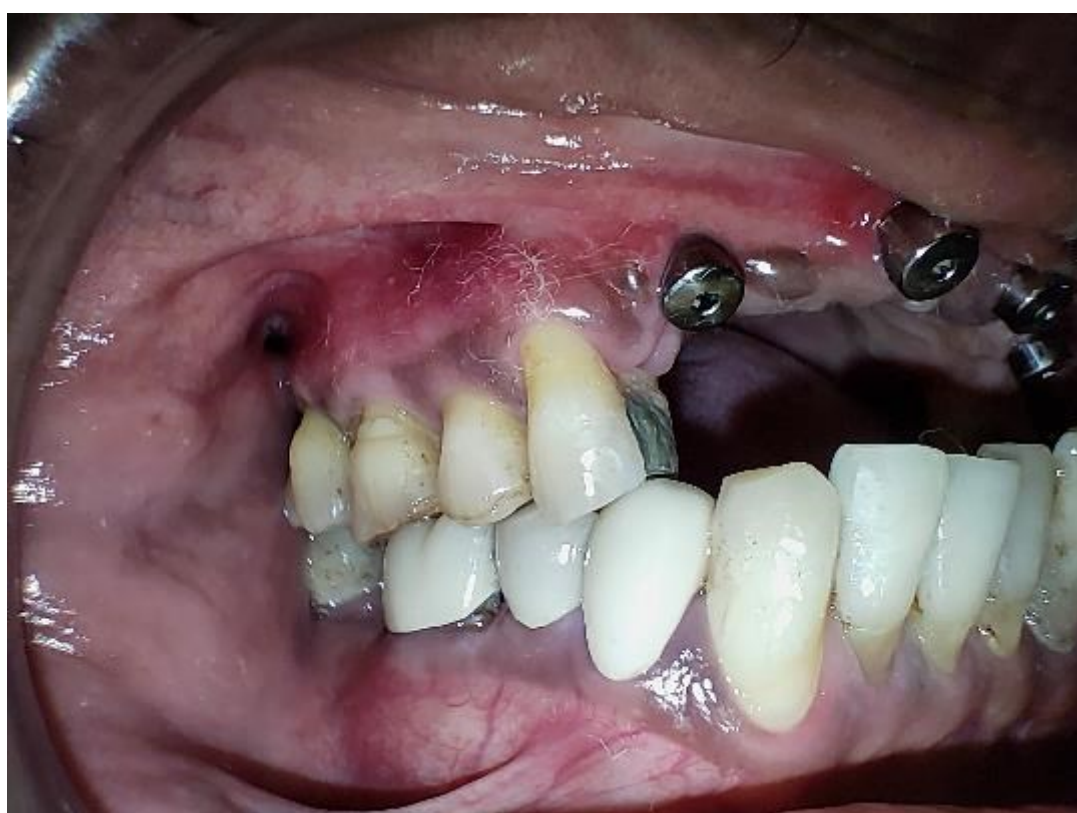
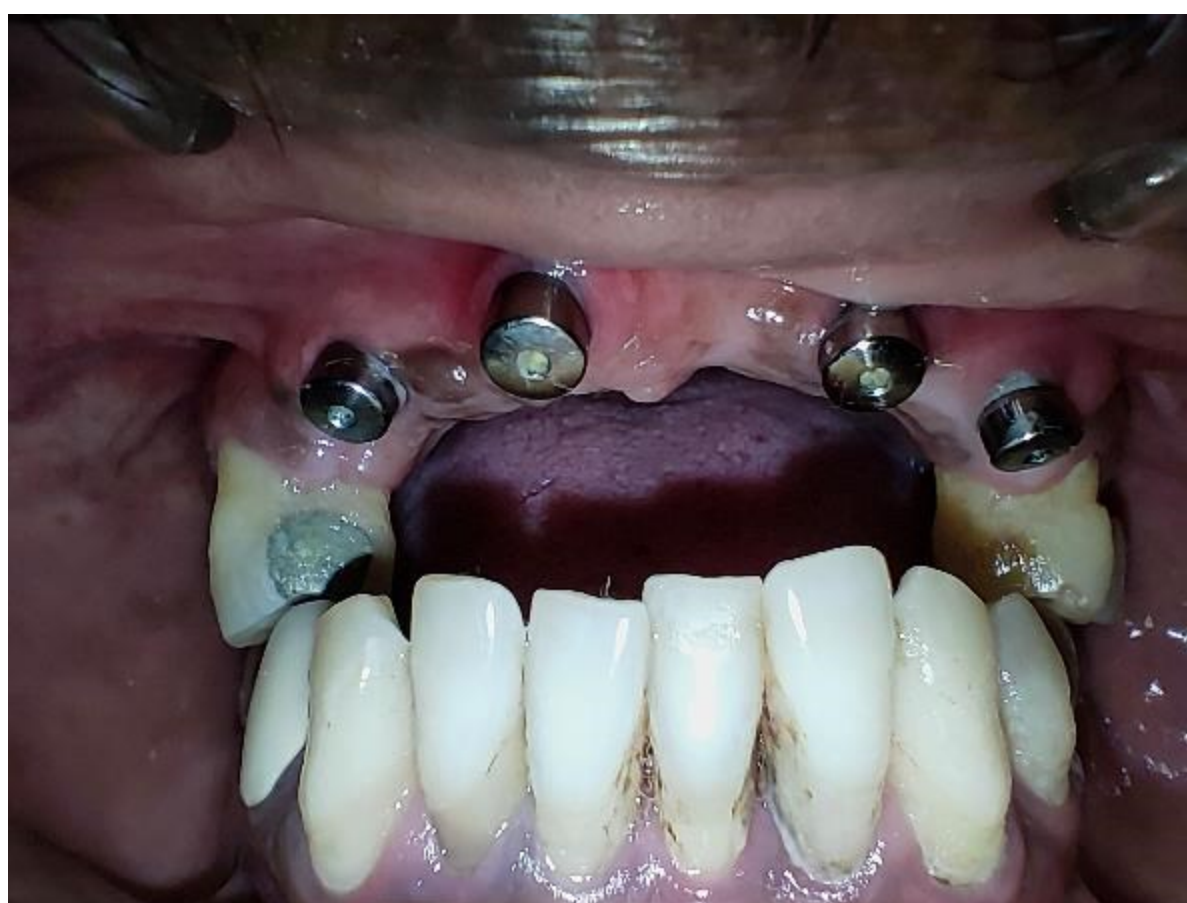ANTERIOR IMPLANTS REHABILITATION WITH MALO BRIDGE

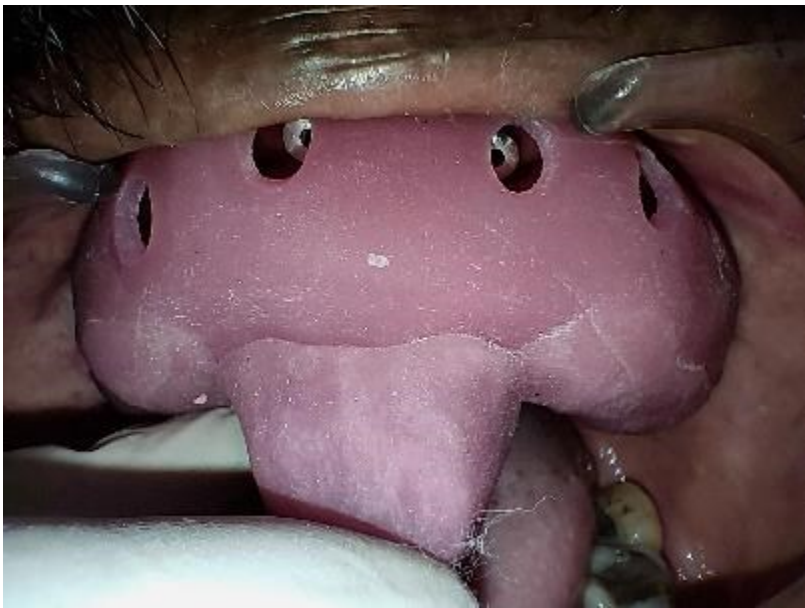PATIENT NAME: Mr. KALAISELVAN

RMCT: 485088

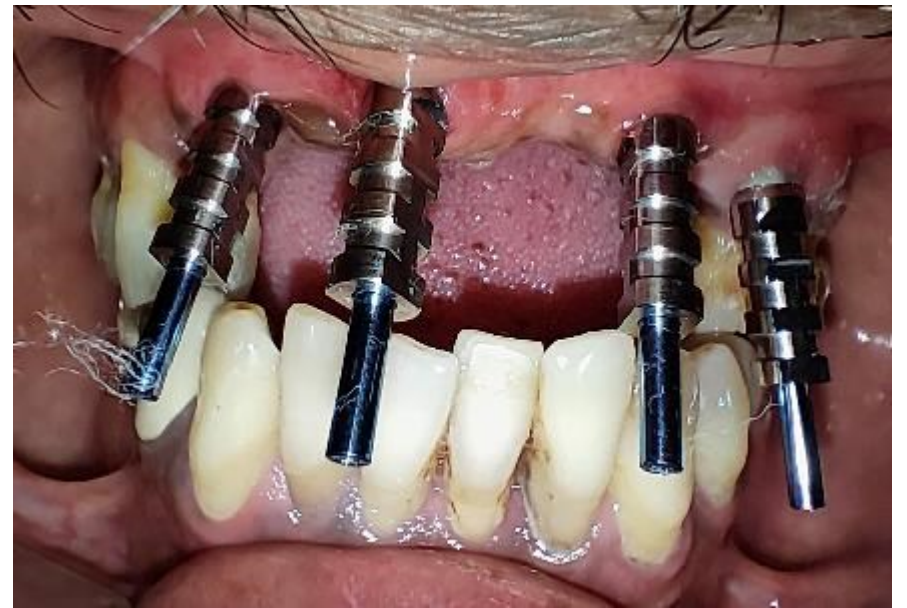PRE OP



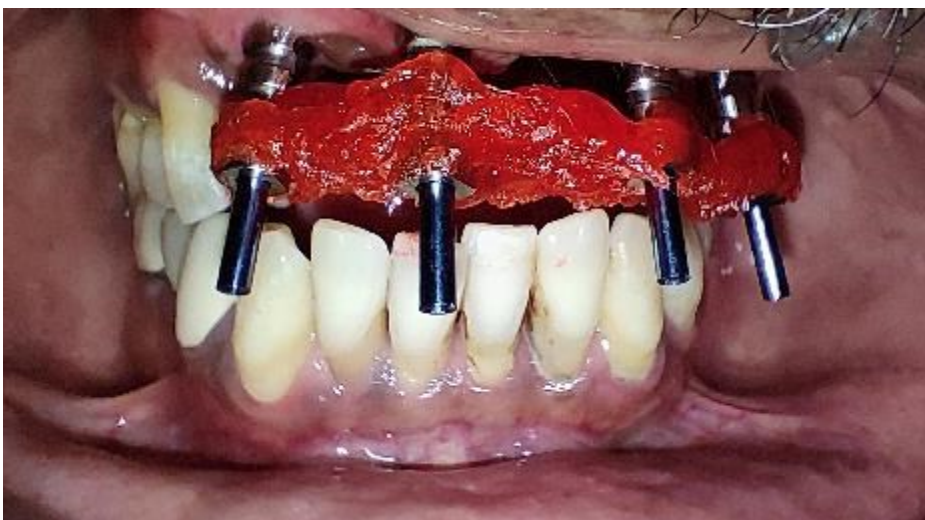IMPRESSION



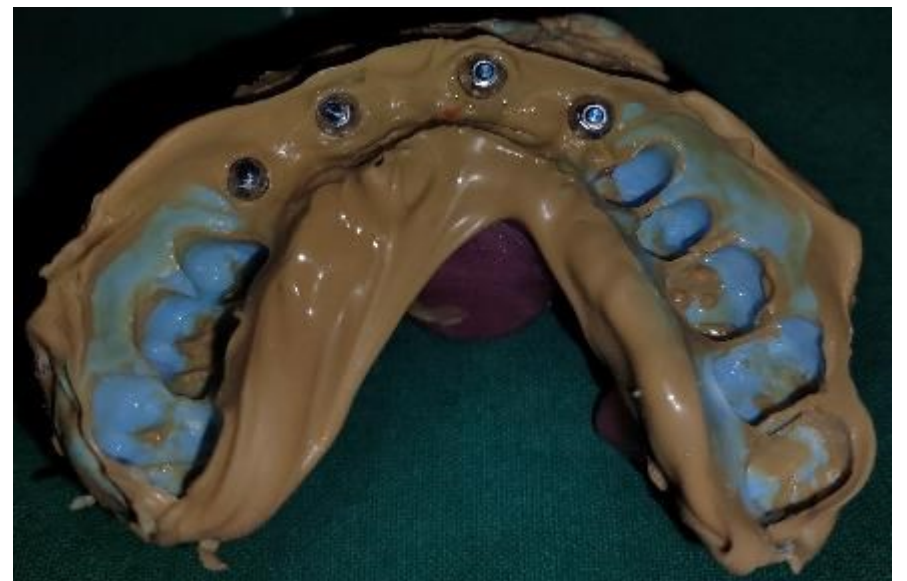SPECIAL TRAY



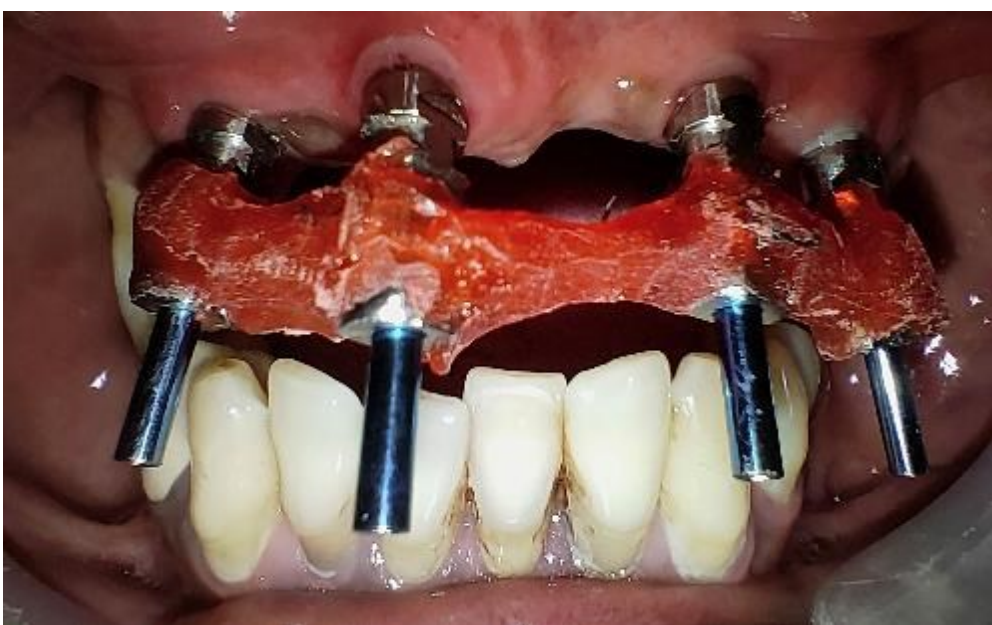OPEN TRAY IMPRESSION POSTS
PLACED



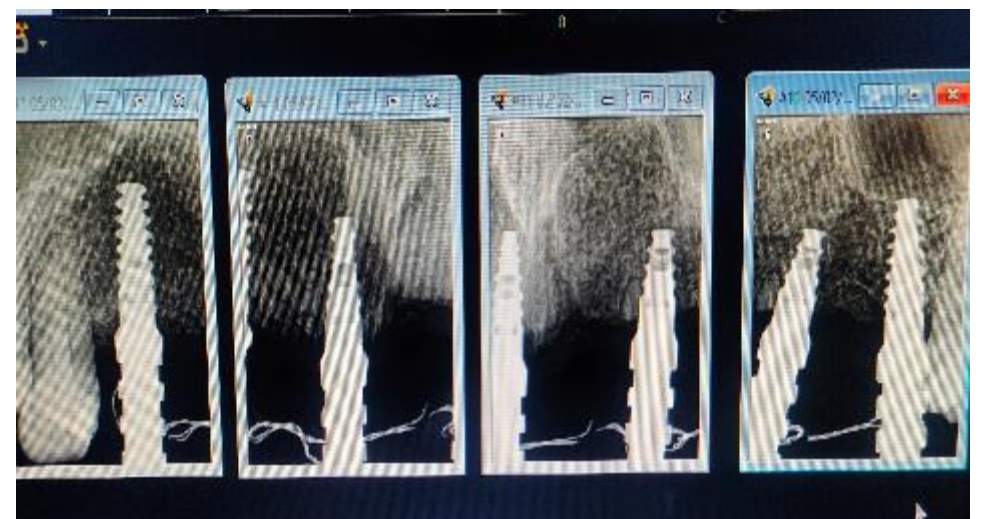
IMPRESSION POSTS SPLINTED
USING PATTERN RESIN



OPEN TRAY IMPRESSION USING
POLY VINYL SILOXANE MATERIAL

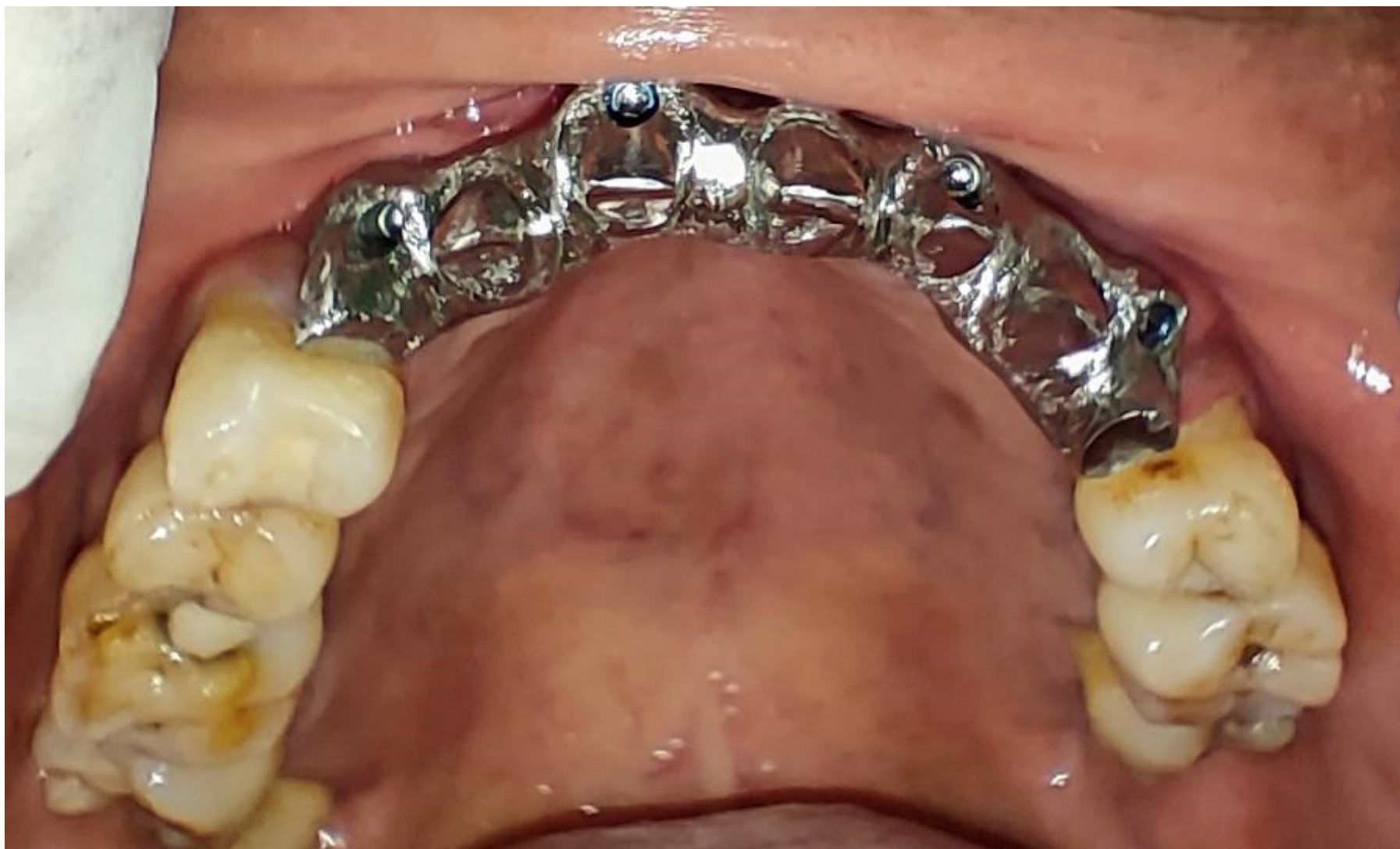
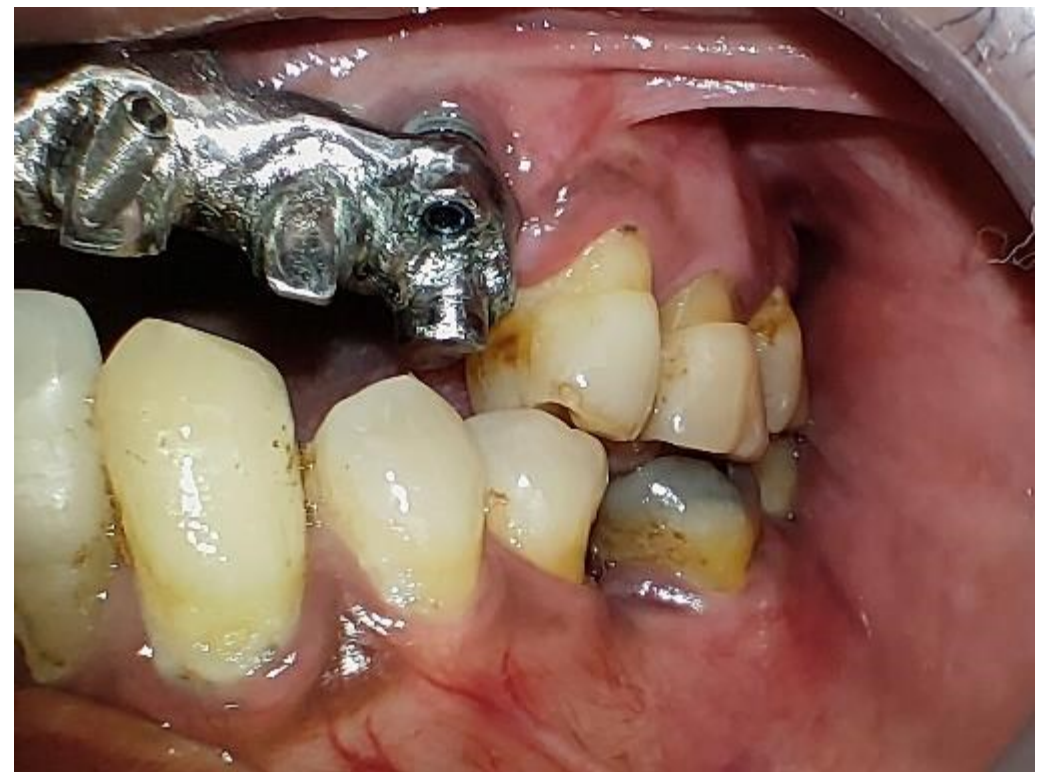
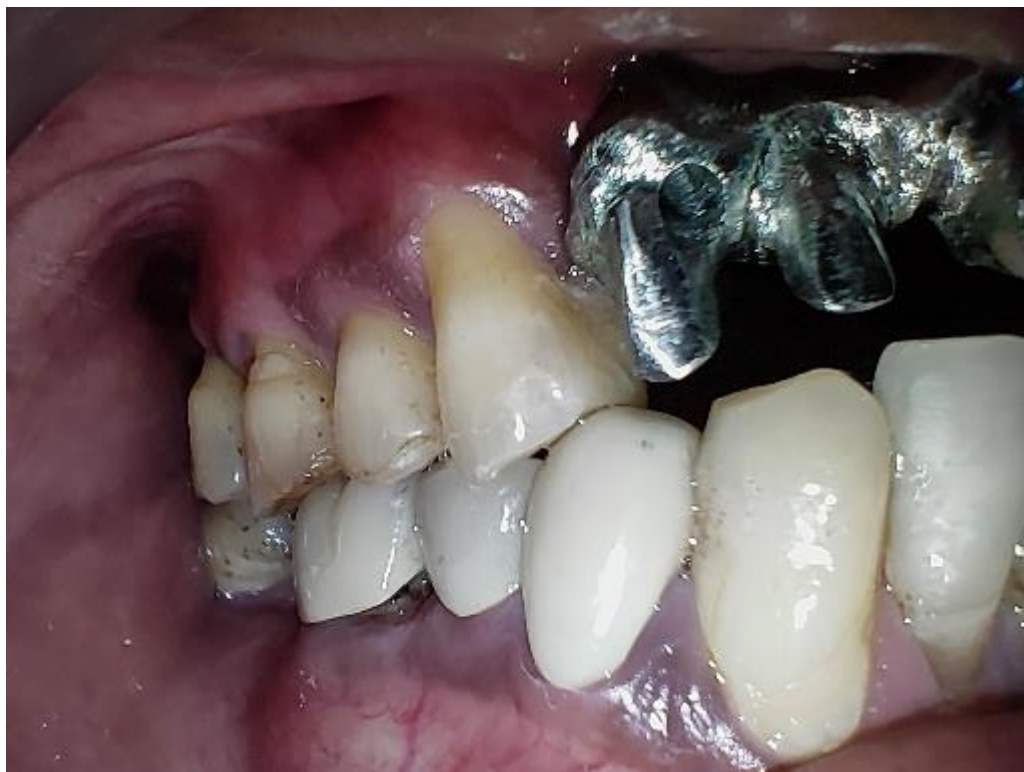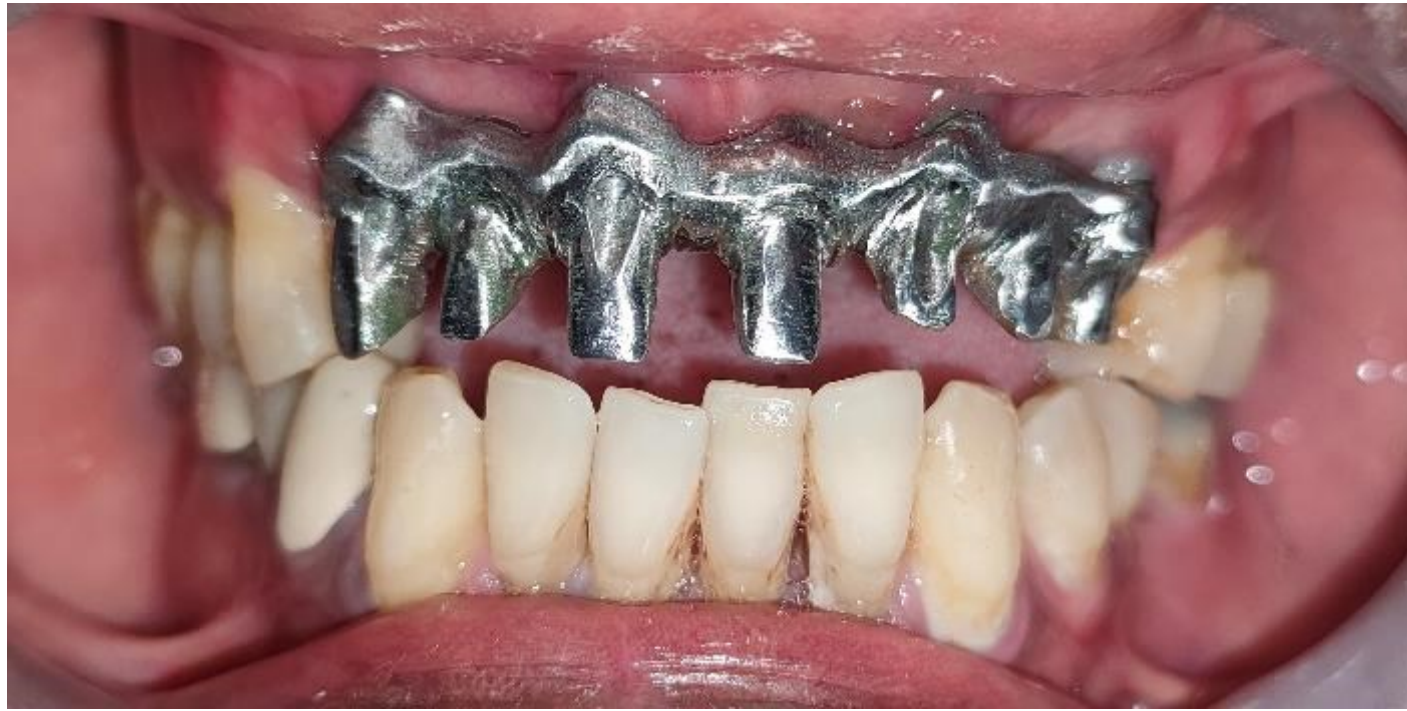JIG TRIAL

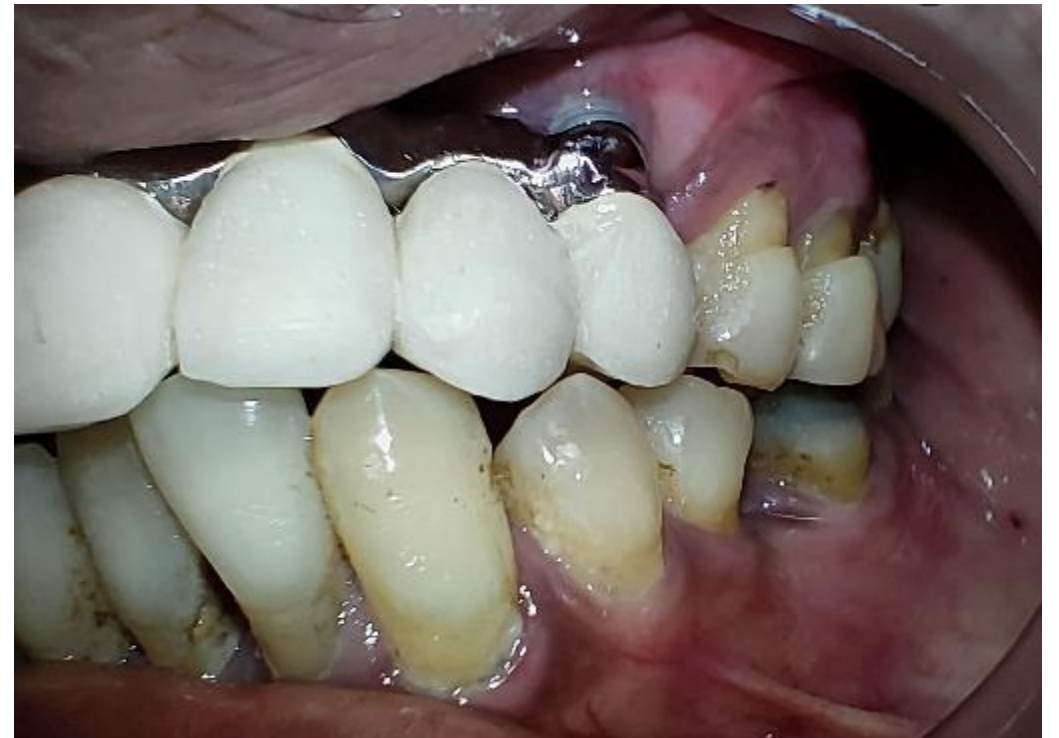
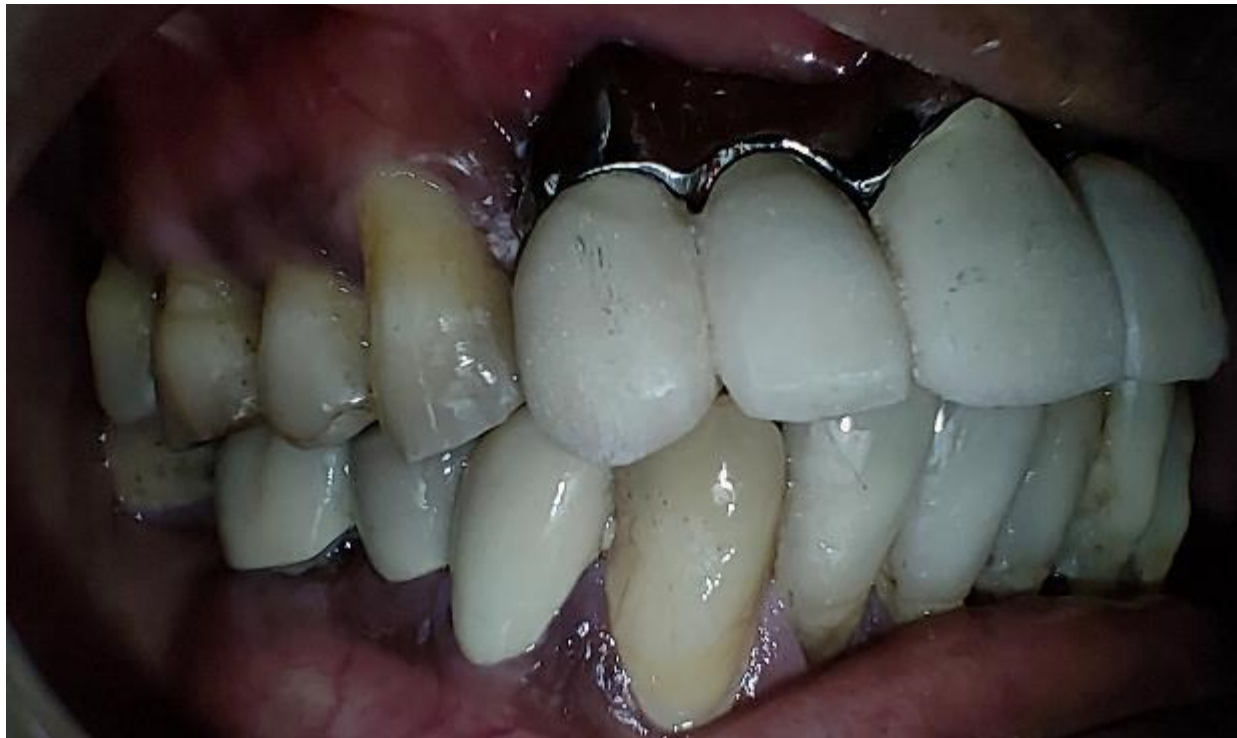
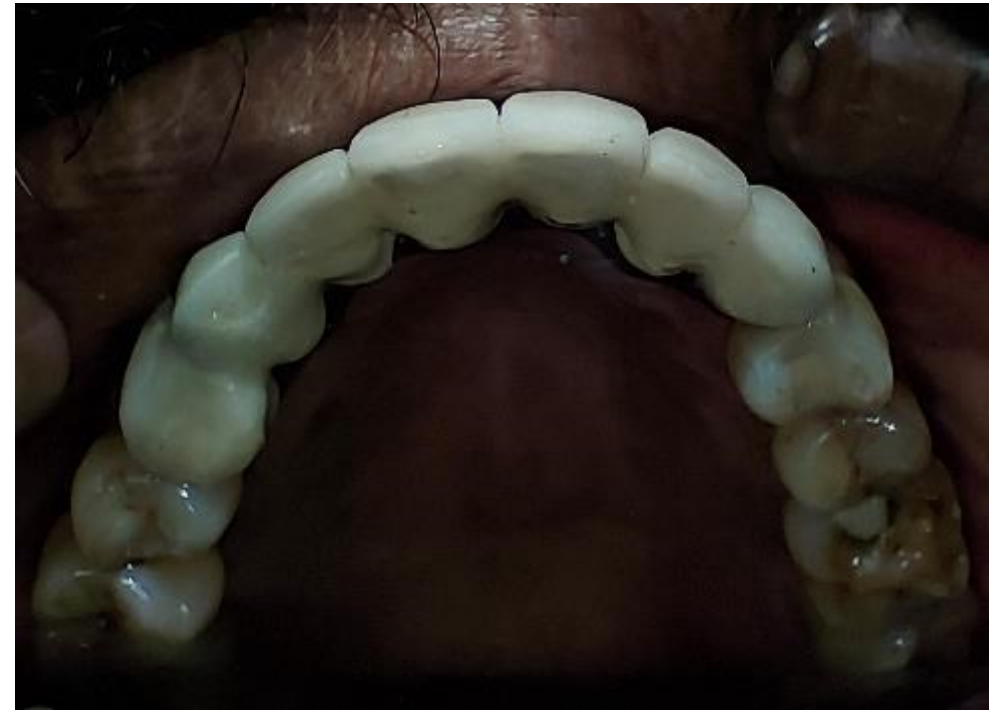
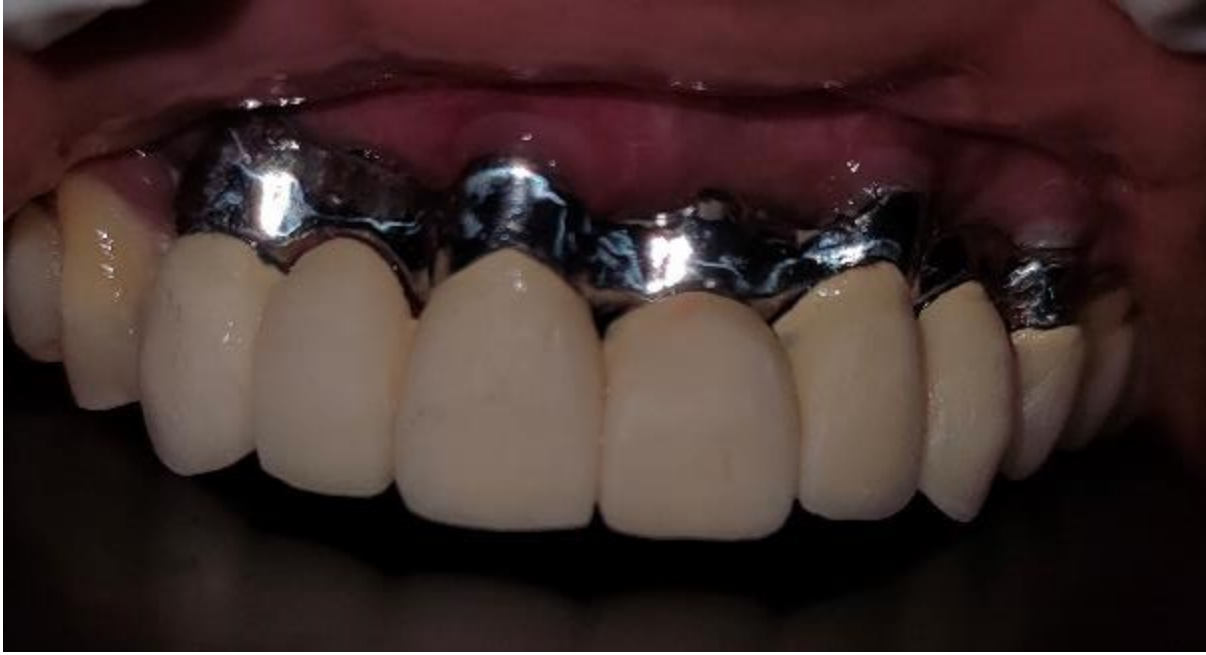RADIOGRAPHS OF
JIG TRIAL

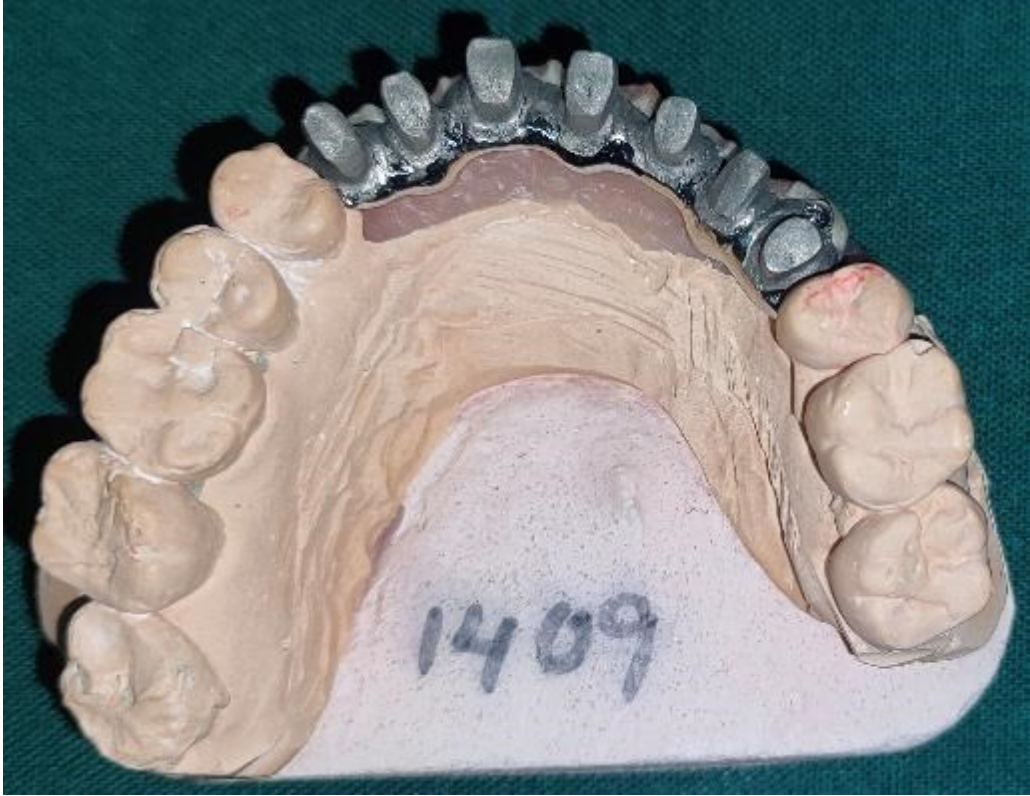METAL FRAME WORK TRIAL



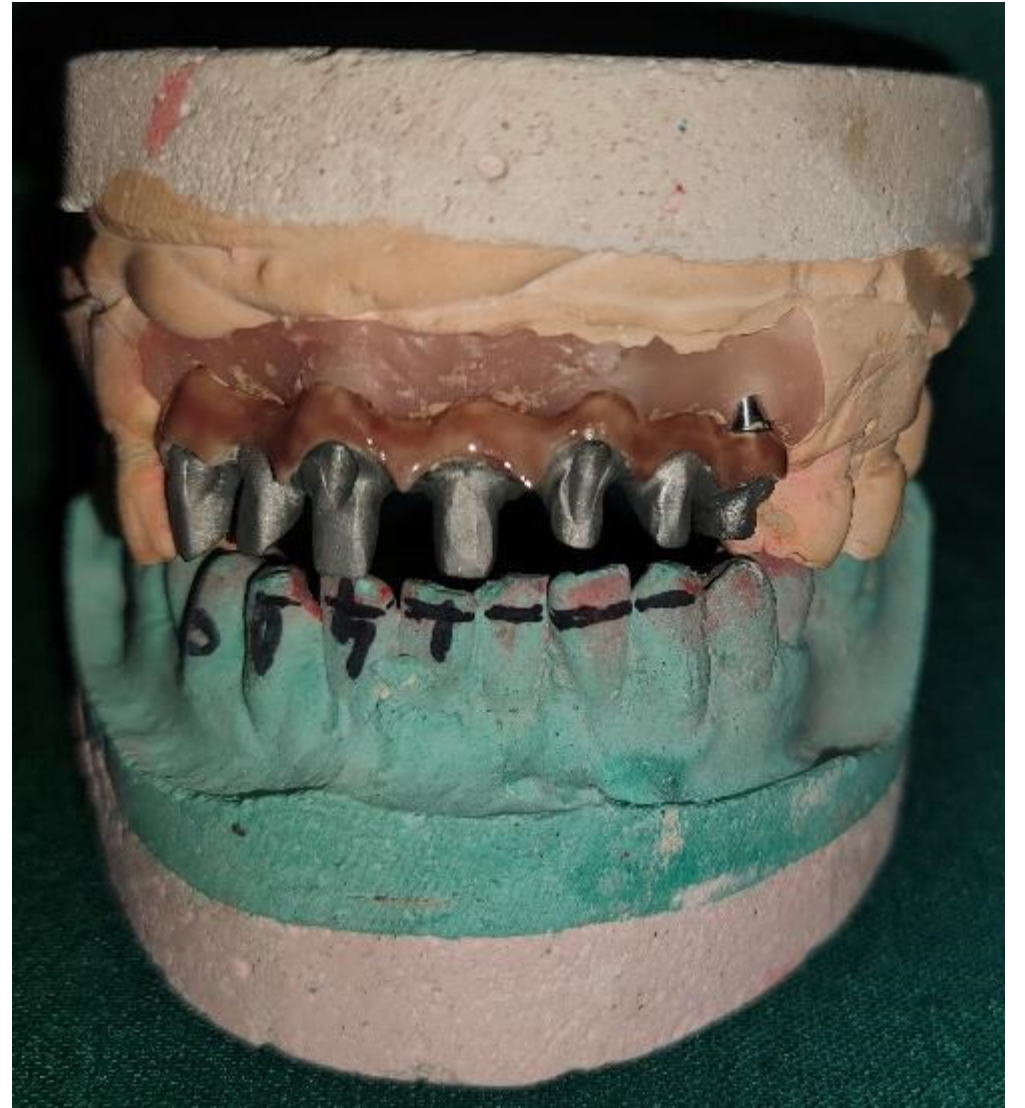PREGLAZE TRIAL



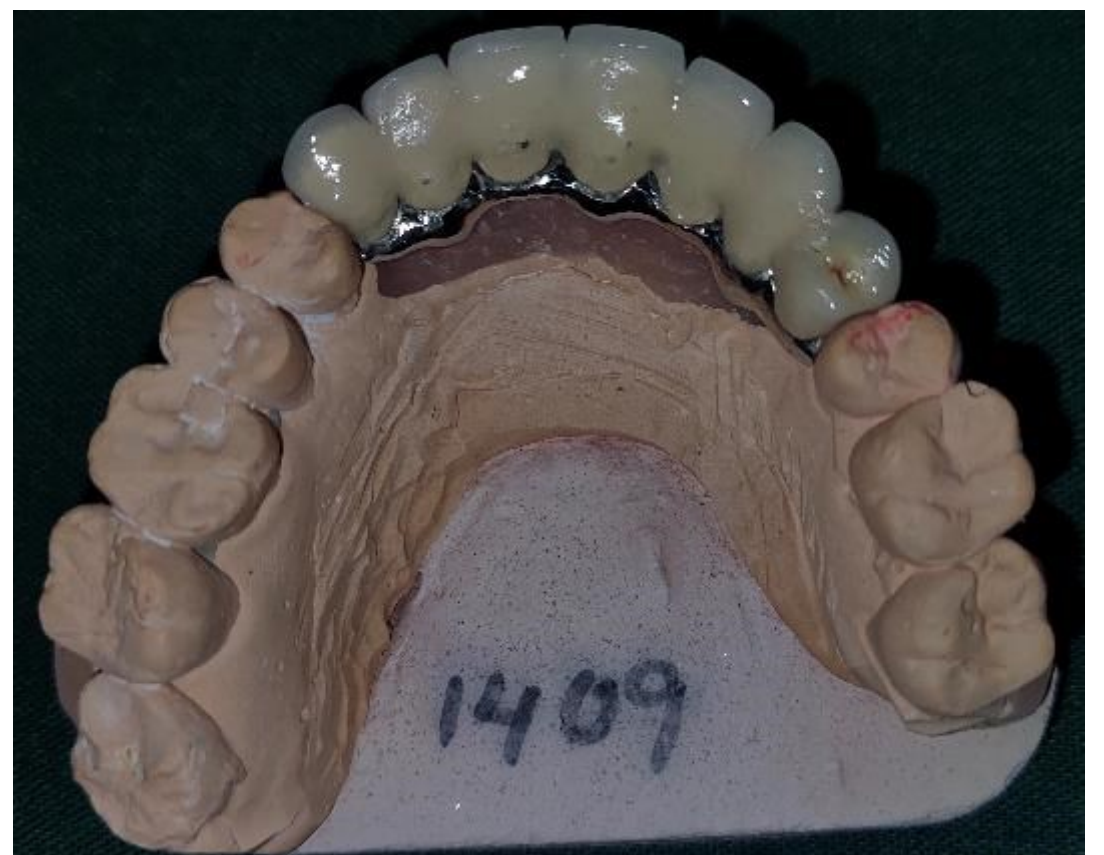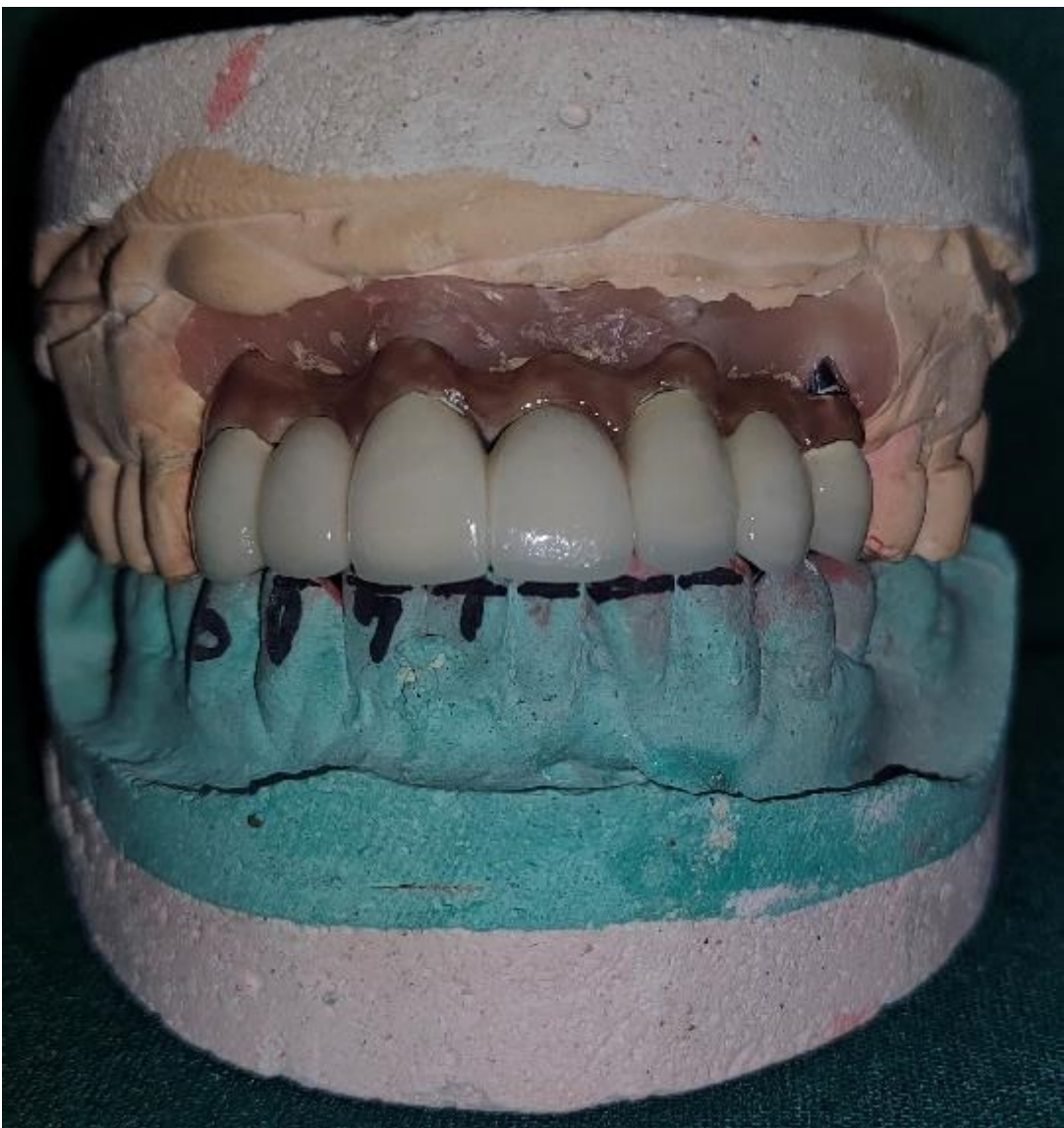GLAZING AND FINISHING



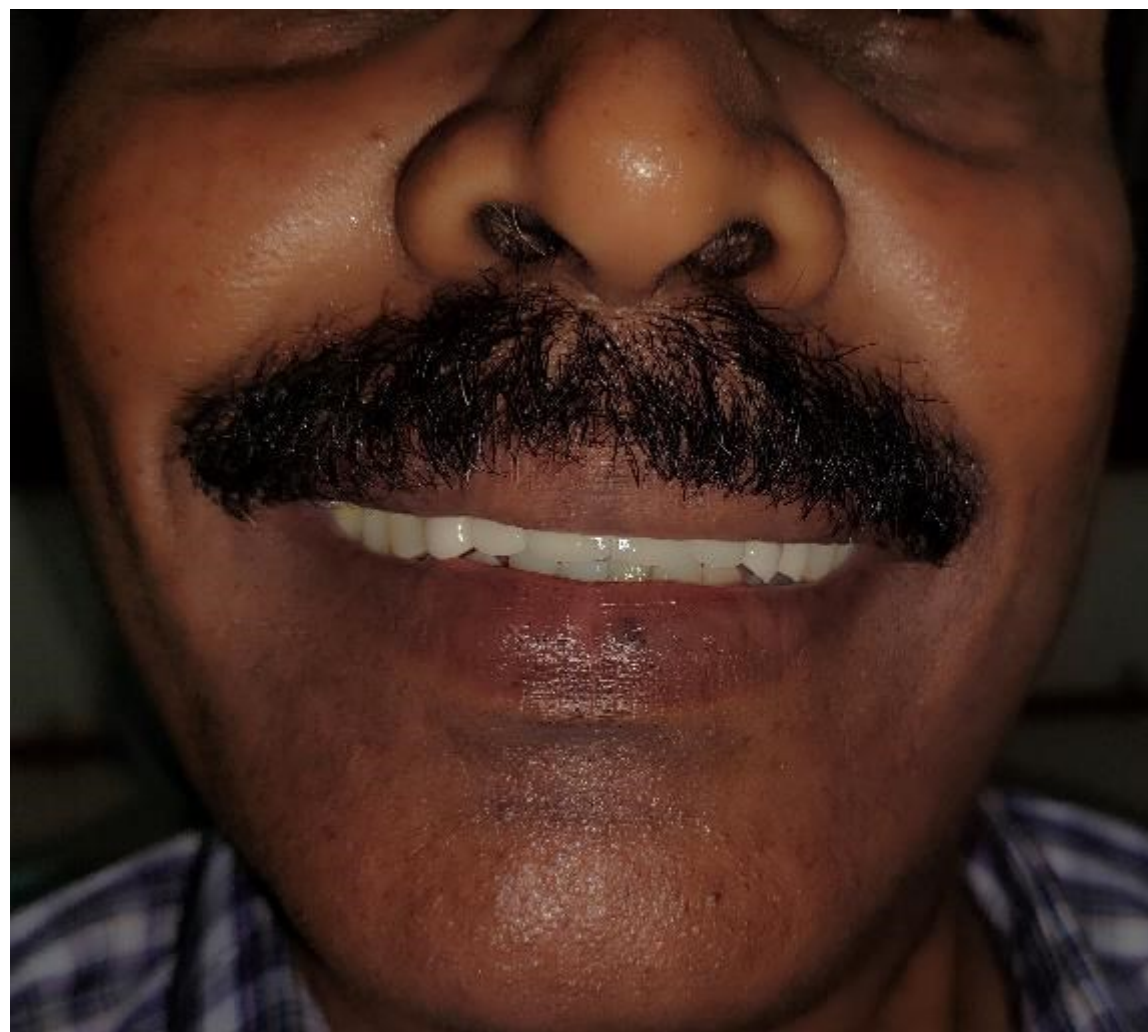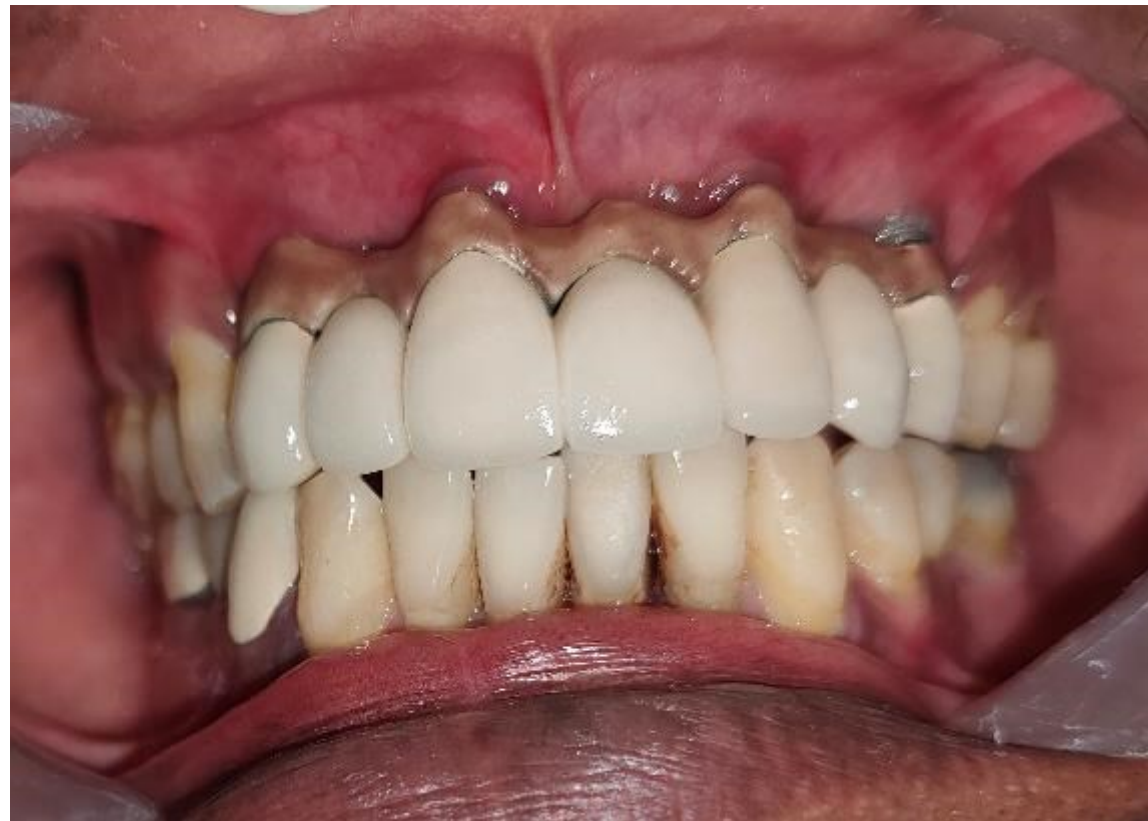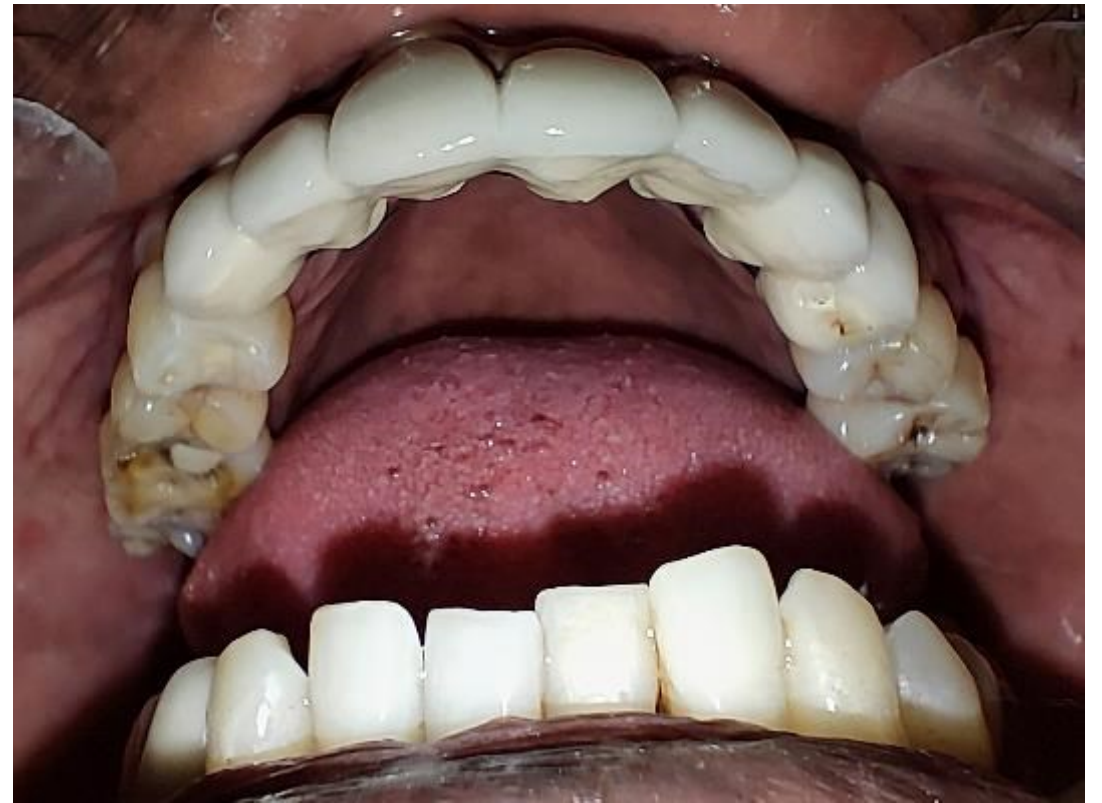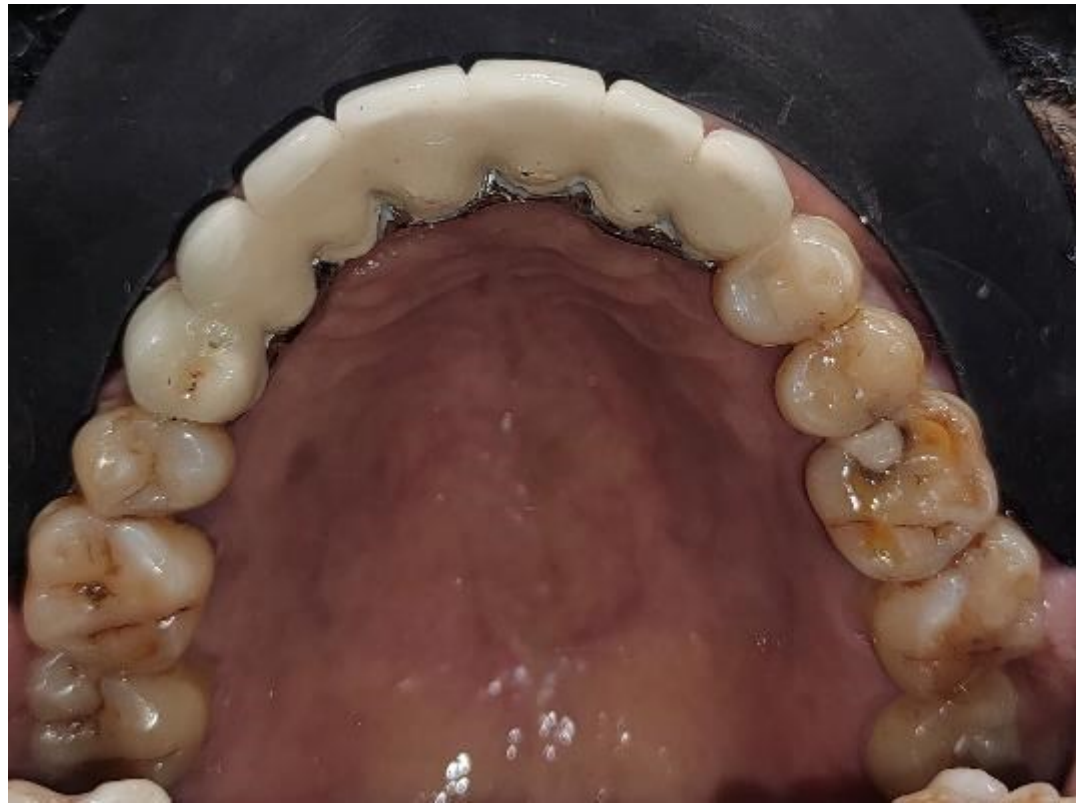SAND BLATED METAL
FRAME WORK



GINGIVAL CONTOURING USING
GINGIVAL COMPOSITE



CEMENTATION

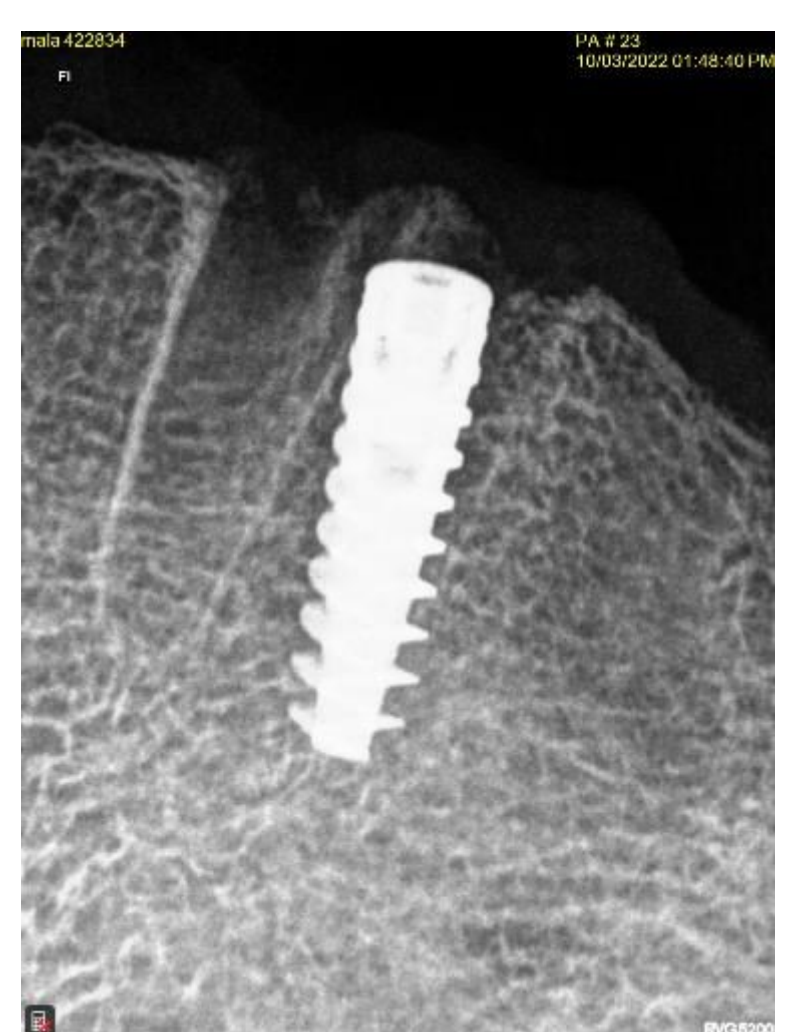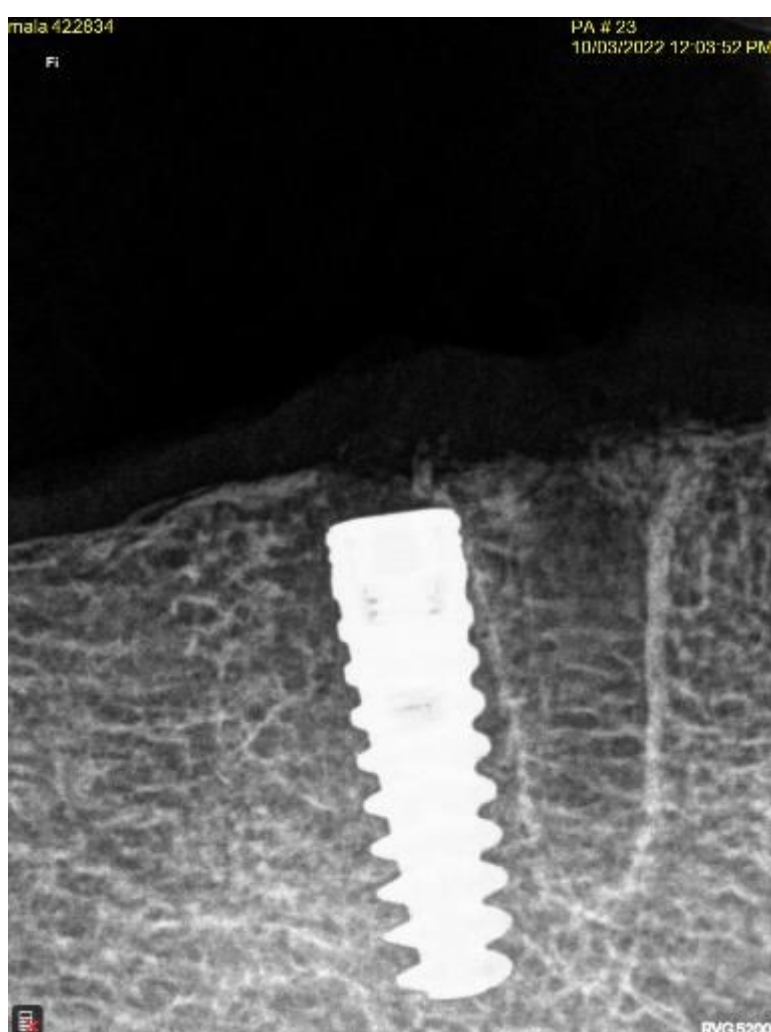
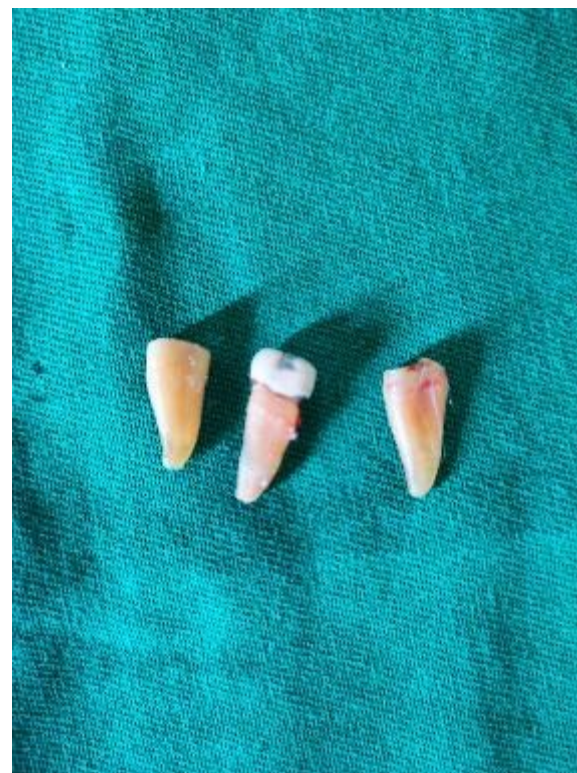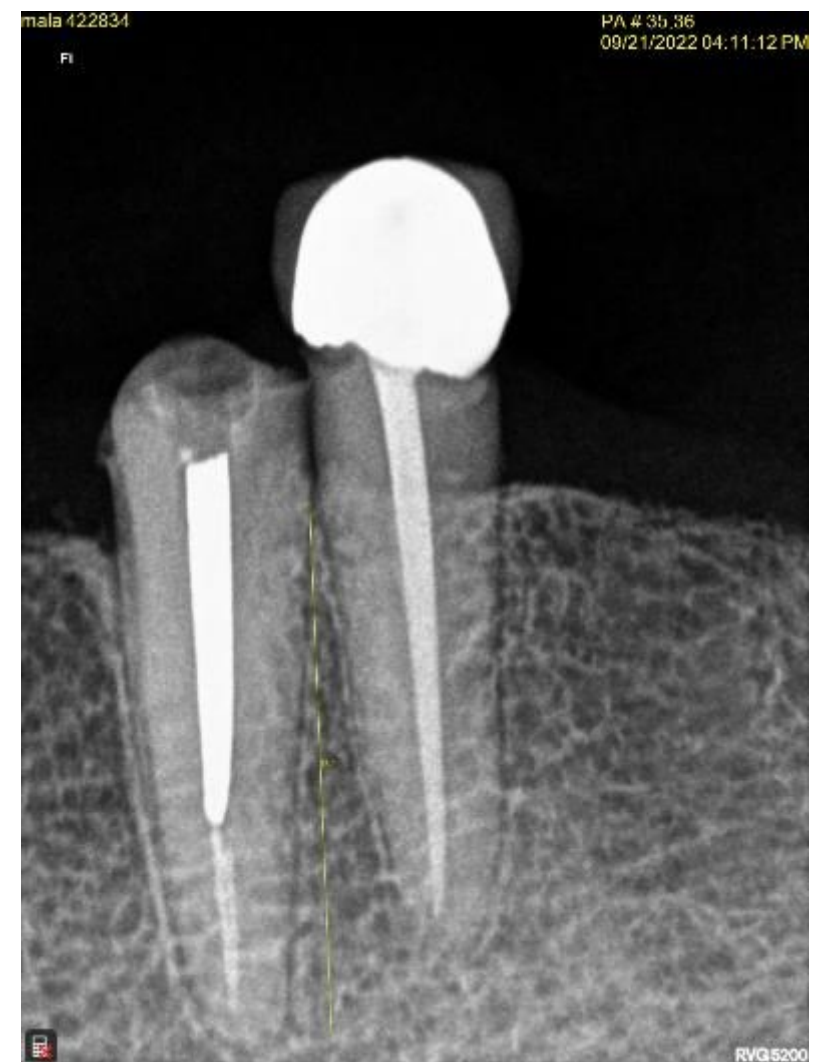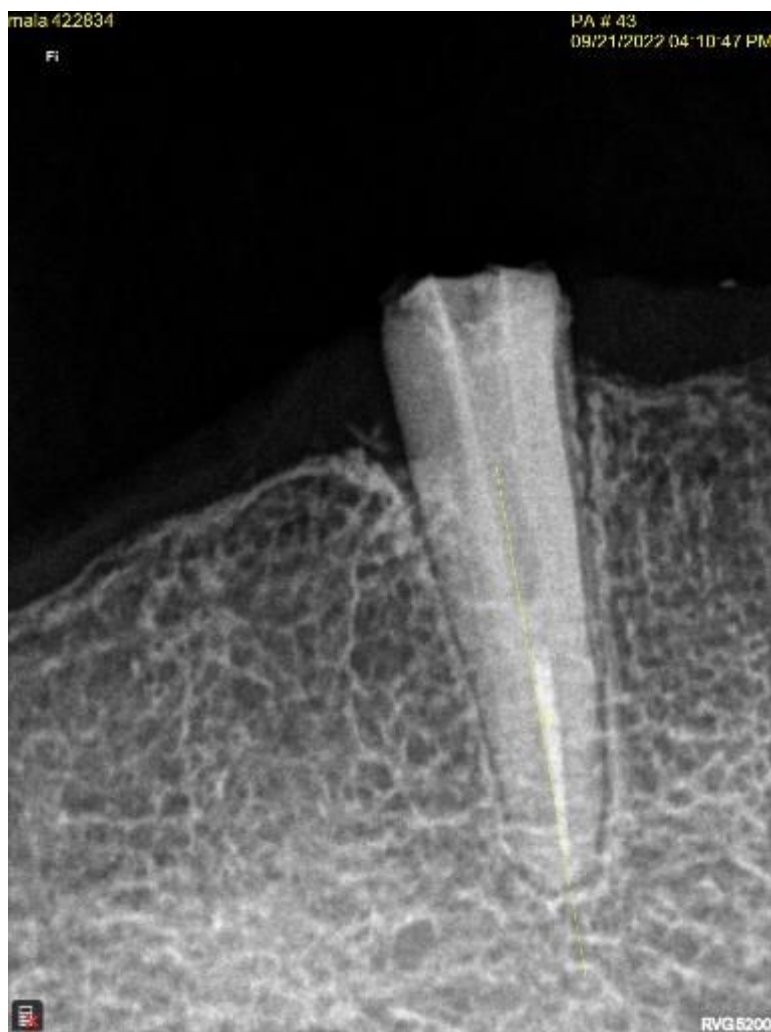


IMPLANT SUPPORTED OVERDENTURE

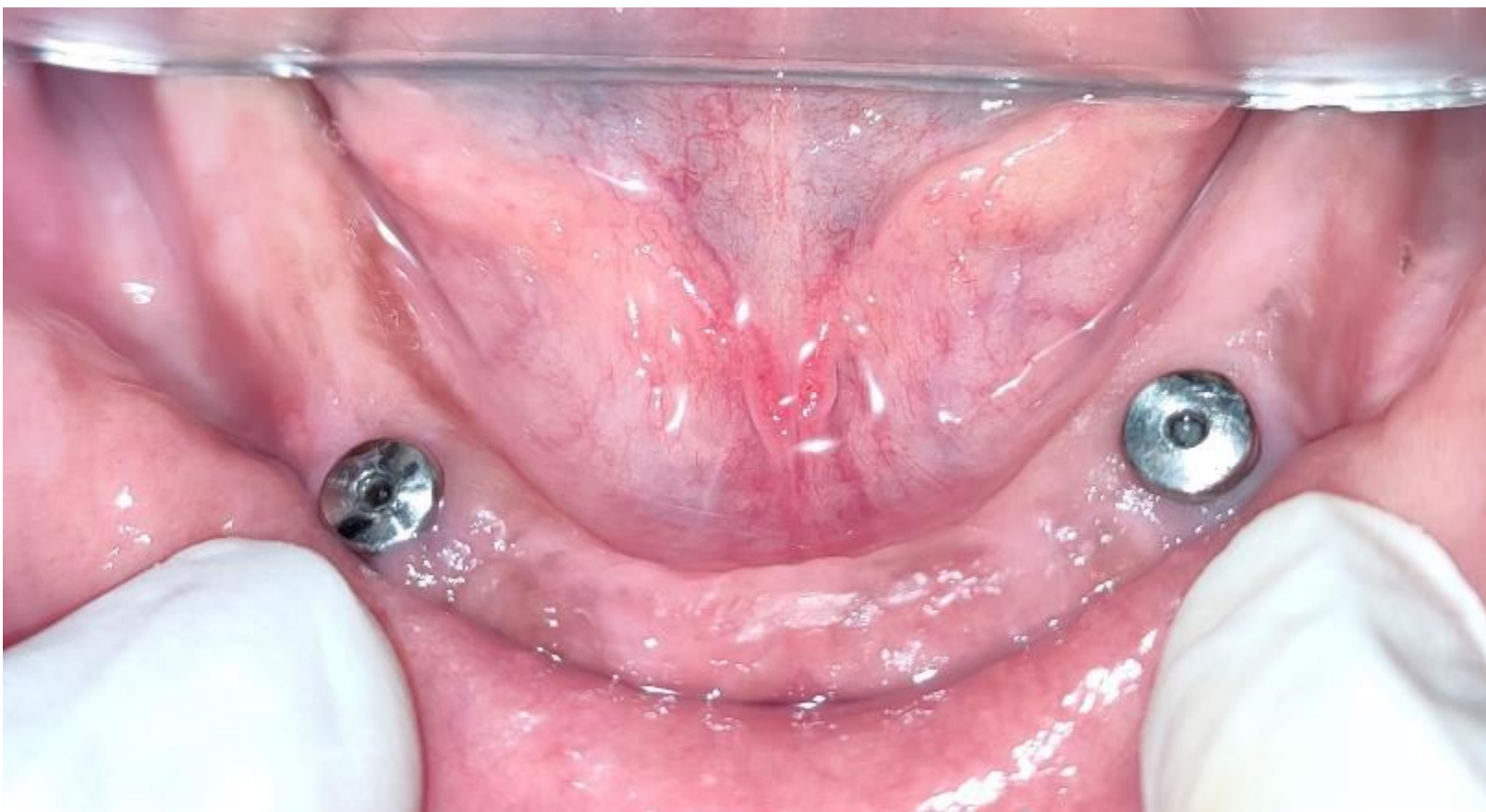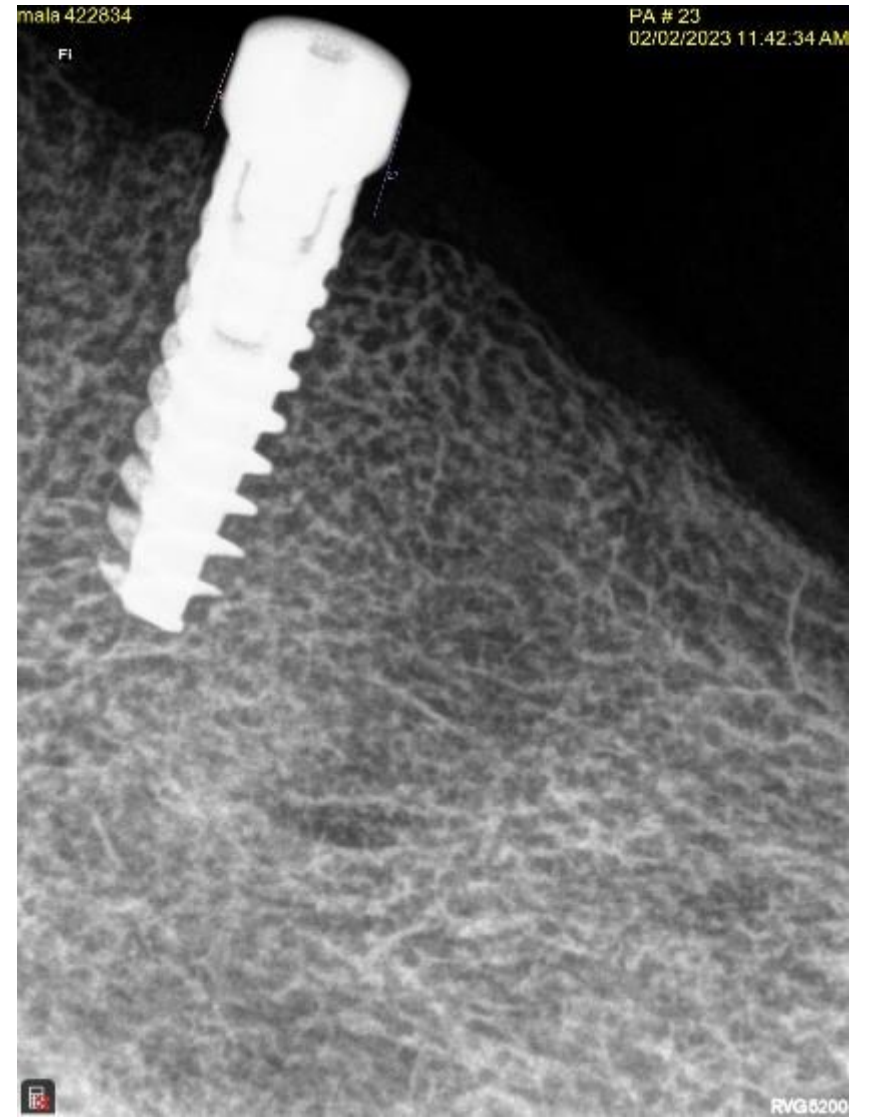
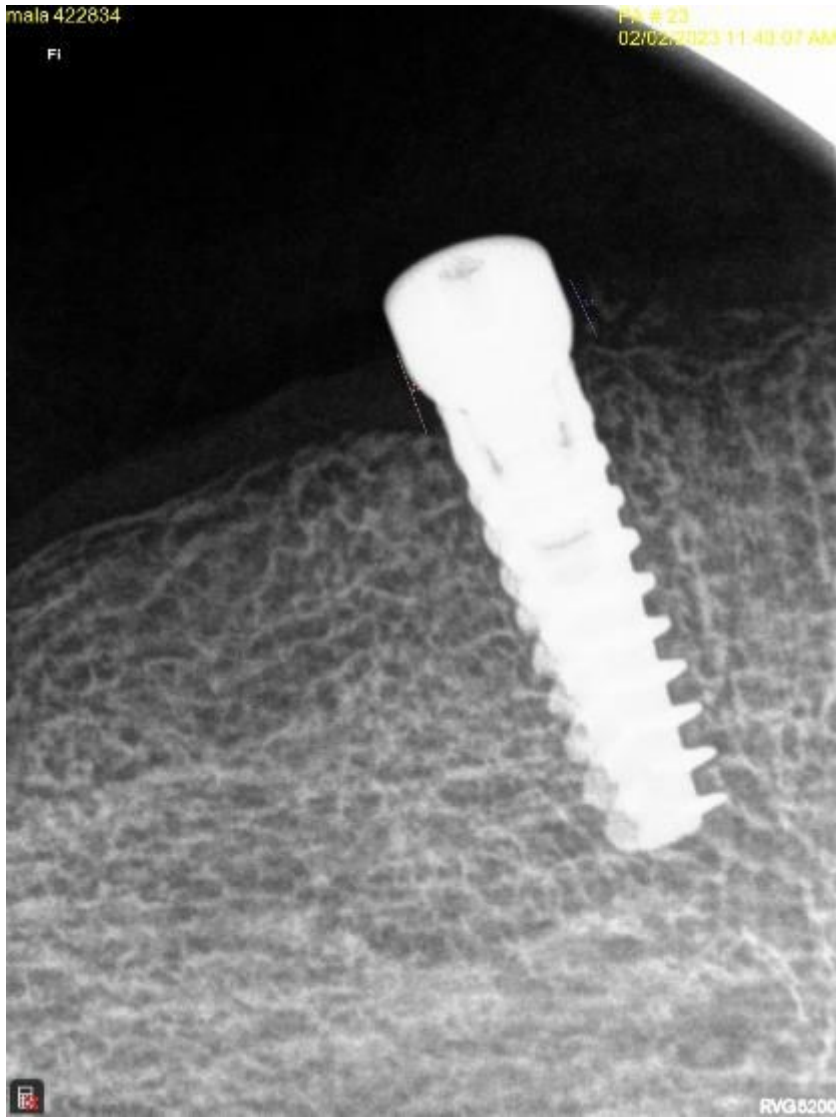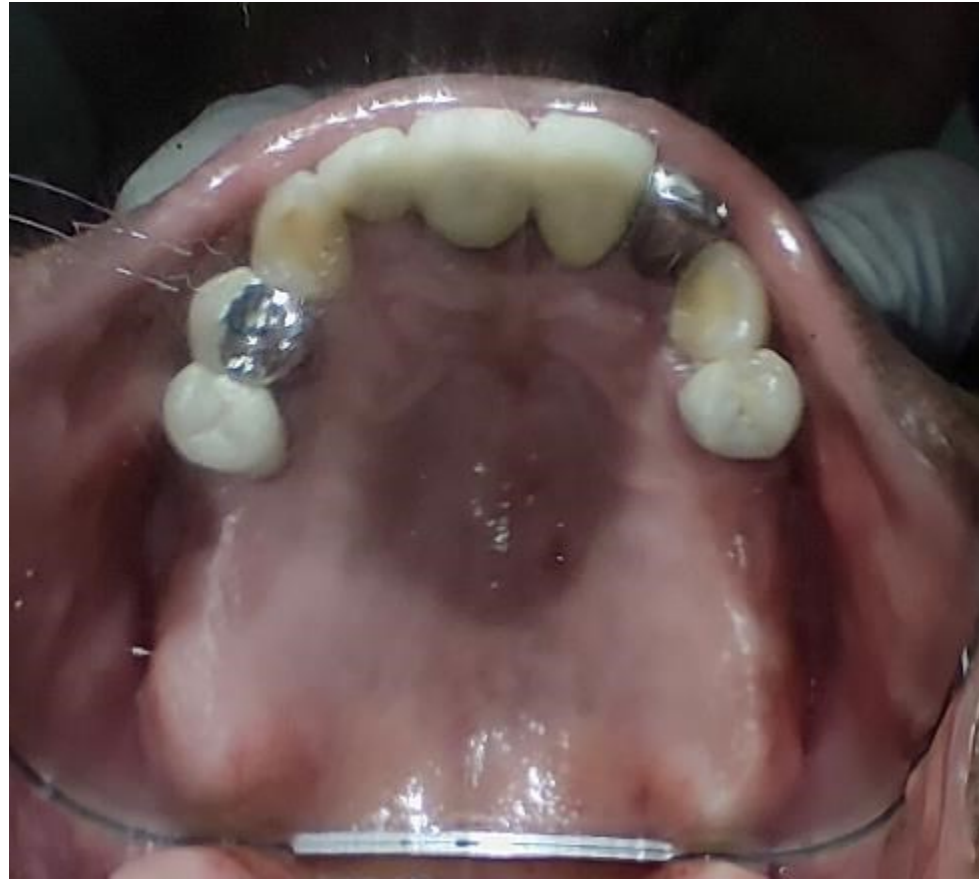PATIENT NAME: Mrs. MALA

RMCT: 422834

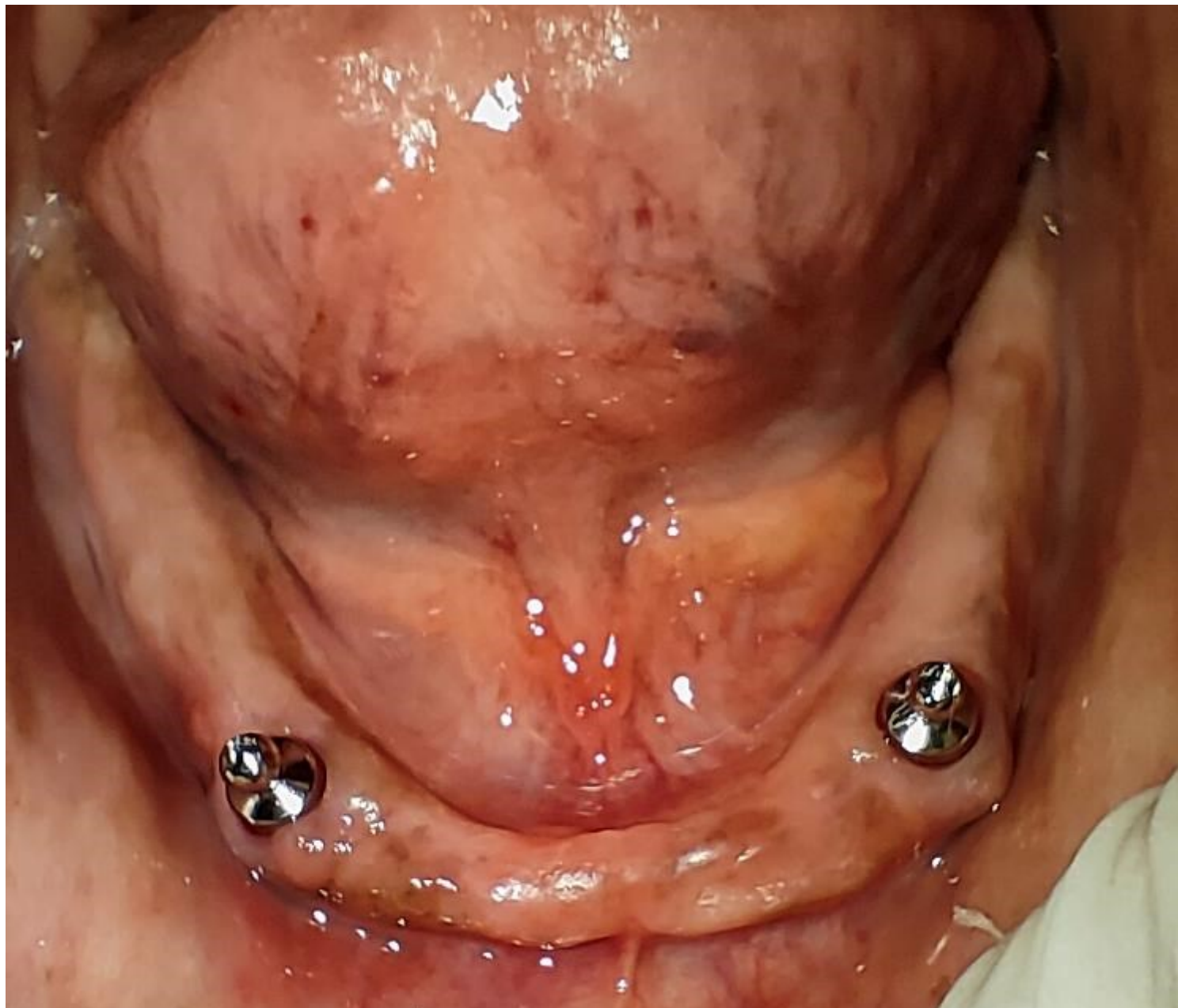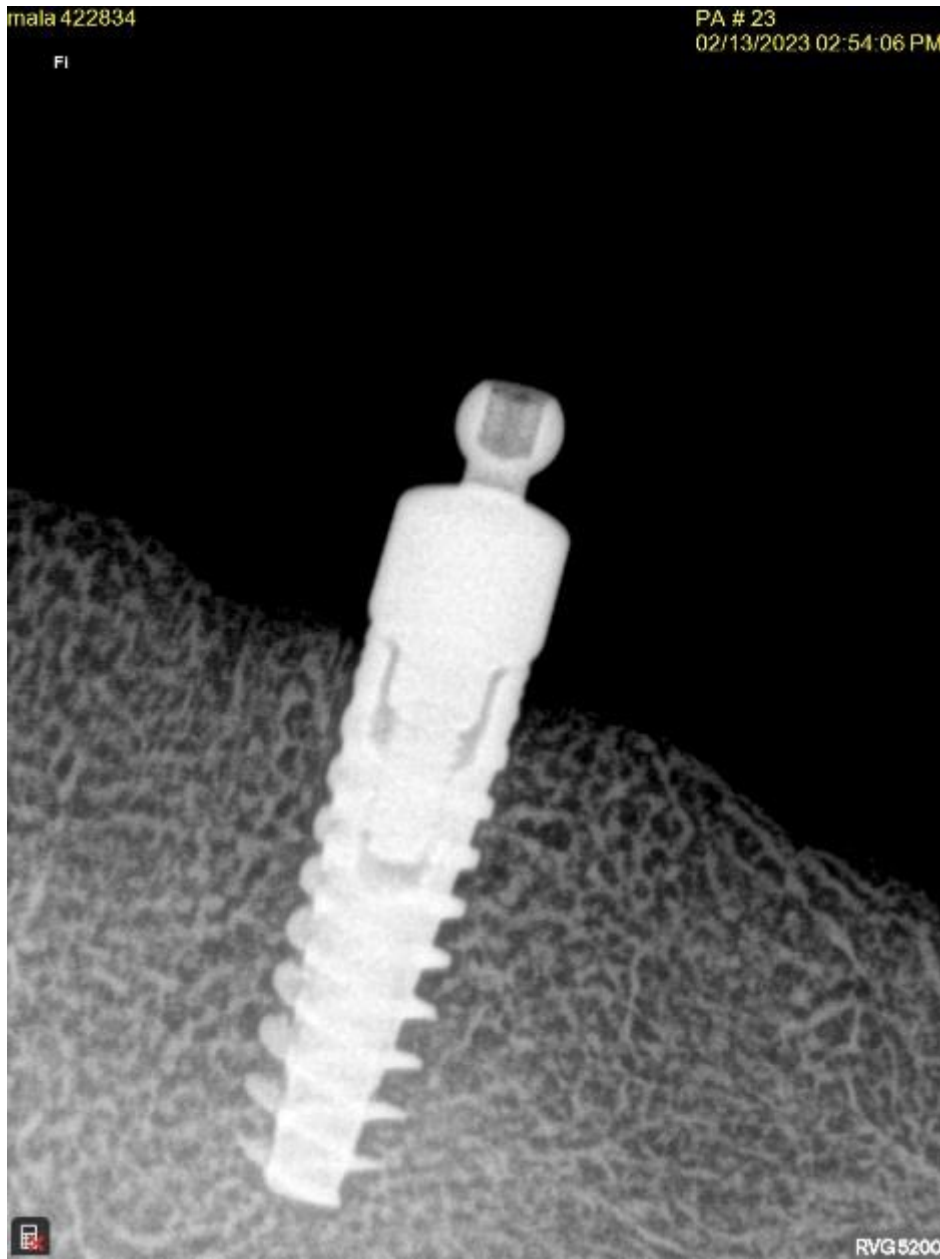
EXTRACTION AND IMMEDIATE IMPLANT



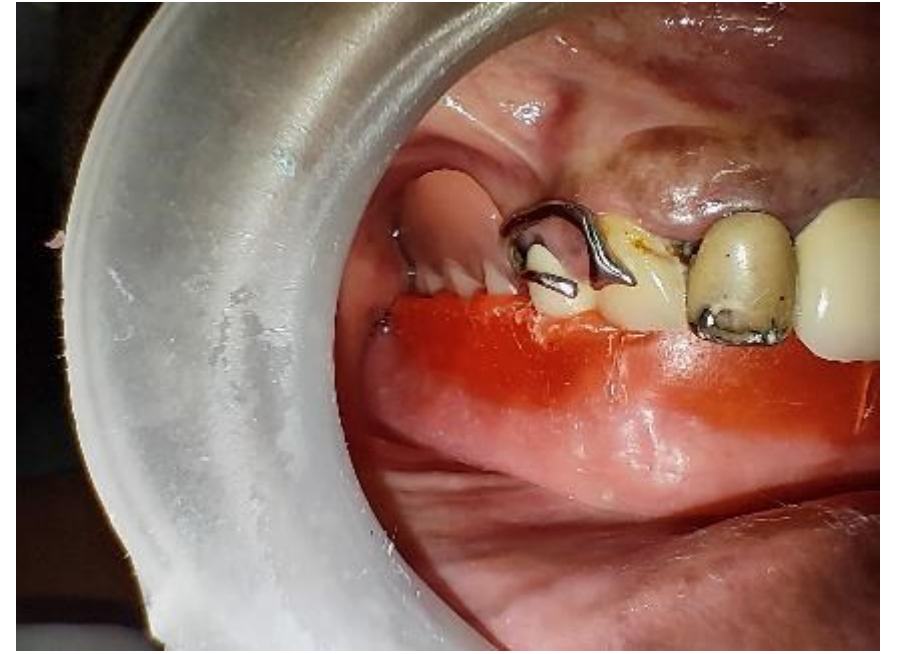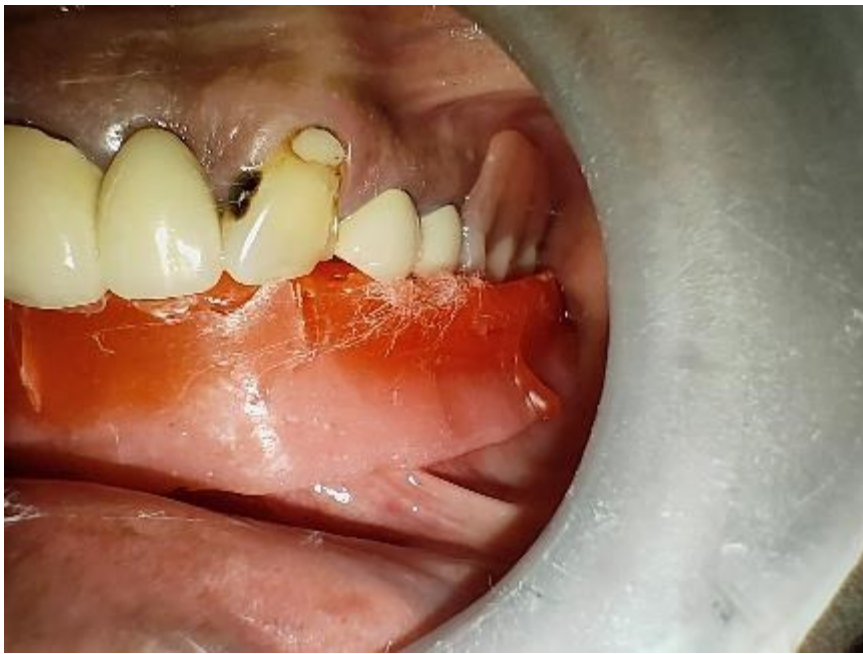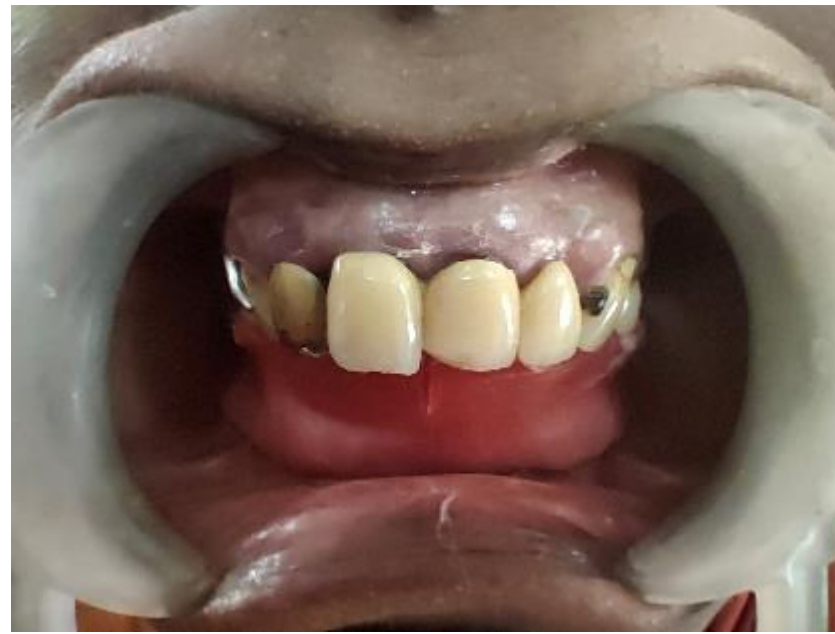SECOND STAGE SURGERY



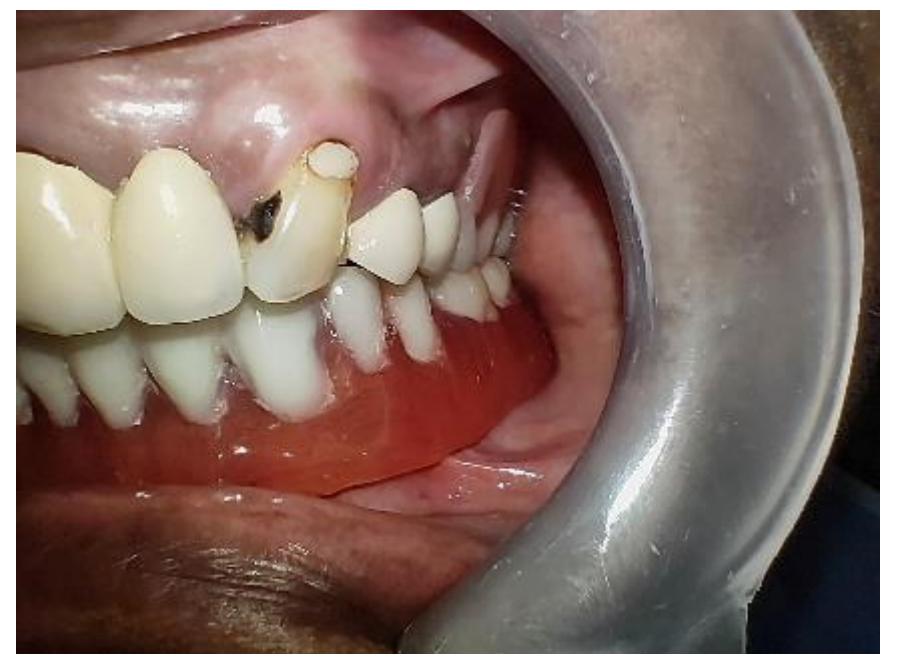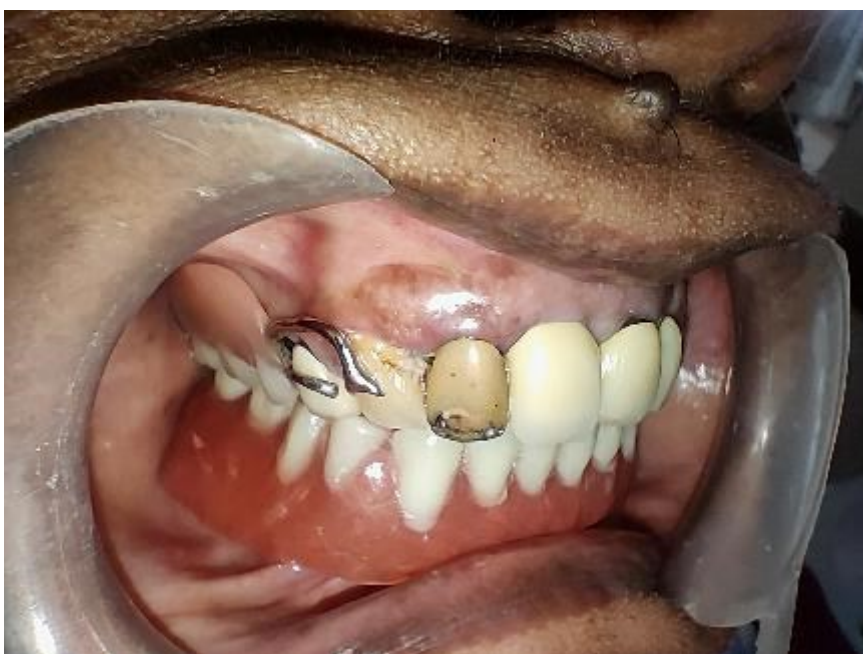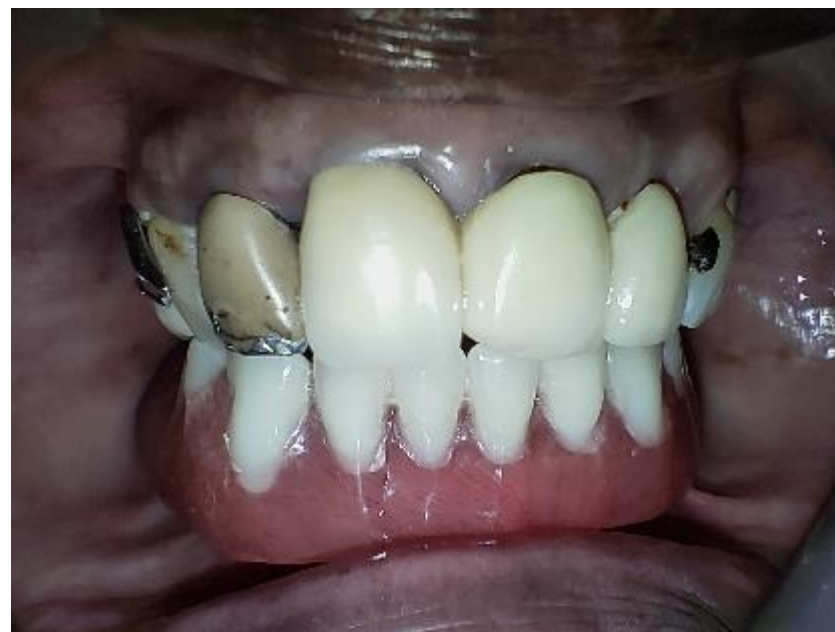BALL ATTACHMENT OVER IMPLANTS



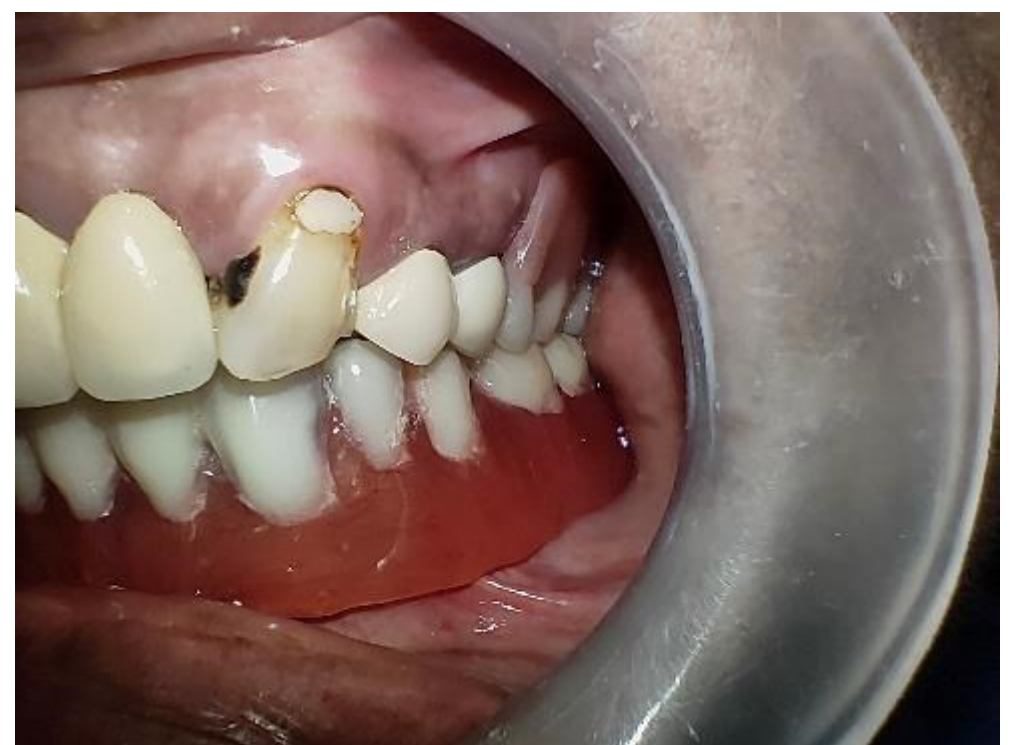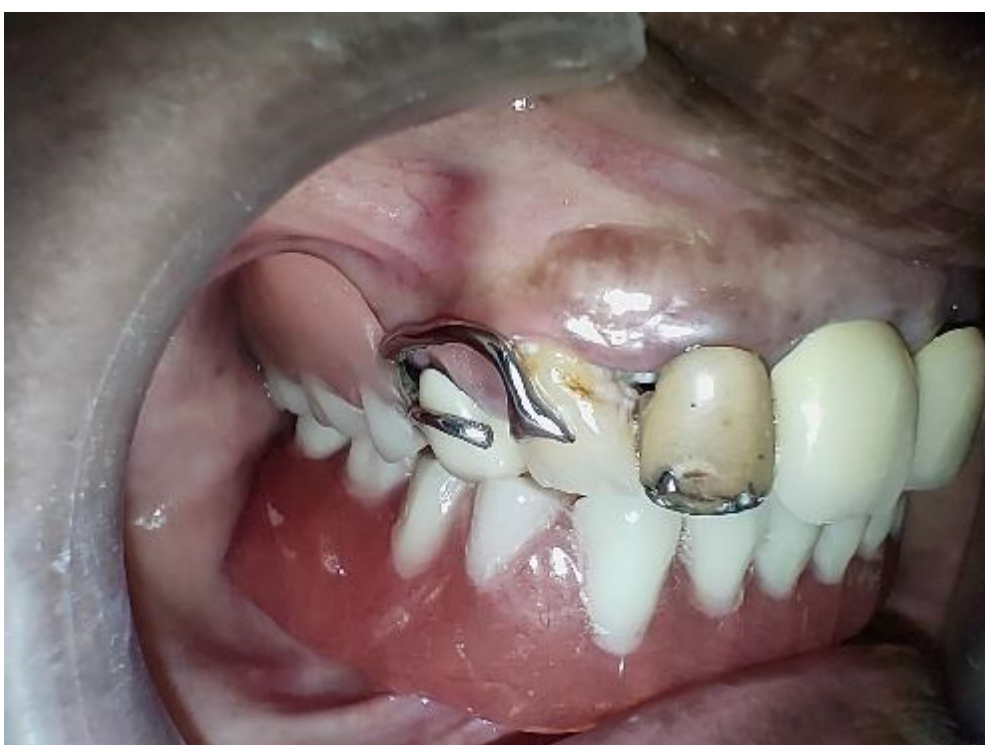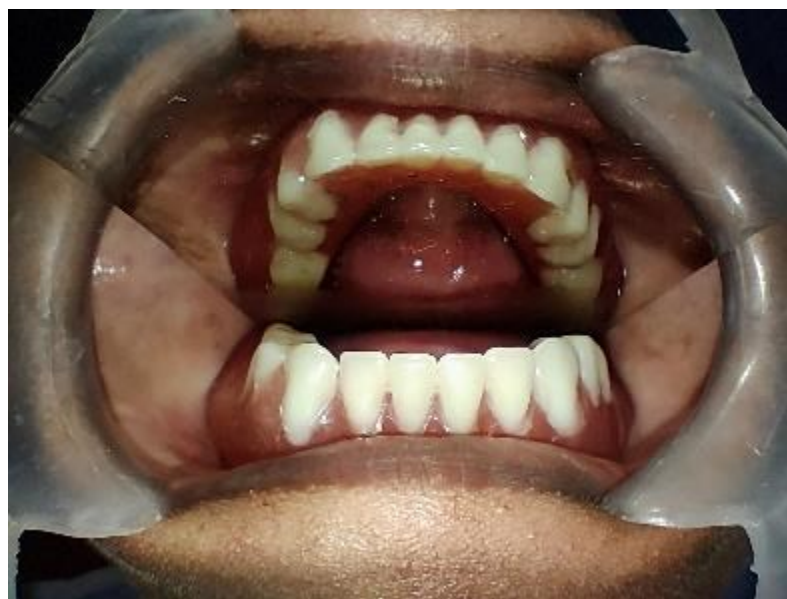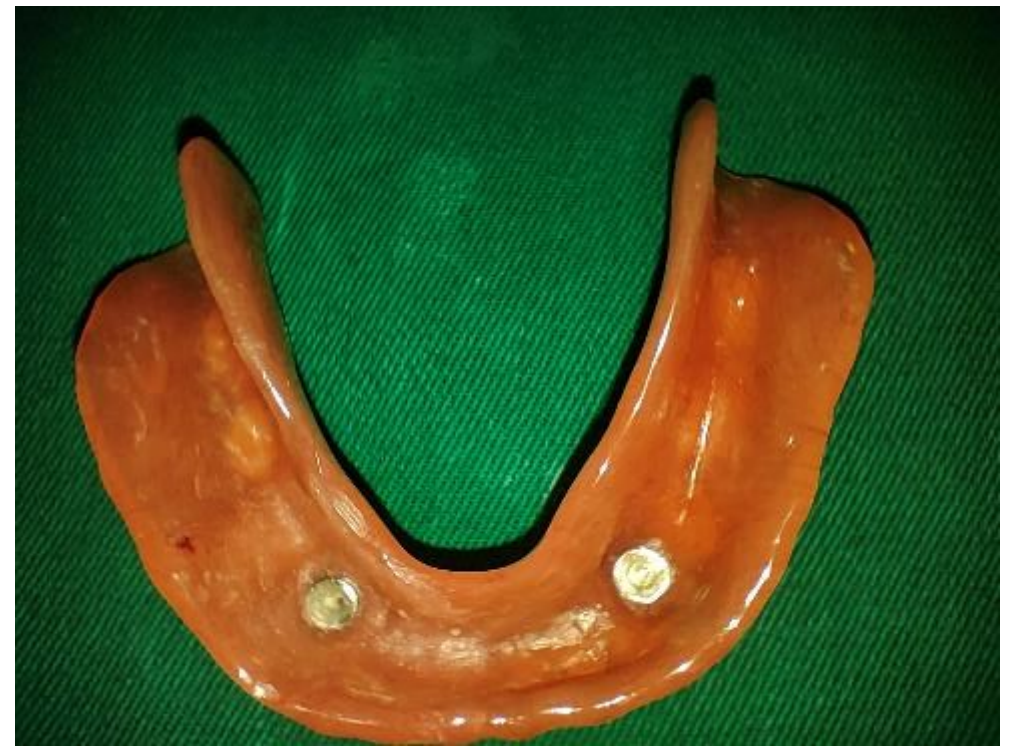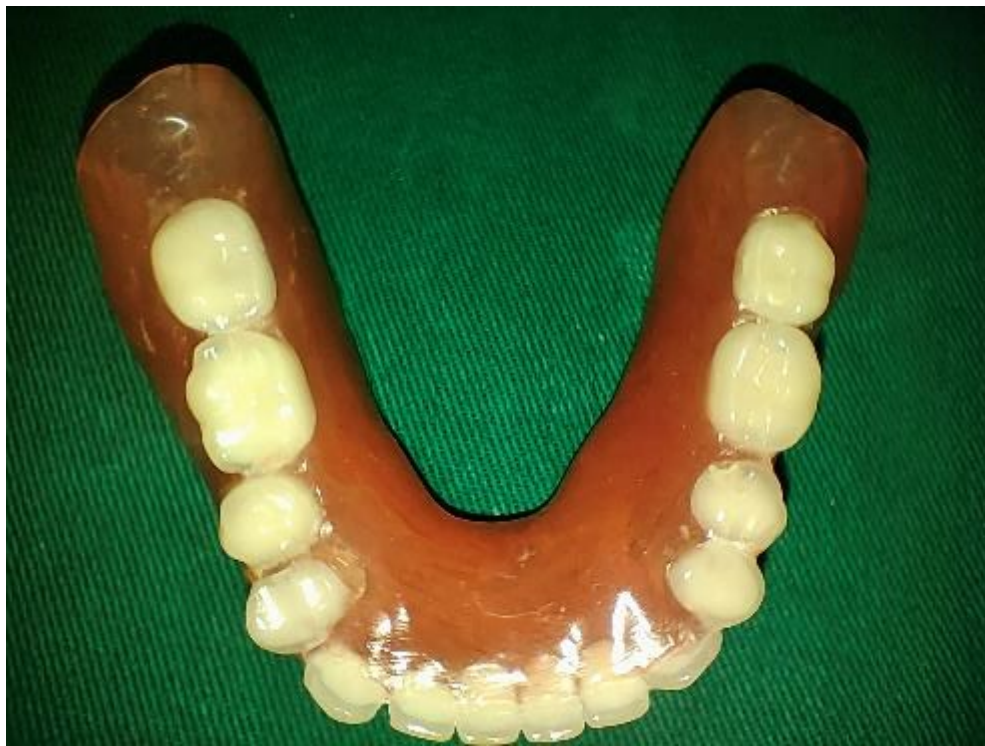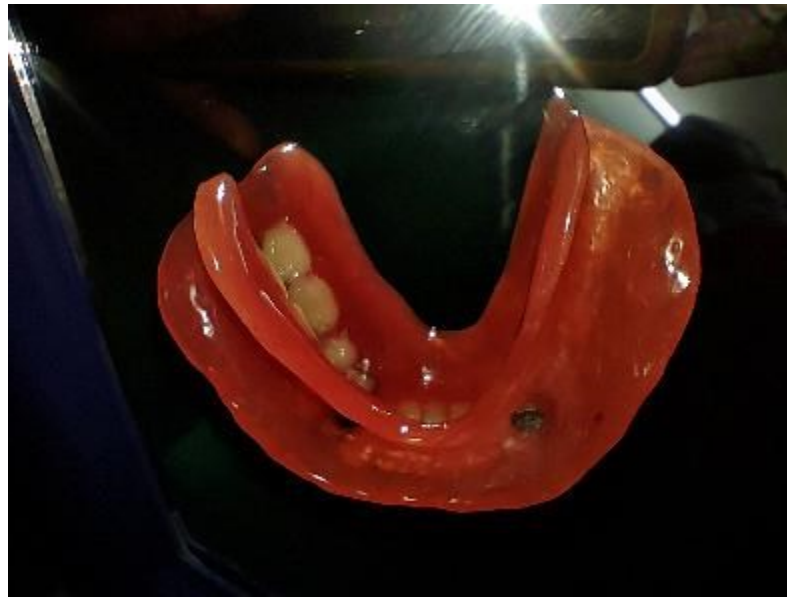BITE REGISTRATION



WAX TRIAL



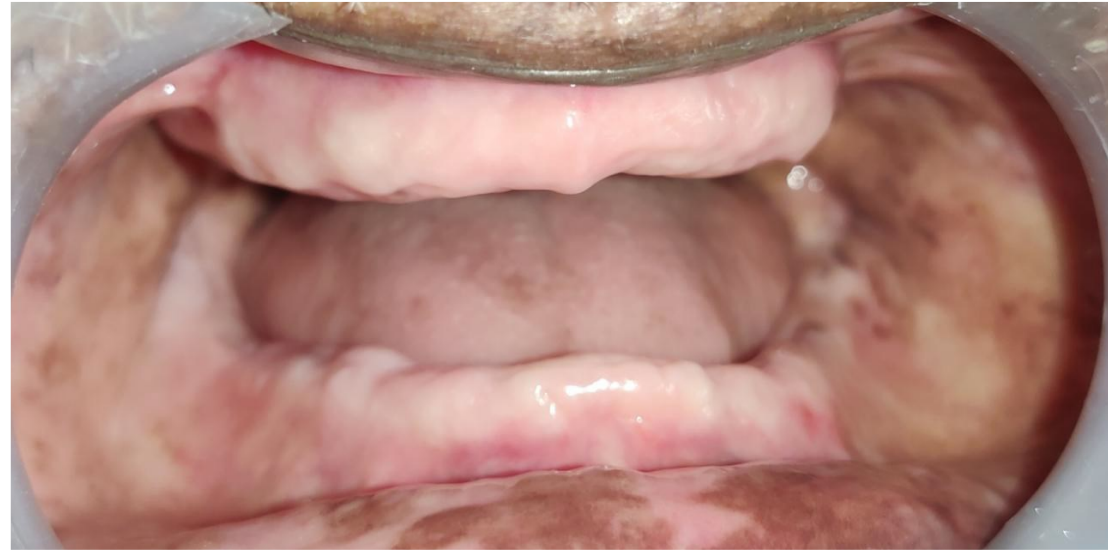OVER DENTURE INSERTION



BIOFUNCTIONAL PROSTHETIC SYSTEM

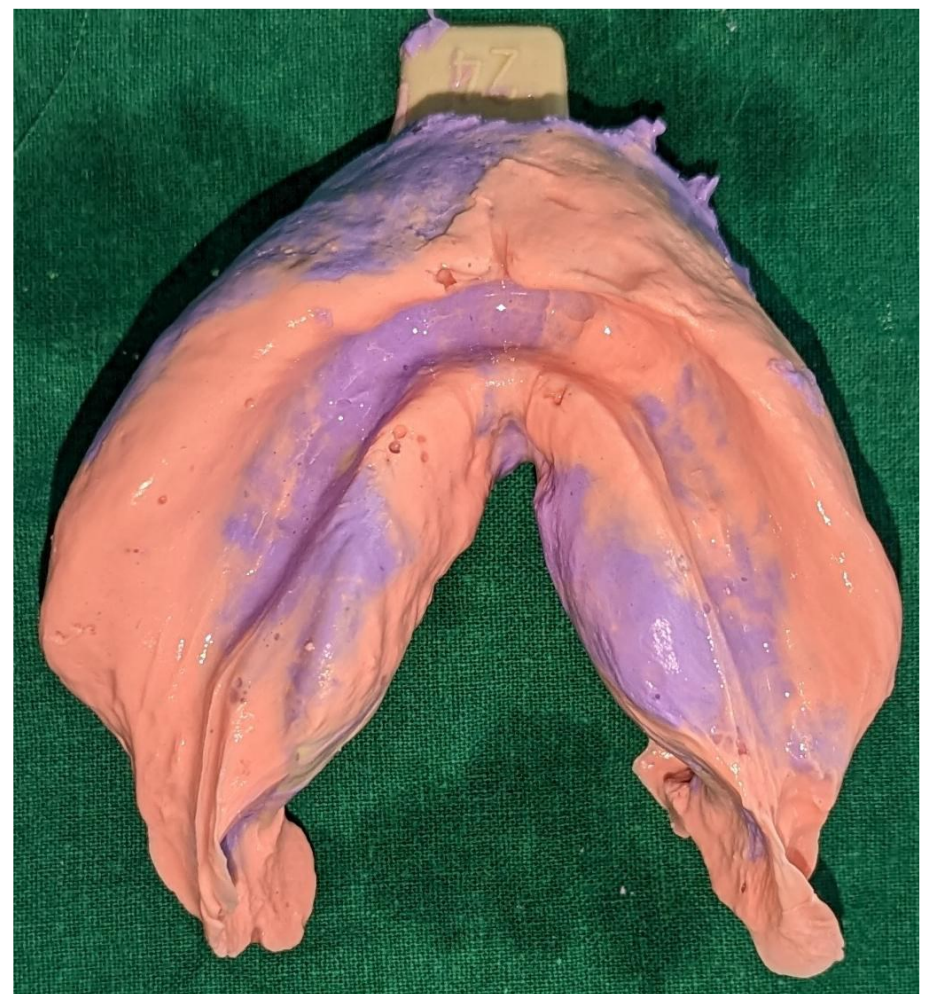
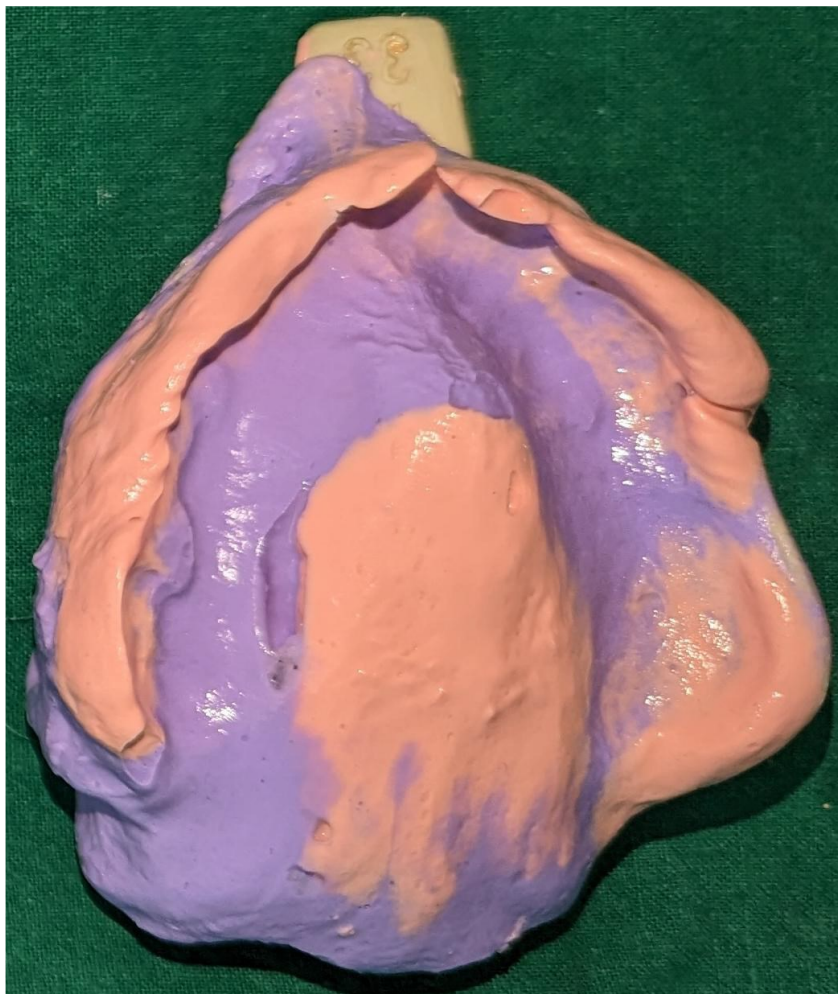
PATIENT NAME: Mr. MUTHUKADAIKAPPAN
RMCT: 398574

PRE - OP

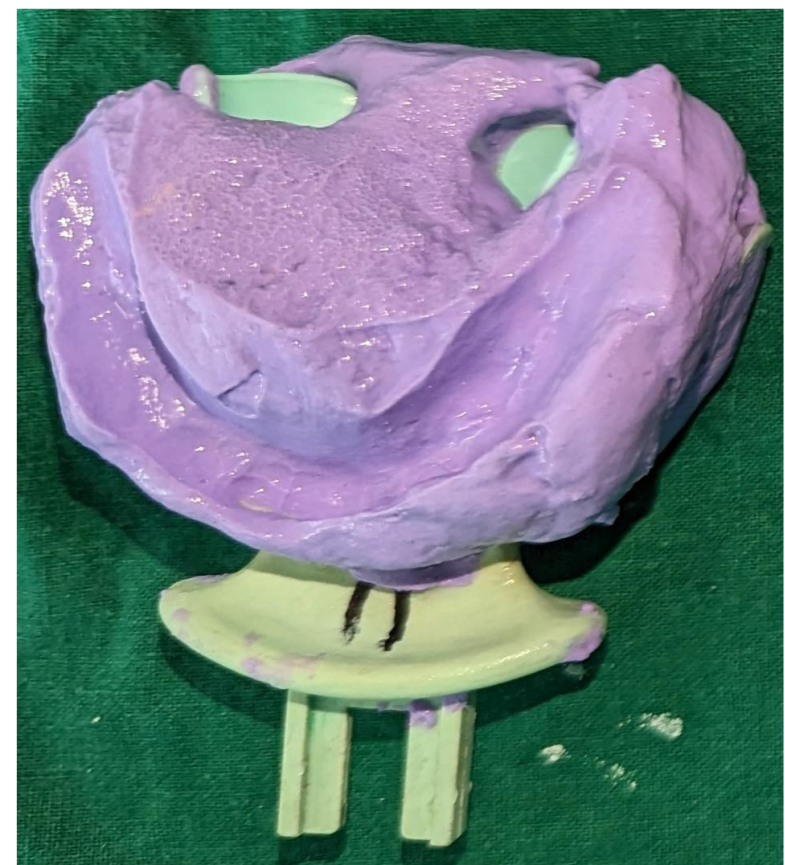
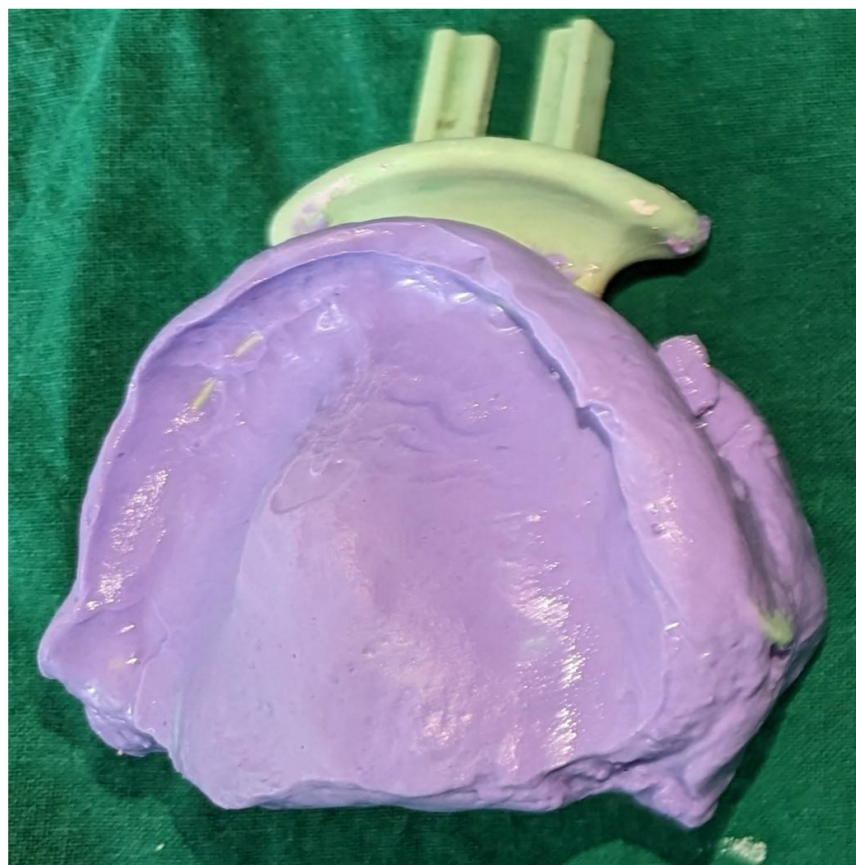
1ST APPOINTMENT

PRIMARY IMPRESSION

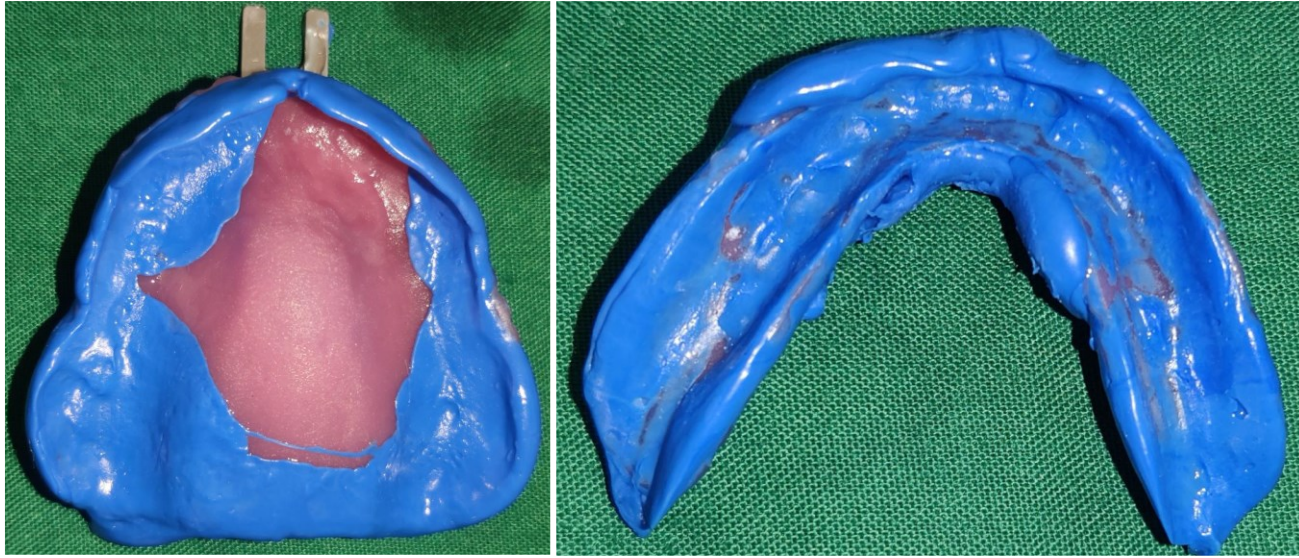


PRILIMINARY JAW RELATION USING
CENTRIC TRAY

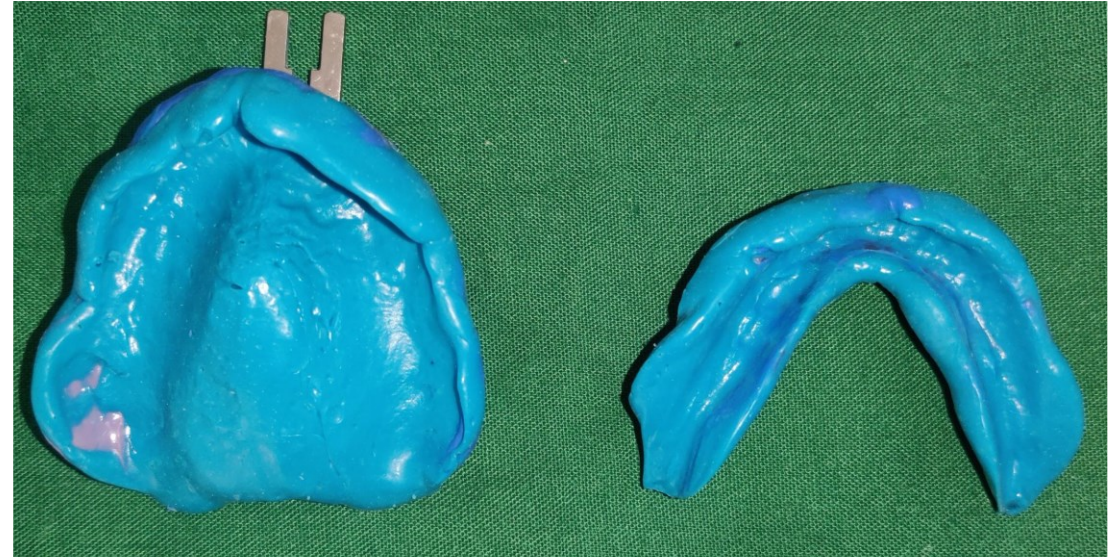


2ND APPOINTMENT

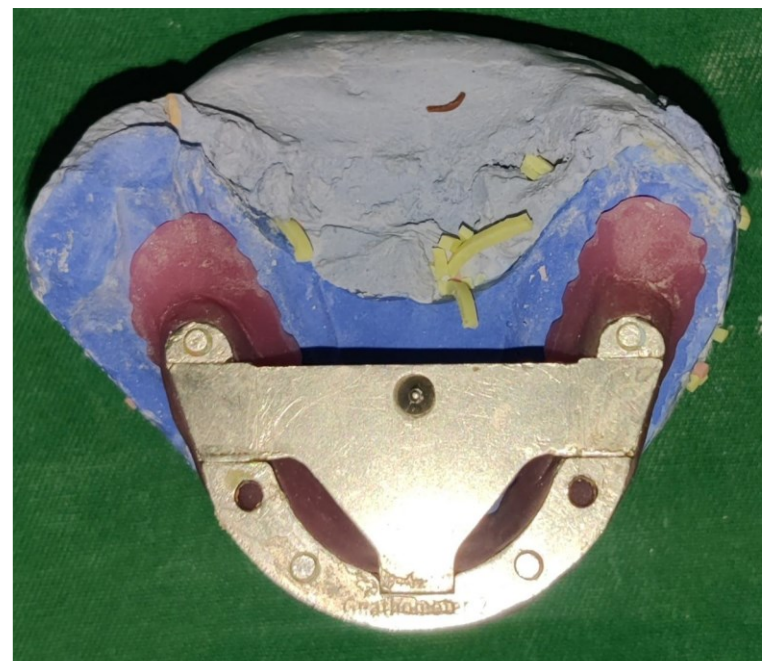

BORDER MOULDING



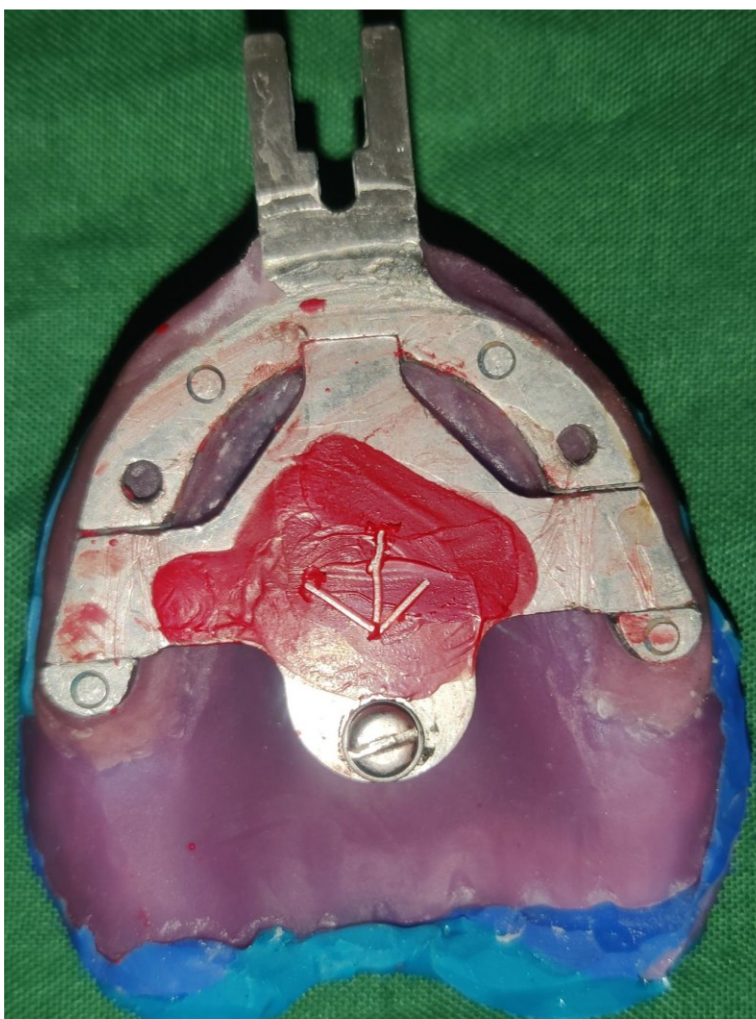
SECONDARY IMPRESSION



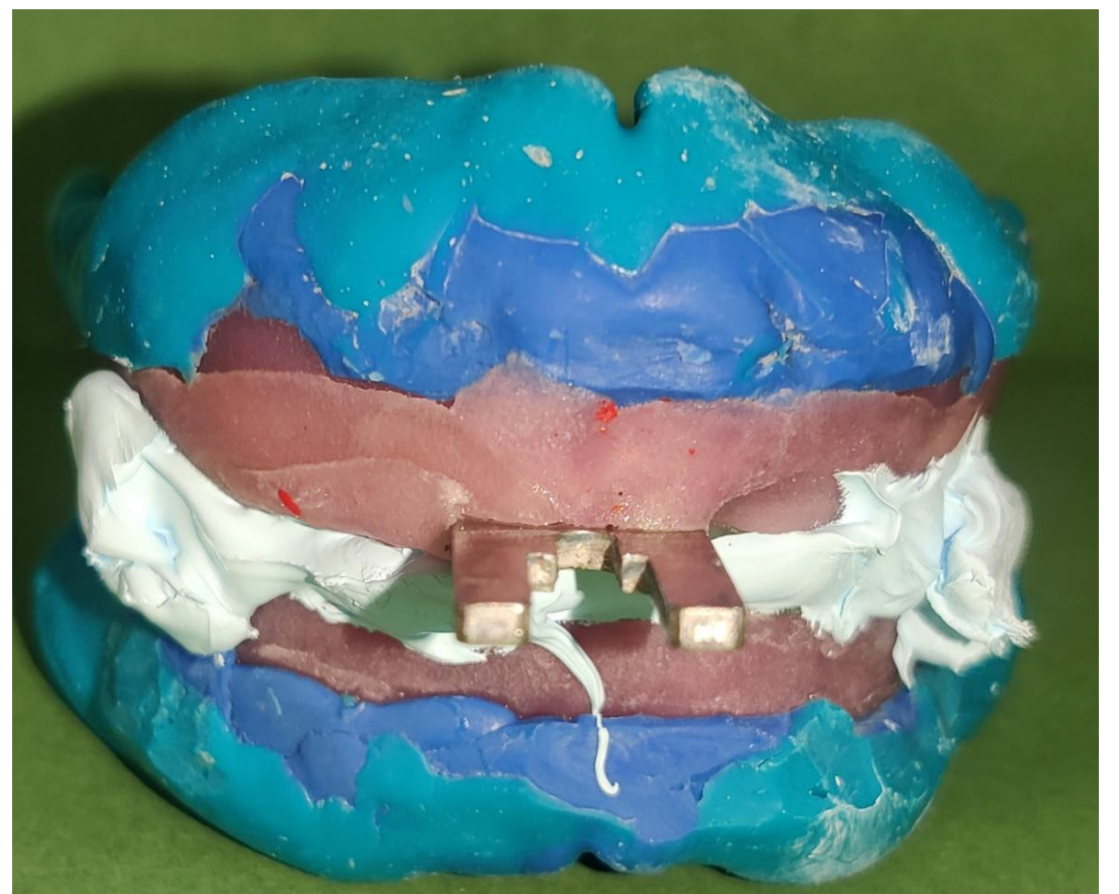
GNATHOMETER ATTACHED WITH OCCLUSAL RIMS



INTRA ORAL TRACING

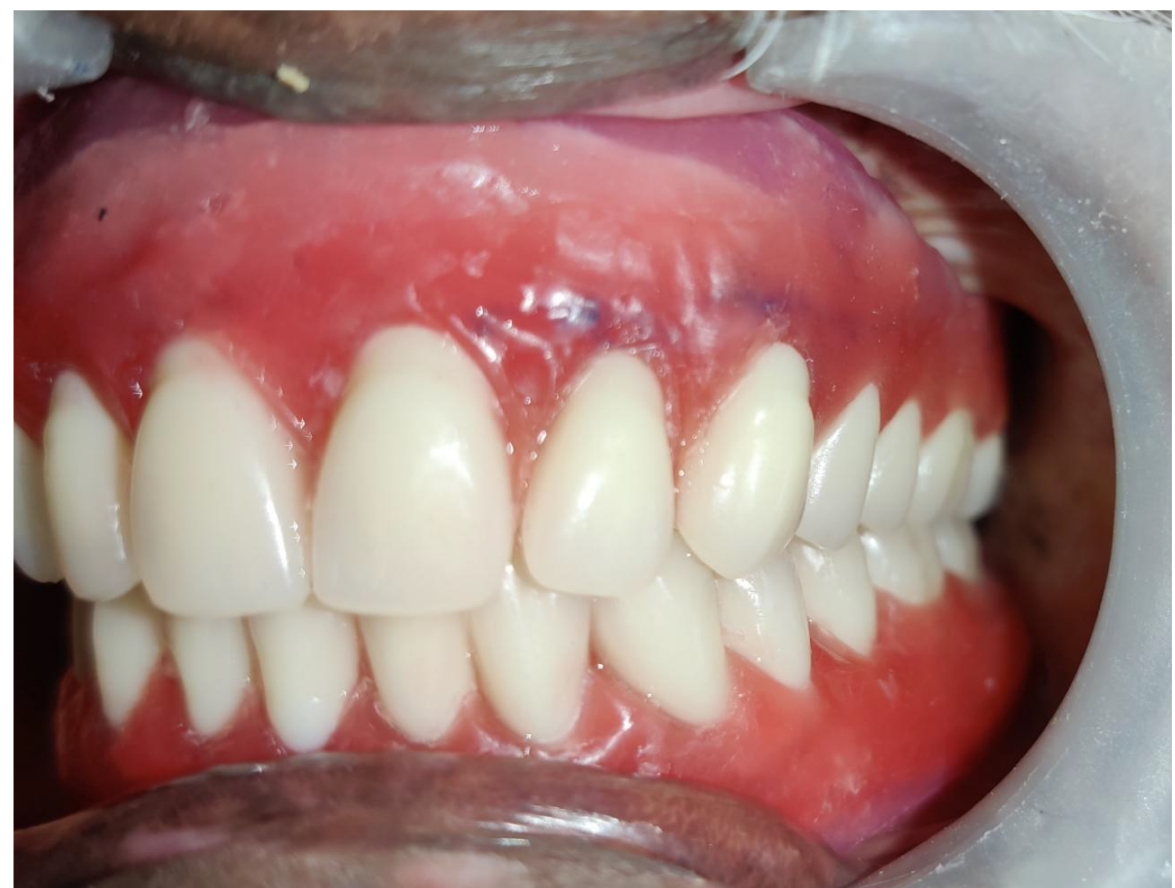
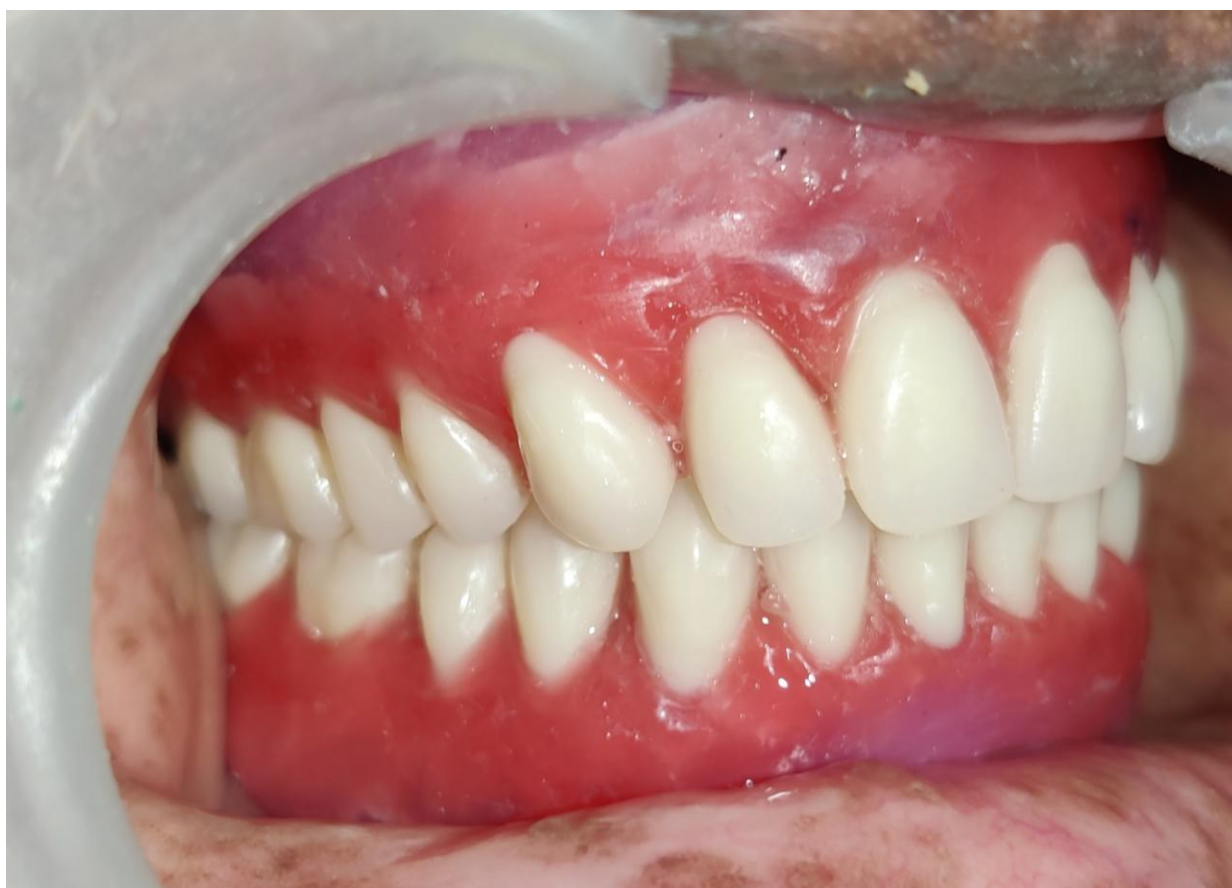
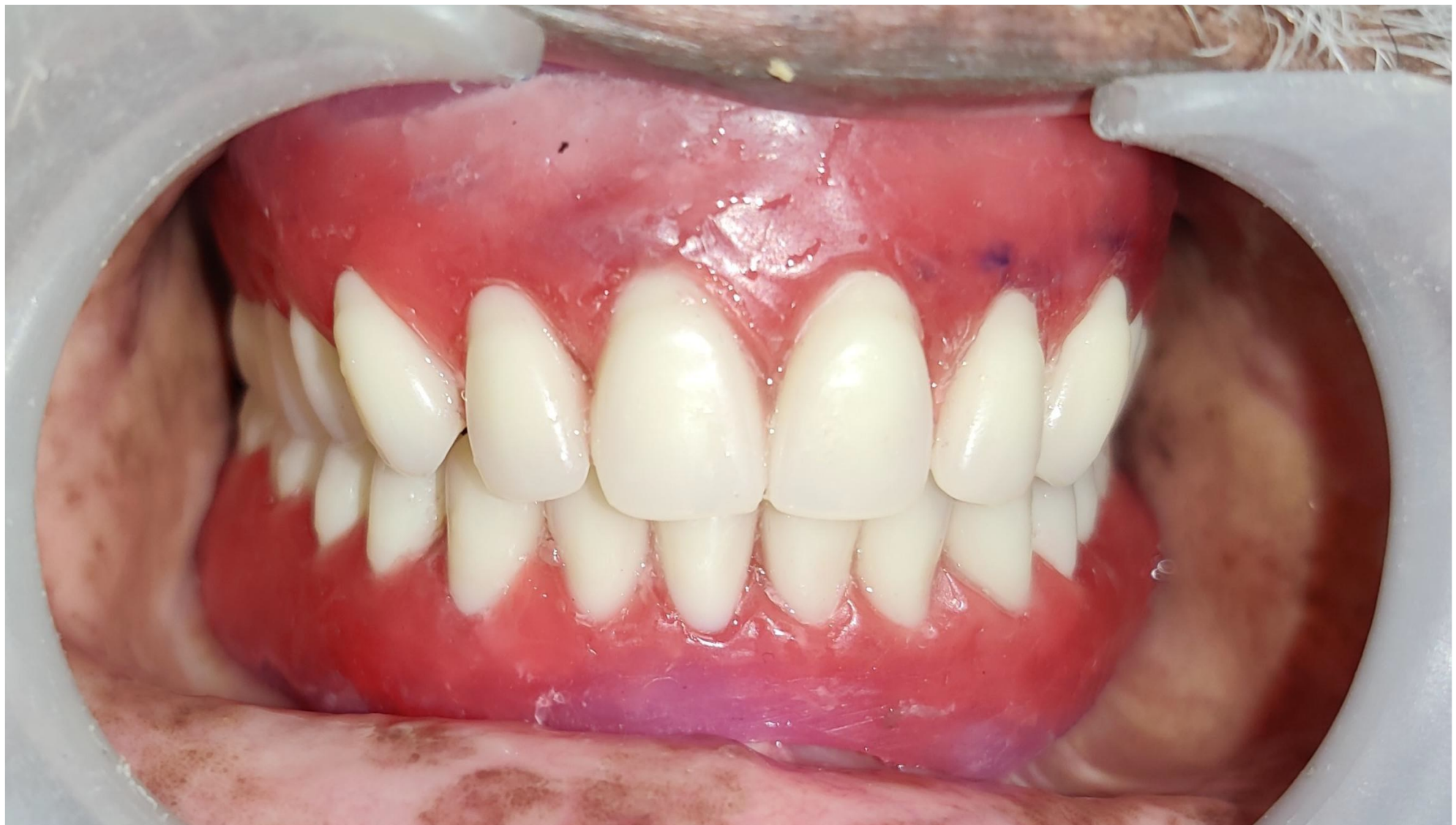INTRA ORAL RECORDS



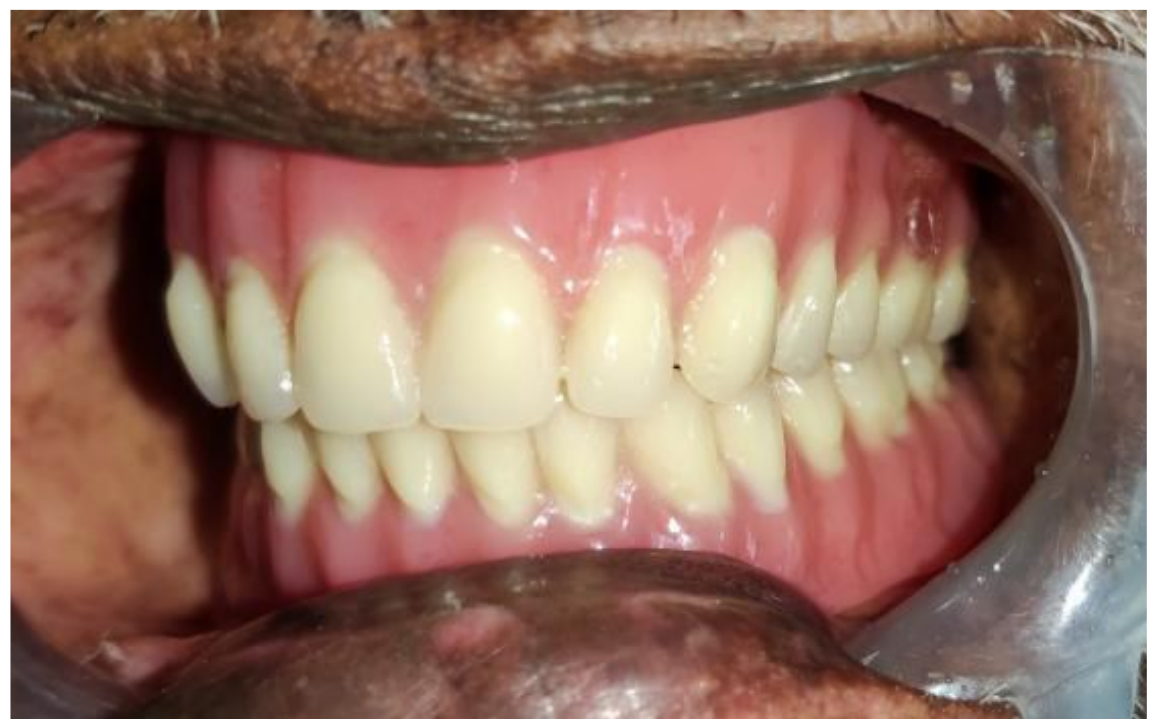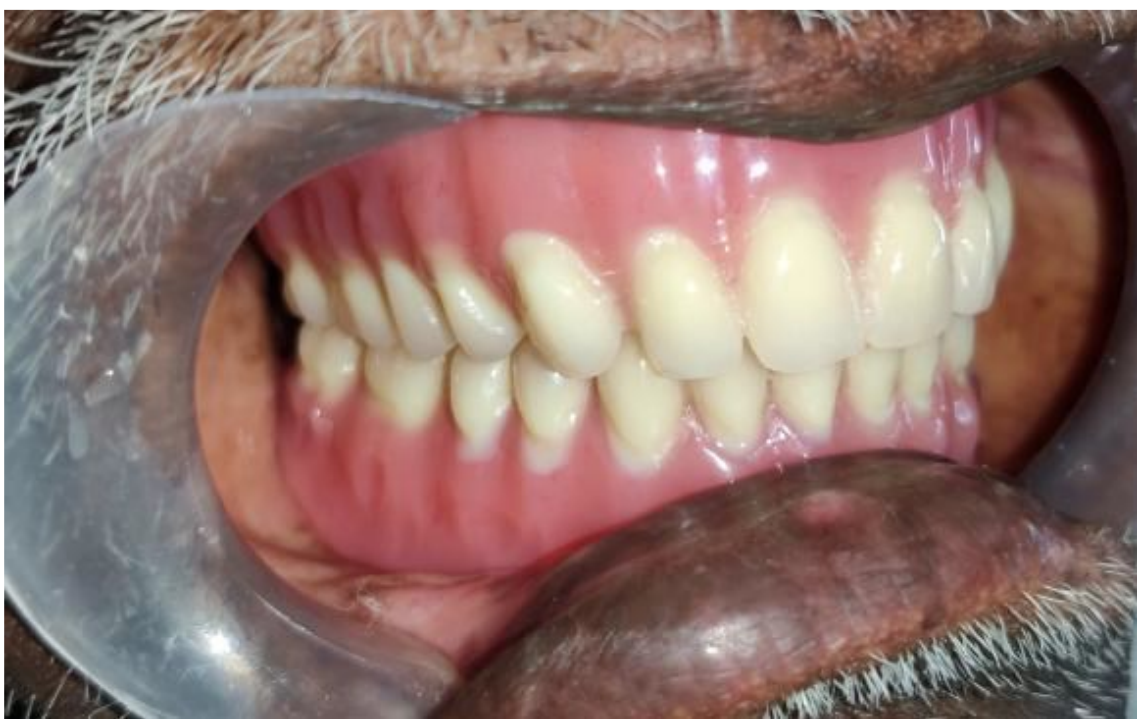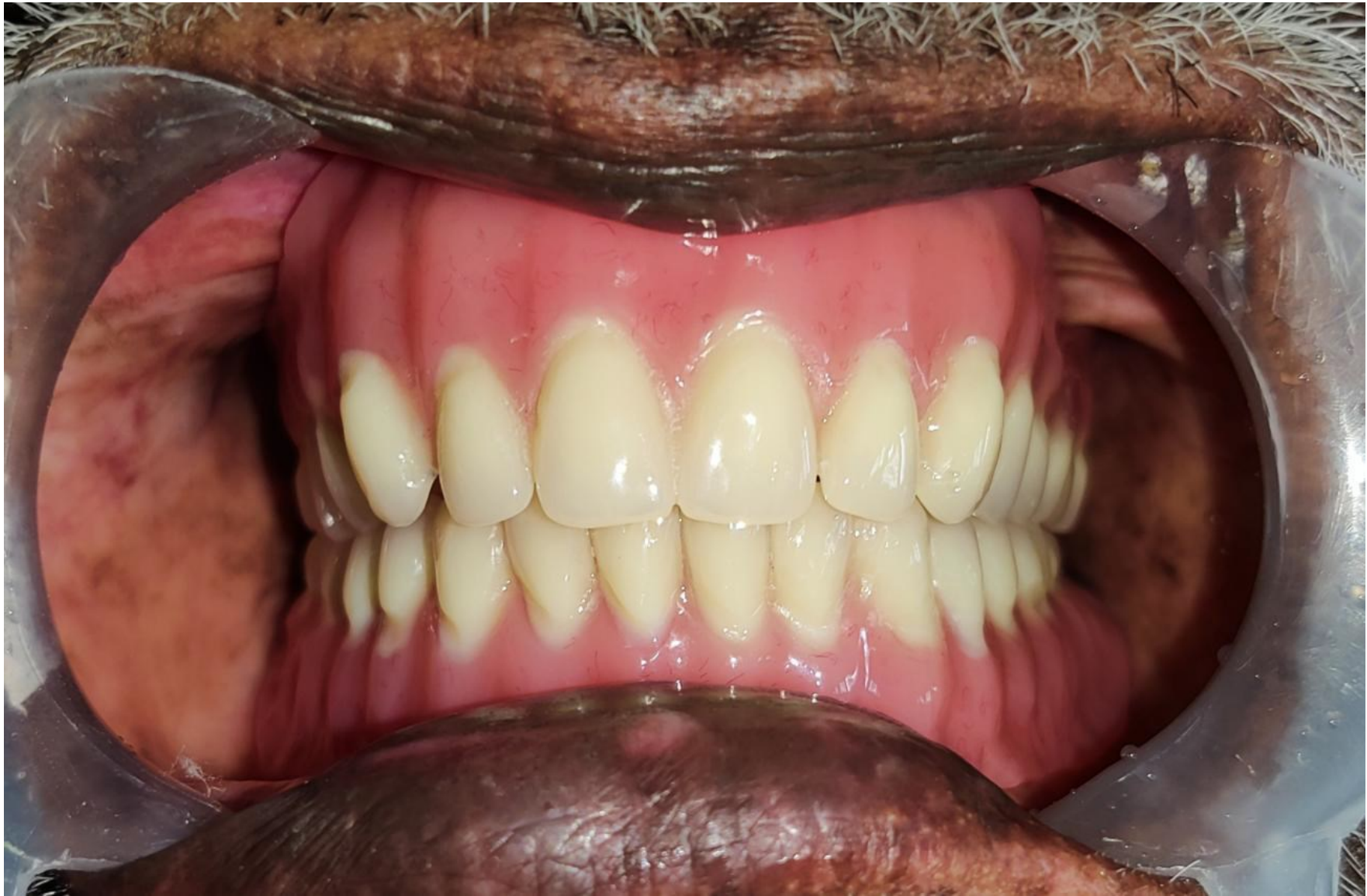3RD APPOINTMENT

WAX TRY IN



DENTURE INSERTION

4TH APPOINTEMENT

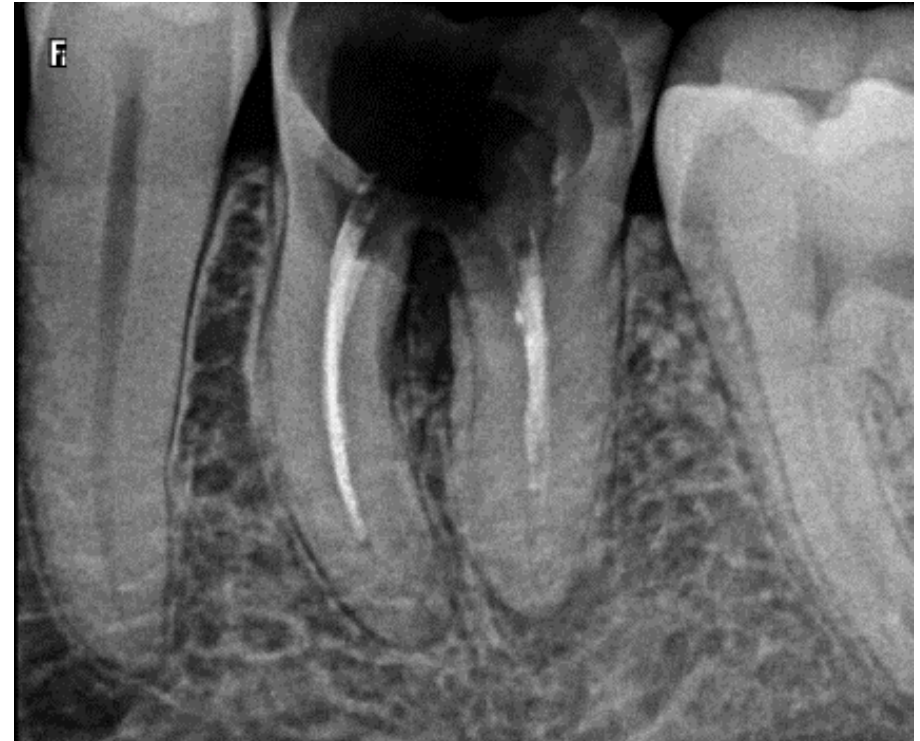
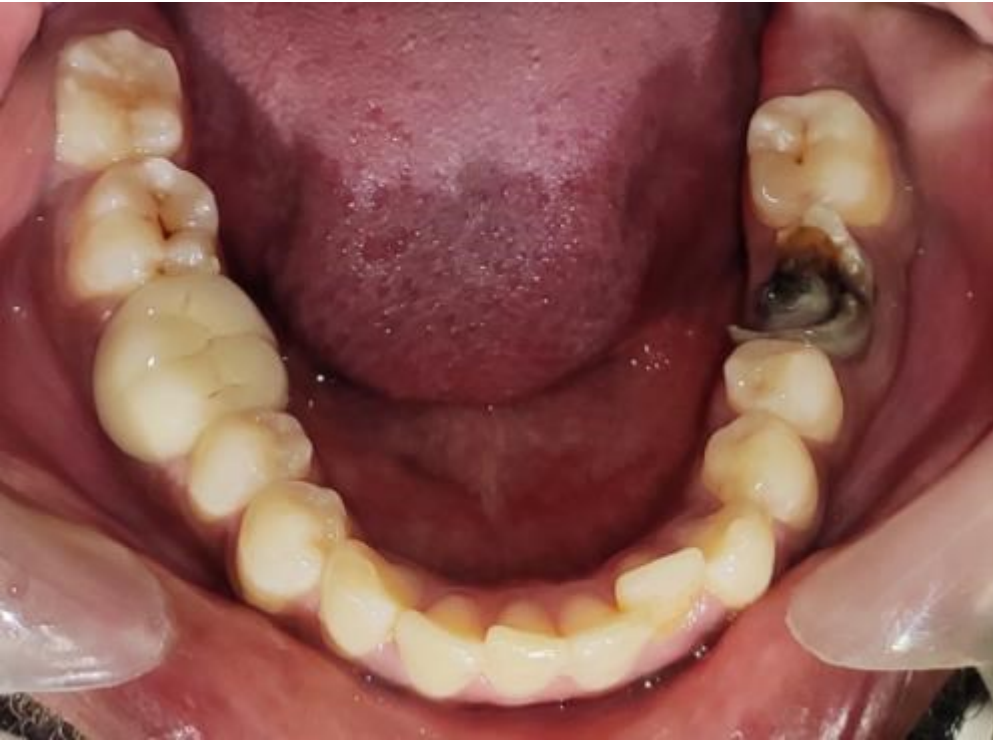
IMMEDIATE IMPLANT PLACEMENT WITH L-PRF AND BONE GRAFT

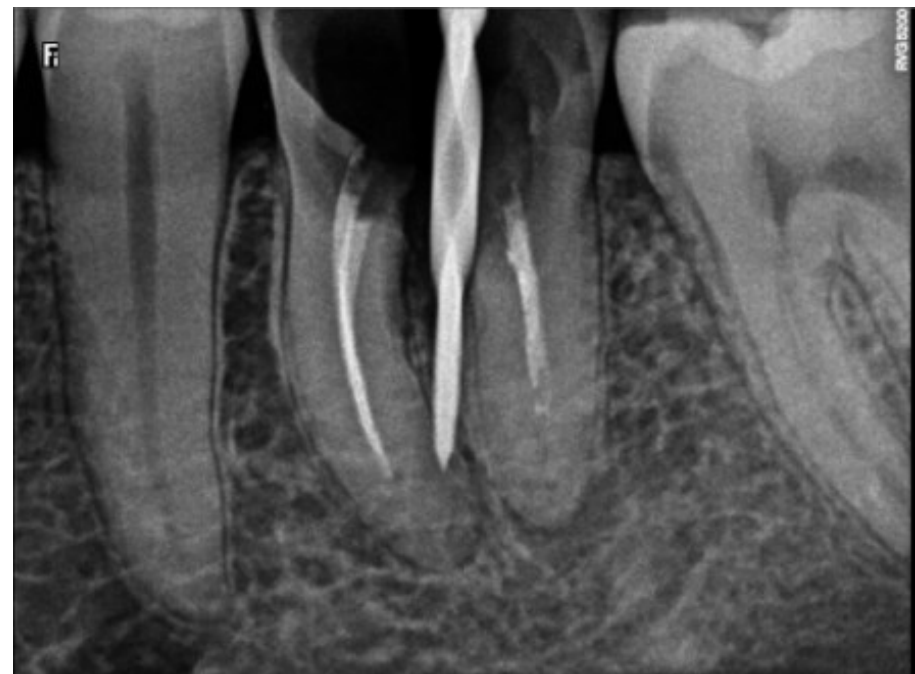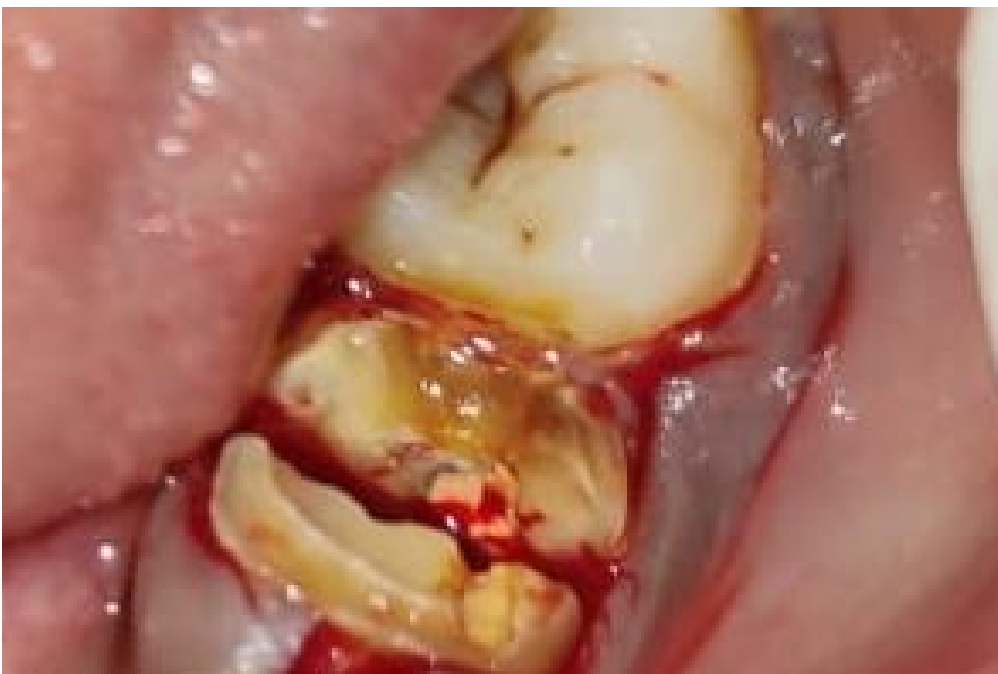PATIENT NAME: Mr. PUGALENDHI

RMCT: 448562

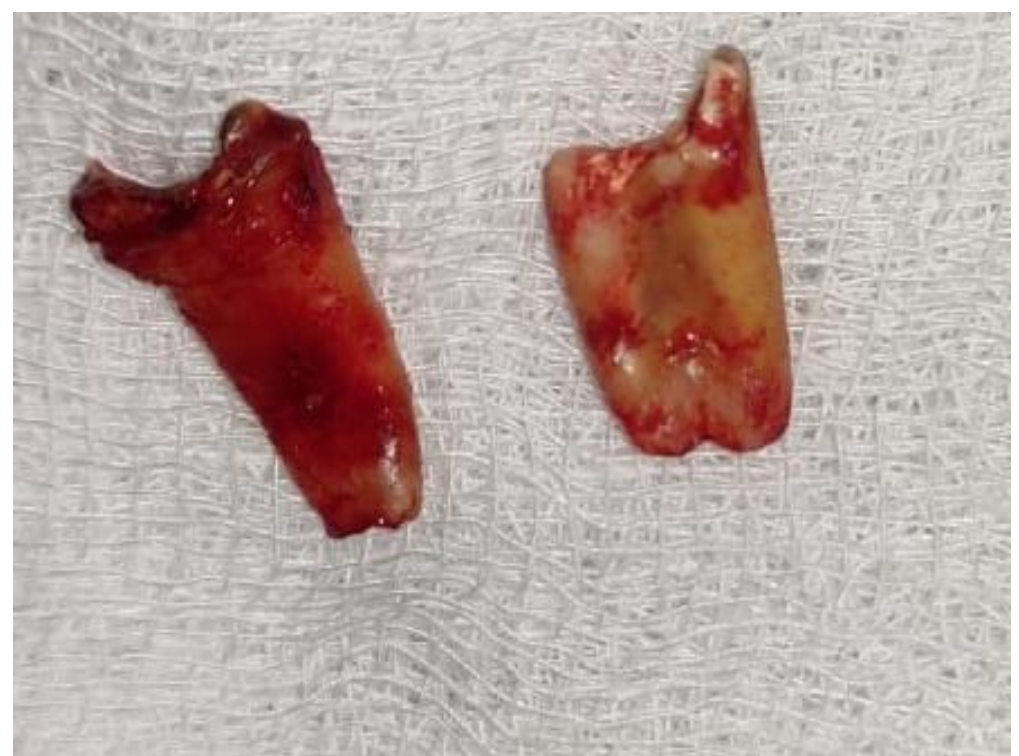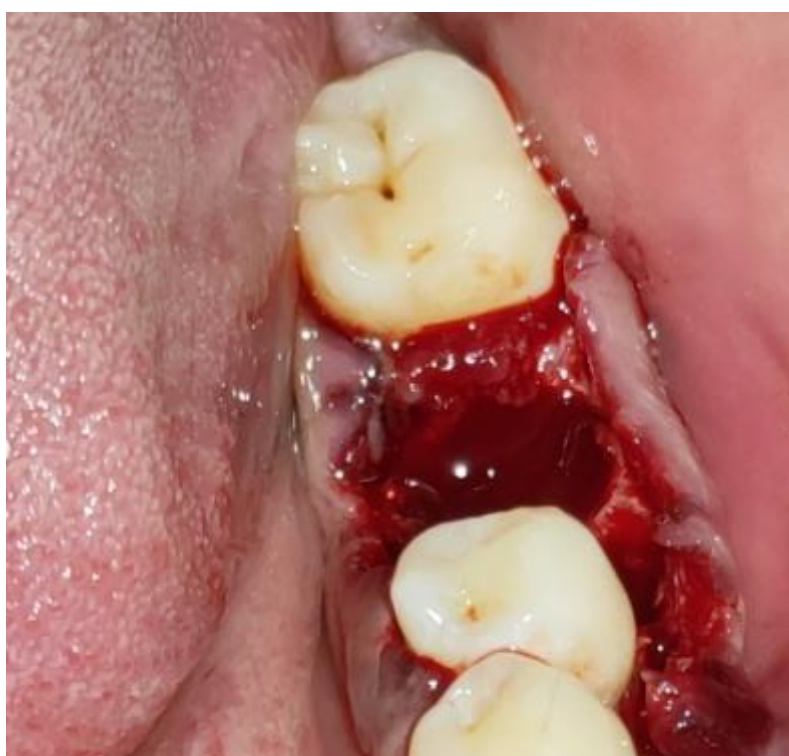PRE OP



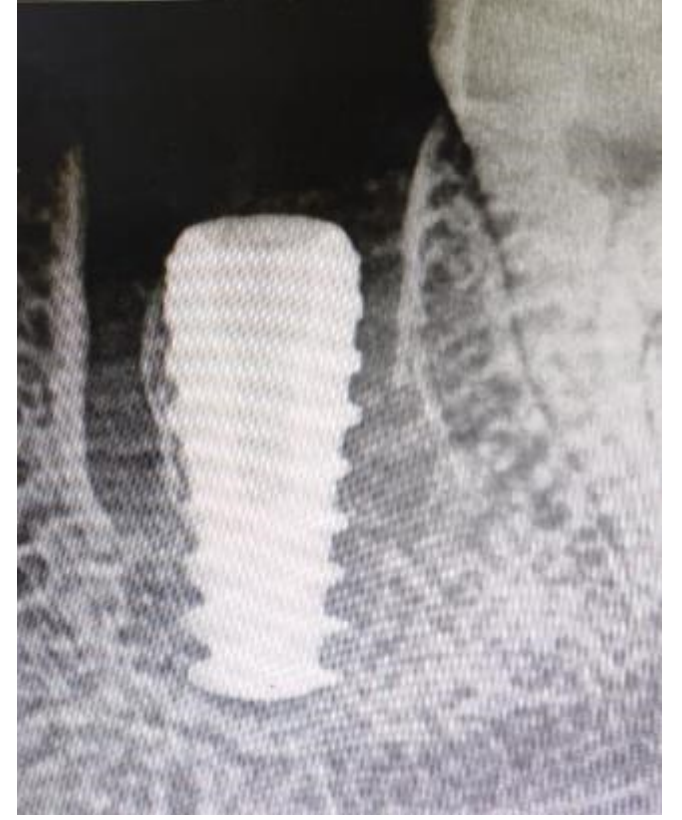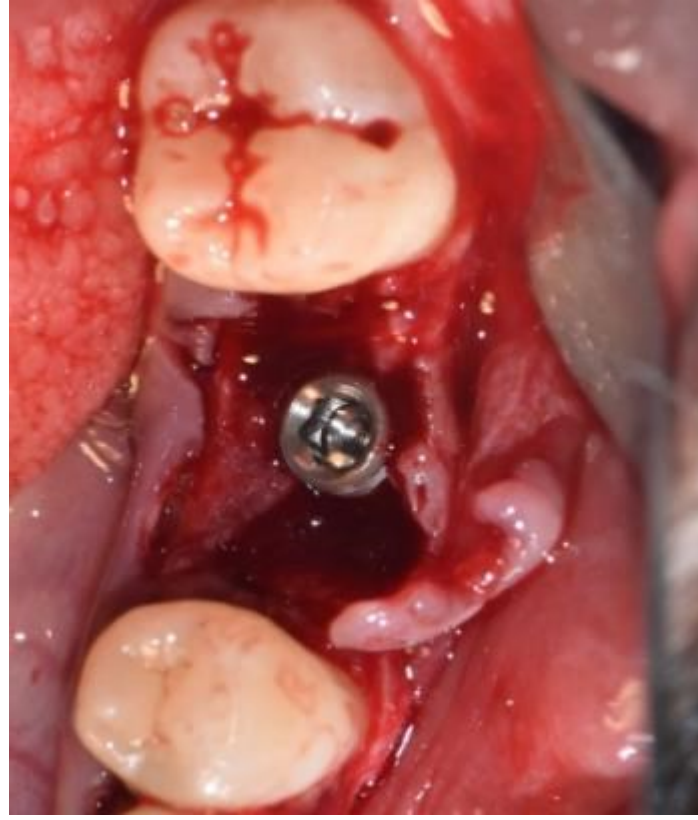
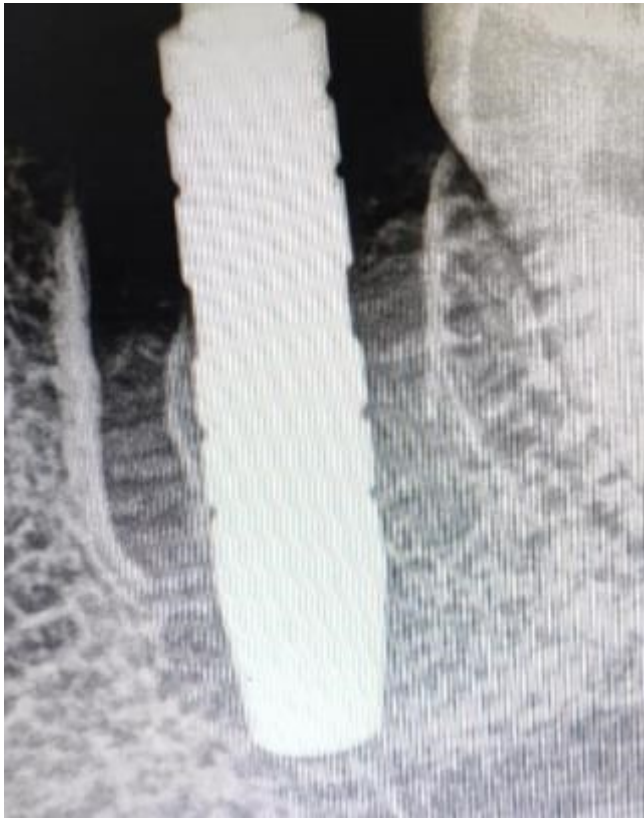TOOTH SPLITTING



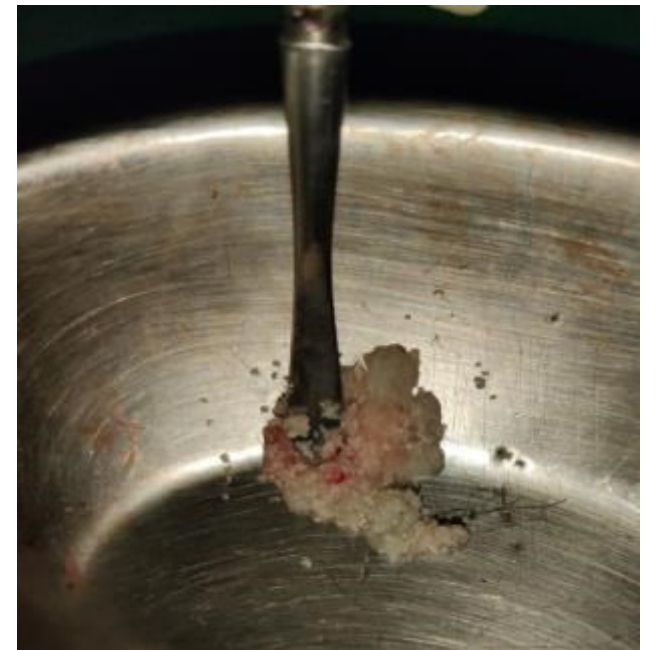EXTRACTION



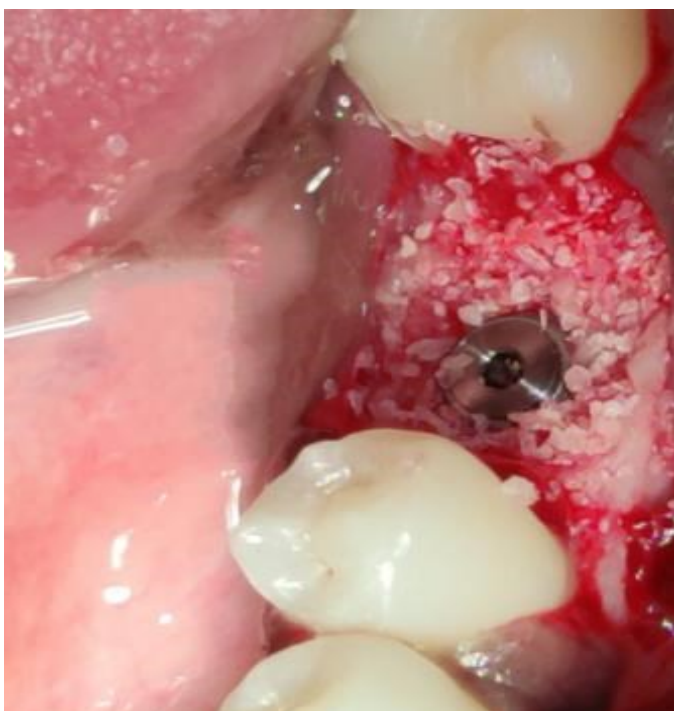
SEQUENTIAL OSTEOTOMY DONE AND IMMEDIATE IMPLANT PLACED



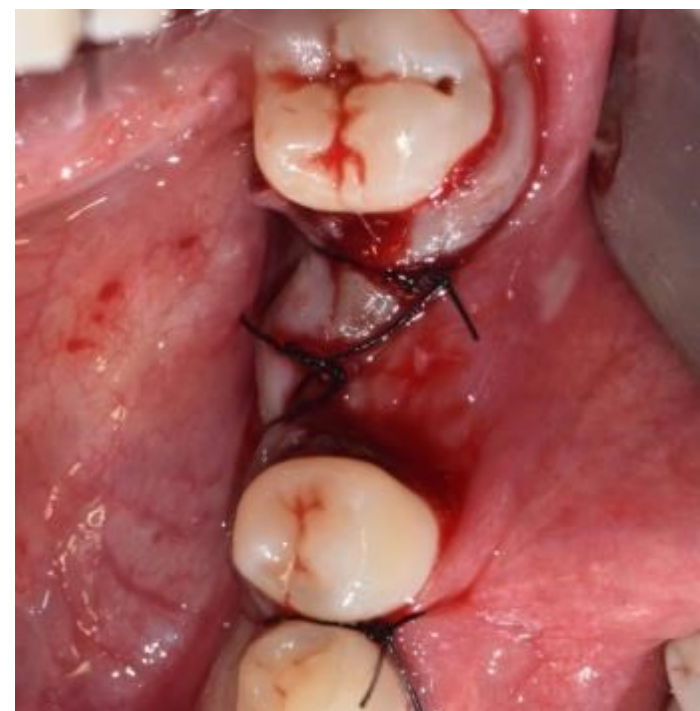MIXTURE OF L-PRF AND BONE GRAFT



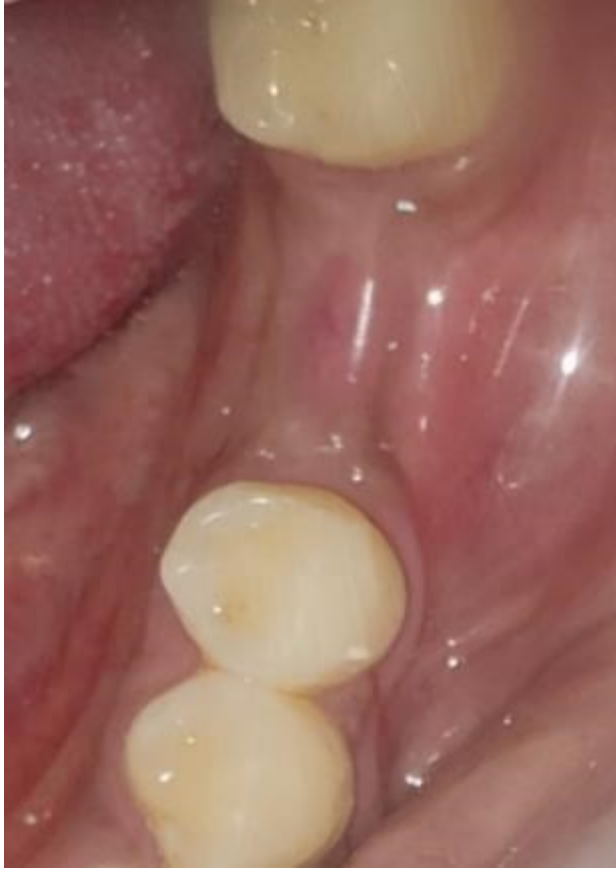MIXTURE OF L-PRF AND BONE GRAFT PLACED



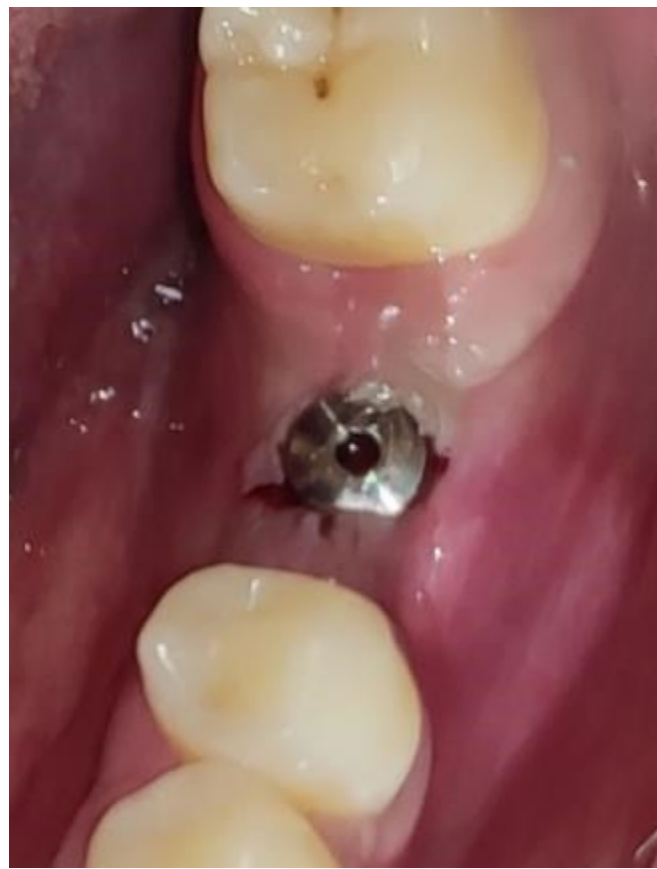SUTURES PLACED



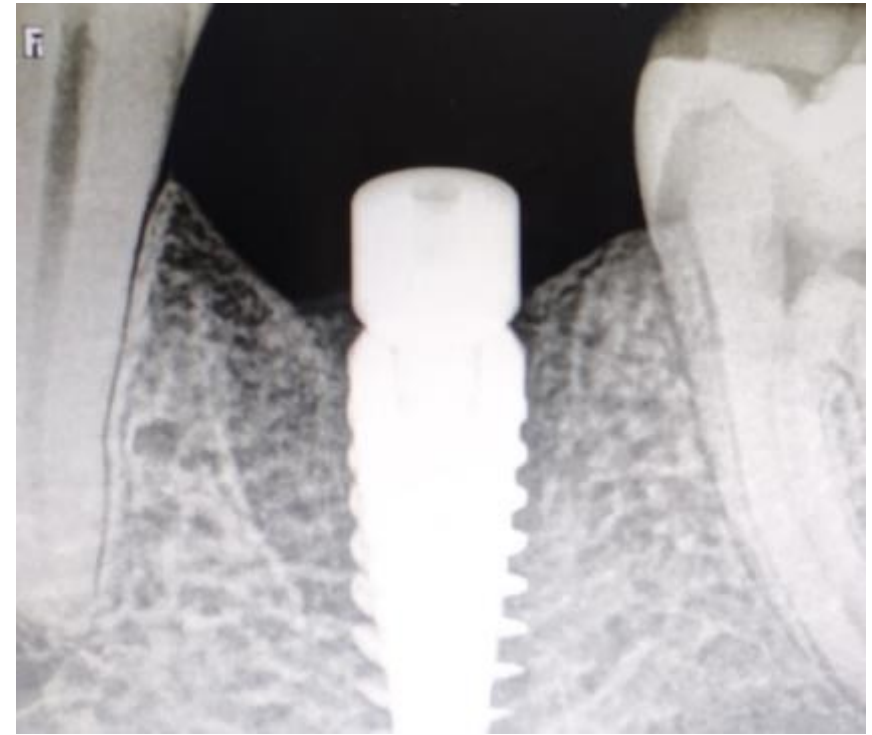
SECOND STAGE
SURGERY



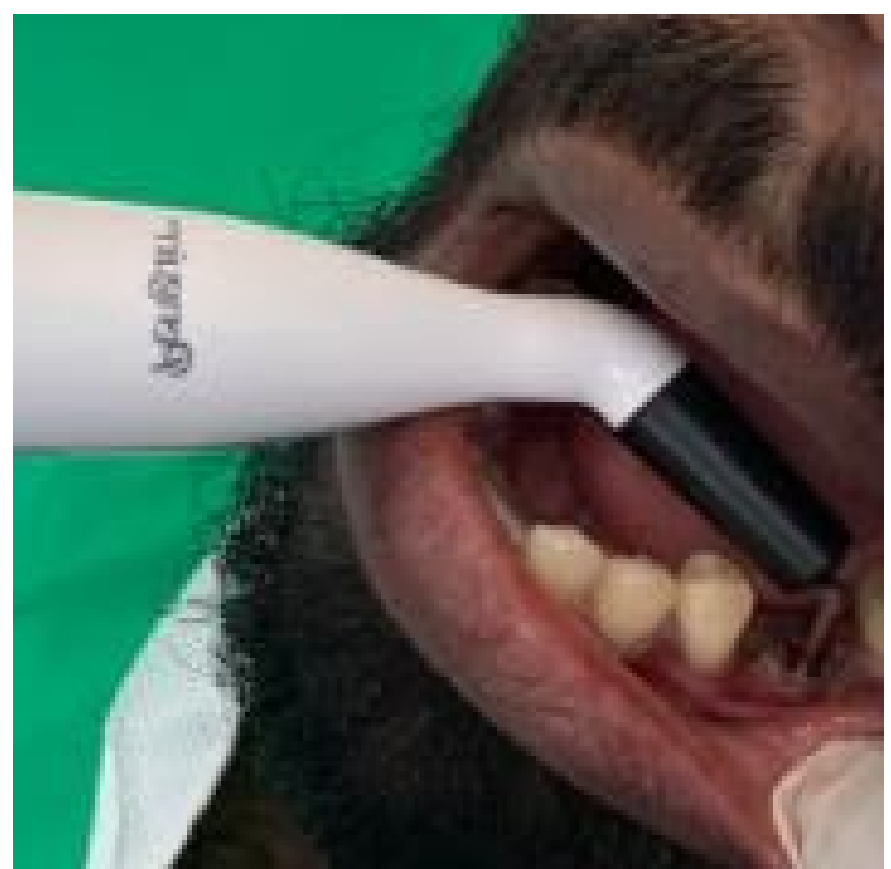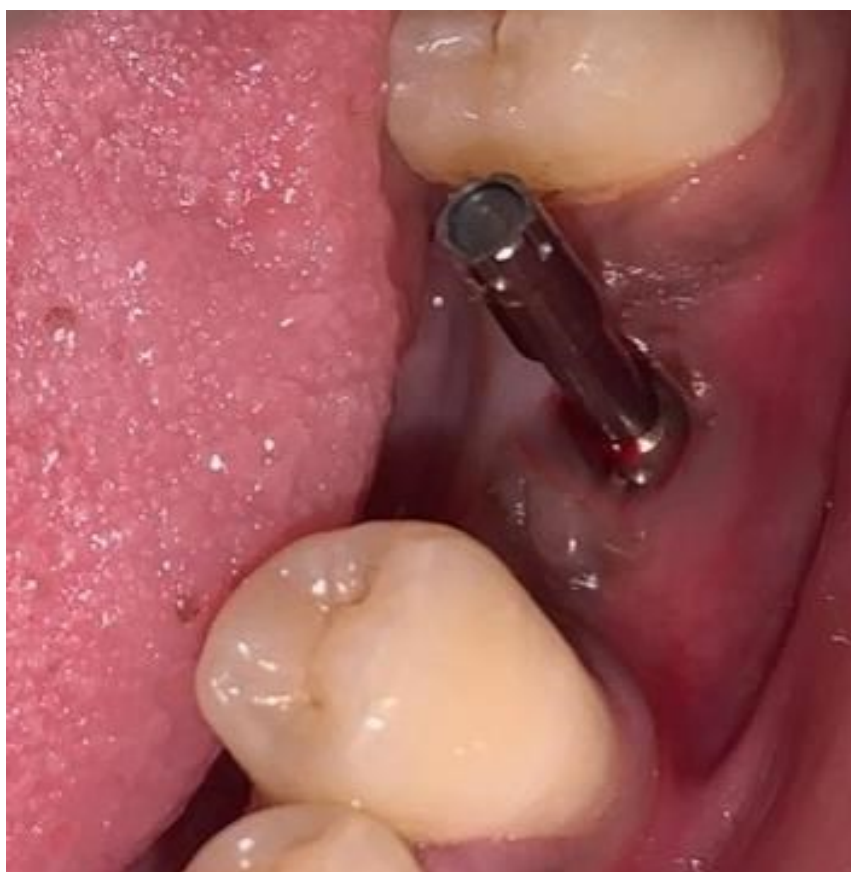HEALING COLLAR
PLACED



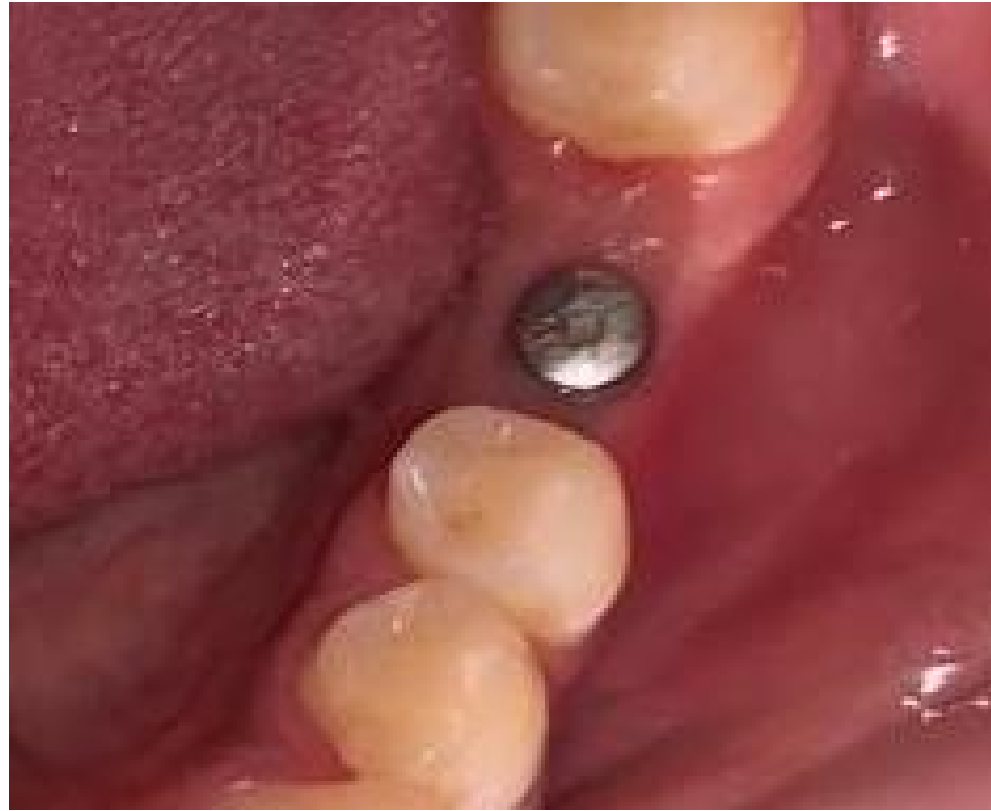CHECK X-RAY



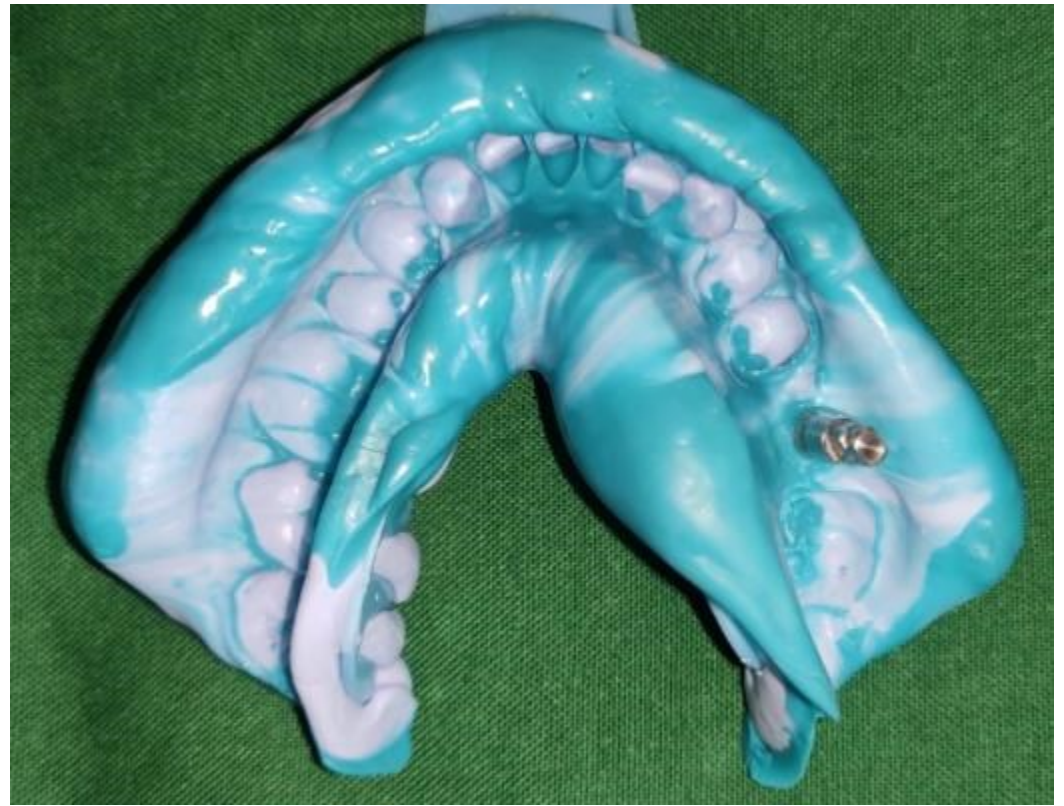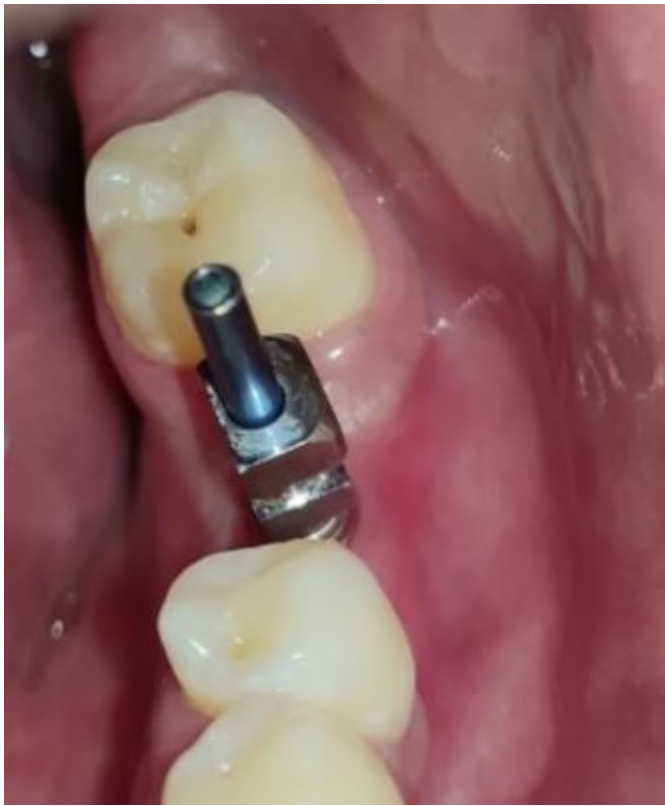IMPLANT STABILITY CHECKED USING RFA



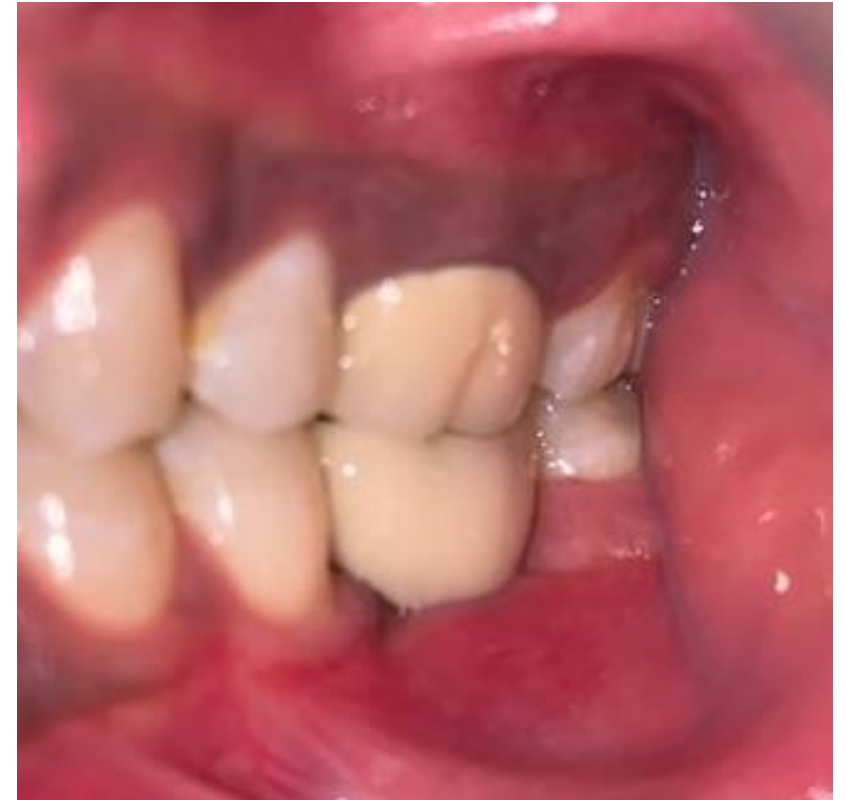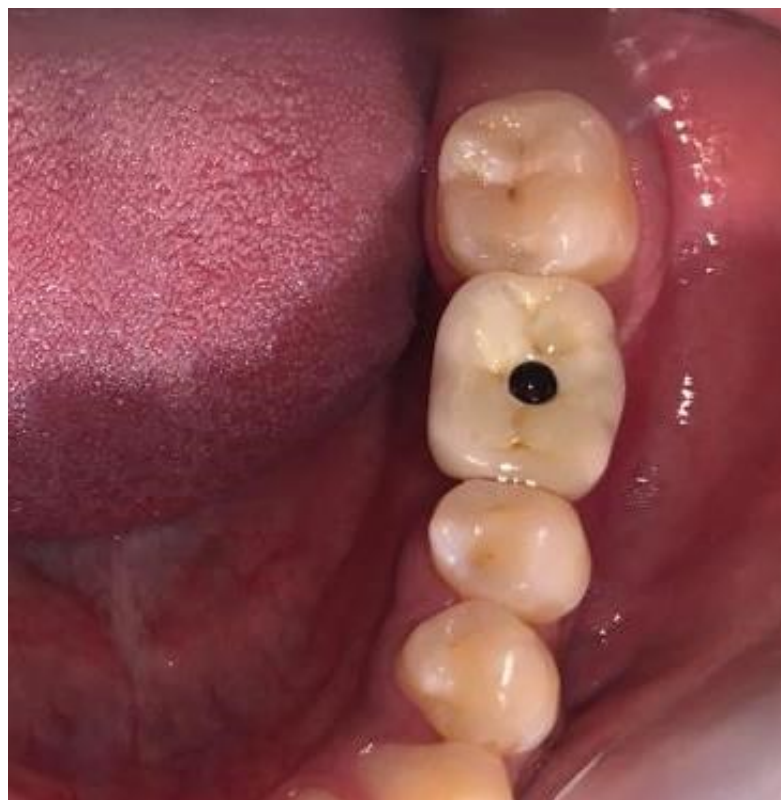
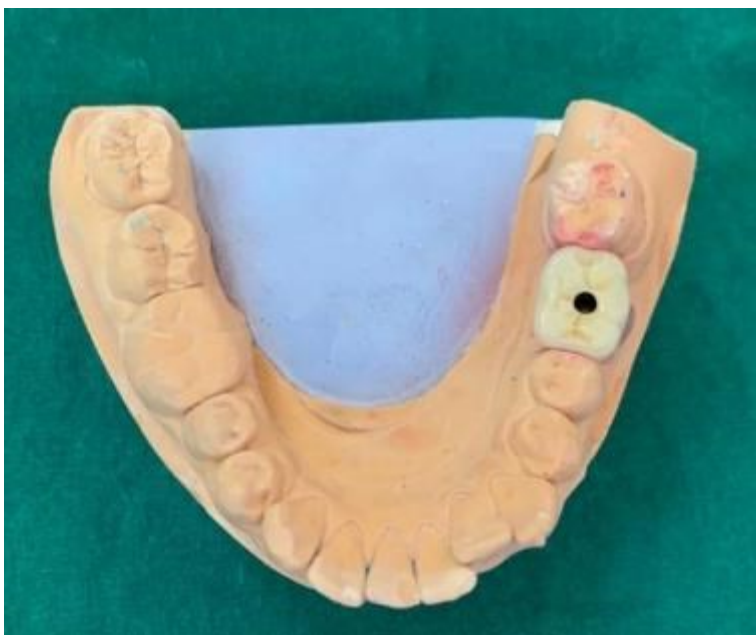PROSTHETIC PHASE



IMPLANT LEVEL-OPEN TRAY IMPRESSION MADE



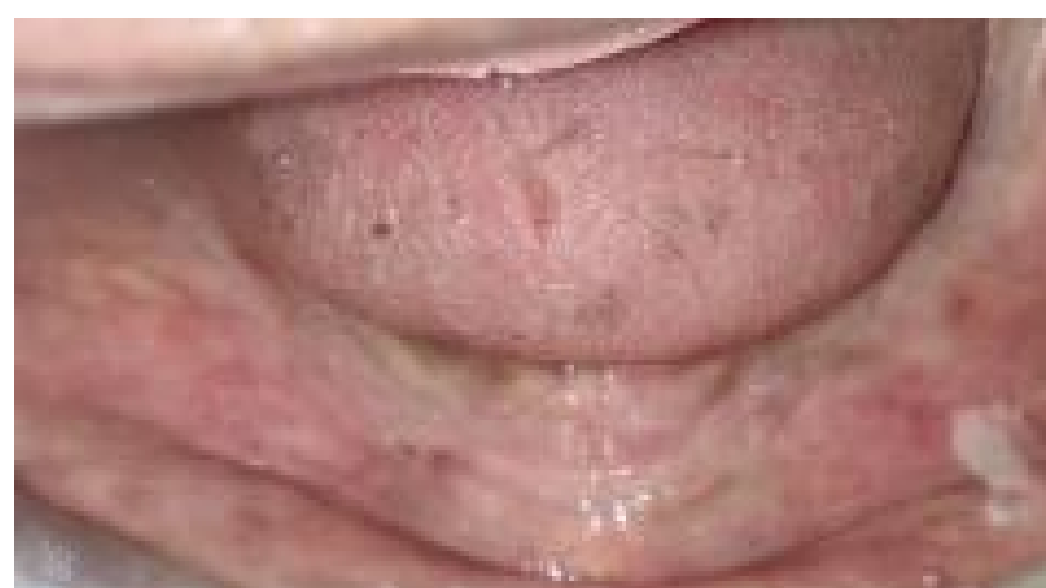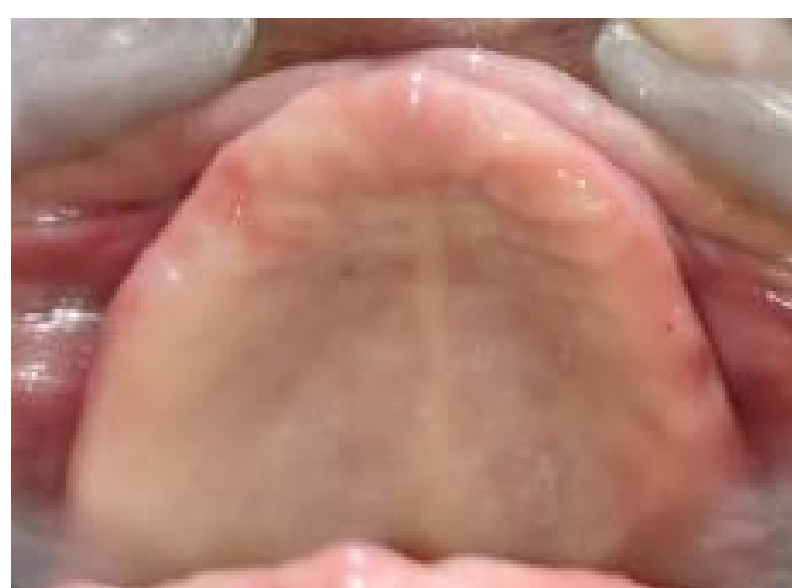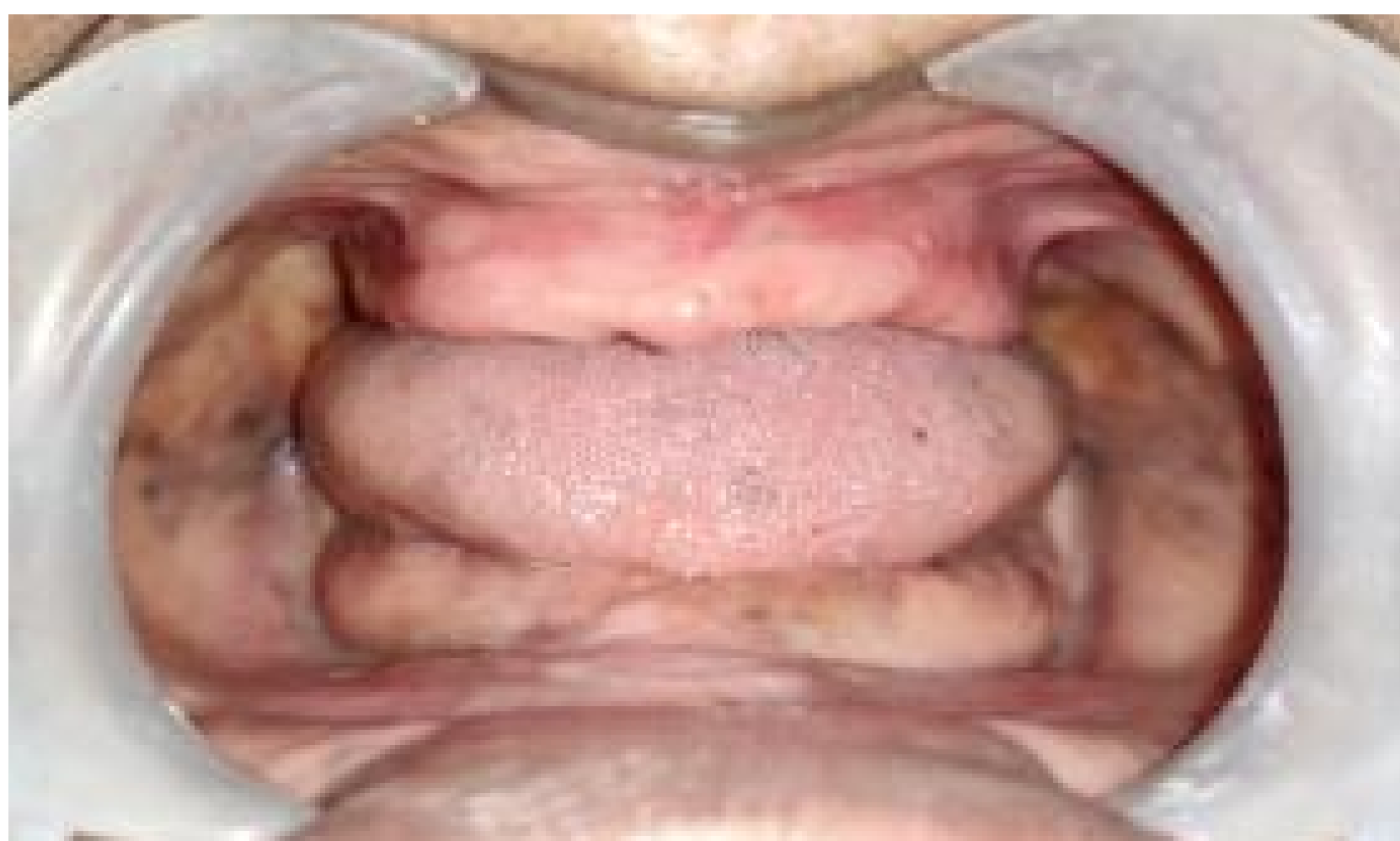POST-OP



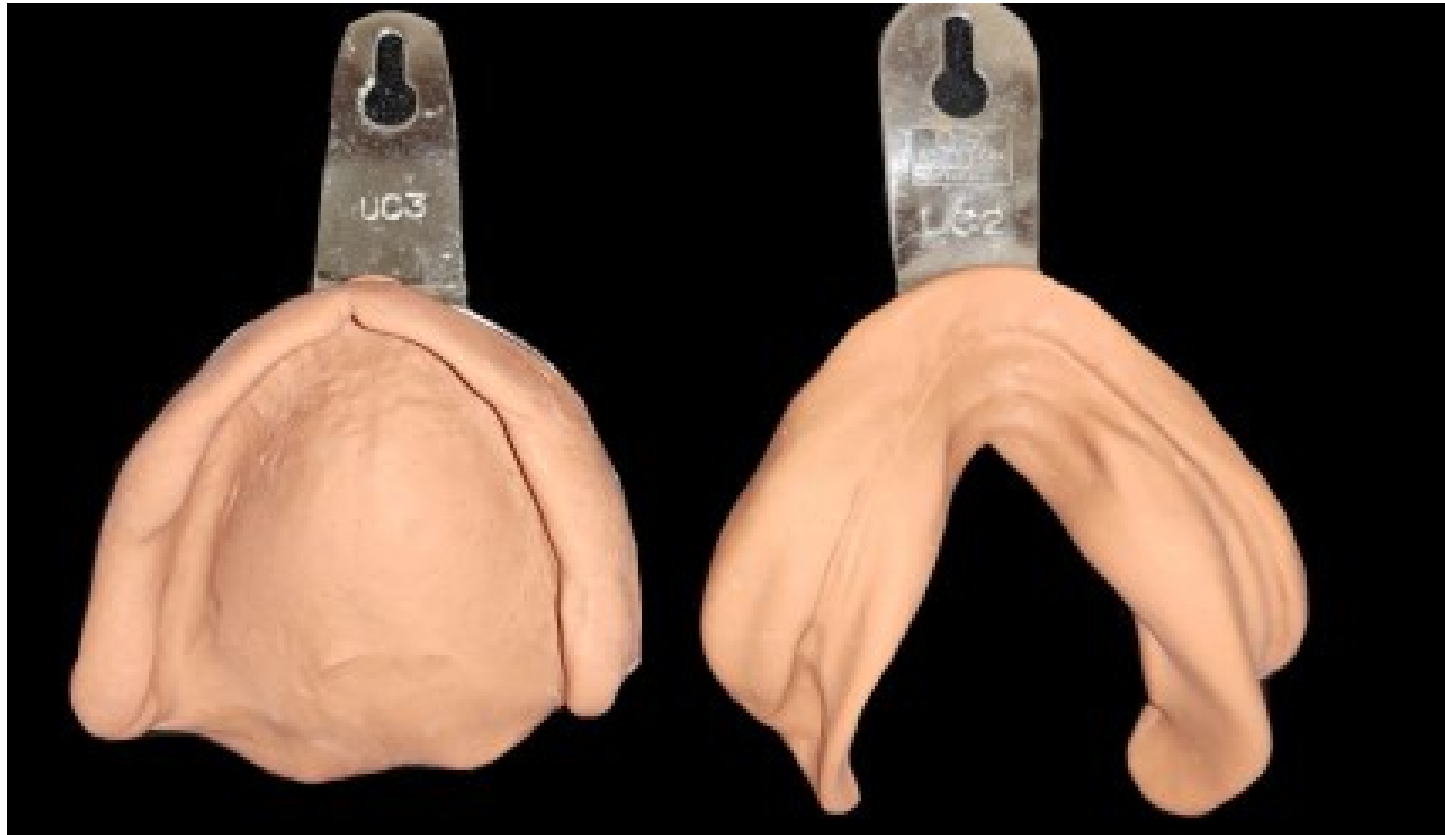NEUTRAL ZONE COMPLETE DENTURE

PATIENT NAME: Mrs. LAKSHMI SRINIVASAN

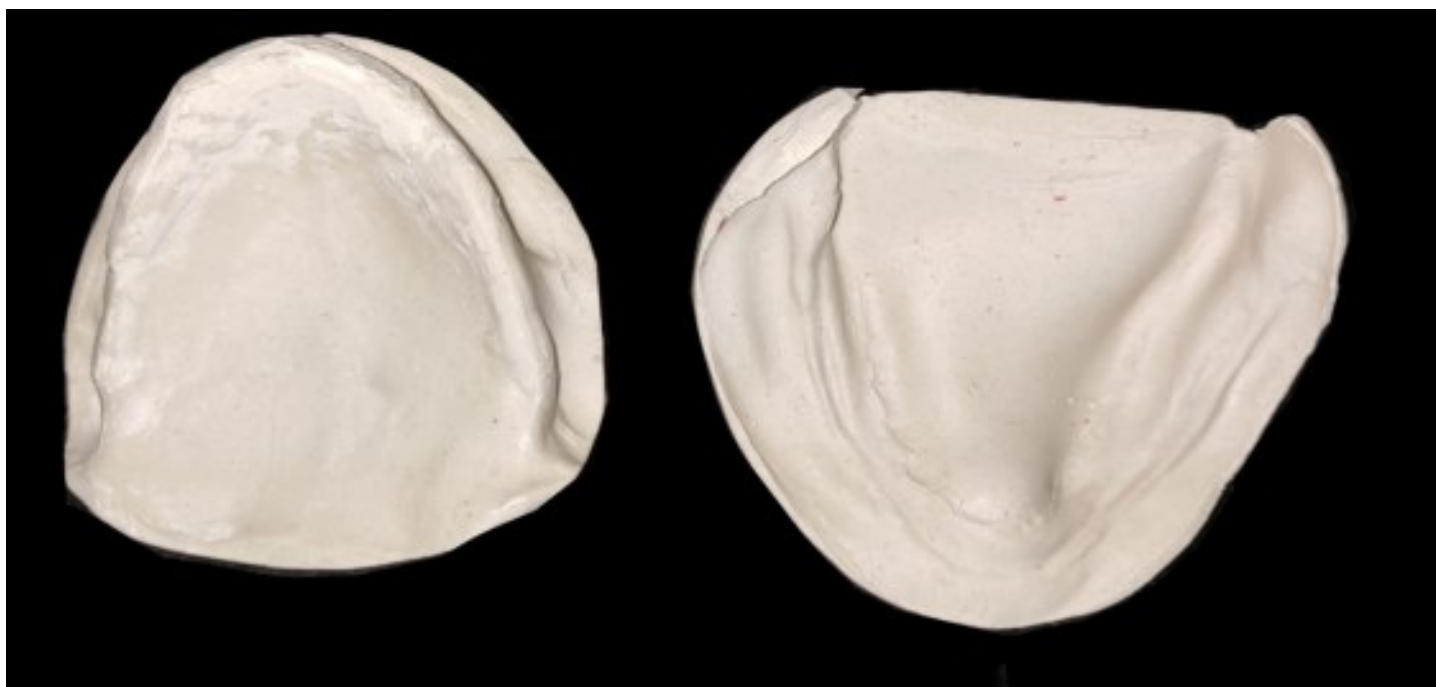
RMCT: 427891



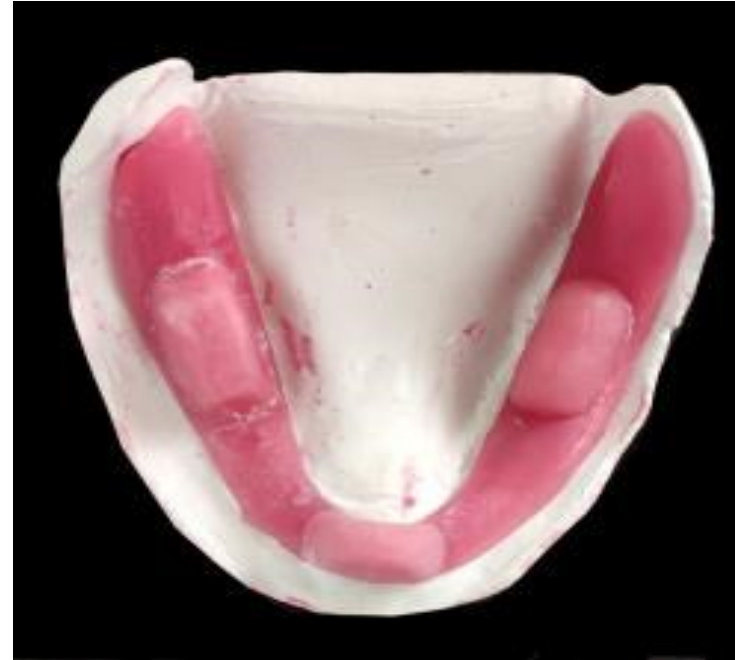PRIMARY IMPRESSION



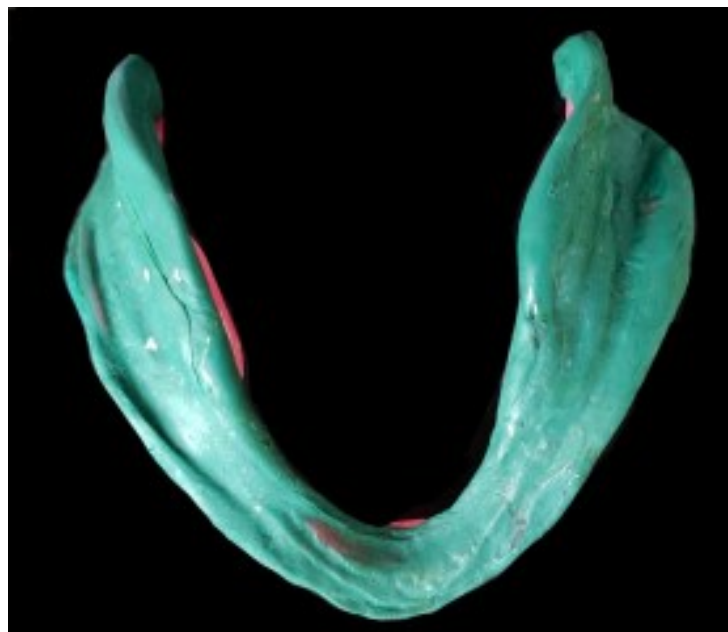
PRIMARY CAST



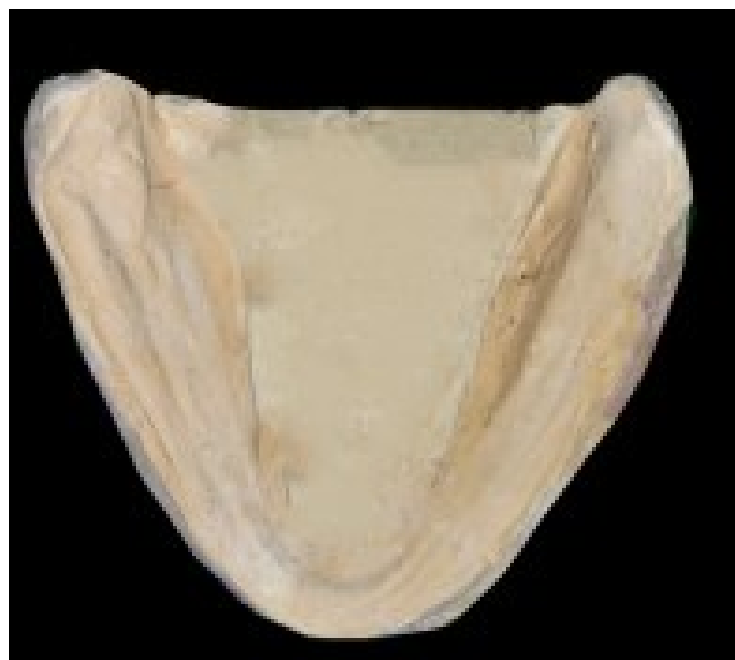SPECIAL TRAY



MANDIBULAR SECONDARY IMPRESSION IN ALL GREEN METHOD



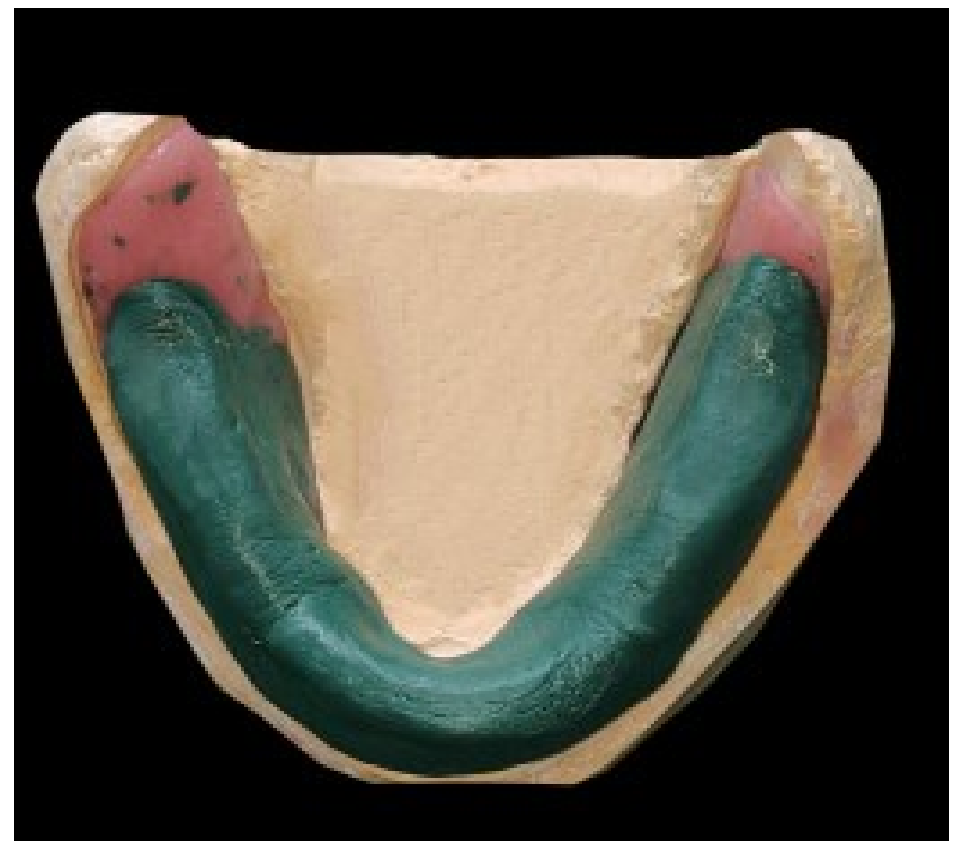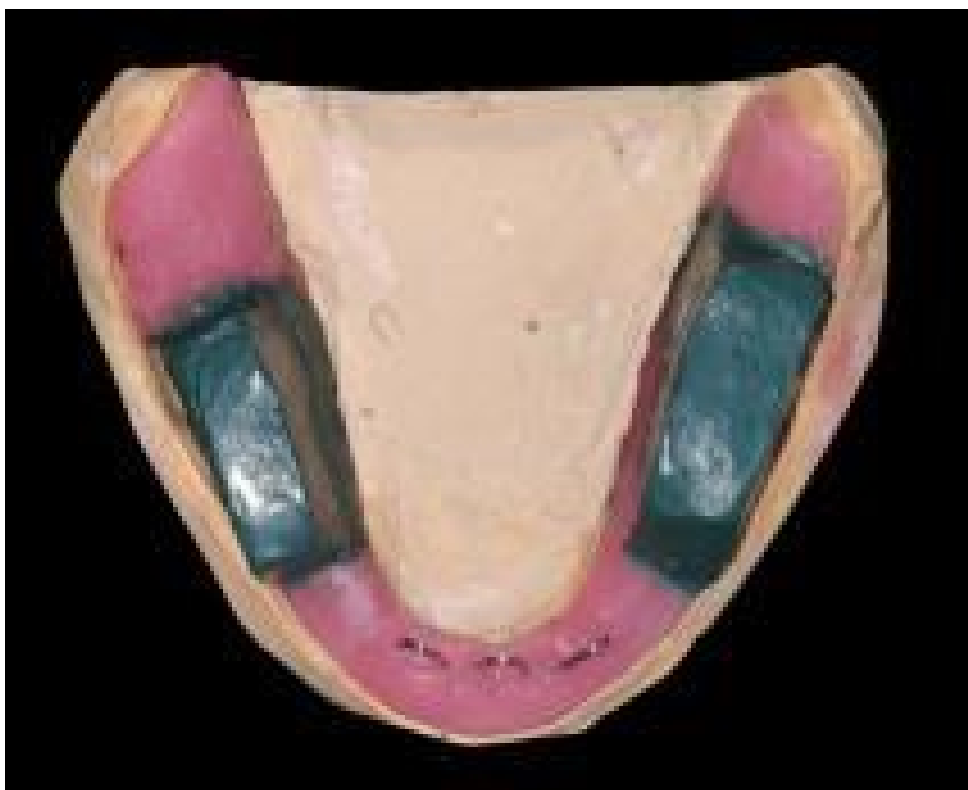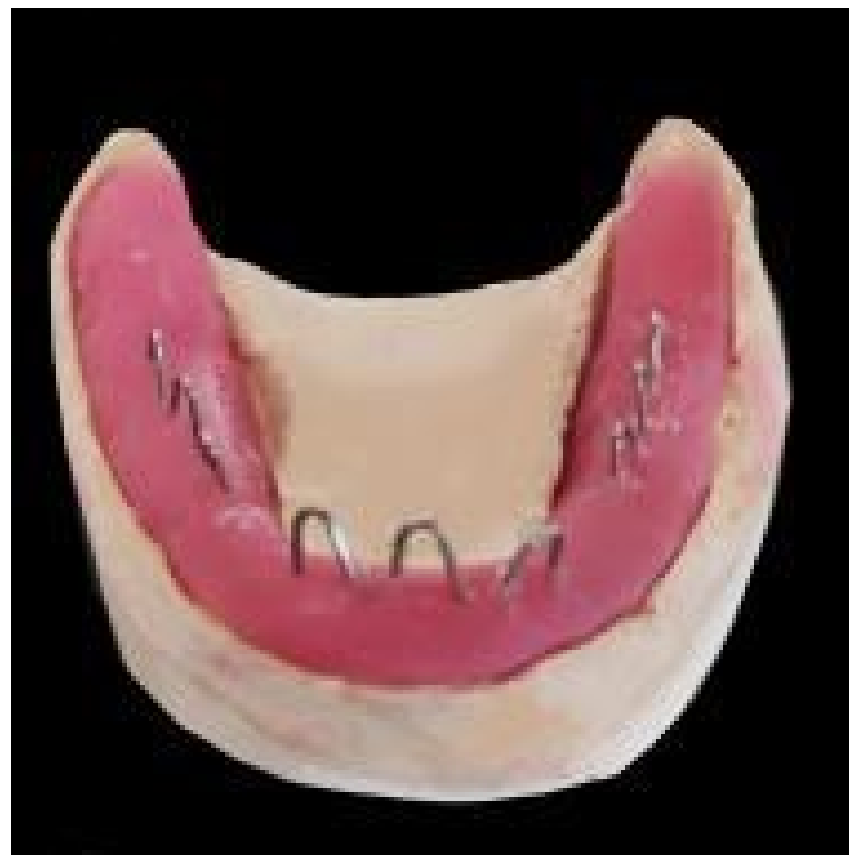MASTER CAST



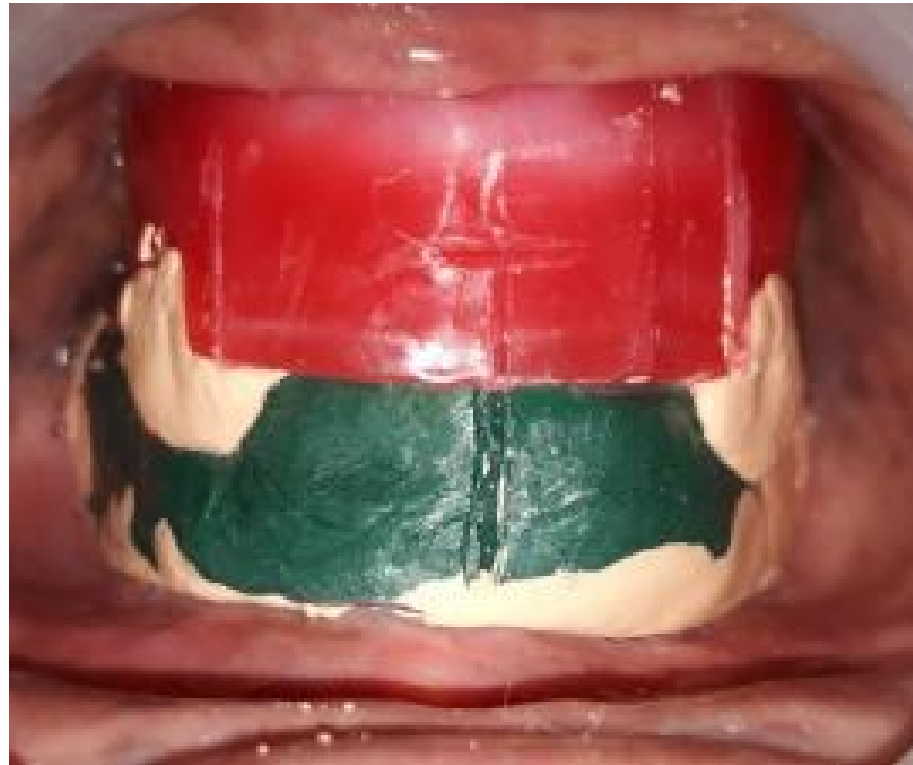MAXILLARY OCCLUSAL RIM



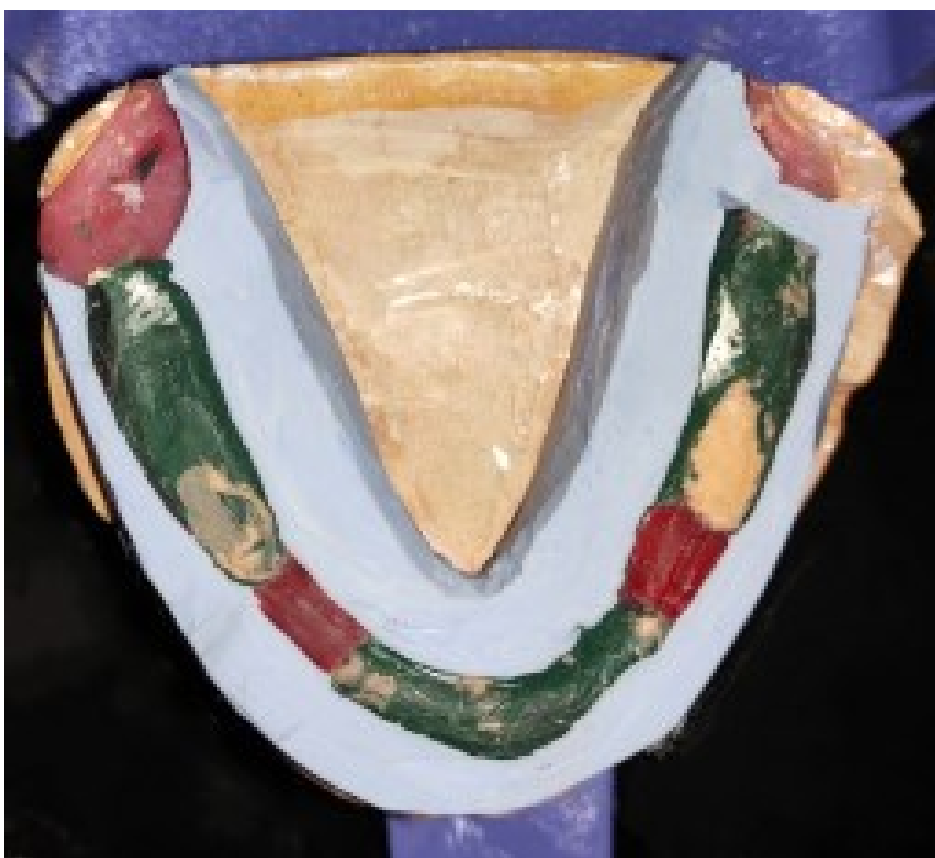NEUTRAL ZONE RECORDED



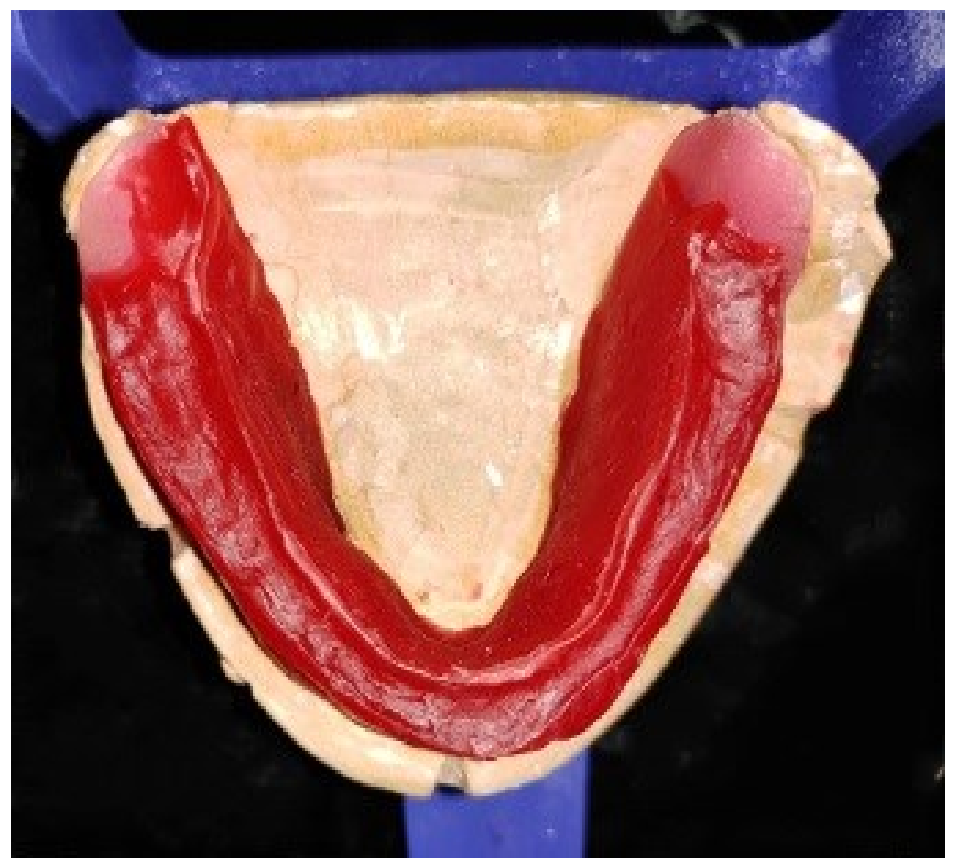JAW RELATION



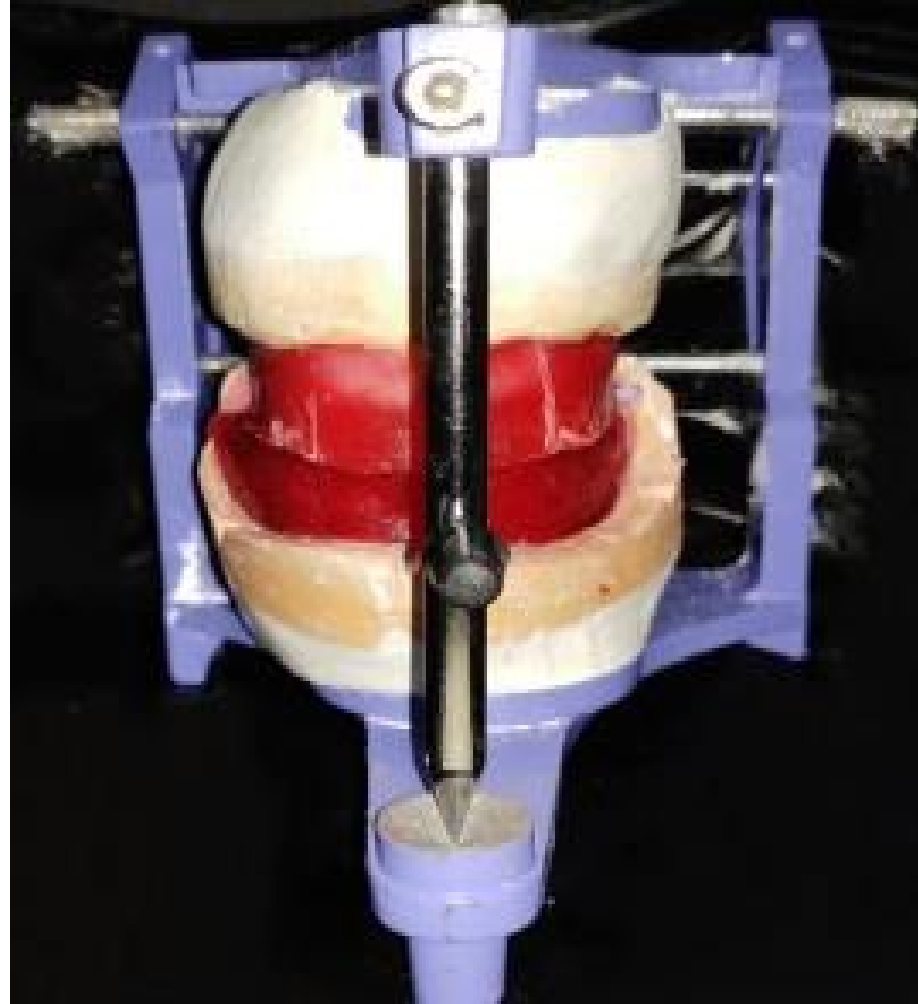
PUTTY INDEX FOR
NEUTRAL ZONE



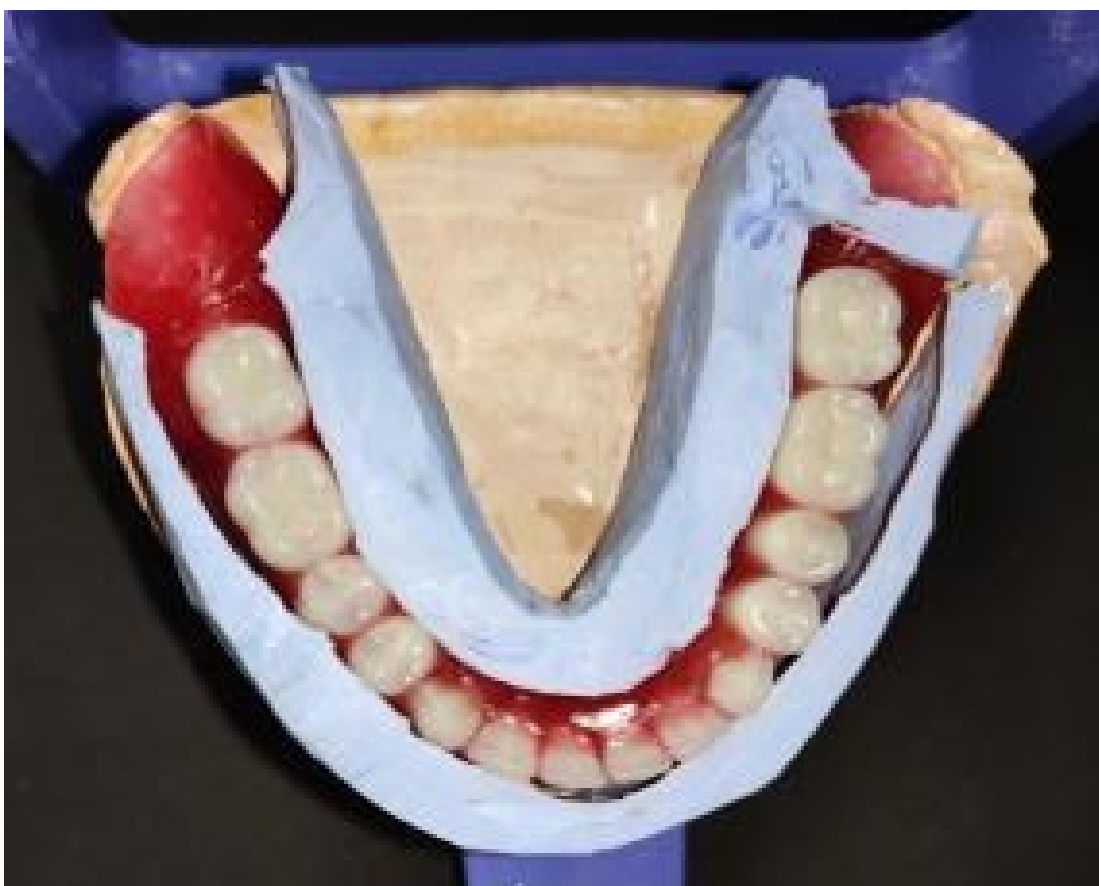NEUTRAL ZONE
CONVERTED TO
OCCLUSAL RIM



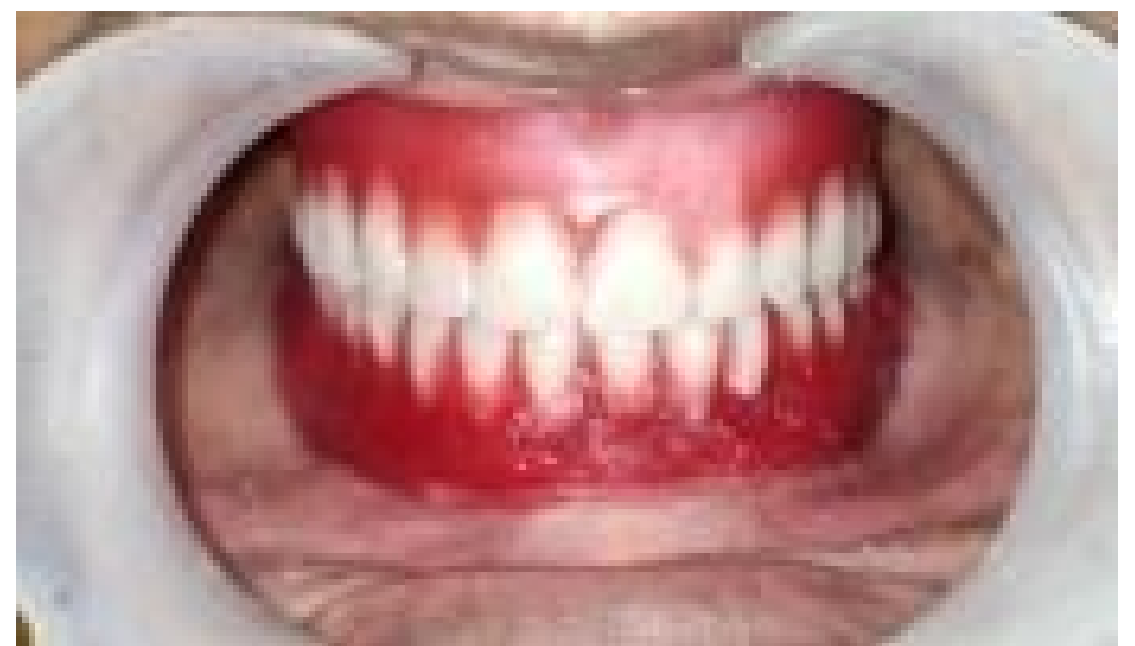ARTICULATION



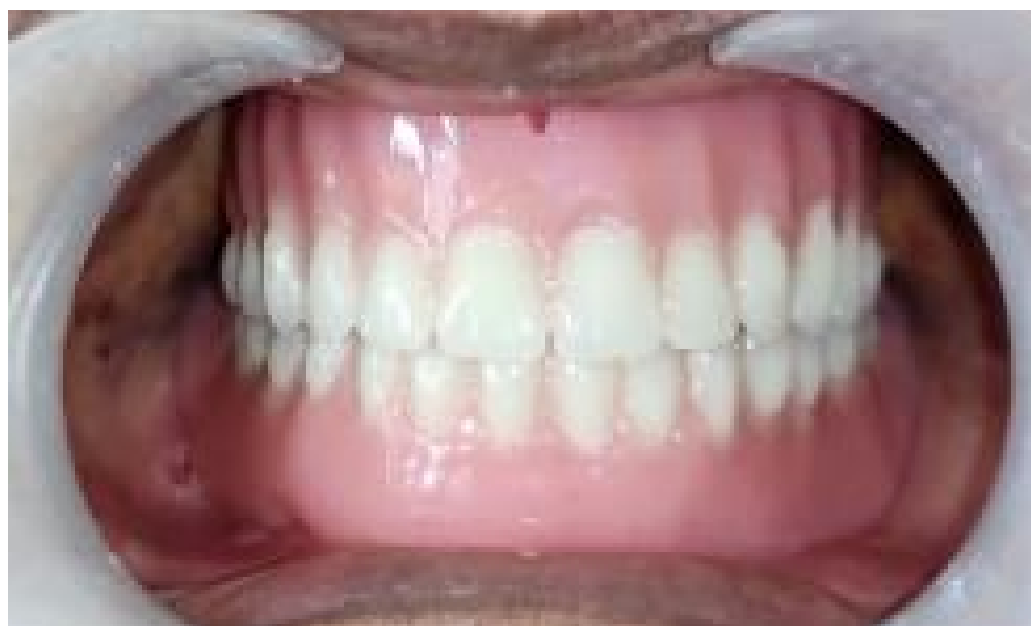MANDIBULAR TEETH
SETTING IN NEUTRAL
ZONE



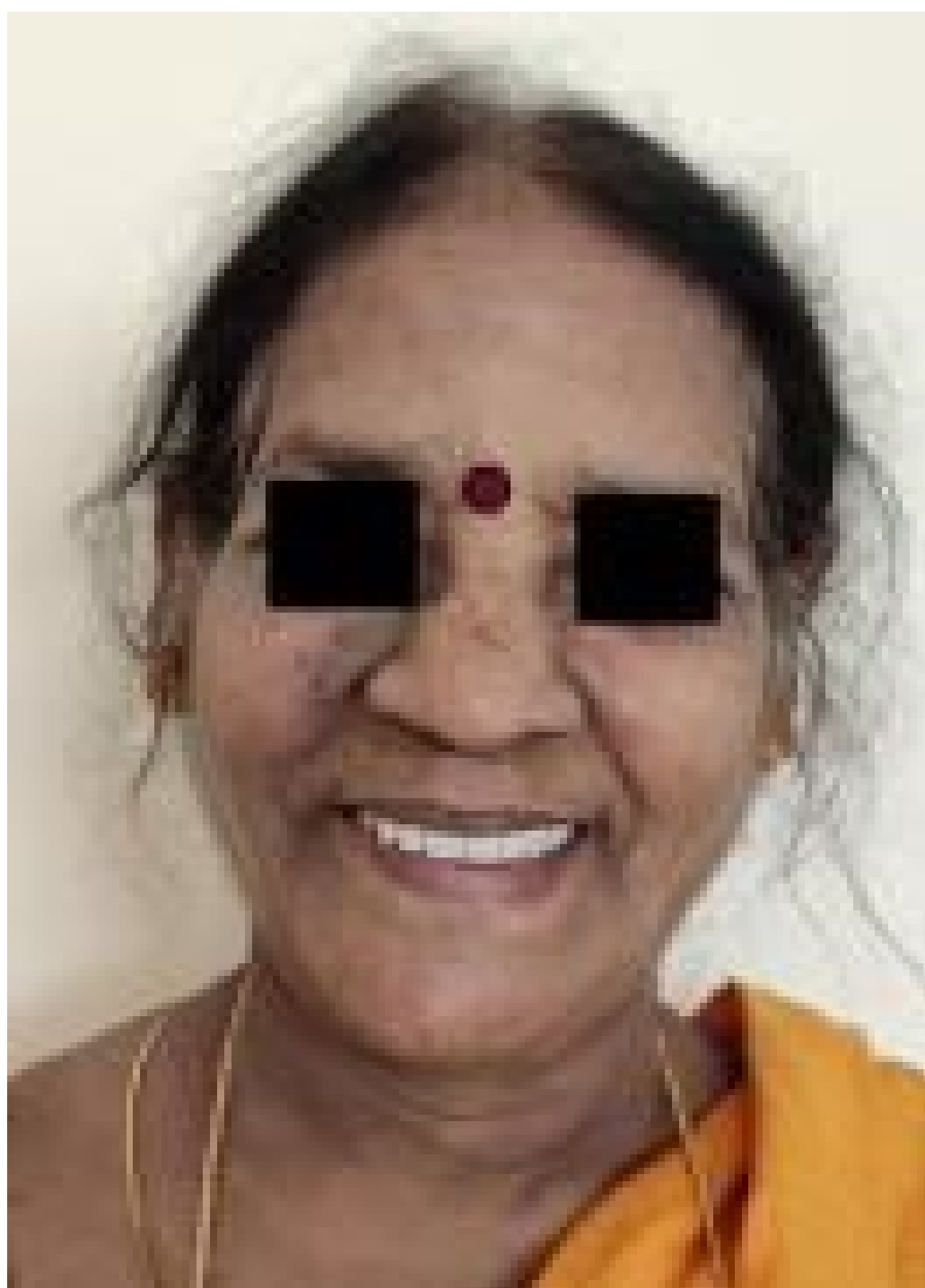WAX TRIAL



INSERTION

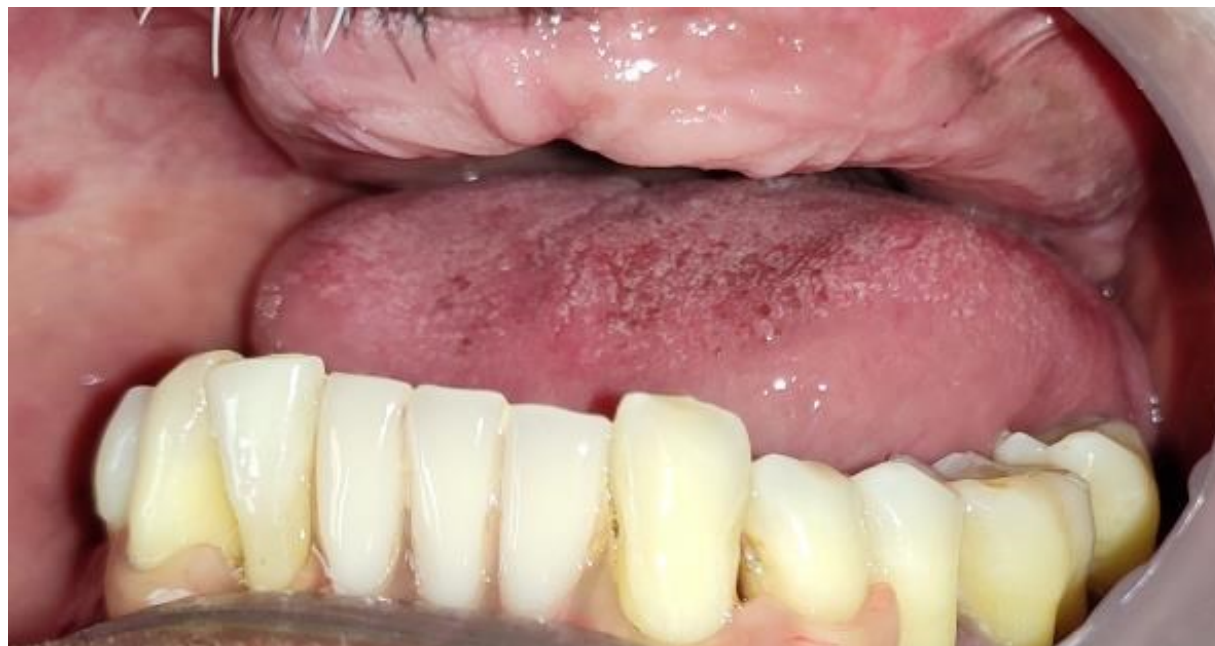
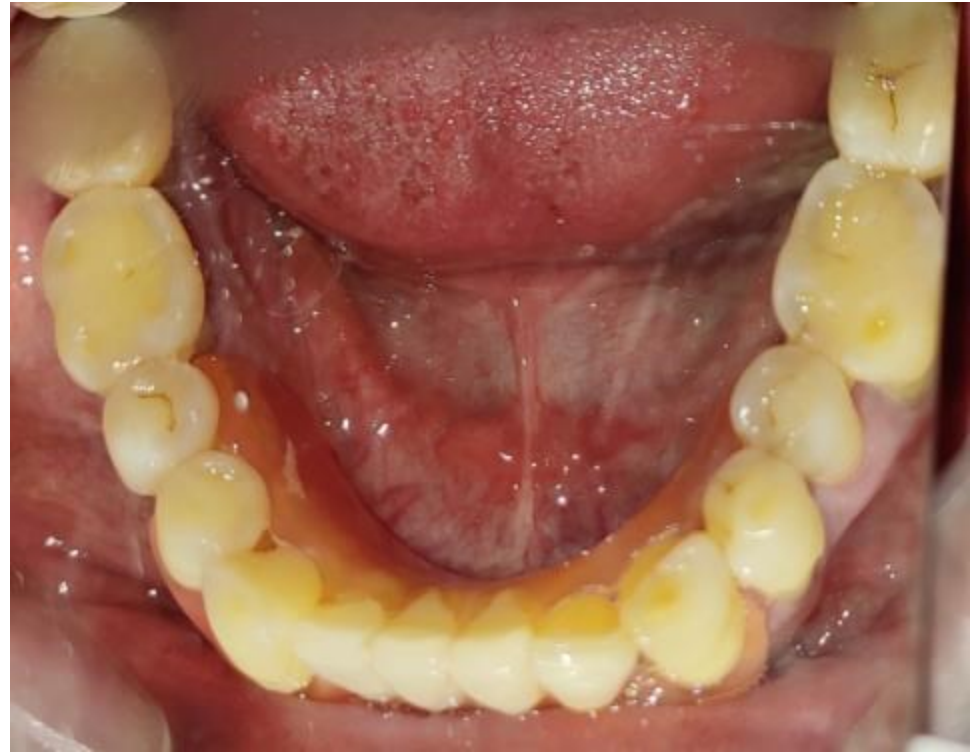
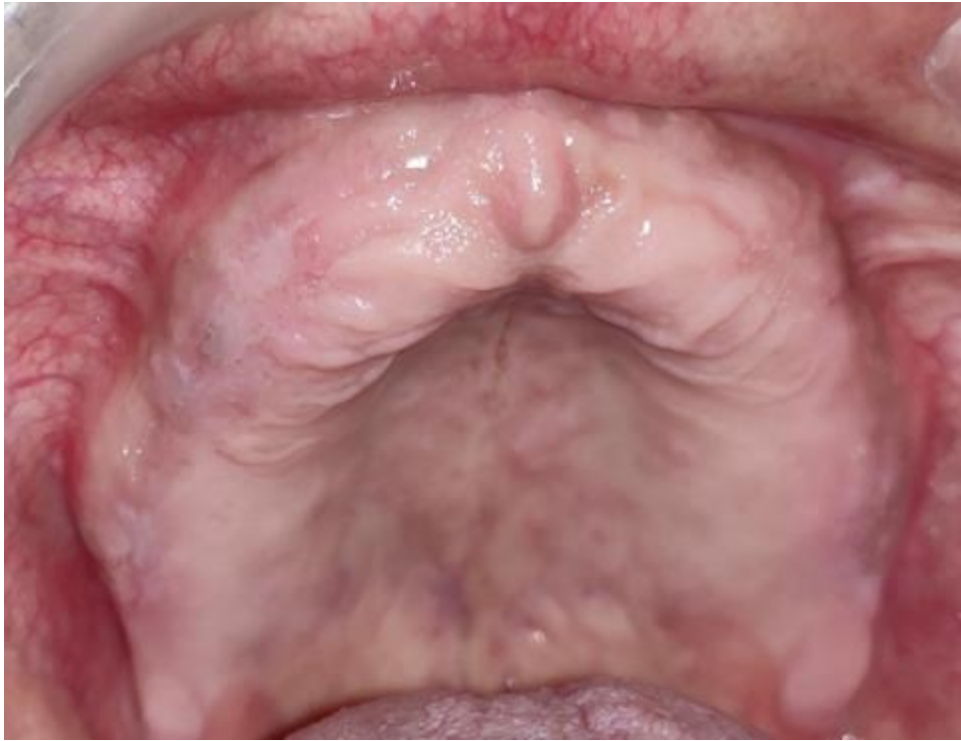POST OP

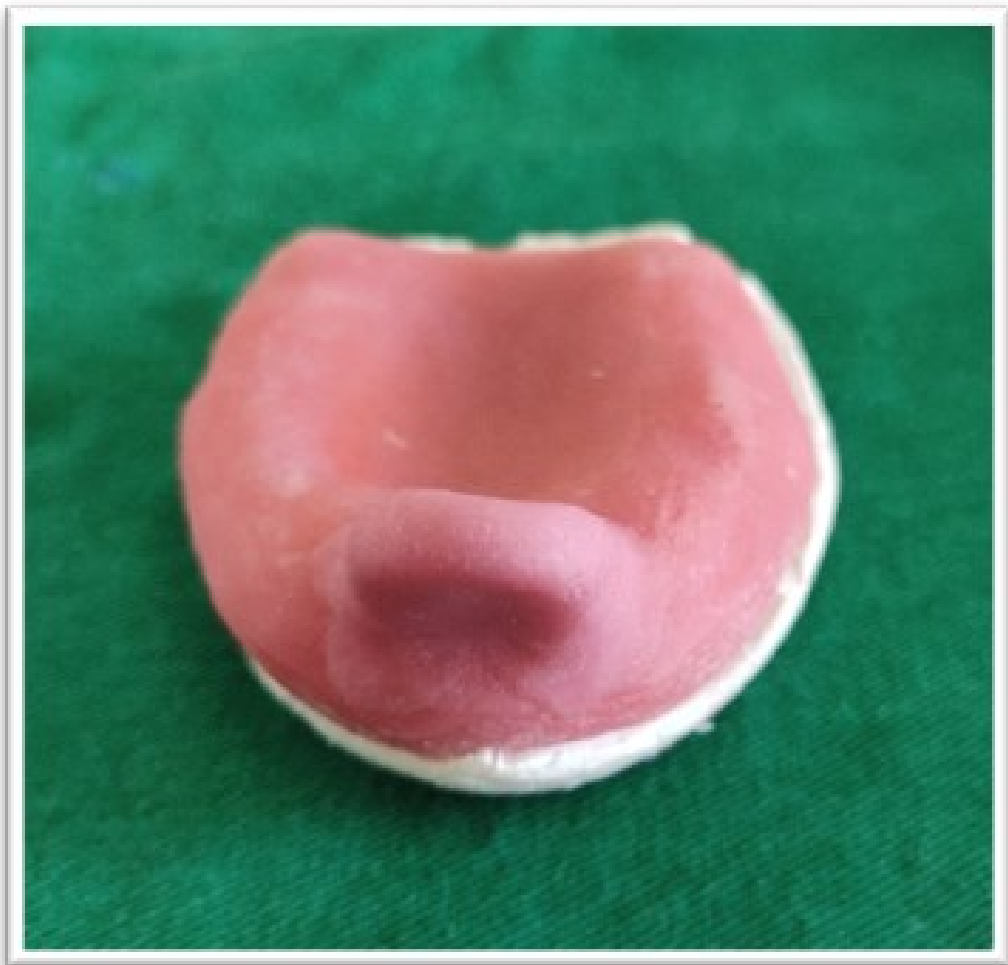

SINGLE METAL COMPLETE DENTURE

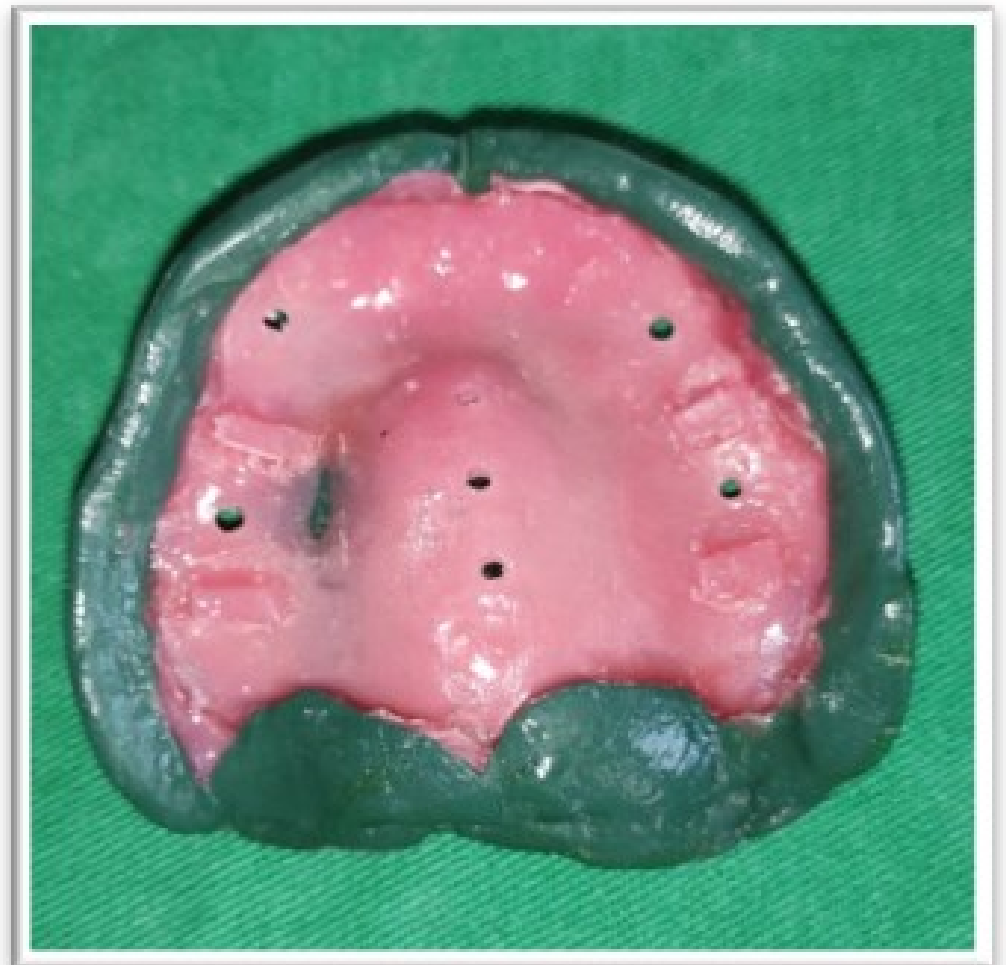PATIENT NAME: Mr. SANJEEVI
RMCT: 472312



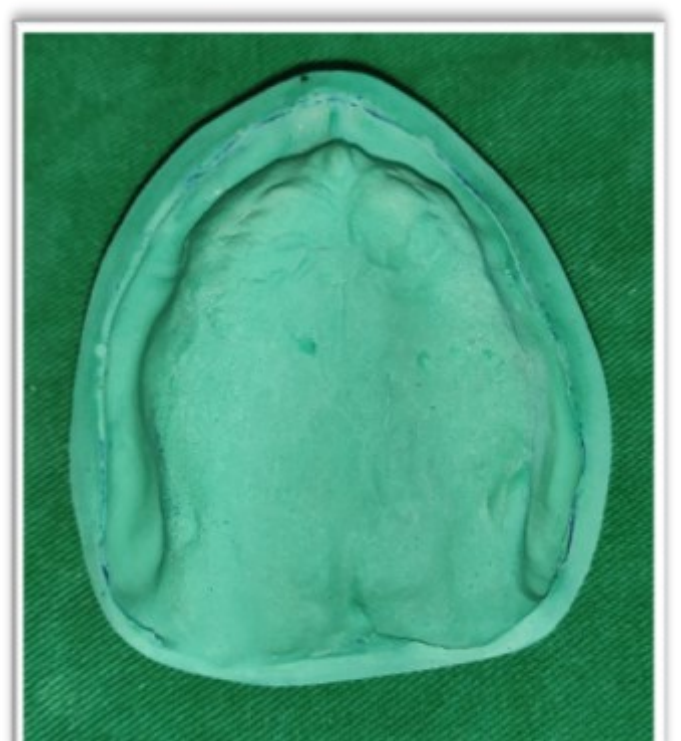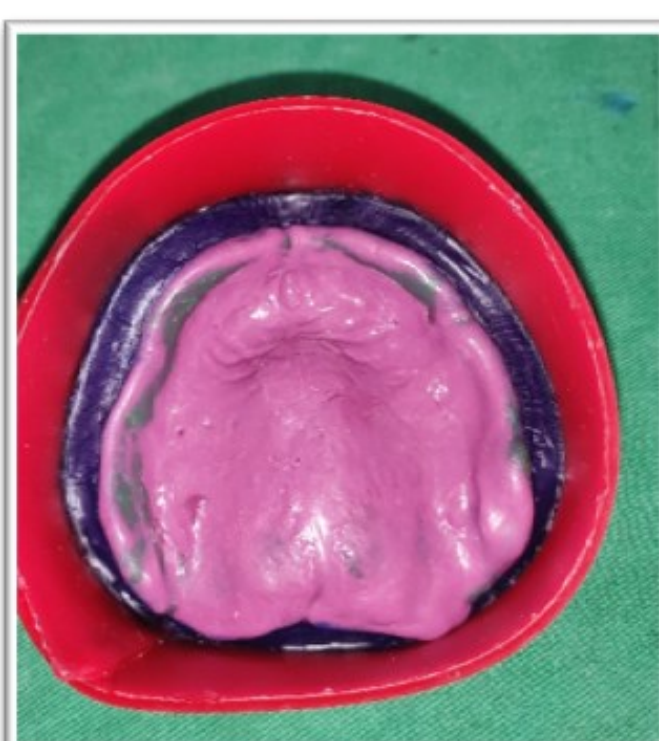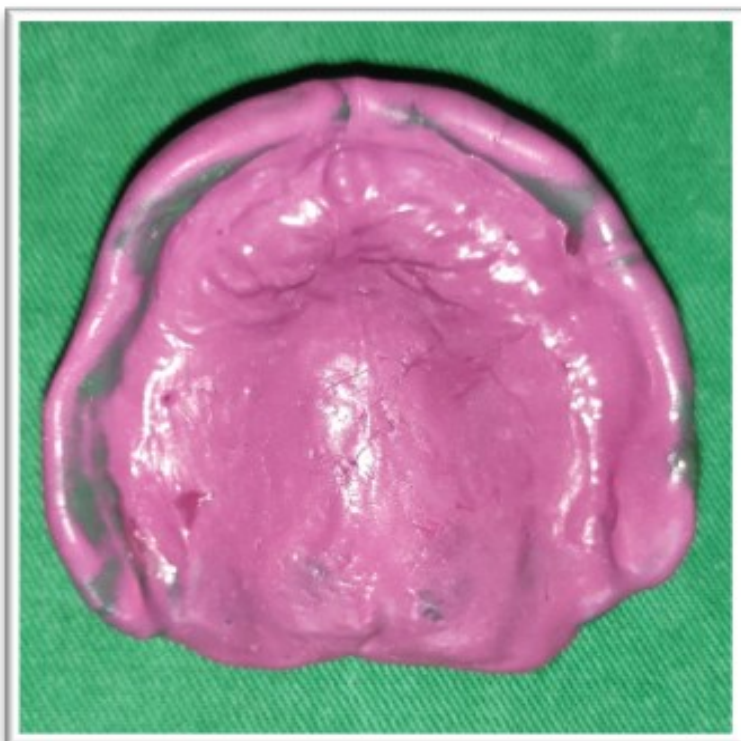
SPECIAL TRAY



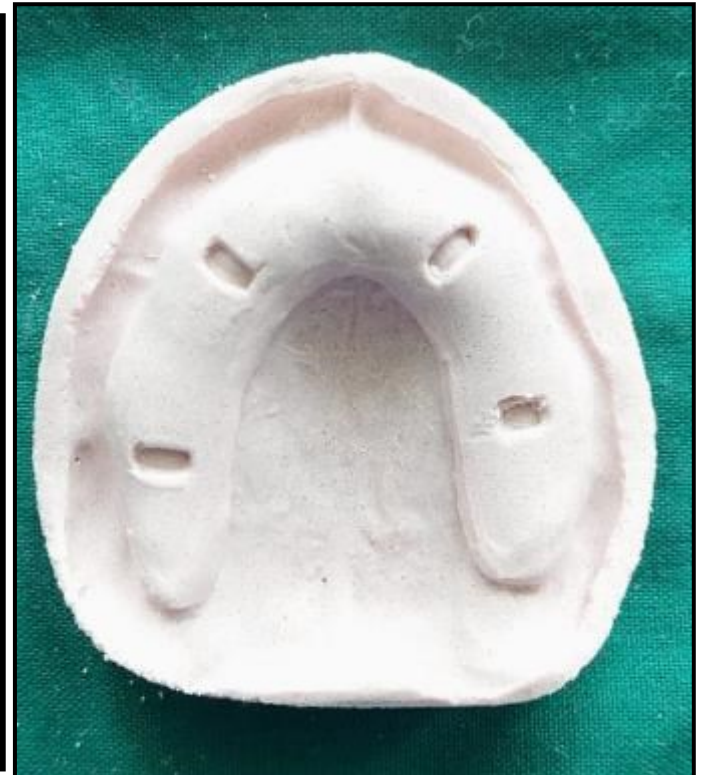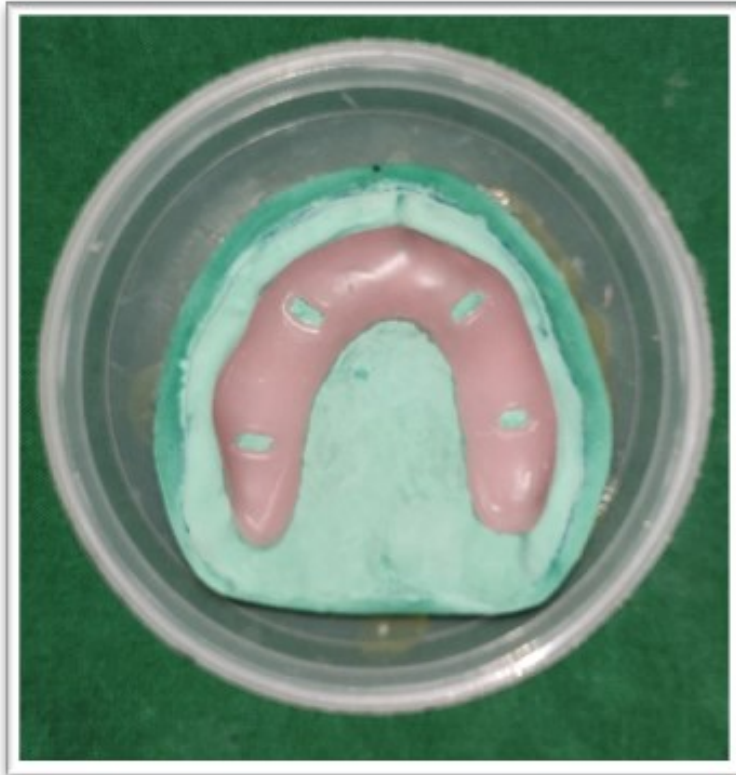BORDER MOULDING



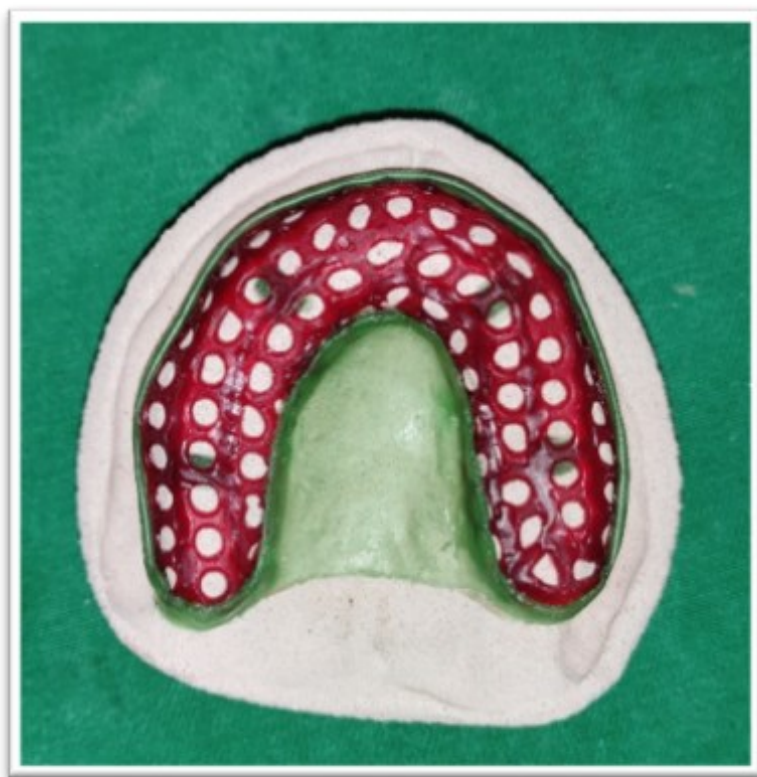
SECONDARY IMPRESSION AND MASTER CAST



DUPLICATION



WAX PATTERN

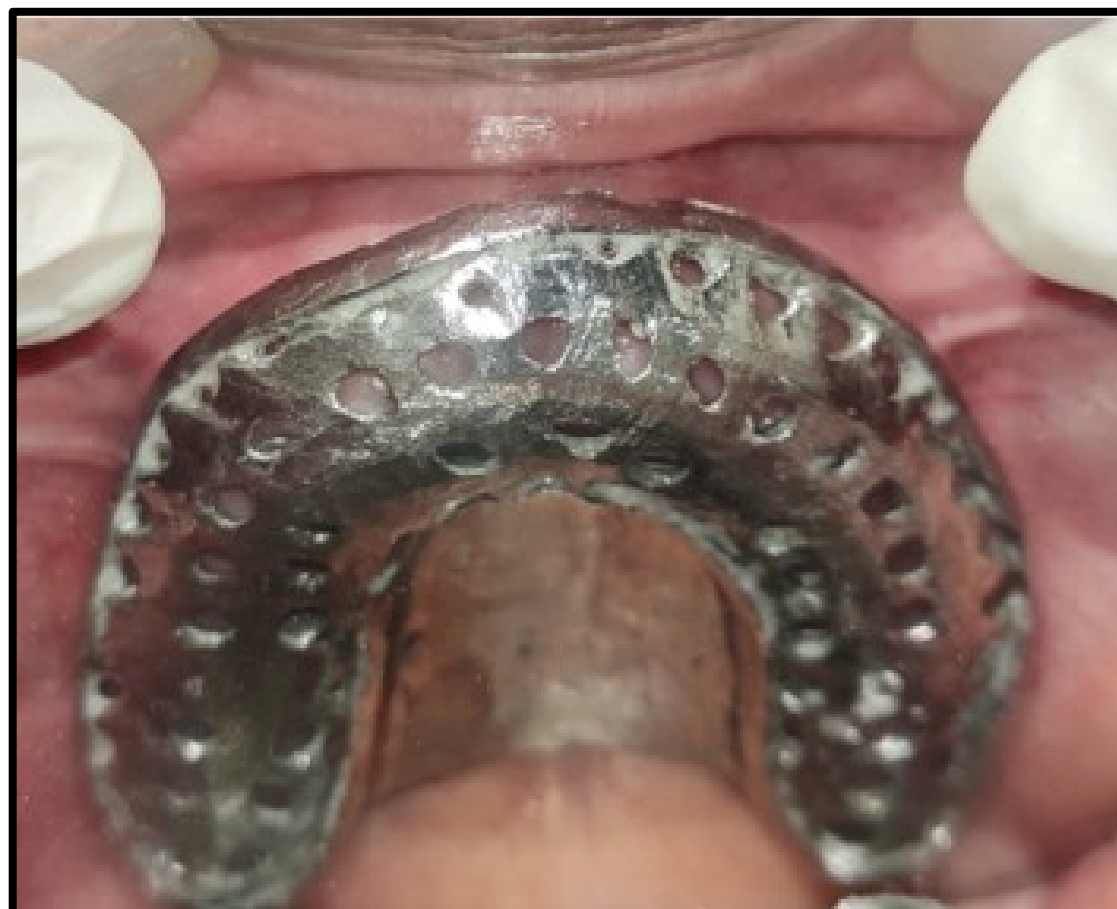
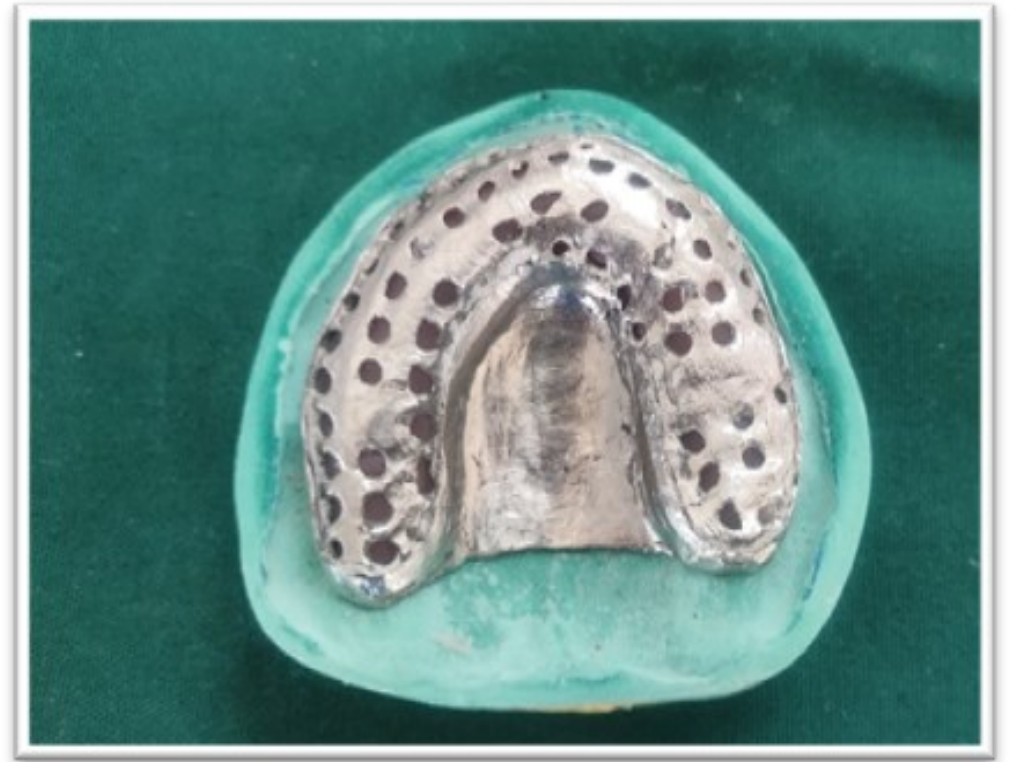
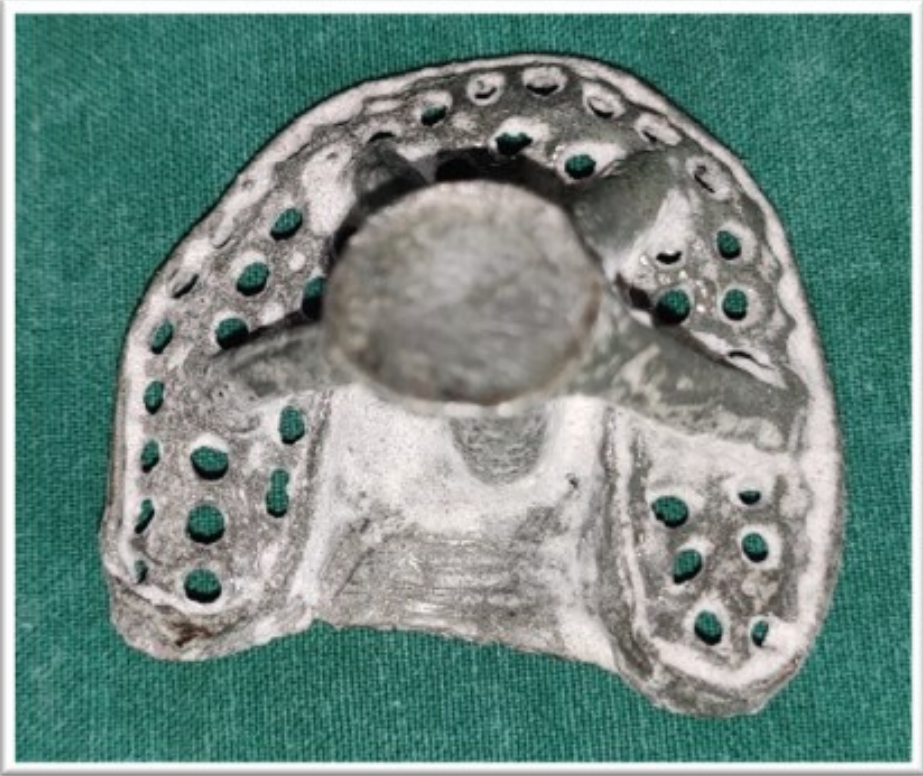INVESTMENT

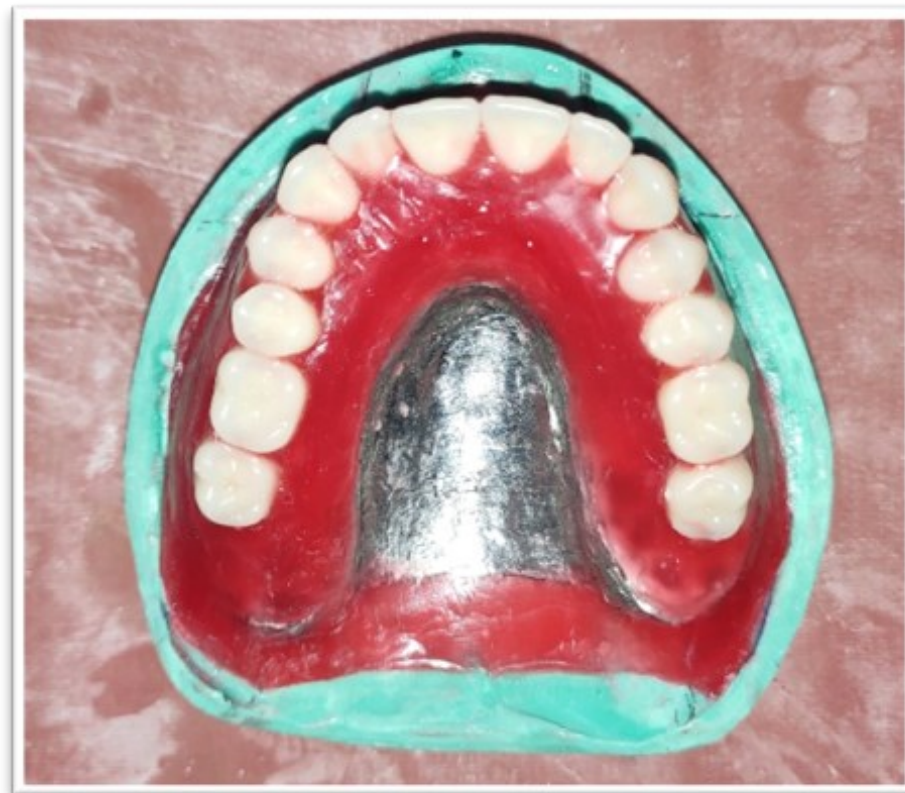
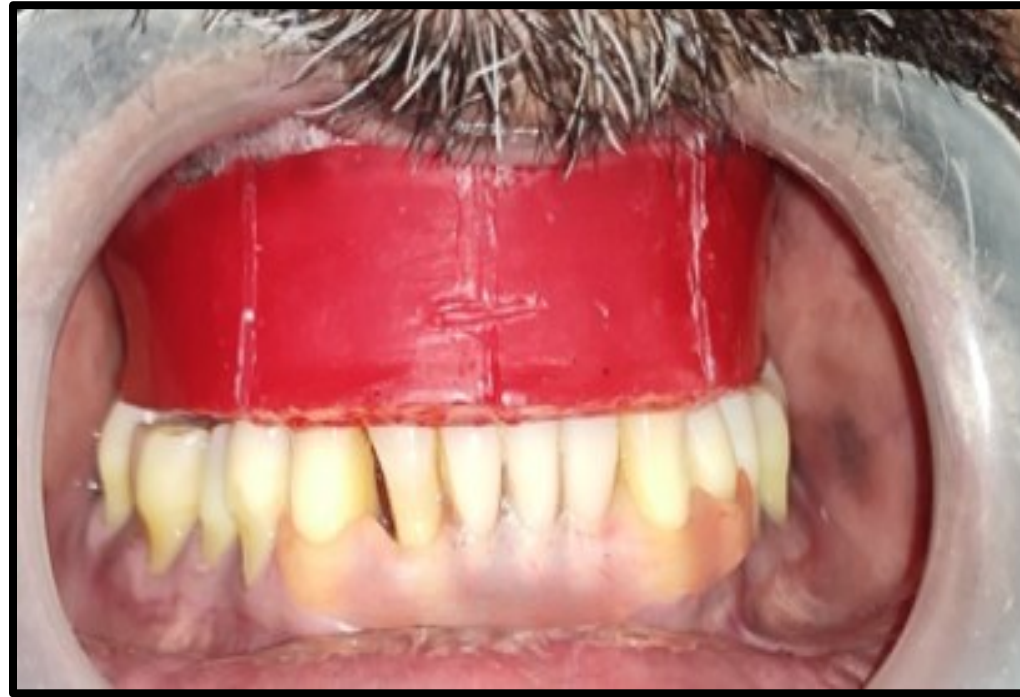
BURN OUT

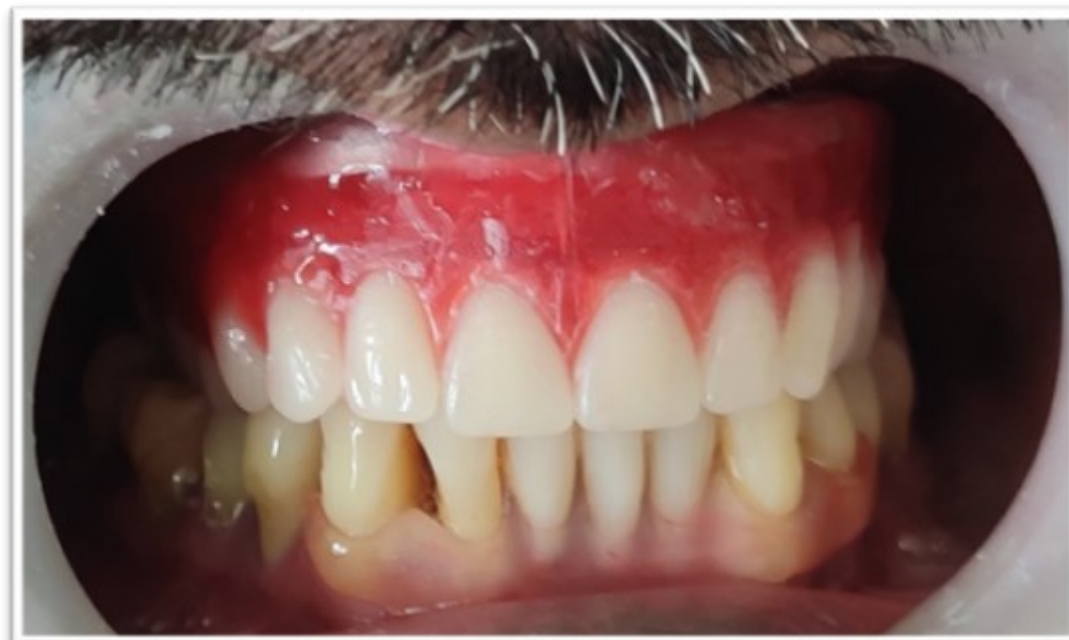


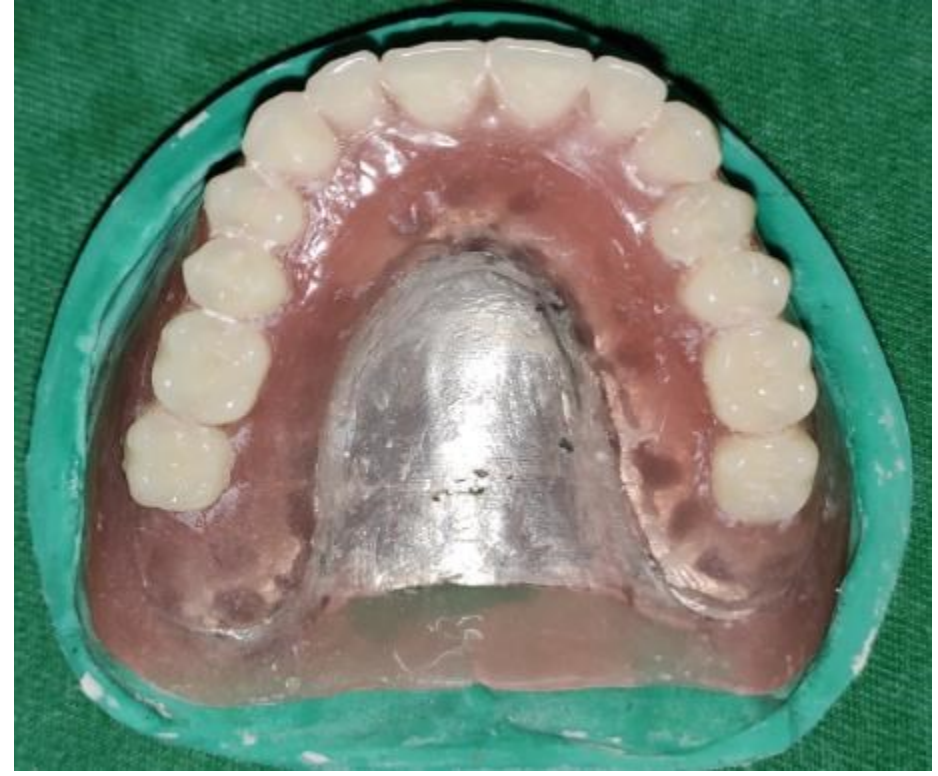
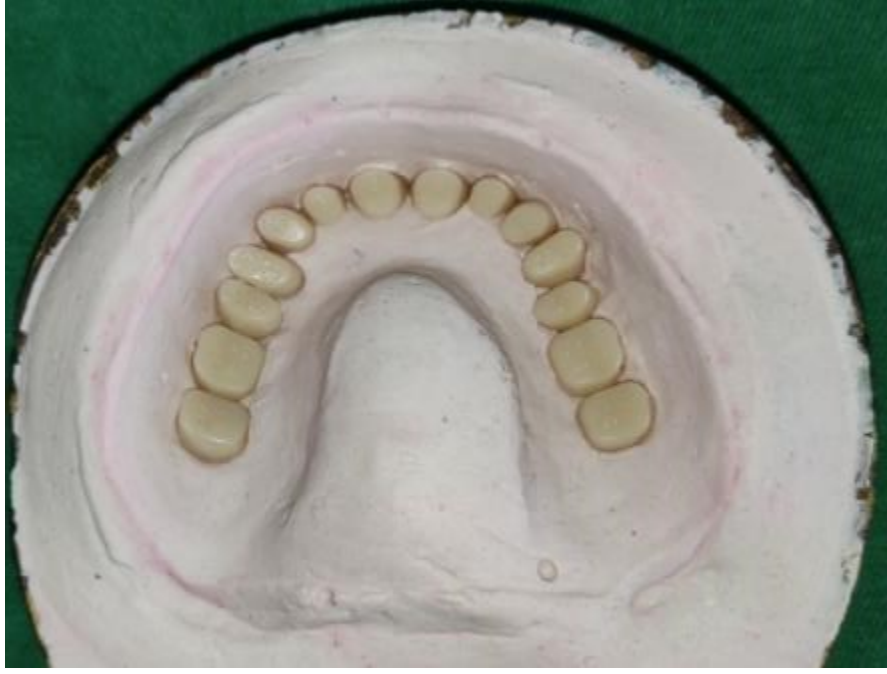BITE REGISTRATION

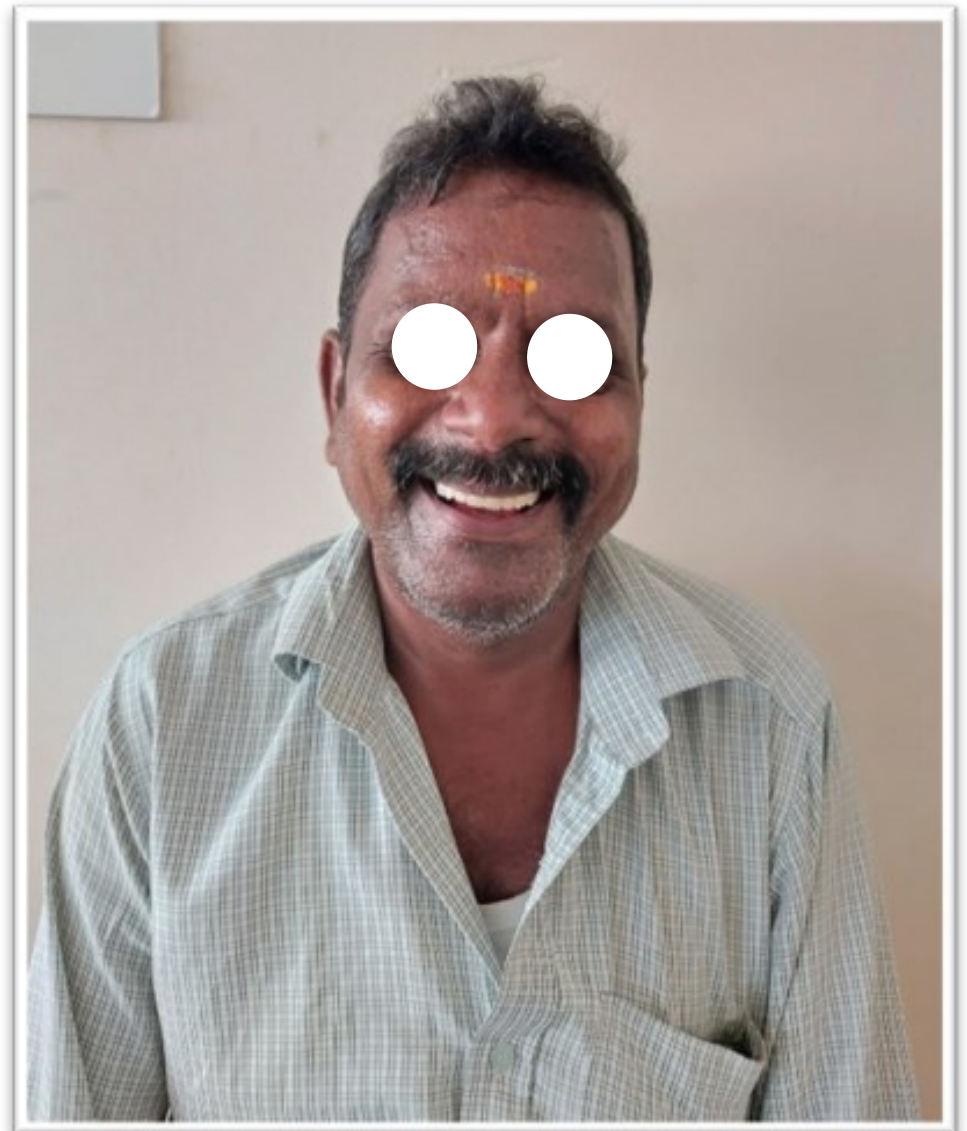
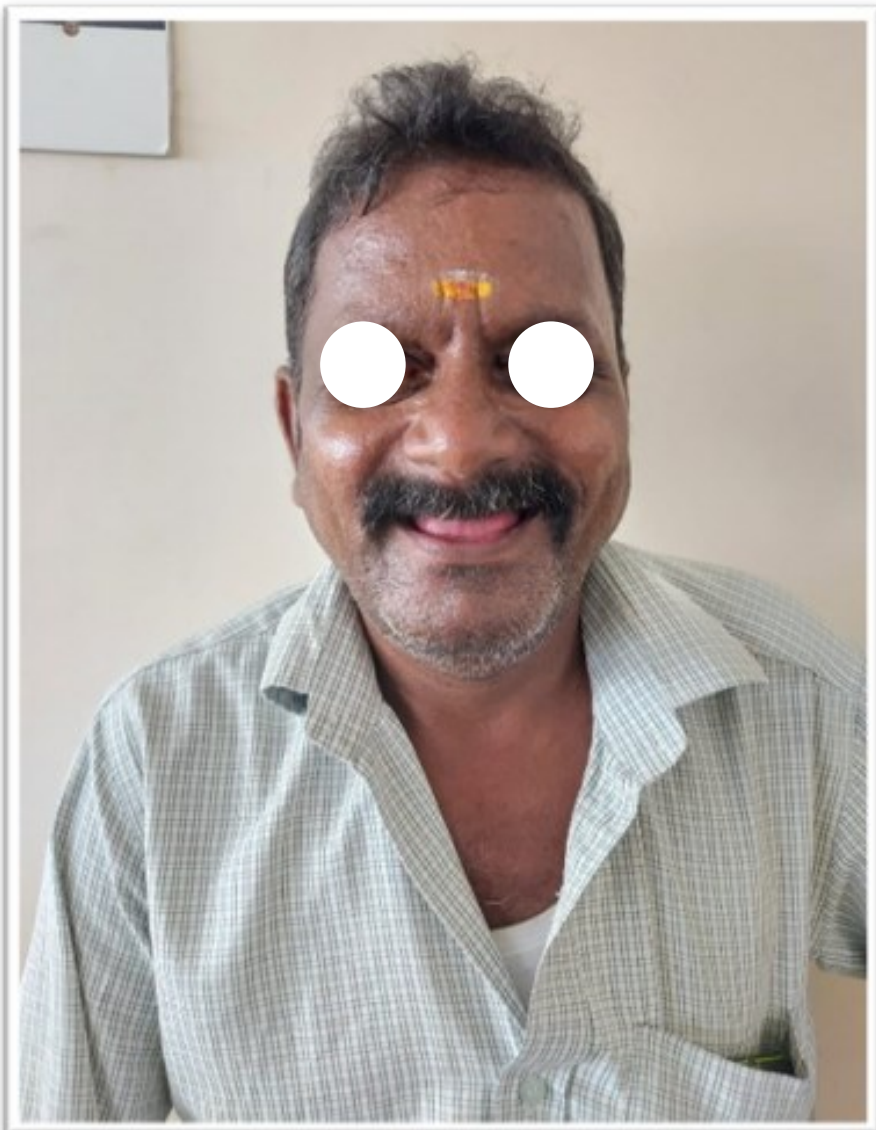
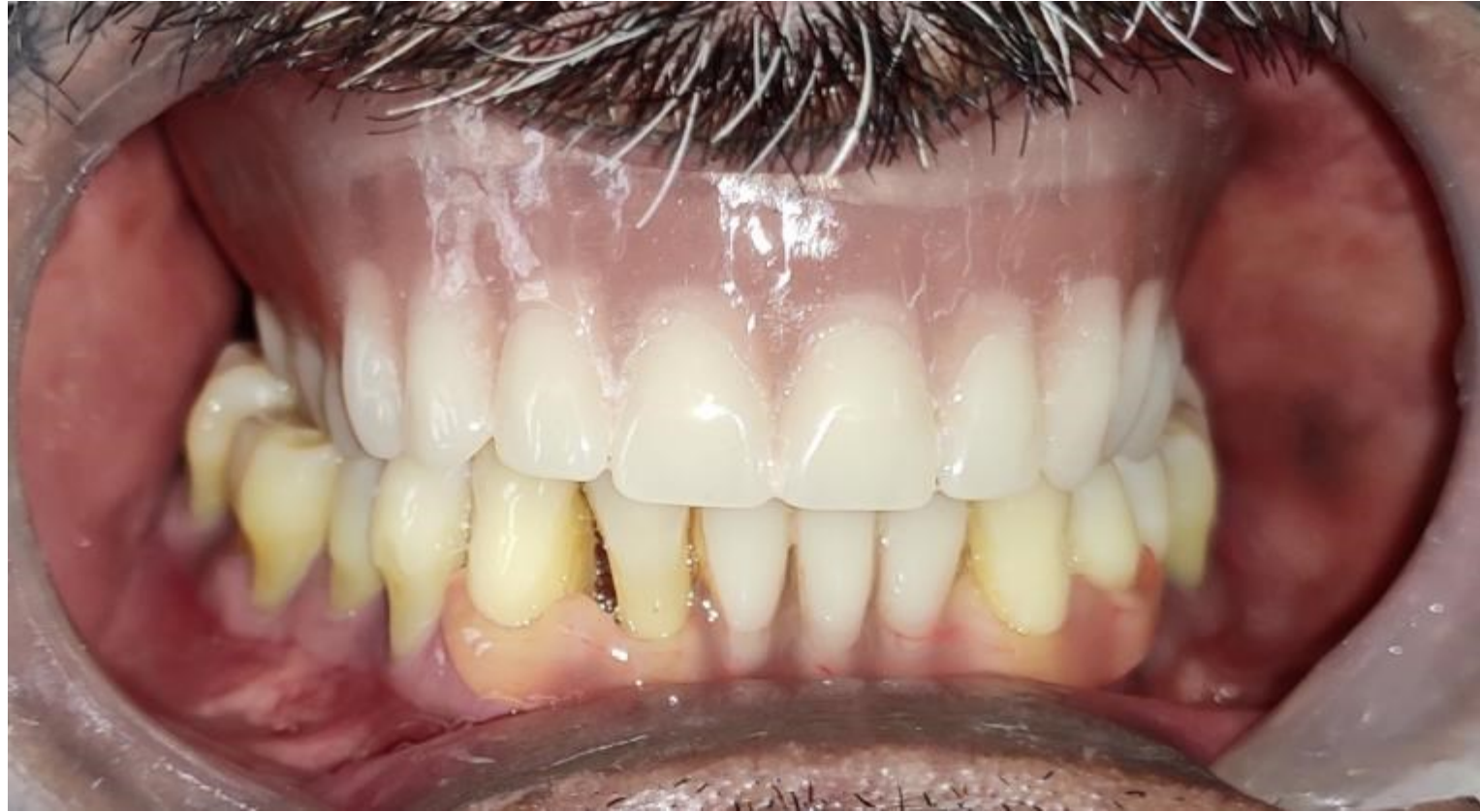WAX TRIAL





FINAL DENTURE

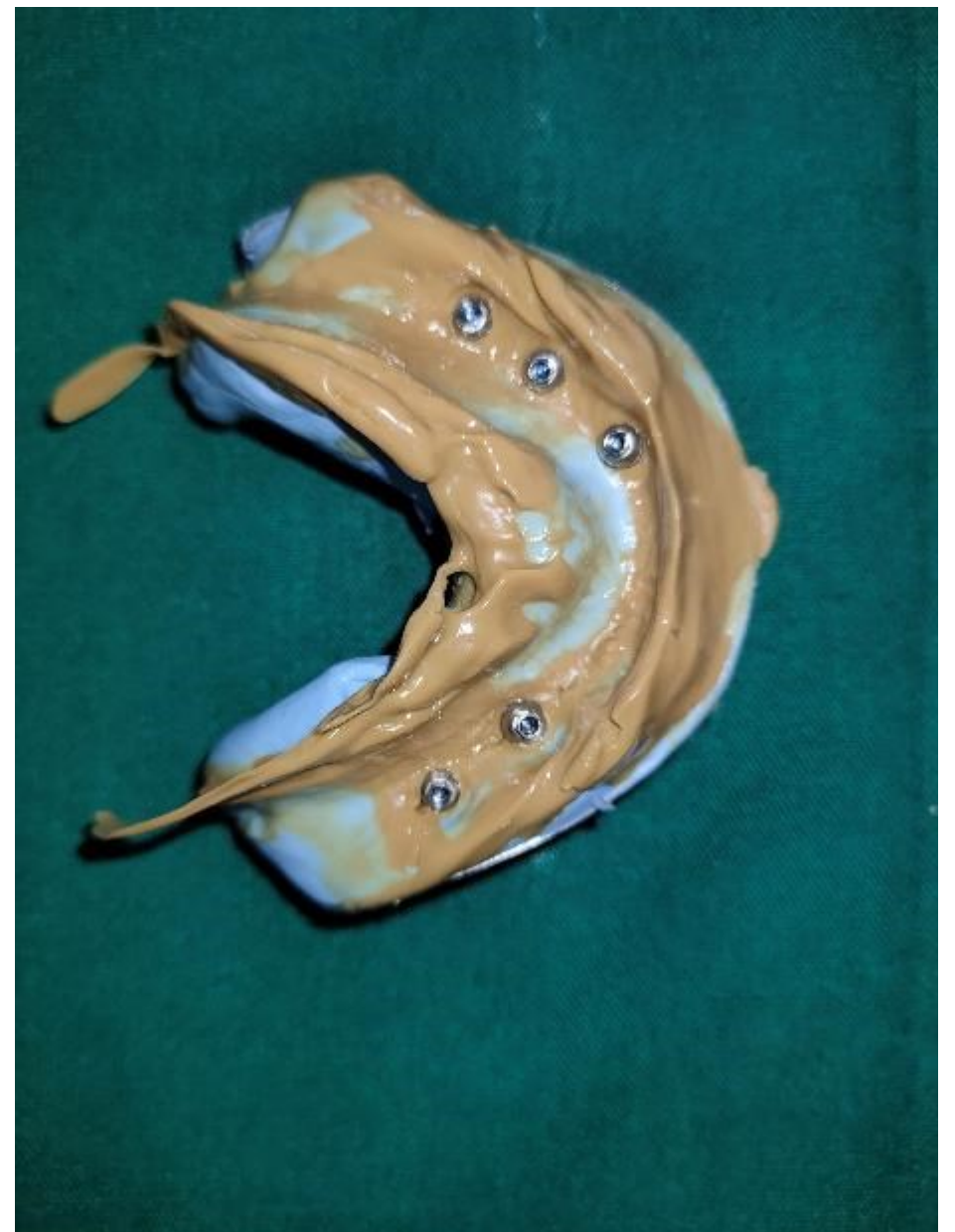
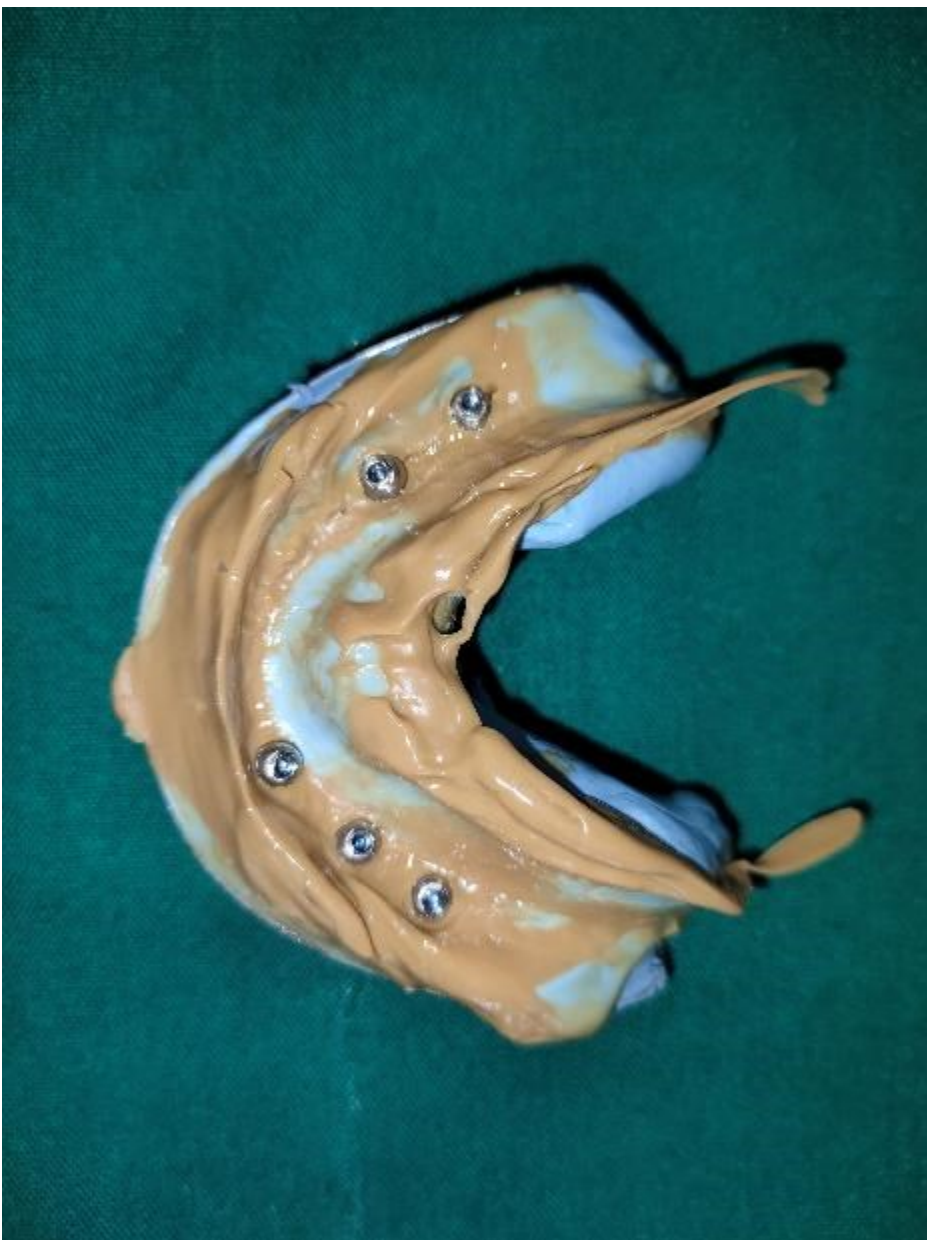
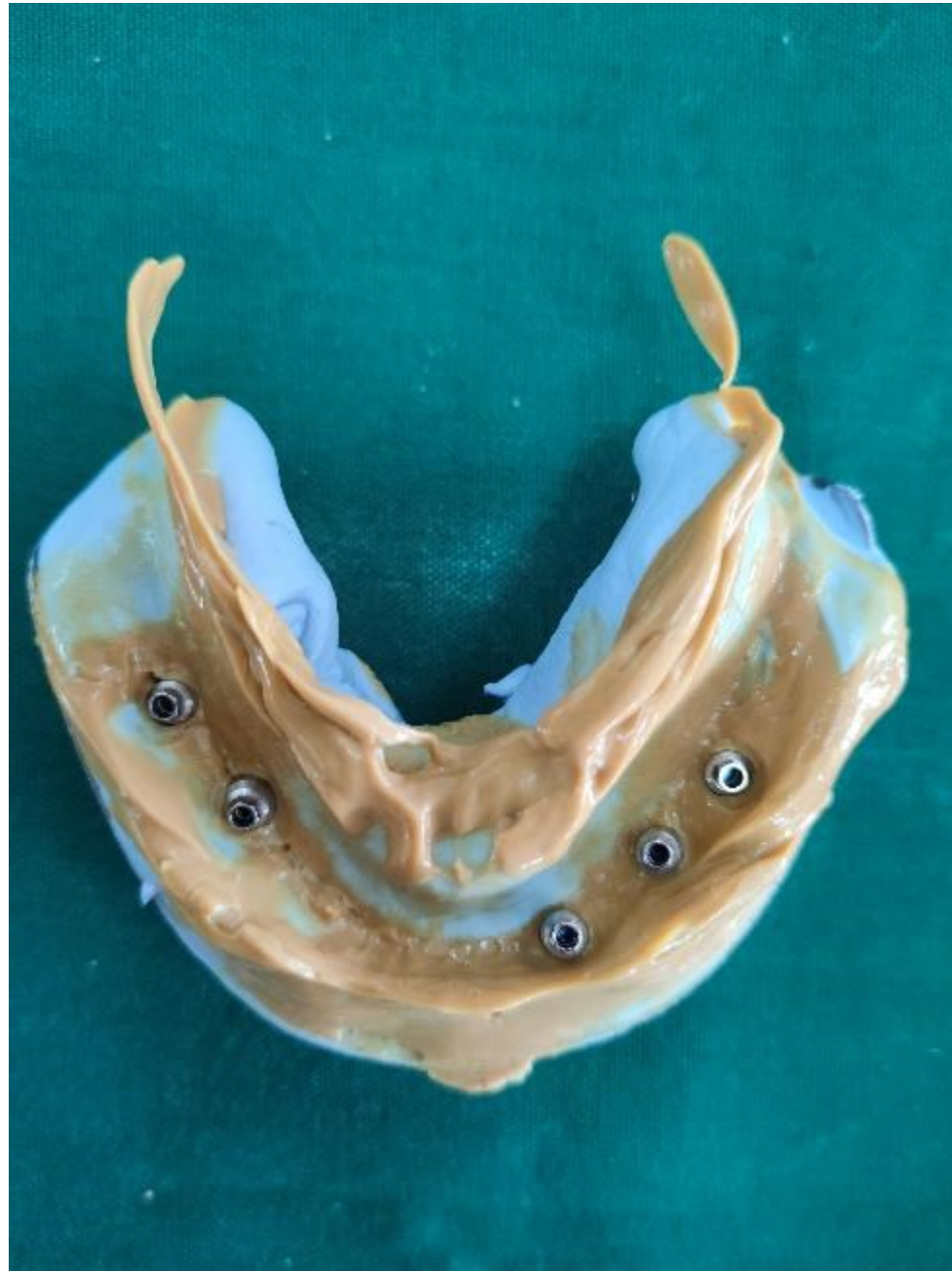HYBRID DENTURE

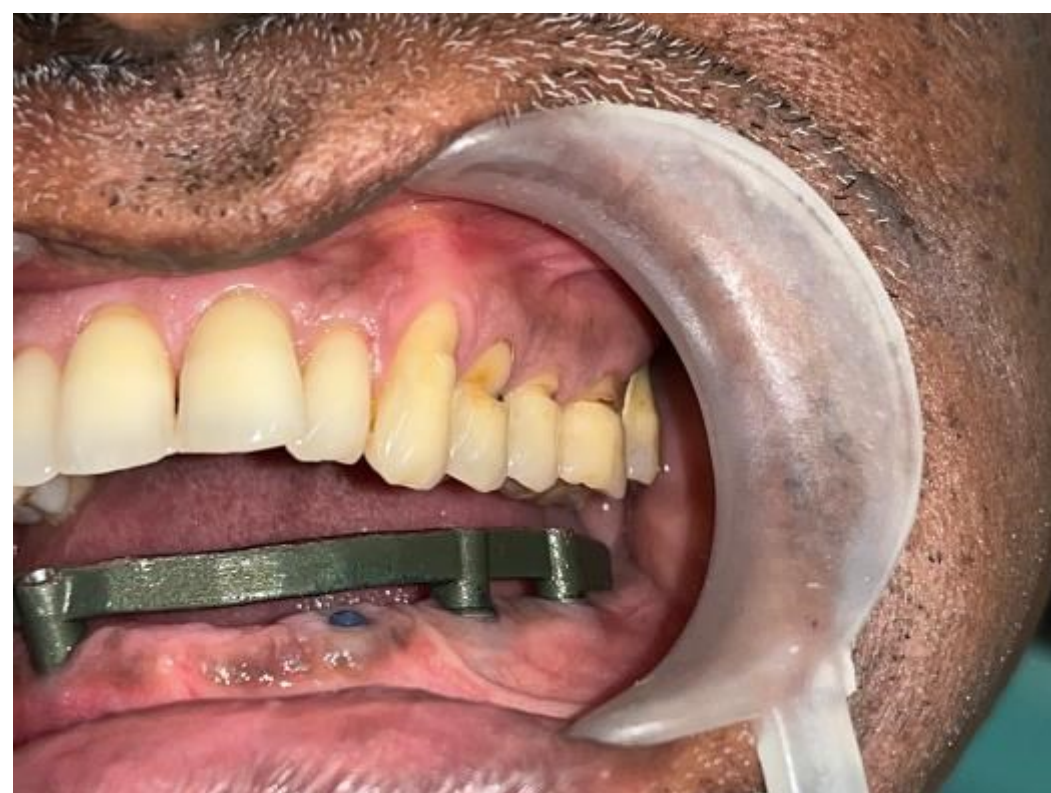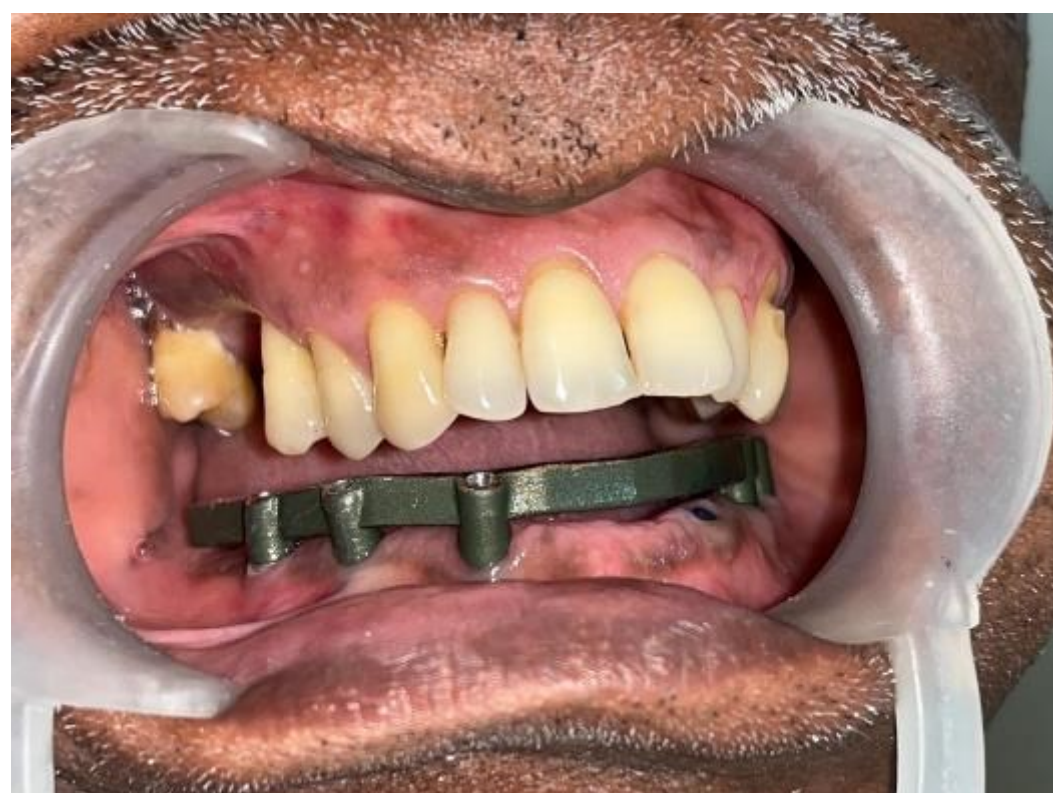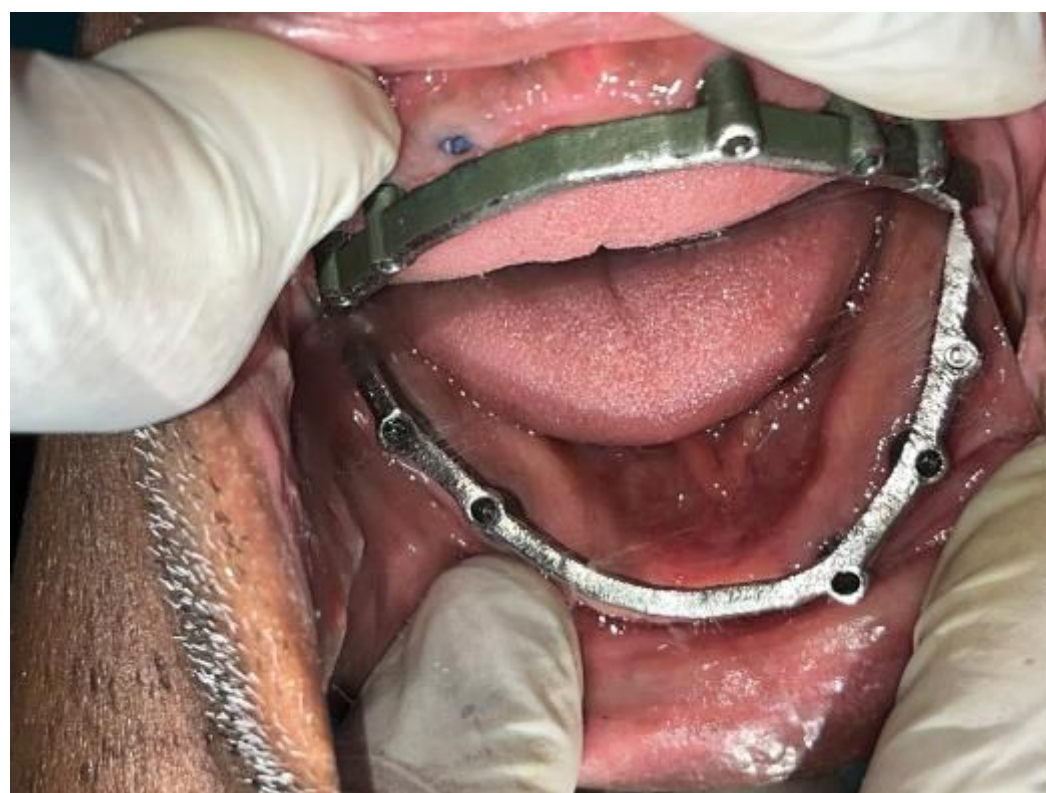PATIENT NAME: Mr. DEVARAJAN

RMCT: 294852

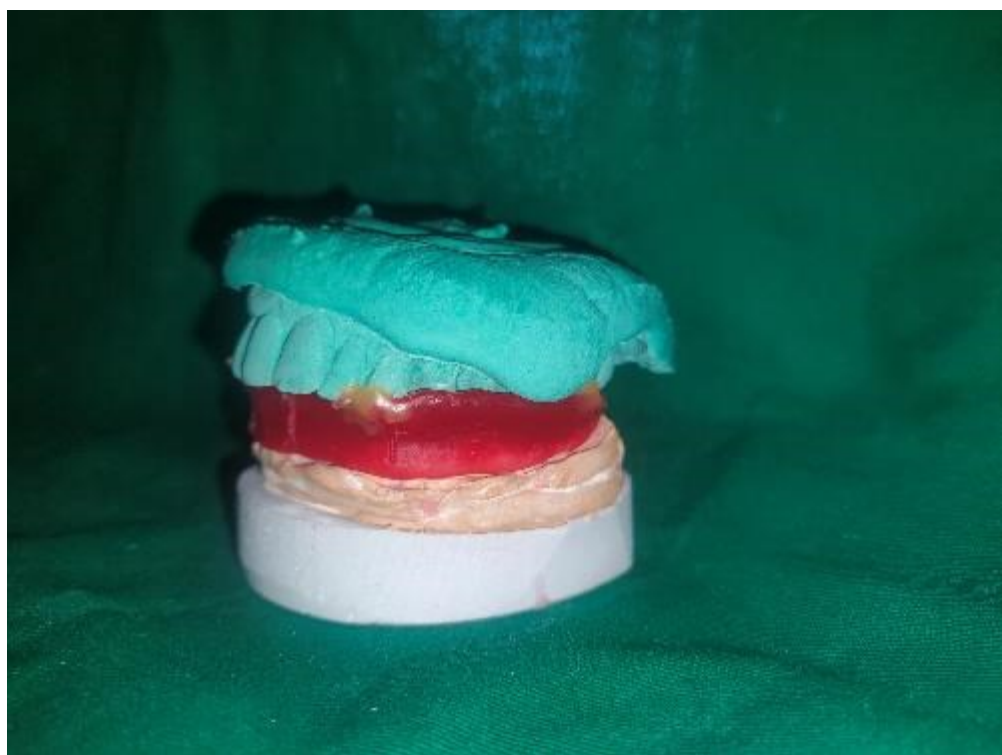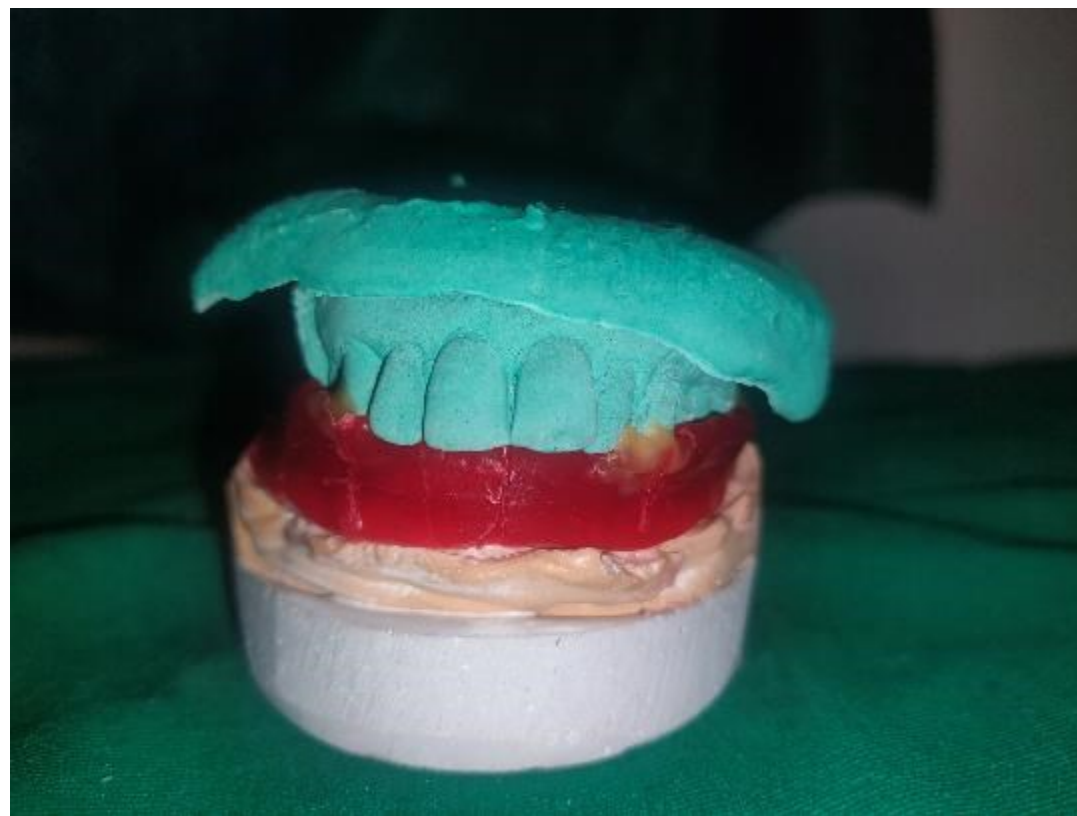IMPLANT LEVEL IMPRESSION



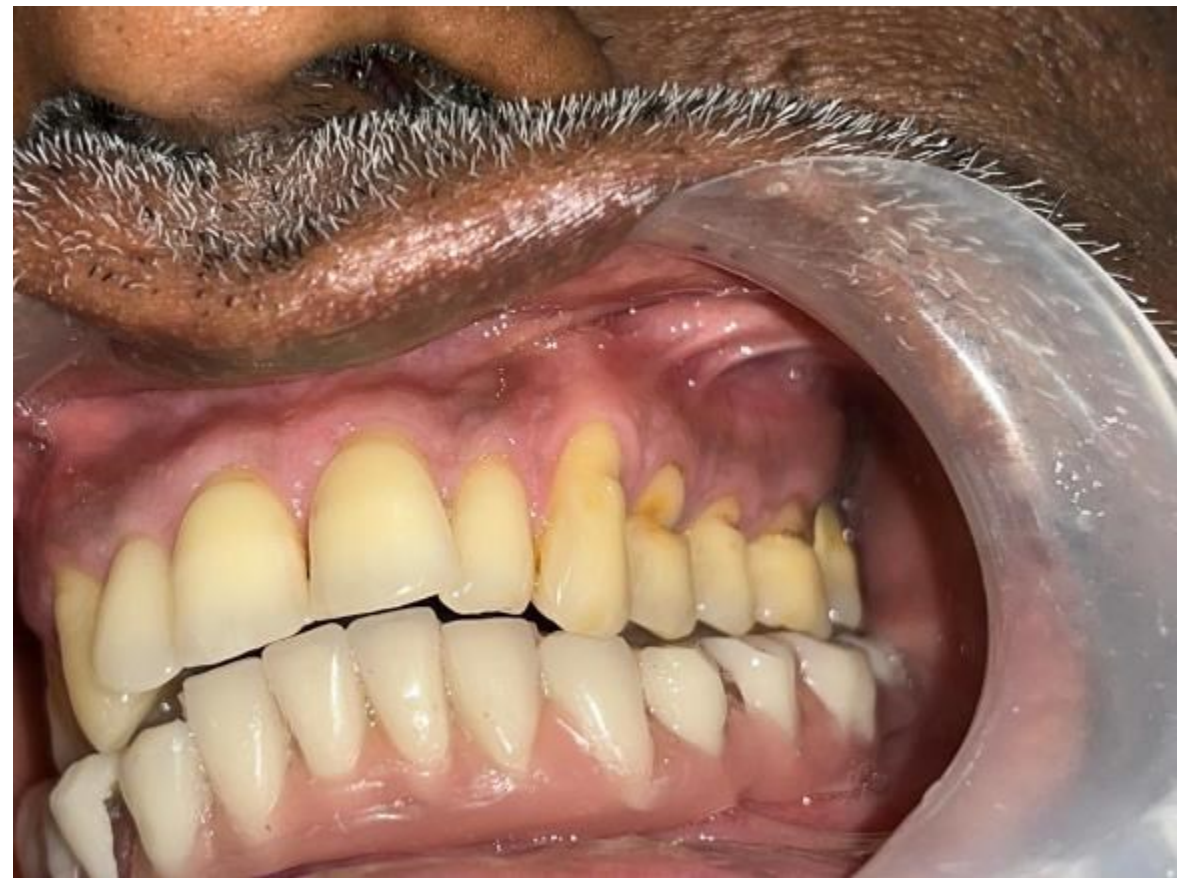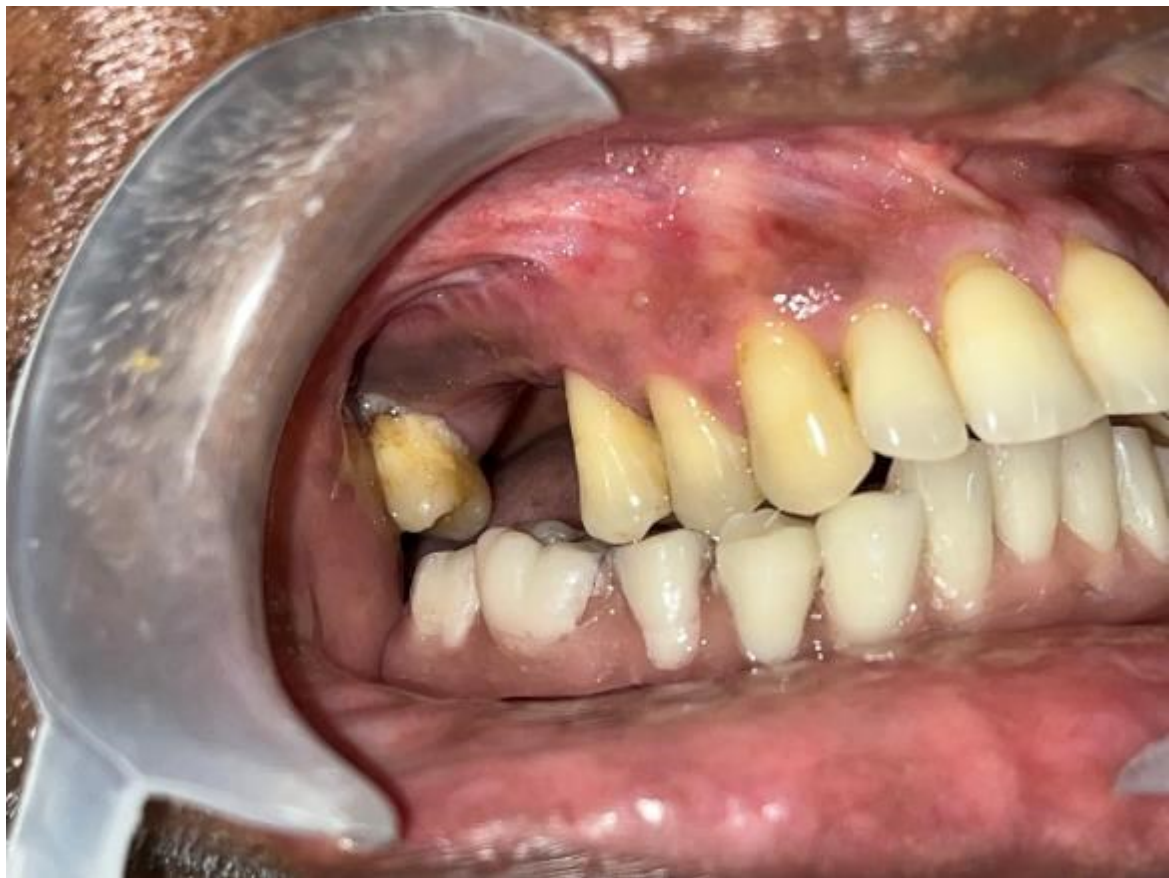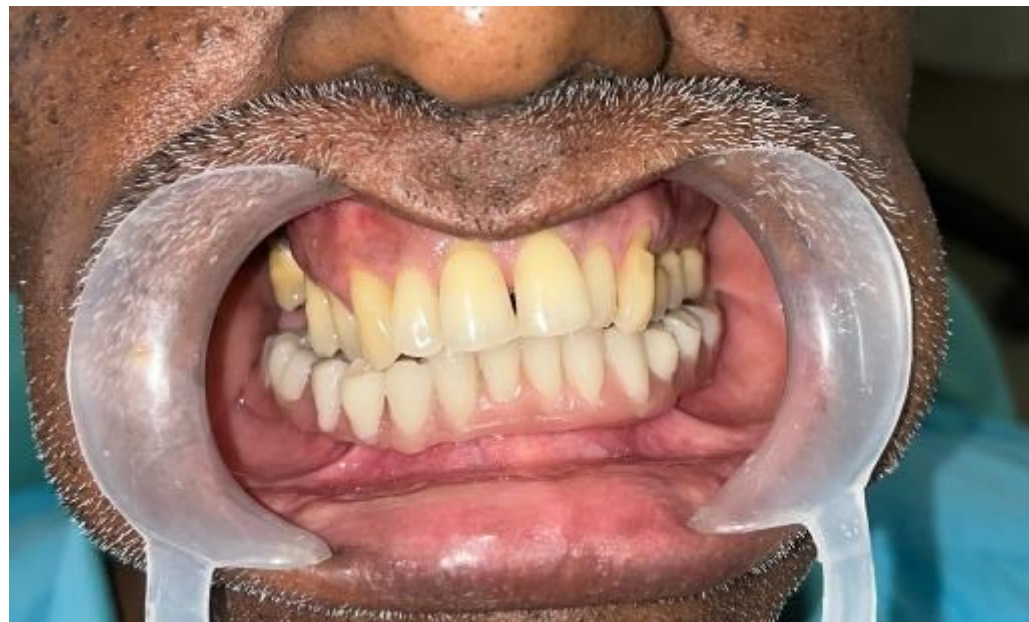METAL FRAME WORK TRIAL



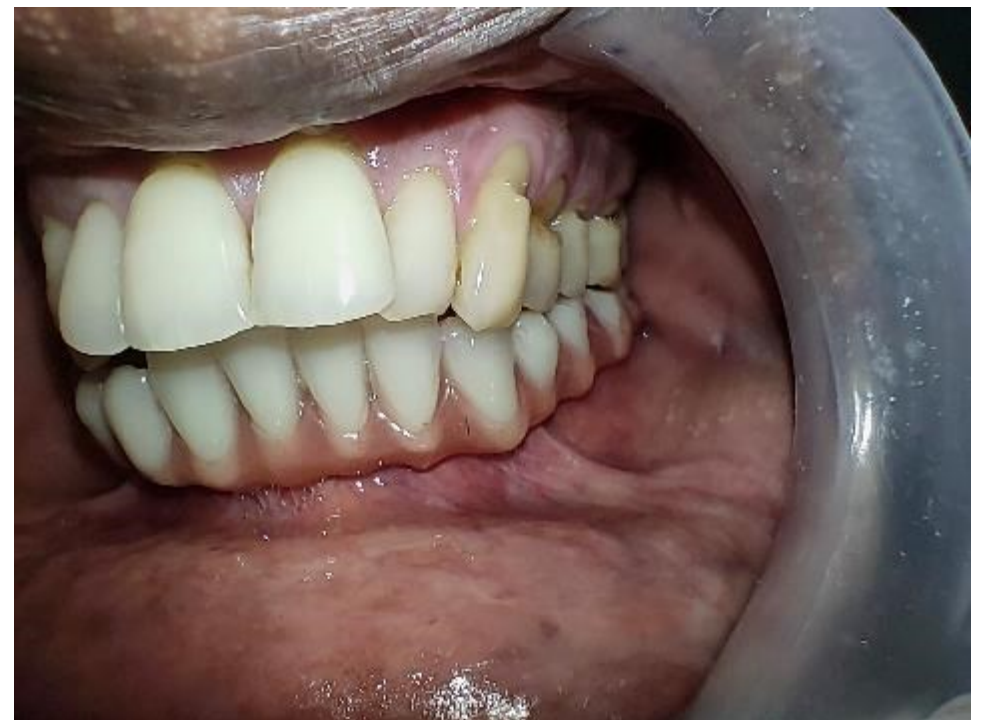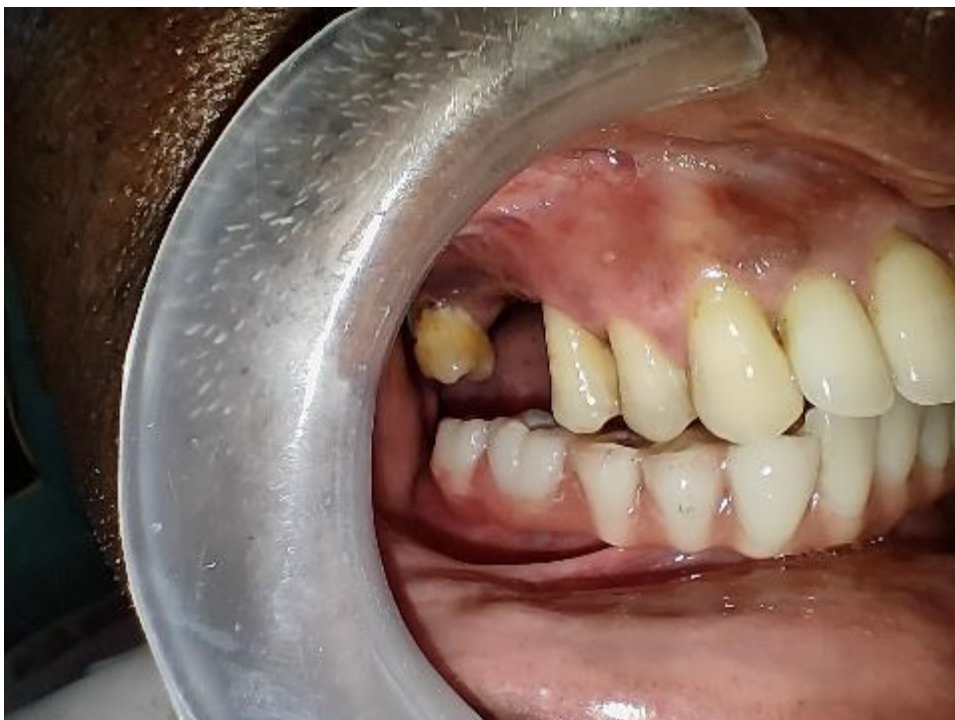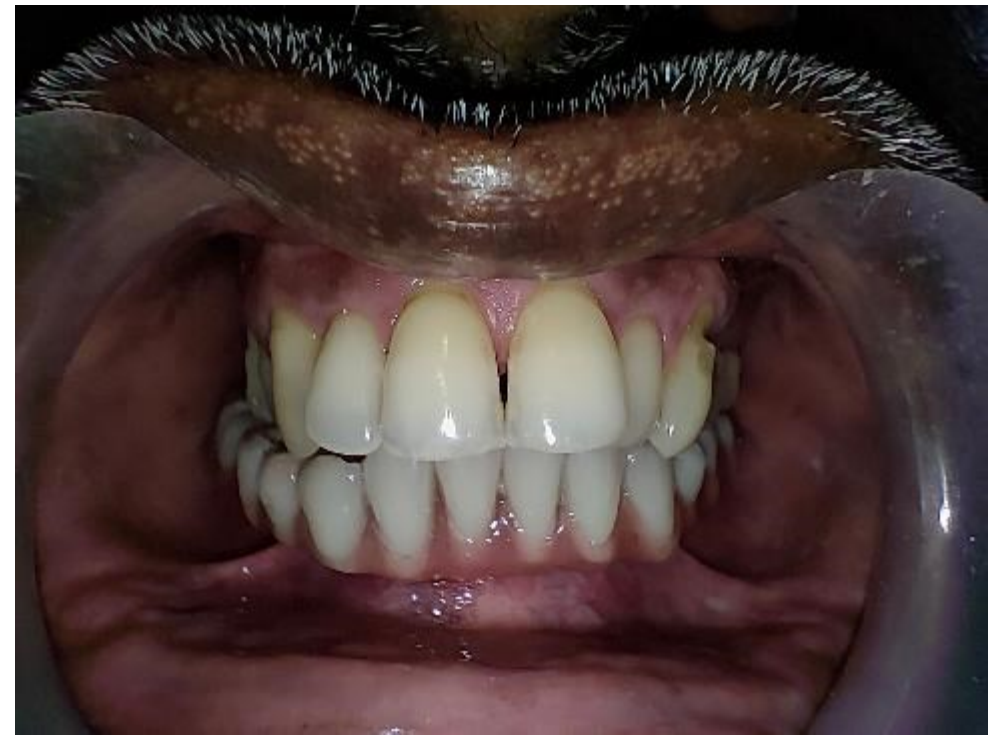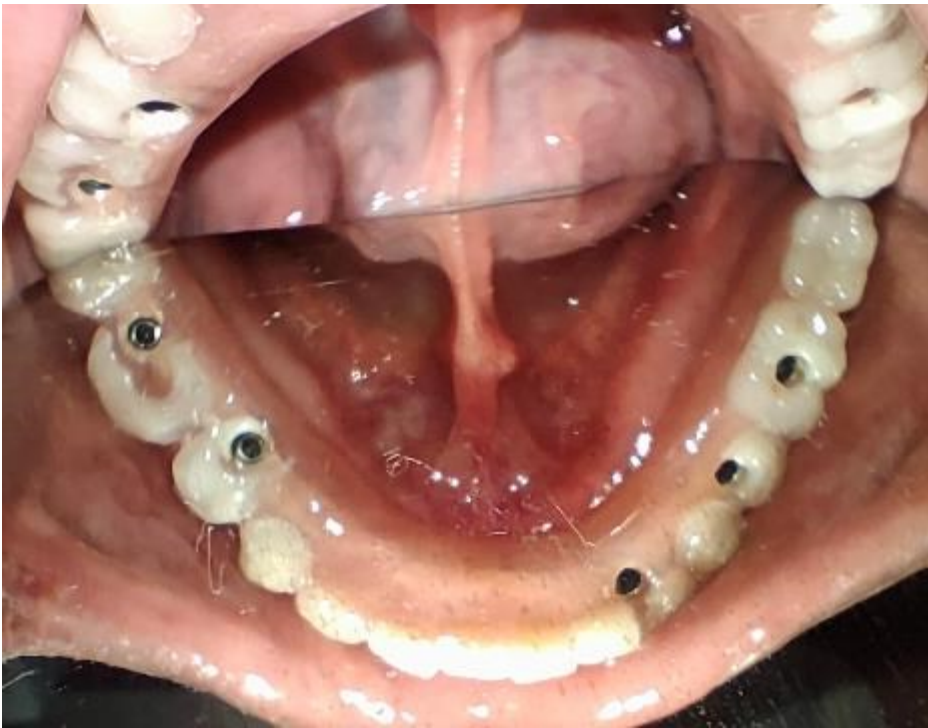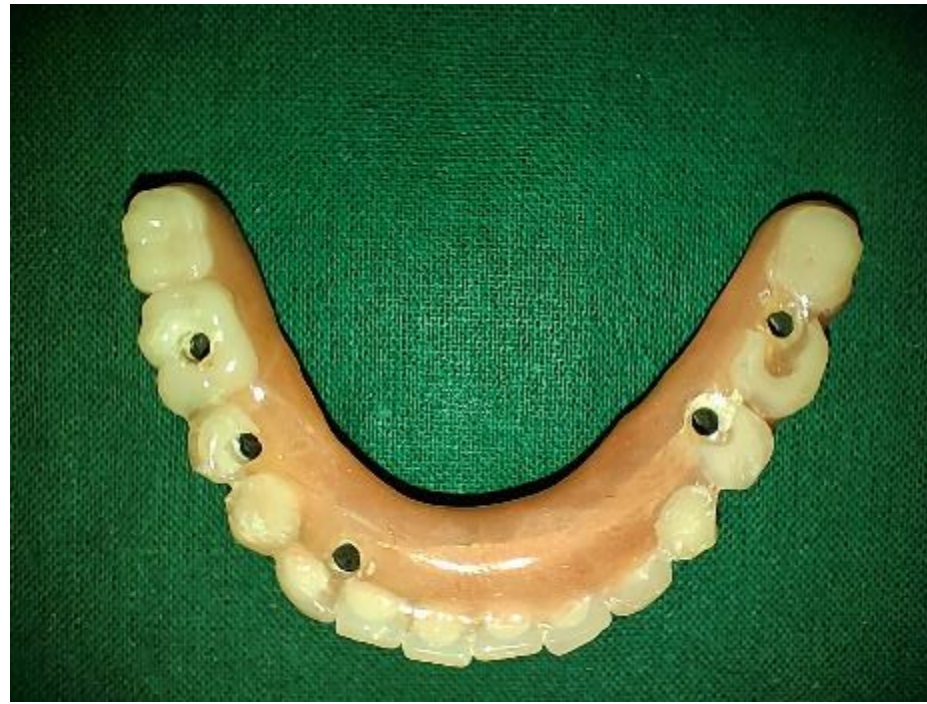JAW RELATION



WAX TRIAL



INSERTION

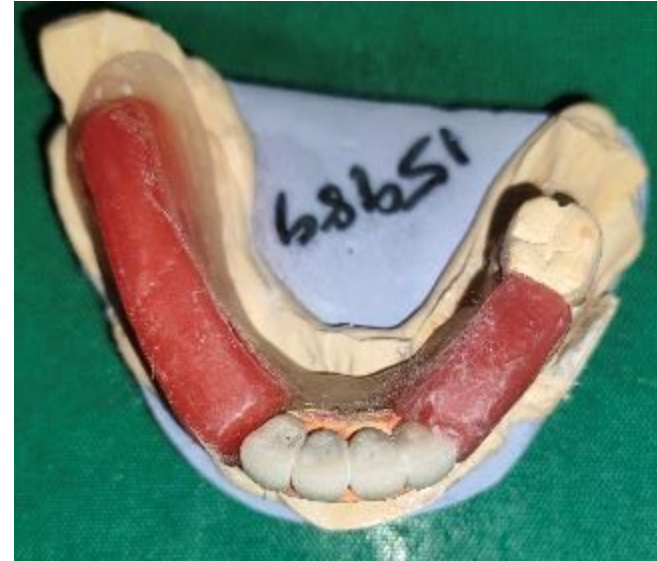

PRECISION ATTACHMENT WITH CAST PARTIAL DENTURE

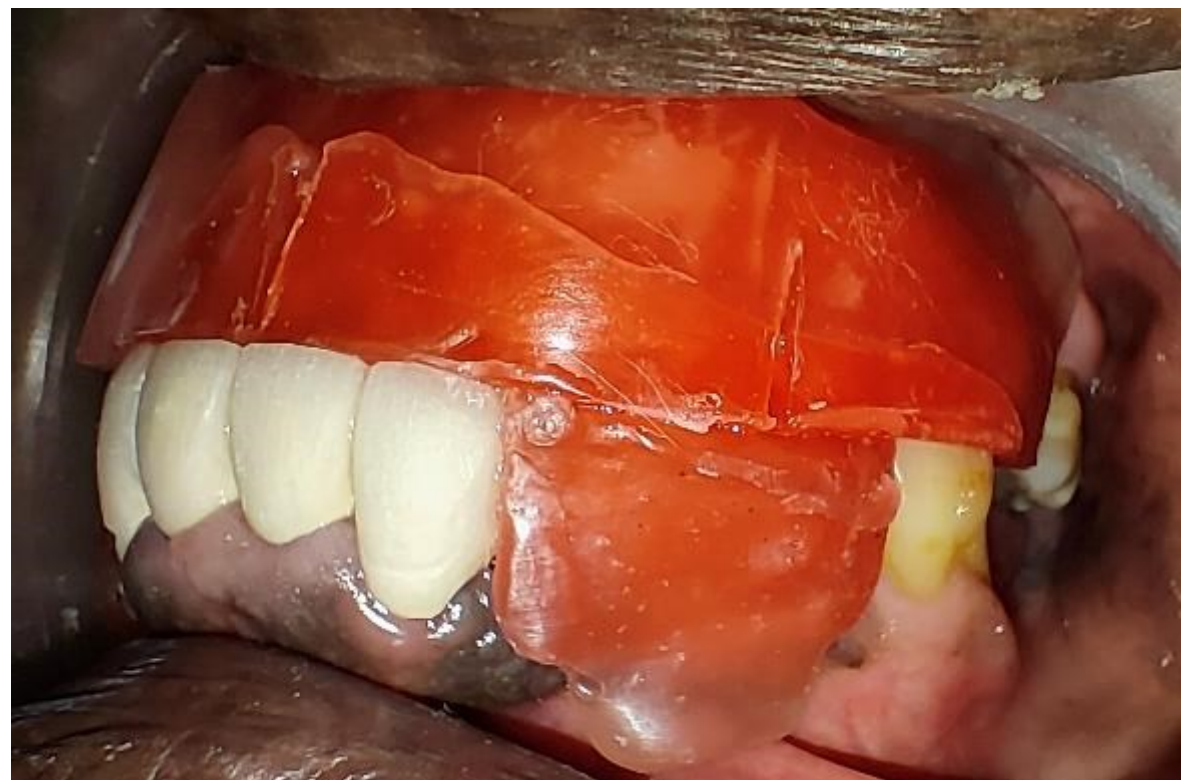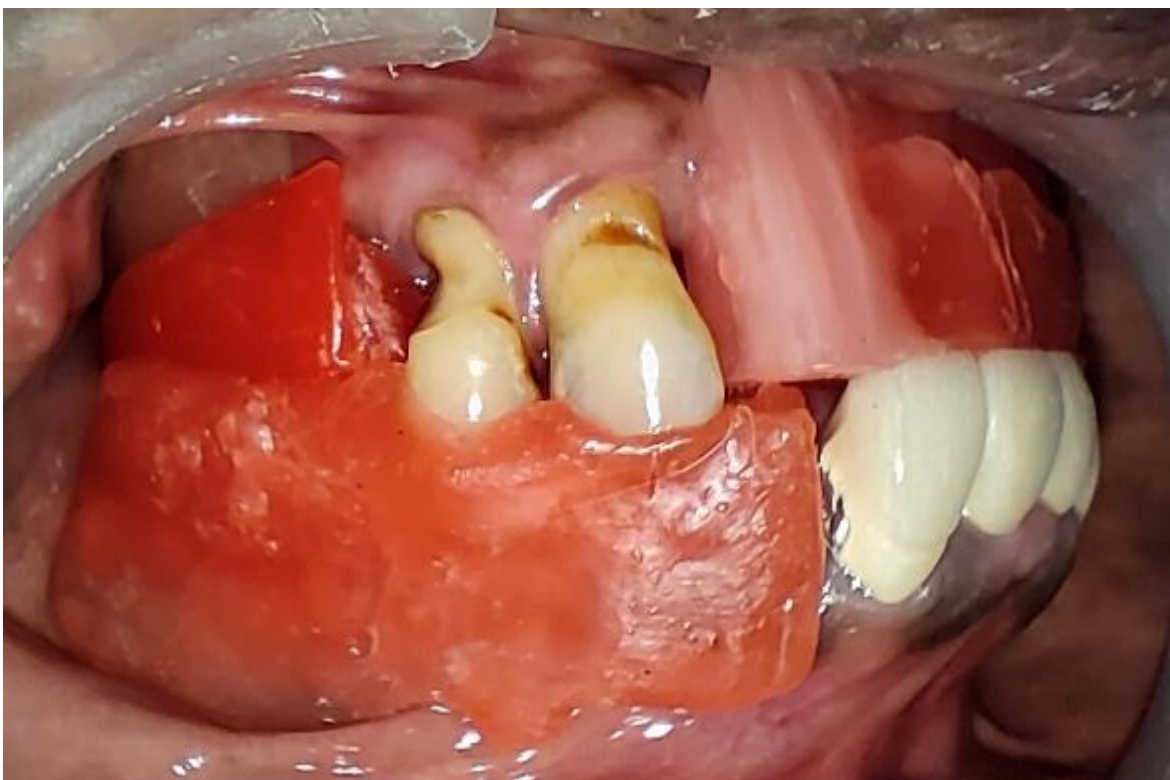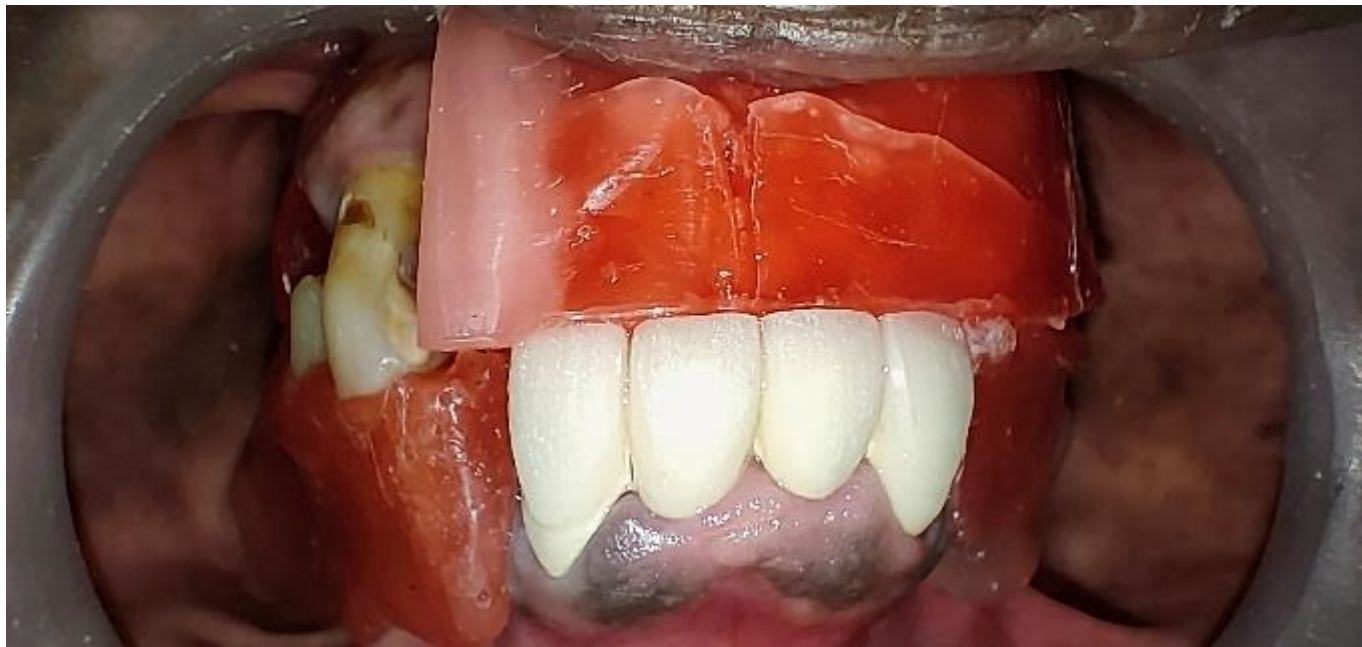Patient Name: Mr. JEBABALAN

RMCT: 462391

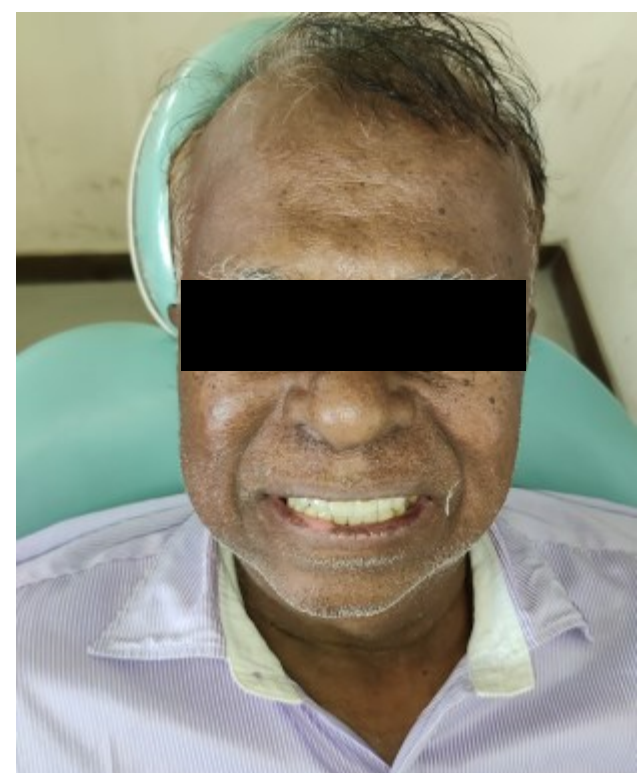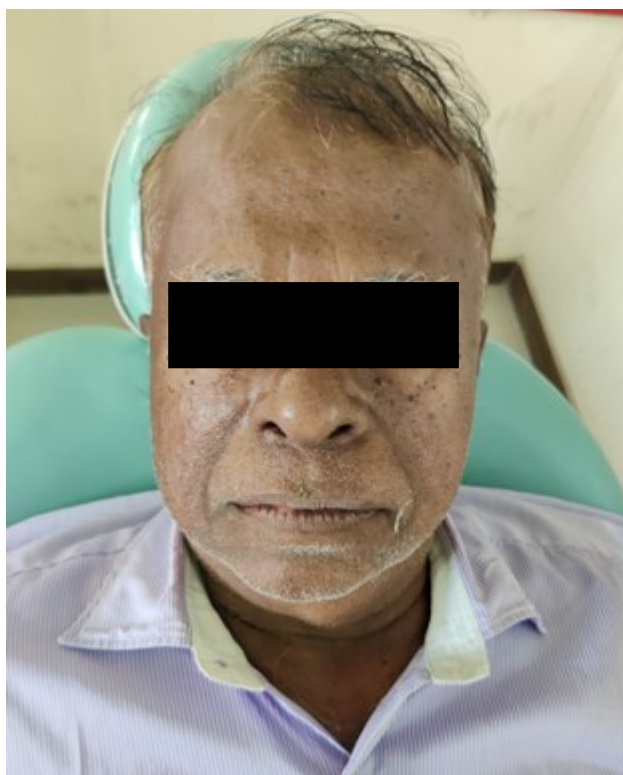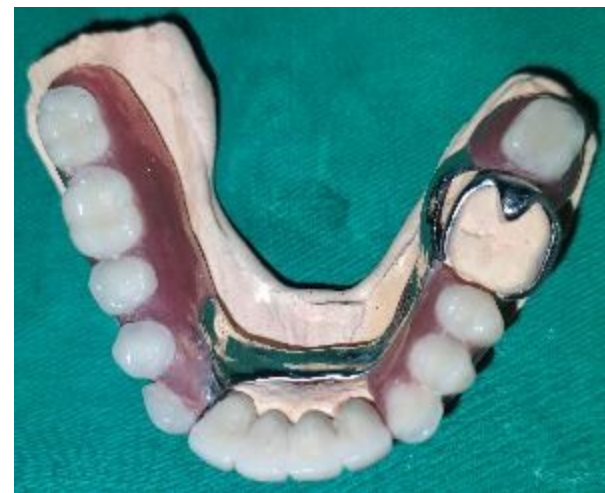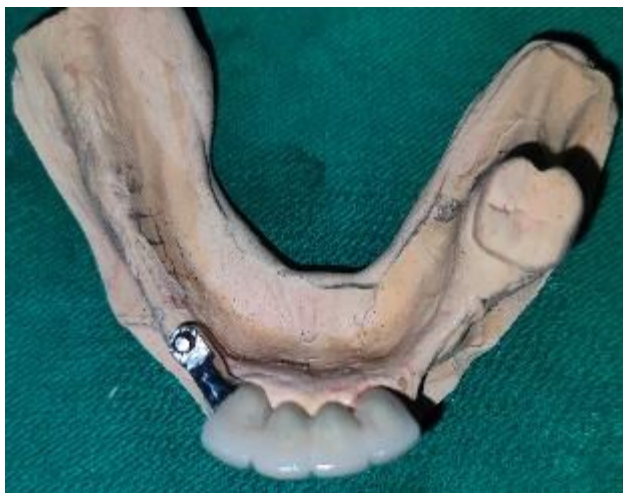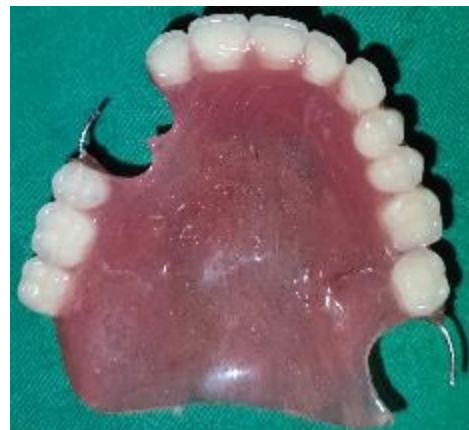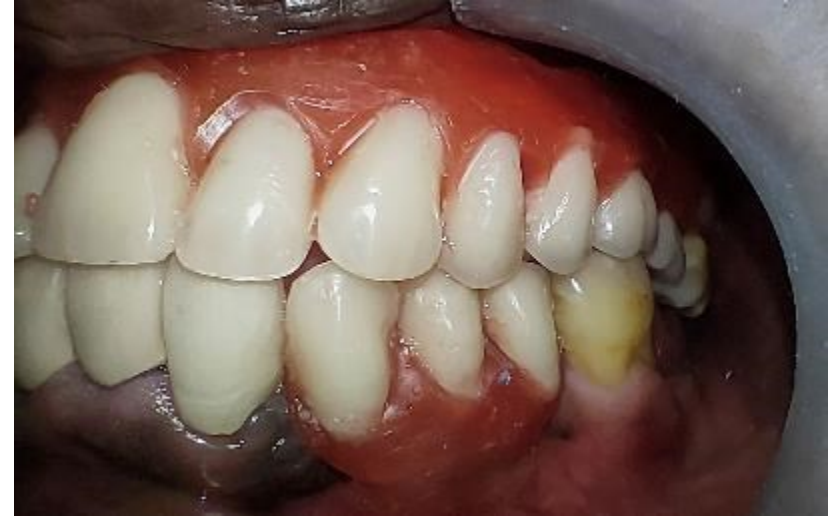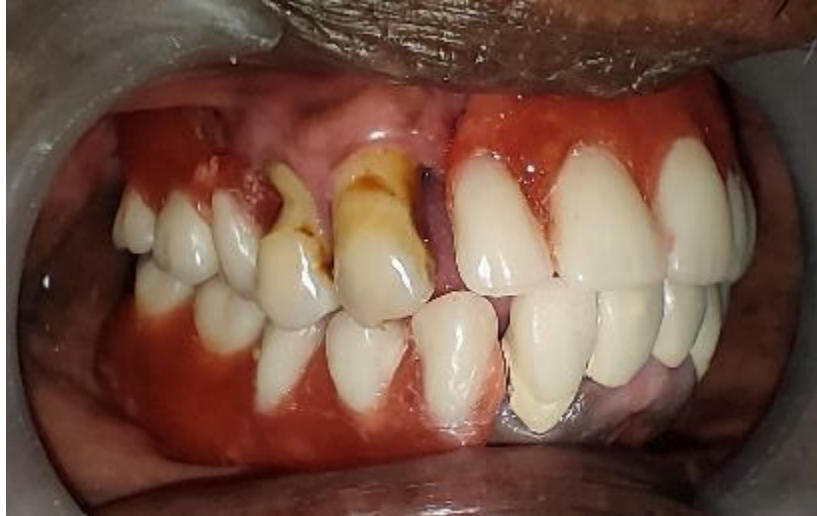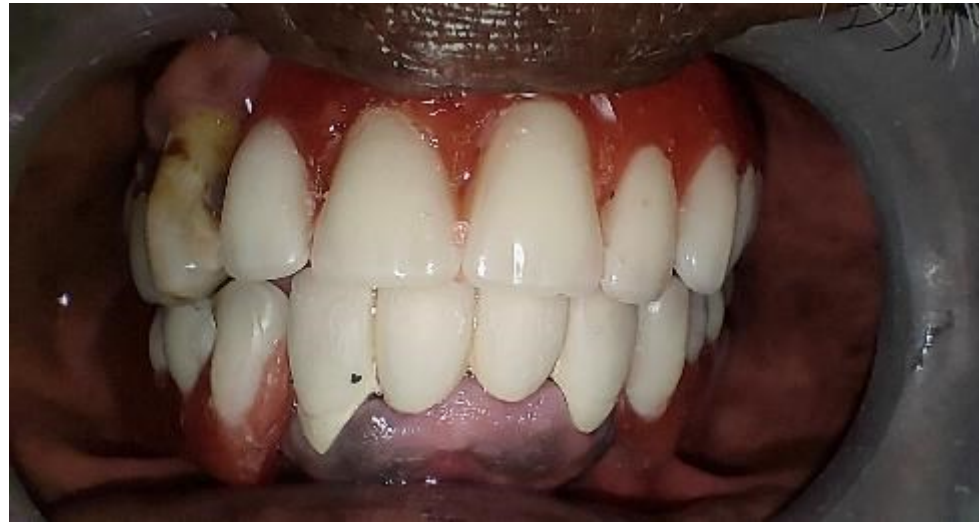OCCLUSAL RIMS WITH PREGLAZE TRIAL



JAW RELATION AND PRE GLAZE TRIAL



WAX TRY IN



TOOTH SUPPORTED OVERDENTURE

PATIENT NAME: Mrs. THILAGAVATHY

RMCT: 465891

TOOTH SUPPORTED OVERDENTURE







