



Chettinad

Dental College & Research Institute

**CHETTINAD DENTAL COLLEGE
AND RESEARCH INSTITUTE**

Affiliated to the Tamil Nadu Dr. M.G.R. Medical University, Chennai

Case Album

Dr. RAJ MANICKAM D

2018-2021

**PROSTHODONTICS AND
CROWN & BRIDGE
CHETTINAD DENTAL COLLEGE
& RESEARCH INSTITUTE**

CONTENTS

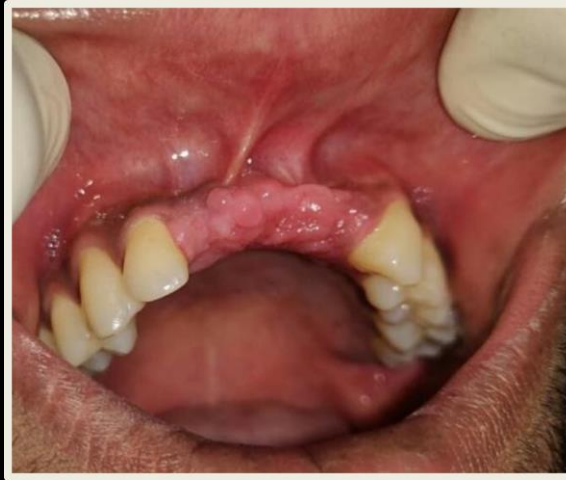S. No	OP no.	Patient name	Type of case
1.	201906120189	Mr. Samson Moses	Implant placement by ridge splitting and rehabilitation by custom abutments
2.	202001020090	Mr. Kannan	Immediate implant and rehabilitation
3.	201901180121	Mr. Paranjothi	Unilateral presision attachment
4.	201807120043	Mr. Praveen kumar bhagat	Management of hemisected teeth
5.	202102080156	Mrs. Indira	Cast post
6.	202002040090	Mrs. Bama	Hybrid prosthesis for zygoma and all on 6 implants
7.	202103290121	Mr. Surya prakash	Implant cantilever
8.	201910090042	Mrs. jothi	Laminate veneers
9.	202101280124	Mr. Subramani	Metal based single complete denture
10.	201907160057	Mr. Rajasekaran Nair	Neutral zone
11.	202012010019	Mr. Sadacharam	Balanced occlusion
12.	201903110008	Mrs. Rajeshwari	Precision attachment supported cast partial denture
13.	202102170170	Mr. Prem singh	Tooth supported overdenture

IMPLANT PLACEMENT BY RIDGE SPLITTING

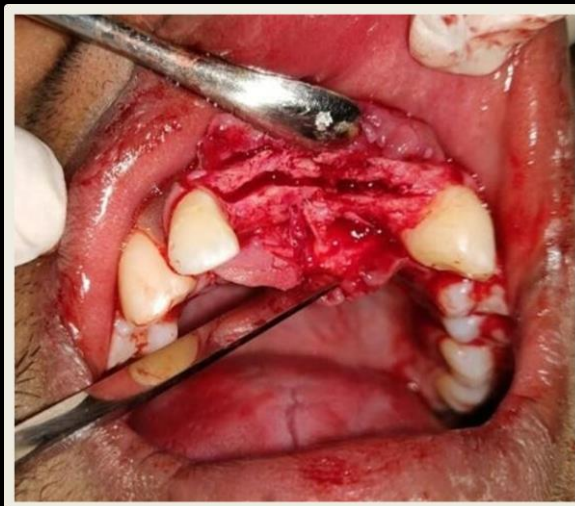Patient name: Mr.Samson Moses

age/sex: 21yrs/male

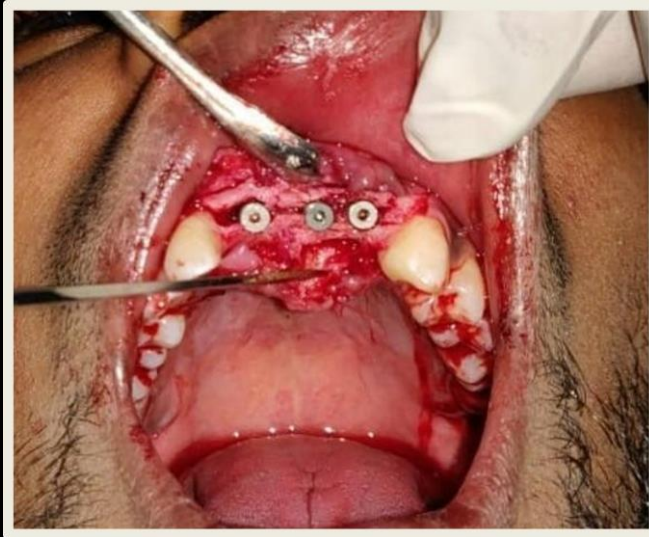PRE-OP



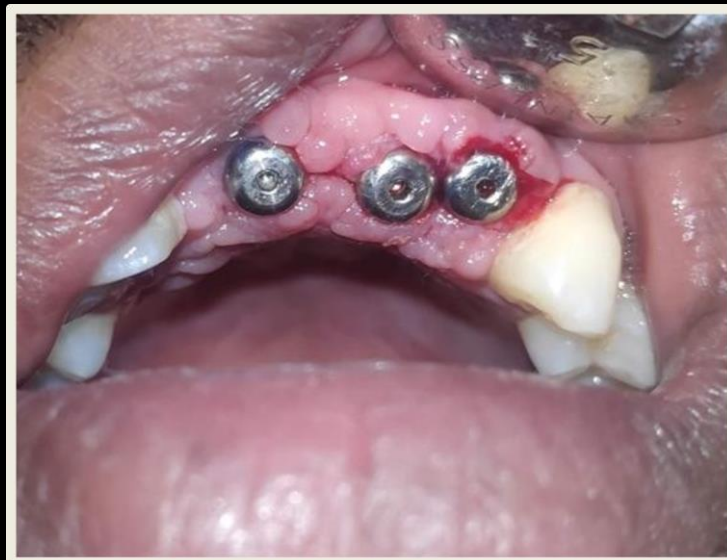RIDGE SPLITTING



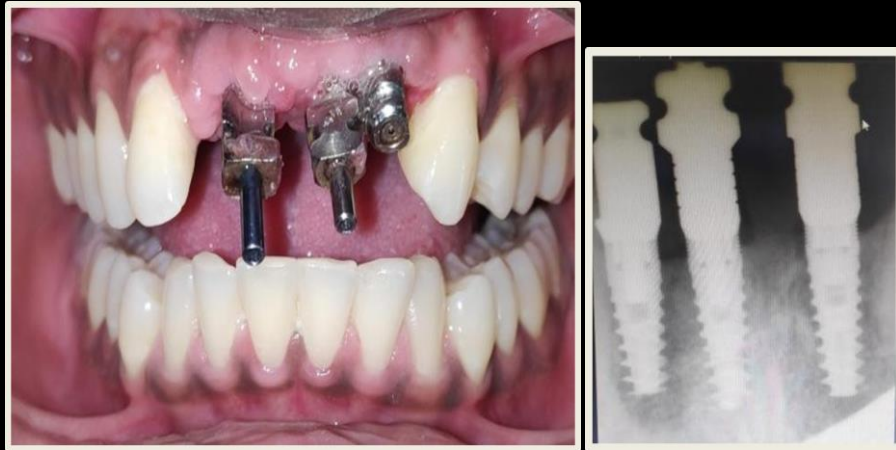IMPLANT PLACEMENT



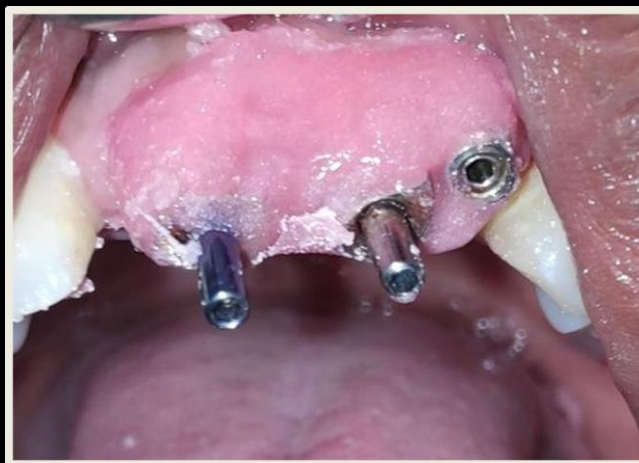PROSTHETIC PHASE



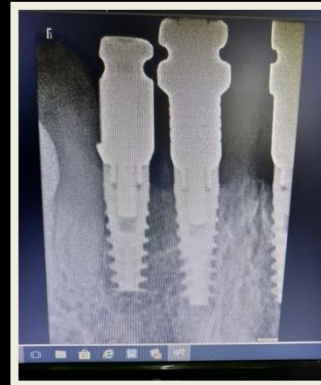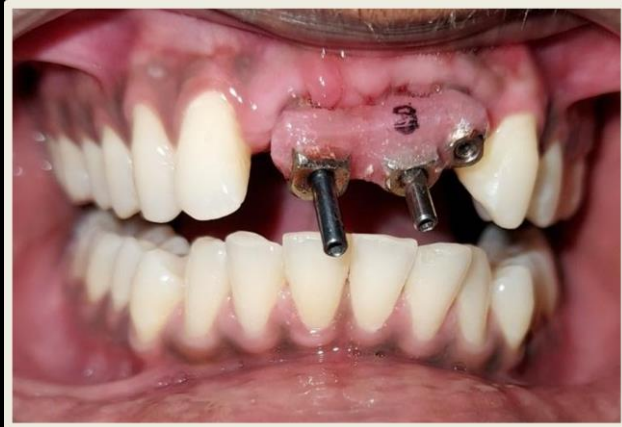IMPRESSION POSTS



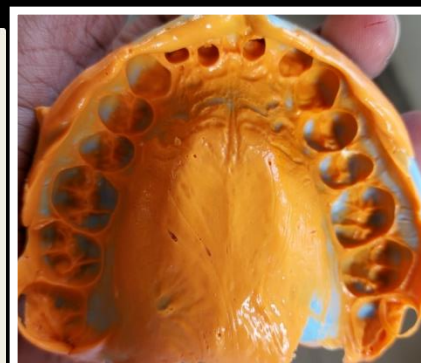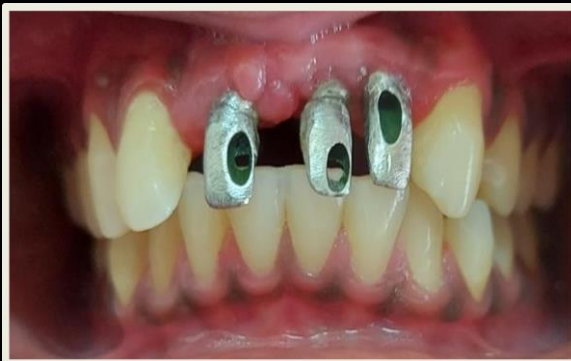SPLINTING



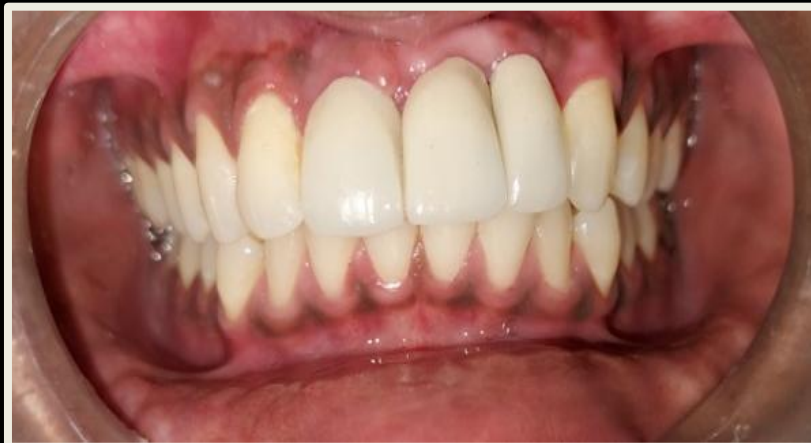JIG TRIAL



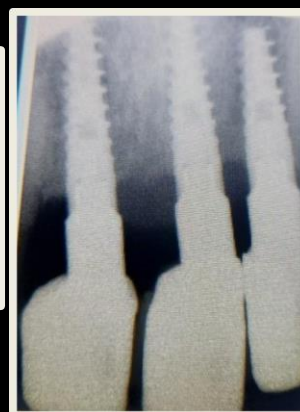
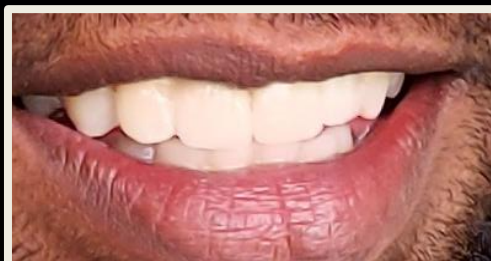CUSTOM ABUTMENTS AND IMPRESSION



POST-OP



POST-OP SMILE AND X-RAY

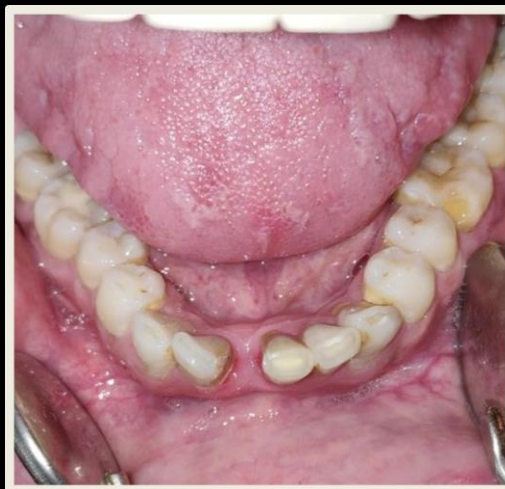
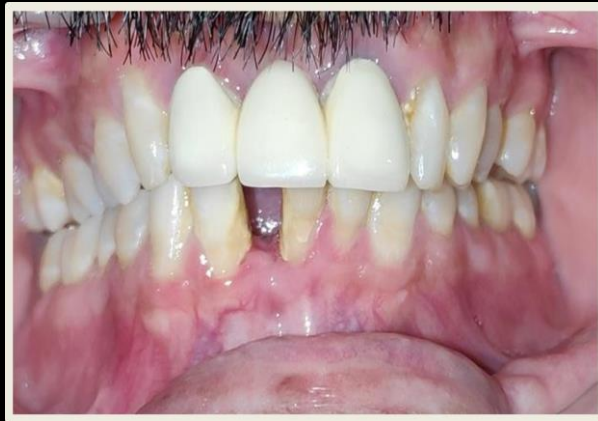
IMMEDIATE IMPLANT PLACEMENT AFTER EXTRACTION

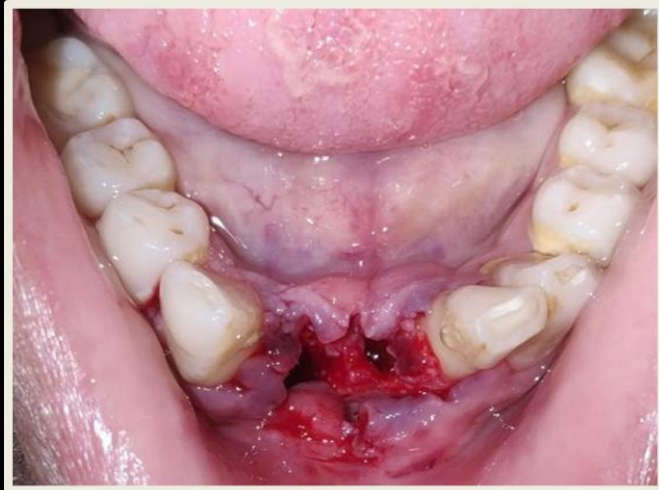Patient name: Mr. Kannan

Age/sex: 45 years / male

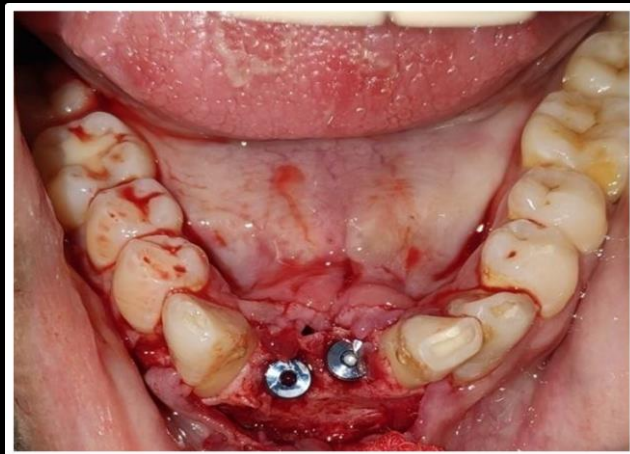
PRE-OP



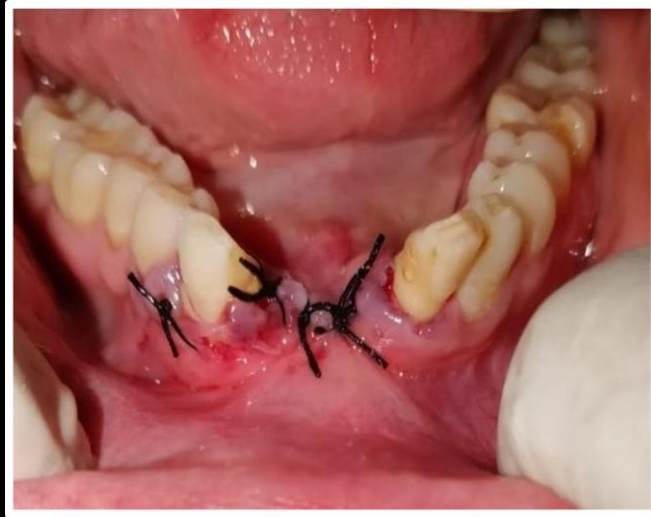EXTRACTION



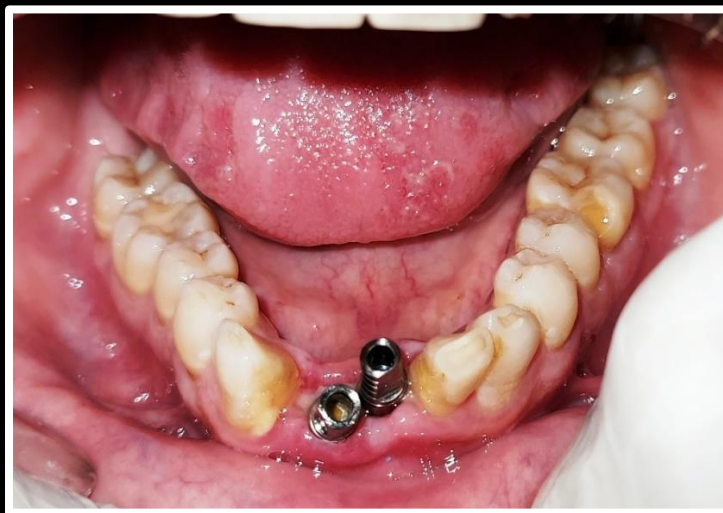IMPLANT PLACEMENT



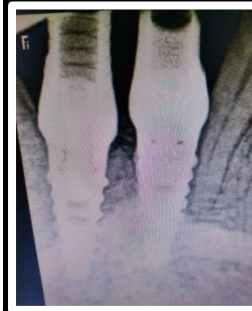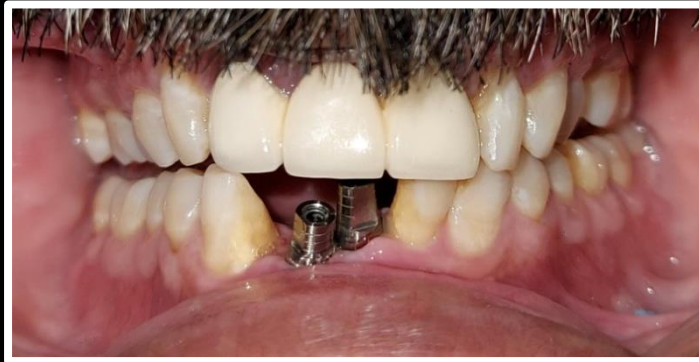SUTURES



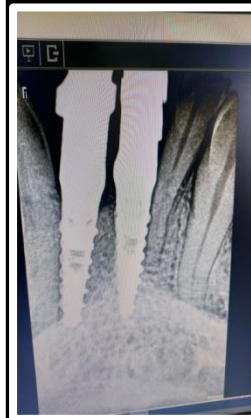
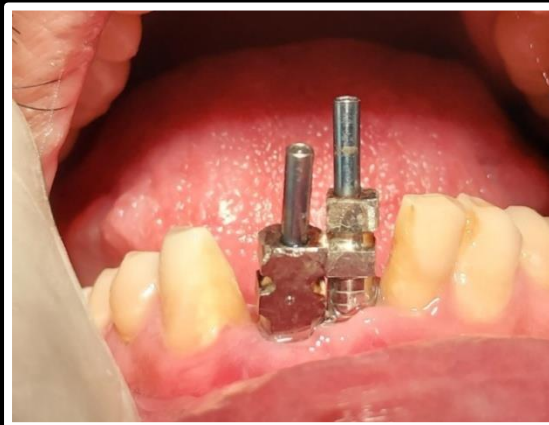
PROSTHETIC PHASE



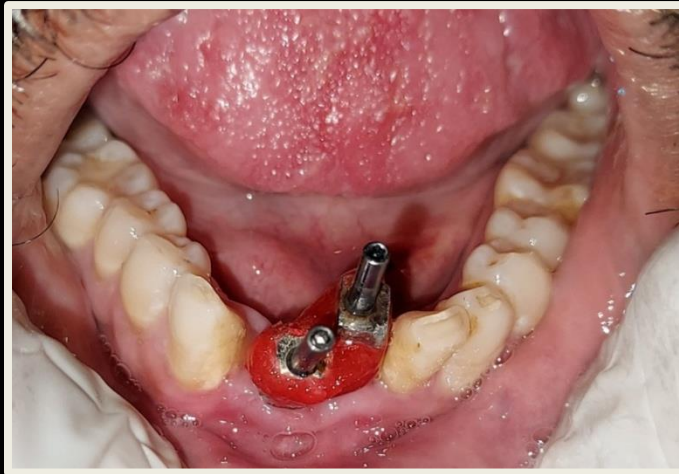
PROSTHETIC PHASE



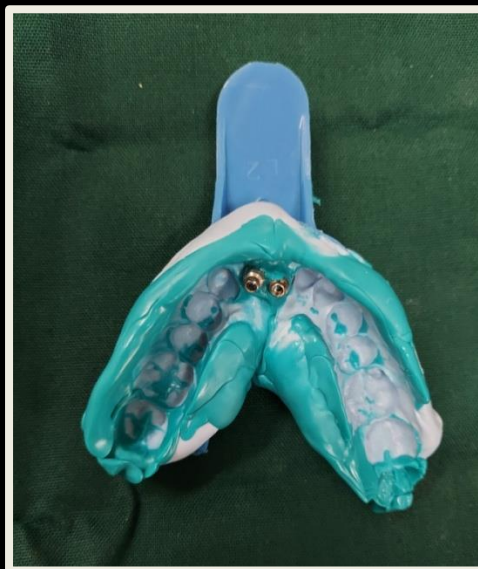IMPRESSION POSTS



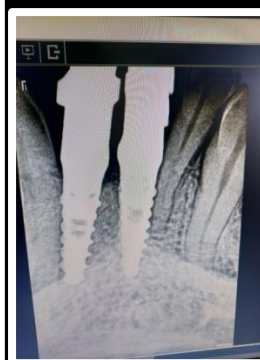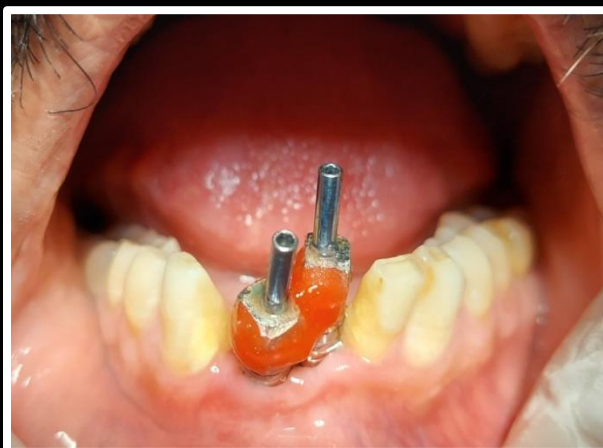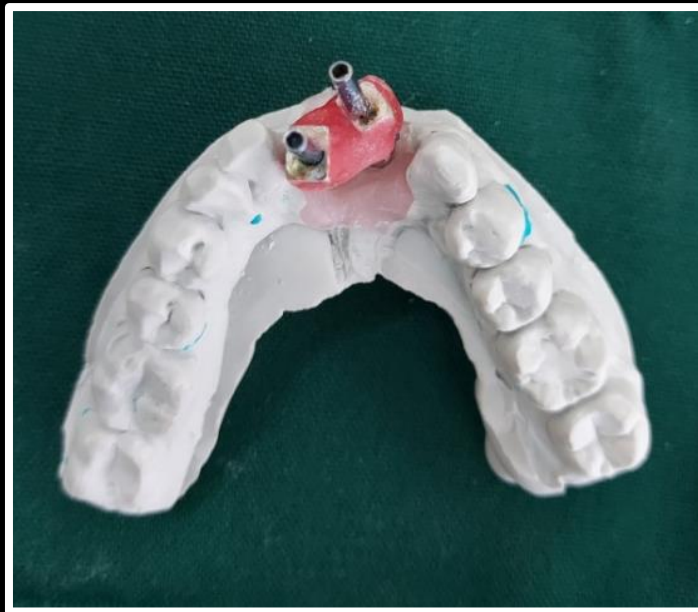SPLINTING



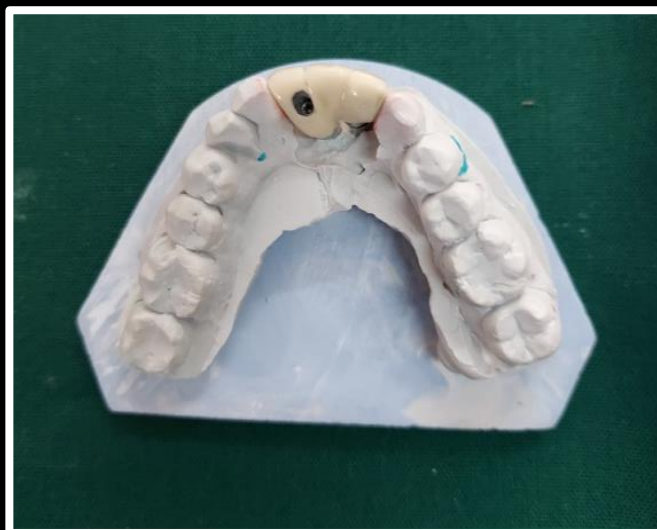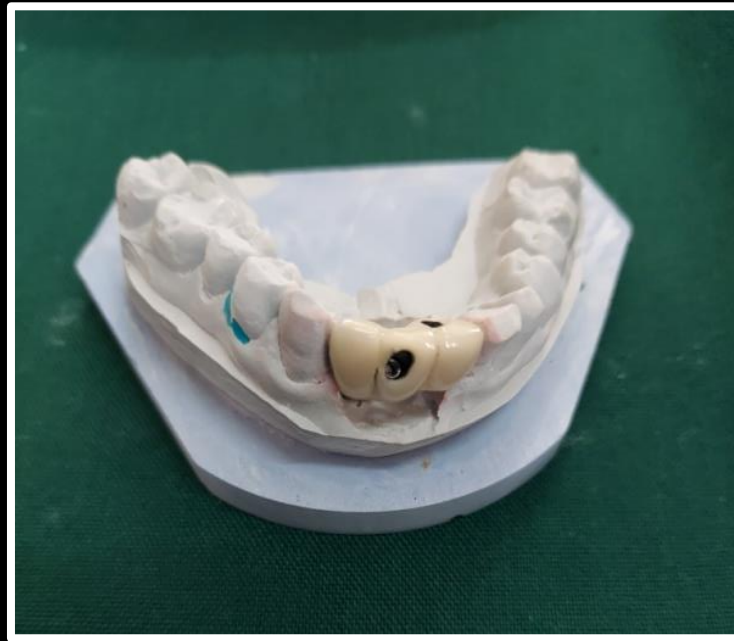IMPRESSION



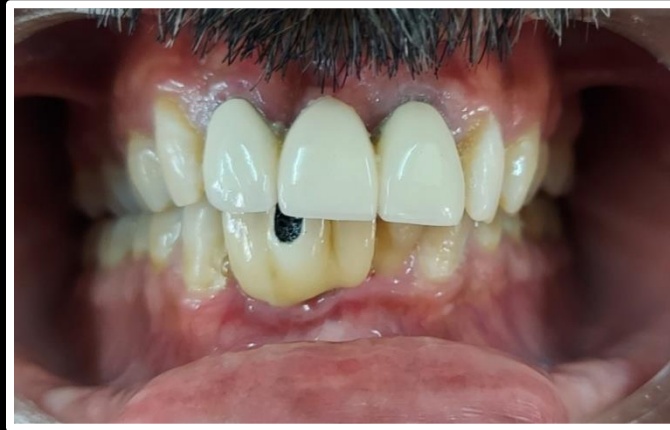JIG TRIAL



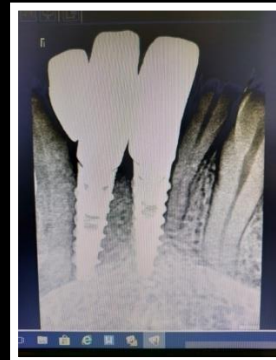
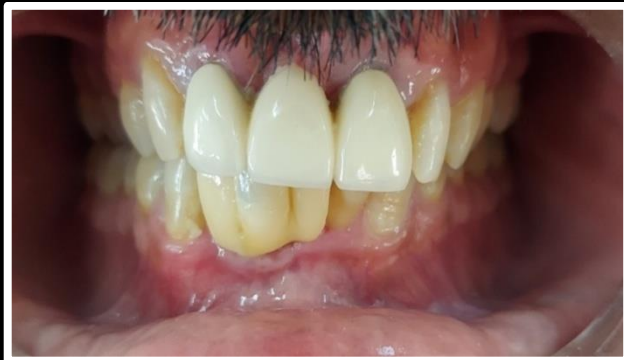FINAL RESTORATION



TRY-IN



POST-OP

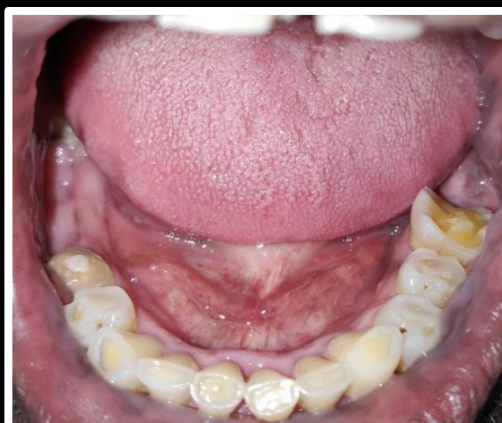
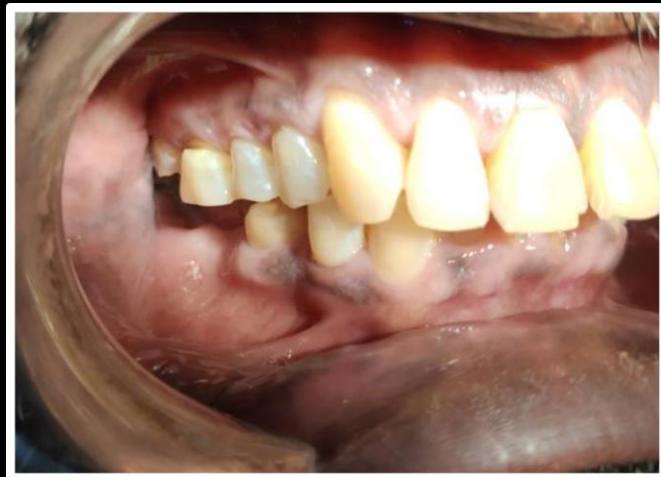
UNILATERAL PRECISION ATTACHMENT

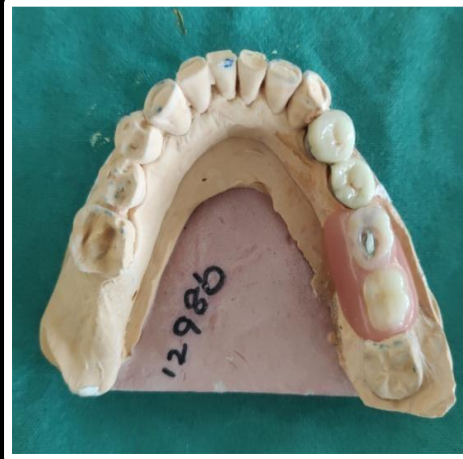Patient name: Mr. Paranjothi

Age/sex: 60years / male

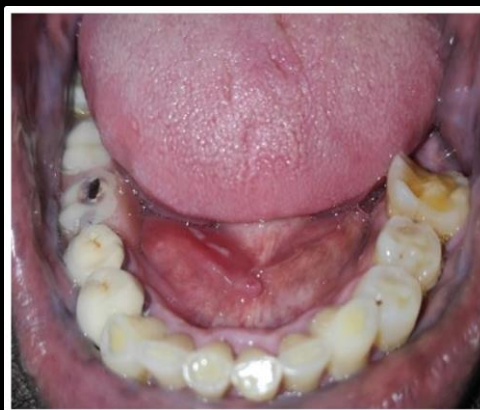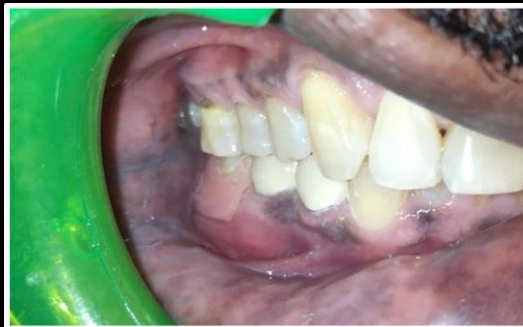PRE-OP



FINAL PROSTHESIS



POST-OP

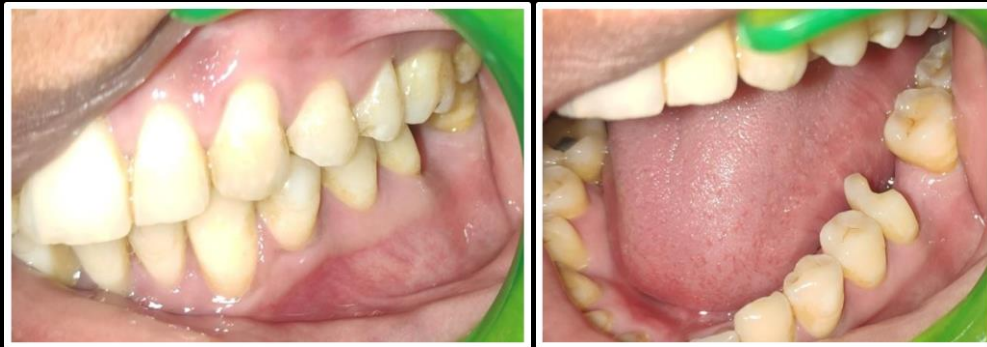

MANAGEMENT OF HEMISECTED TEETH

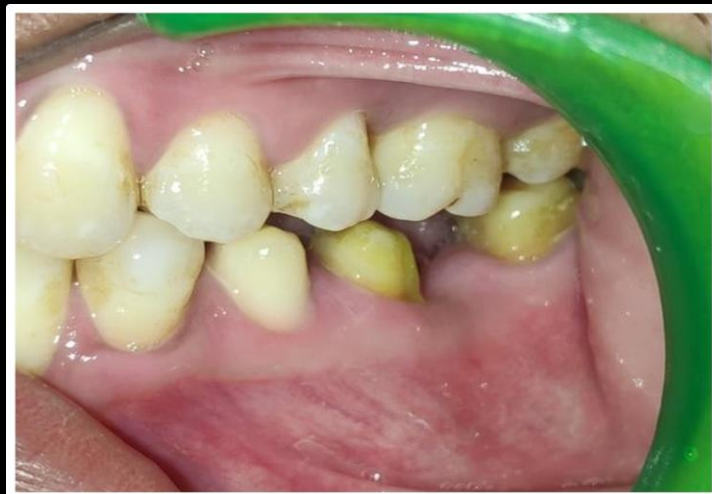Patient name: Mr. Praveen Kumar Bhagat

Age/sex: 29 years / male

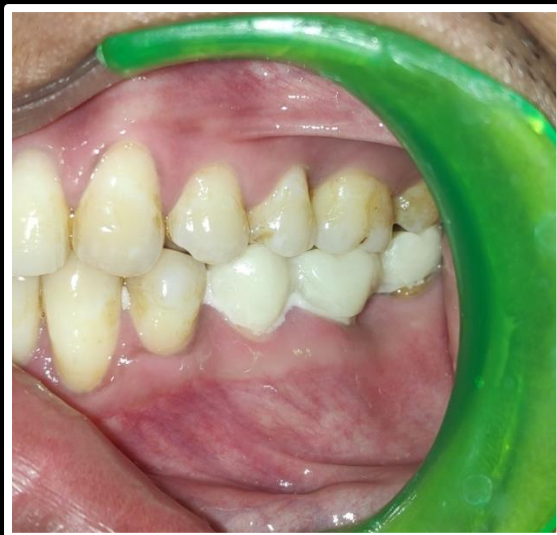PRE-OP



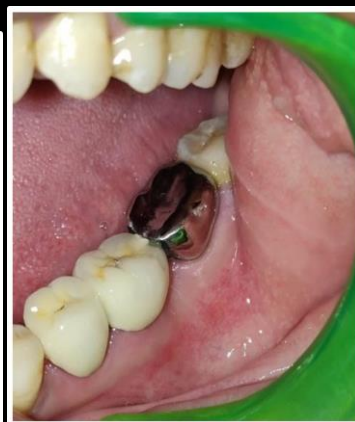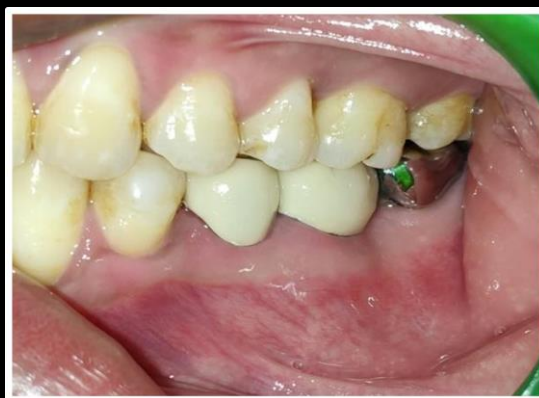TOOTH PREPARATION



TEMPORARIZATION



POST-OP

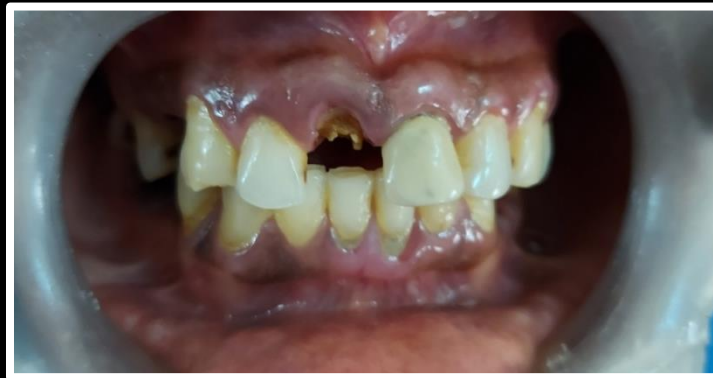

MANAGEMENT OF SEVERELY DAMAGED TOOTH – CAST POST

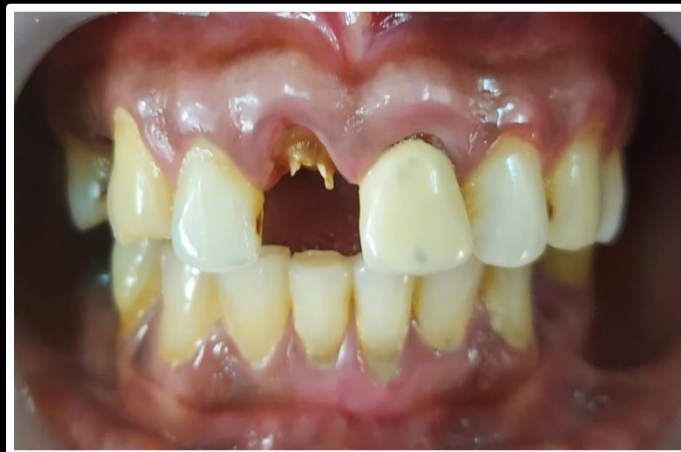Patient name: Mrs. Indira

Age/sex: 56 years / female

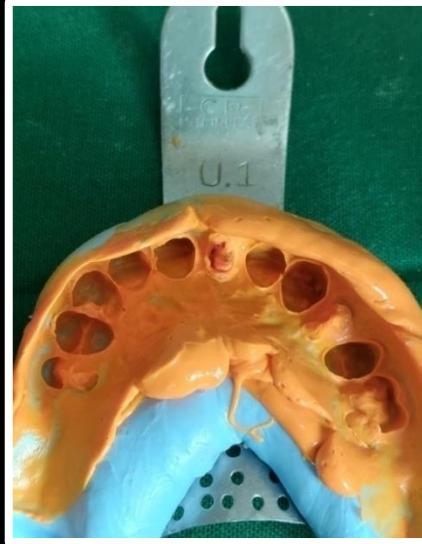PRE-OP



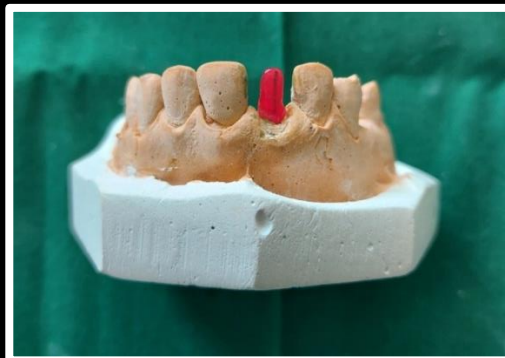PREPARATION



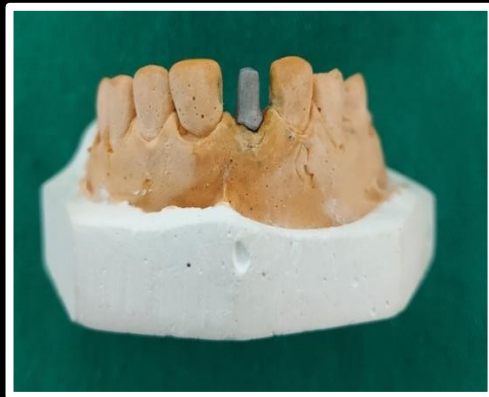IMPRESSION



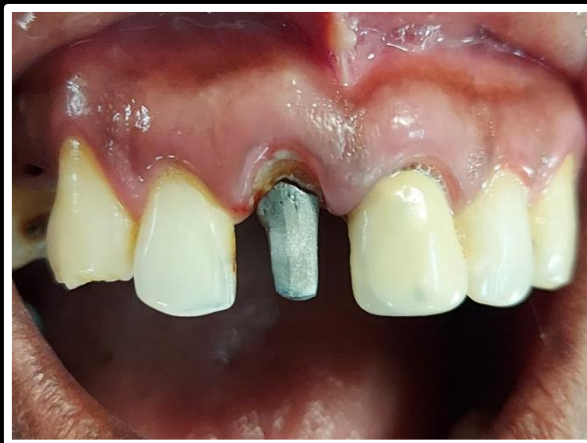PATTERN FABRICATION USING PATTERN RESIN



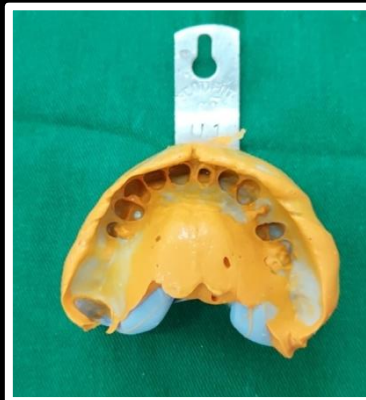CAST POST



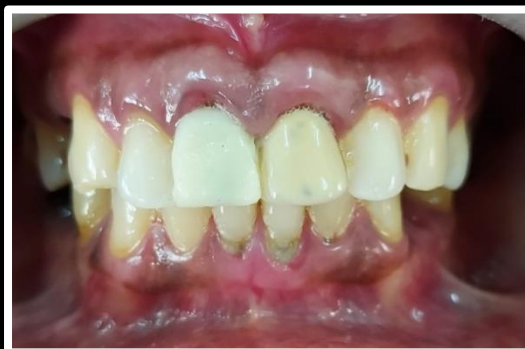CAST POST CEMENTATION



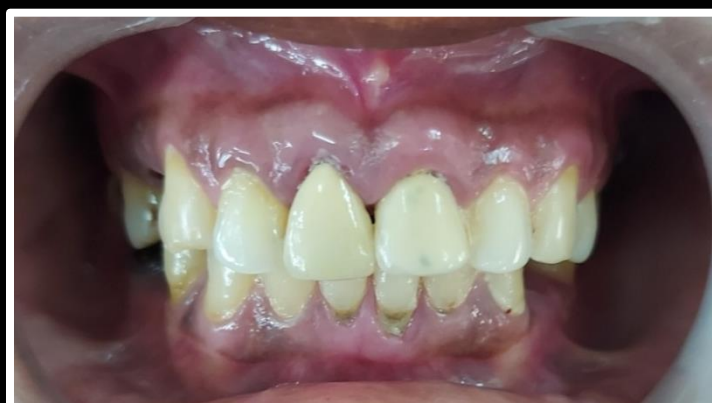IMPRESSION



TEMPORARIZATION



POST-OP

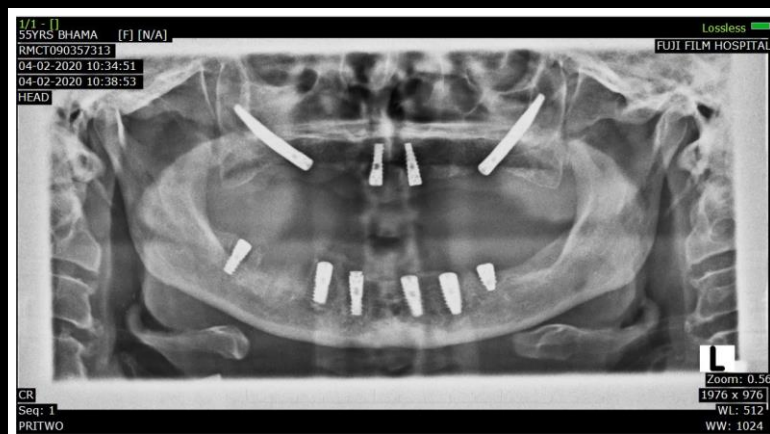
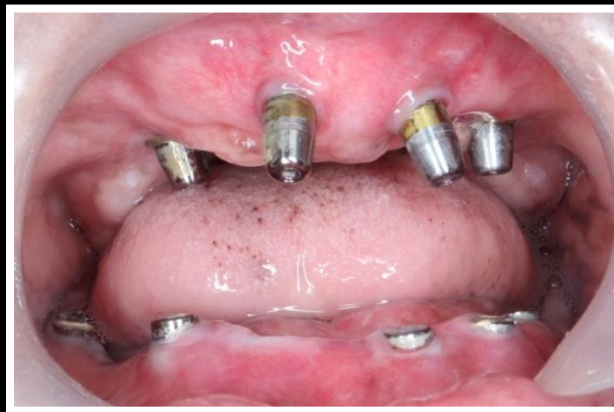

FABRICATION OF HYBRID PROSTHESIS FOR UPPER ZYGOMA AND LOWER ALL ON 6 IMPLANTS

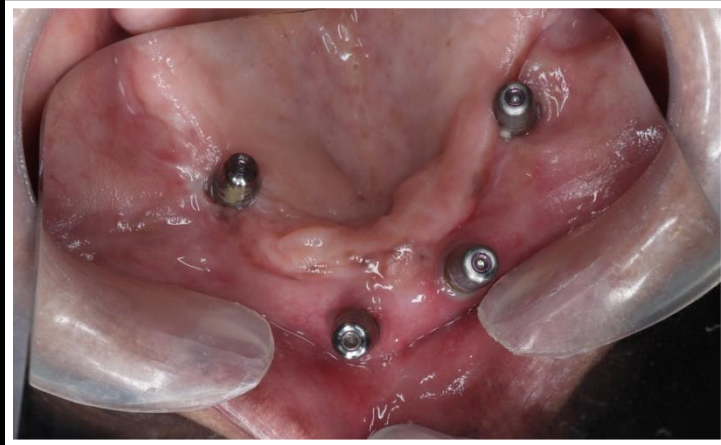Patient name: Mrs. Bama

Age/sex: 60 years / female

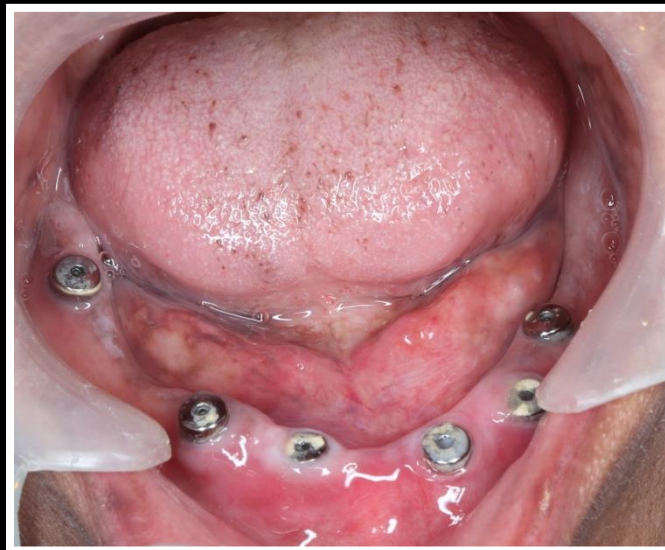PRE-OP



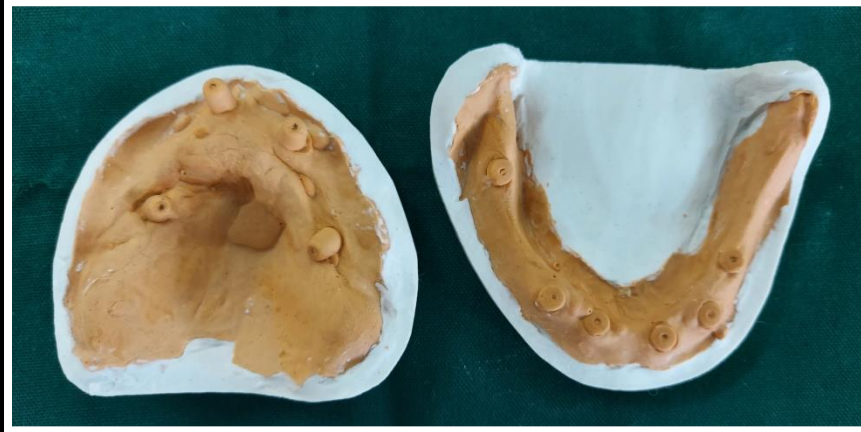
MAXILLA



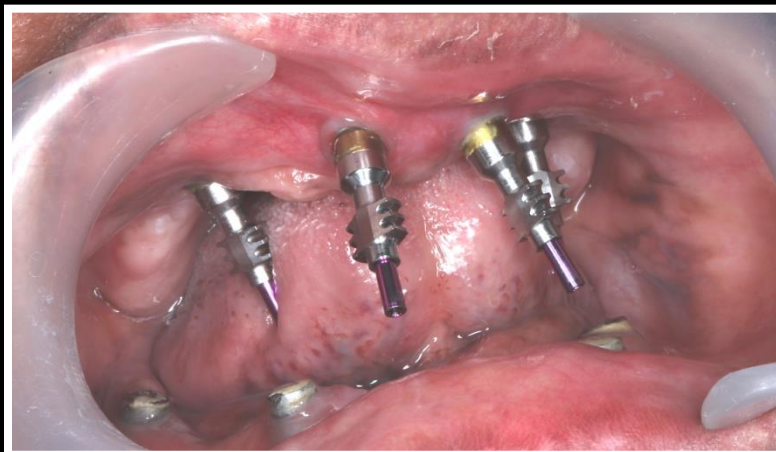
MANDIBLE



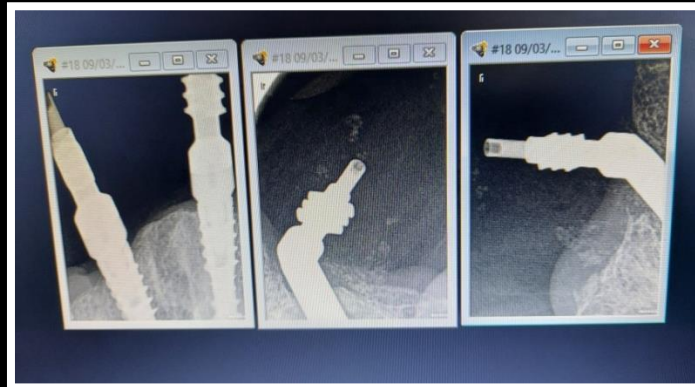
DIAGNOSTIC MODEL



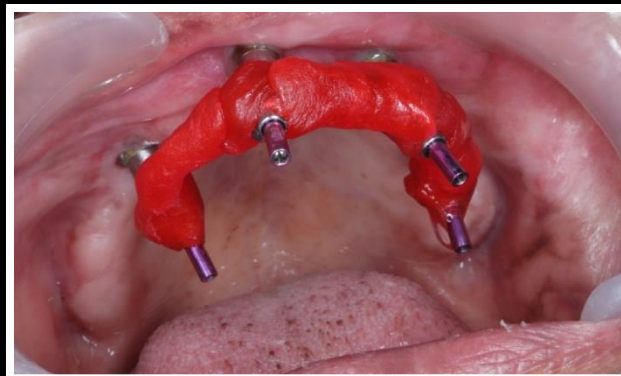
IMPRESSION POSTS-MAXILLA



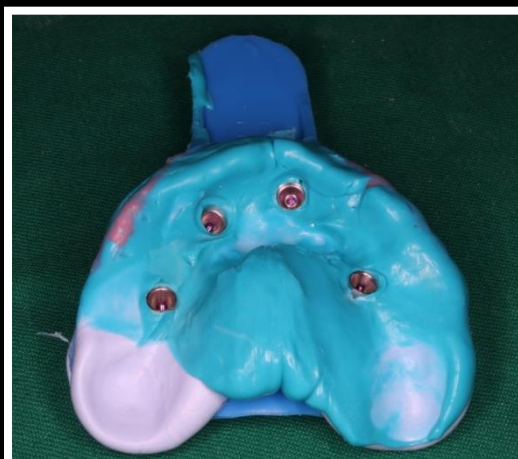X-RAY VERIFICATION FOR FIT



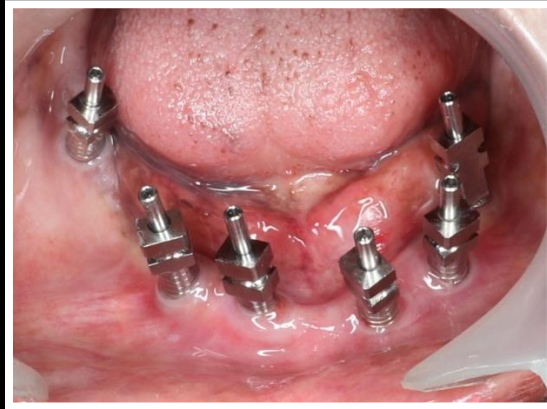
SPLINTING



OPEN TRAY IMPRESSION-MAXILLA



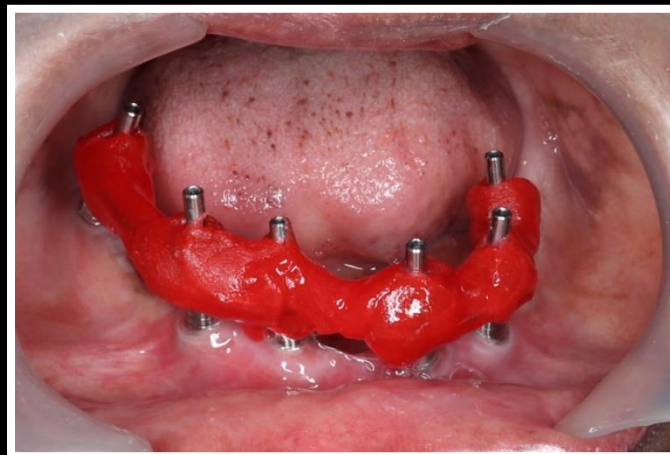
IMPRESSION POSTS-MANDIBLE



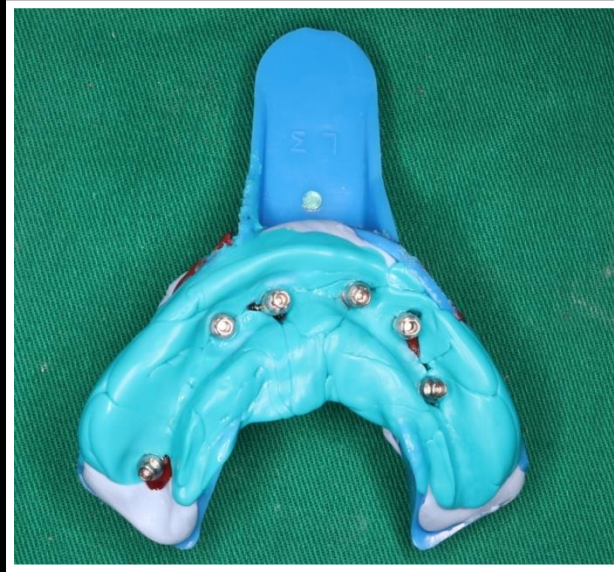X-RAY VERIFICATION FOR FIT



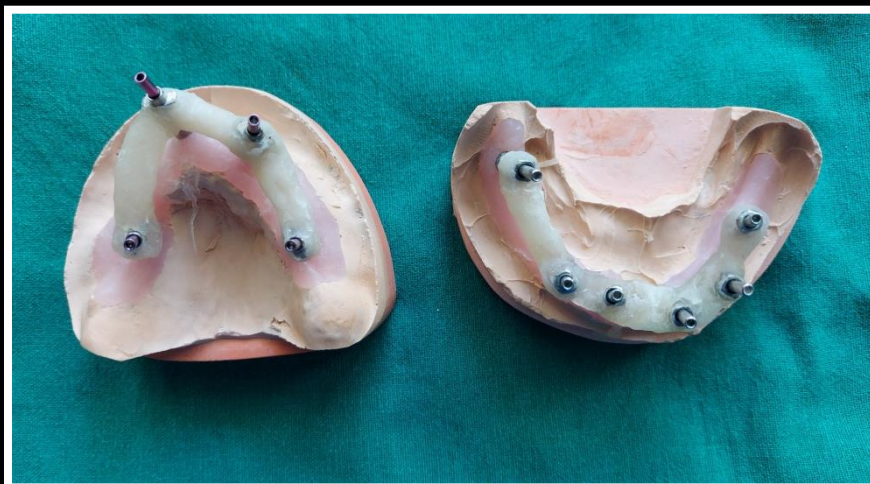SPLINTING



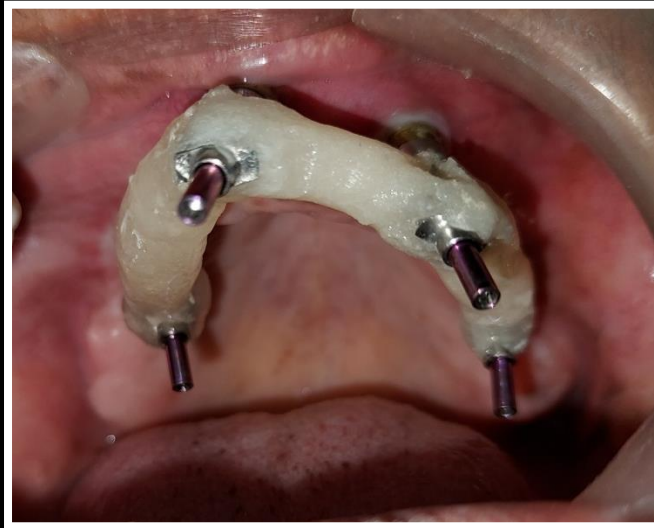
OPEN TRAY IMPRESSION-MANDIBLE



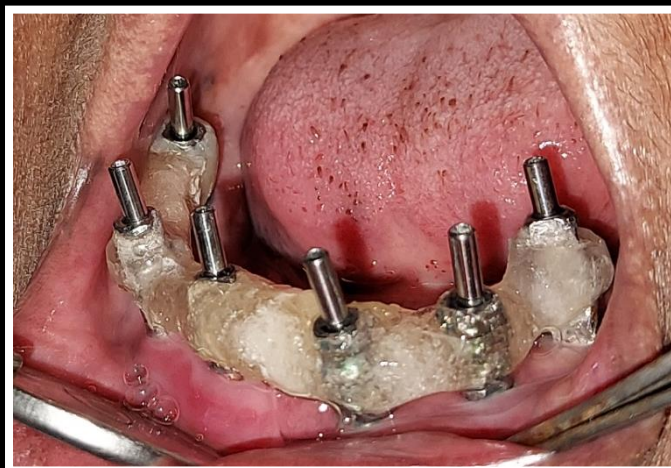
JIG TRIAL



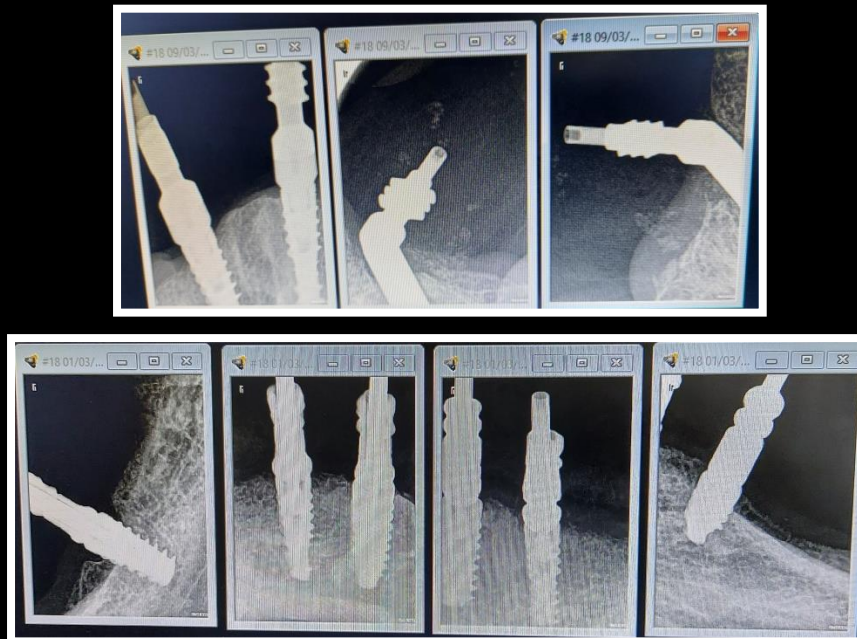JIG TRIAL-MAXILLA



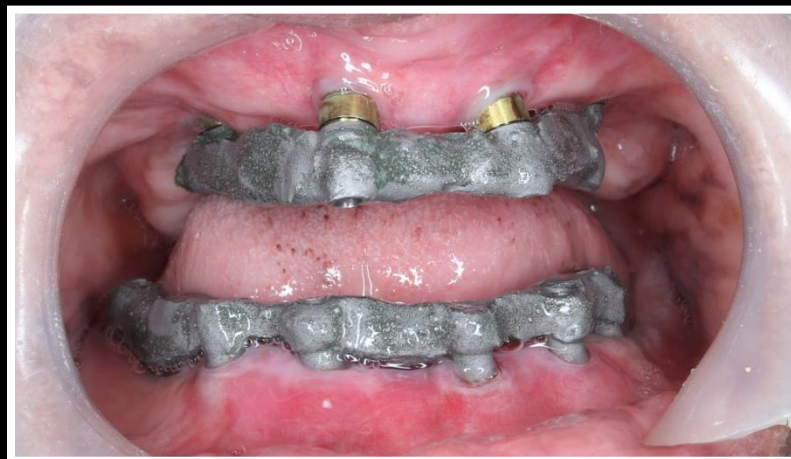JIG TRIAL- MANDIBLE



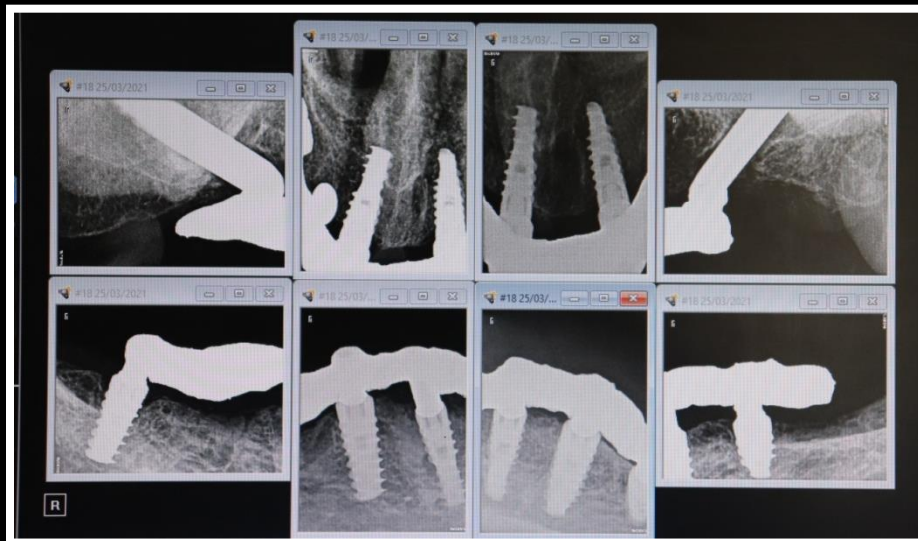VERIFICATION BY X-RAY



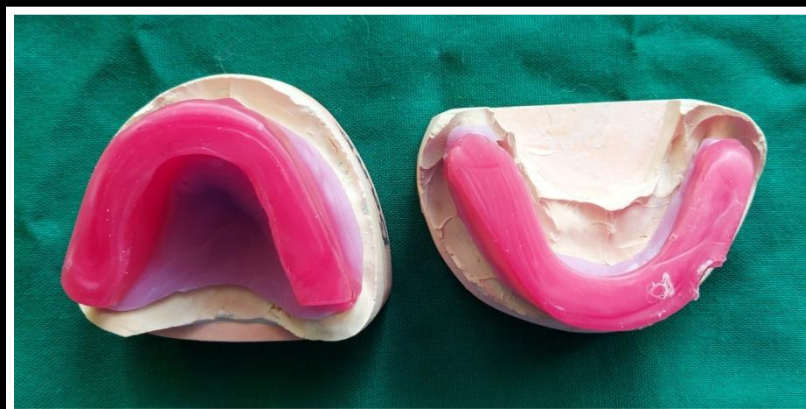METAL FRAMEWORK TRY IN



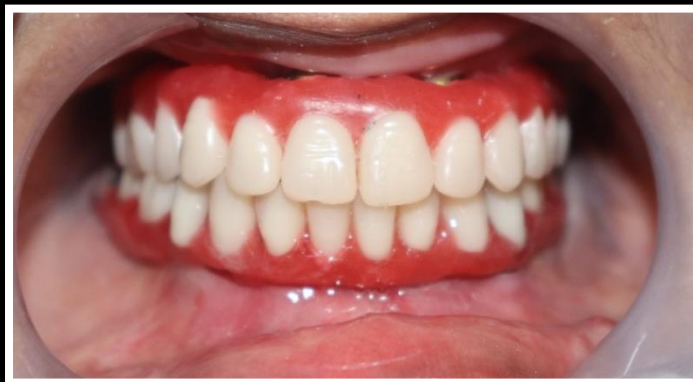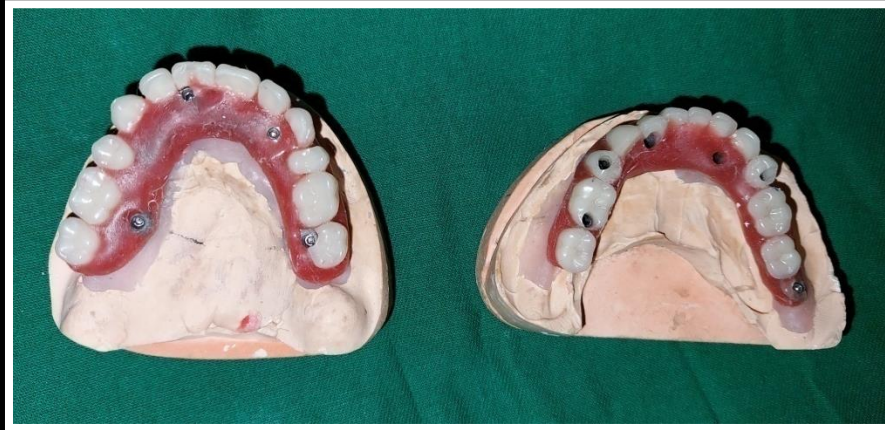
VERIFICATION BY X-RAY



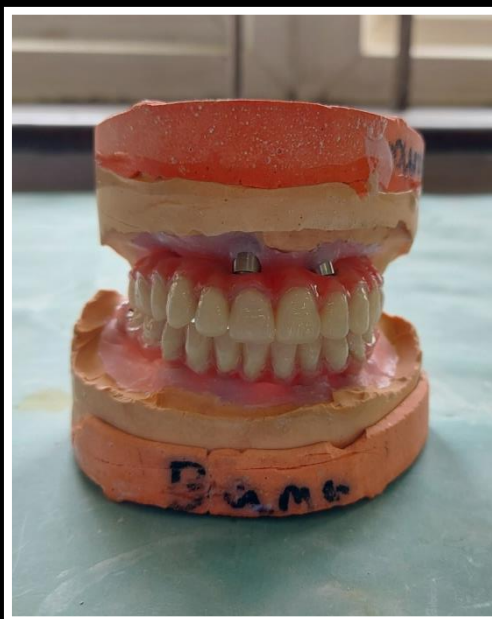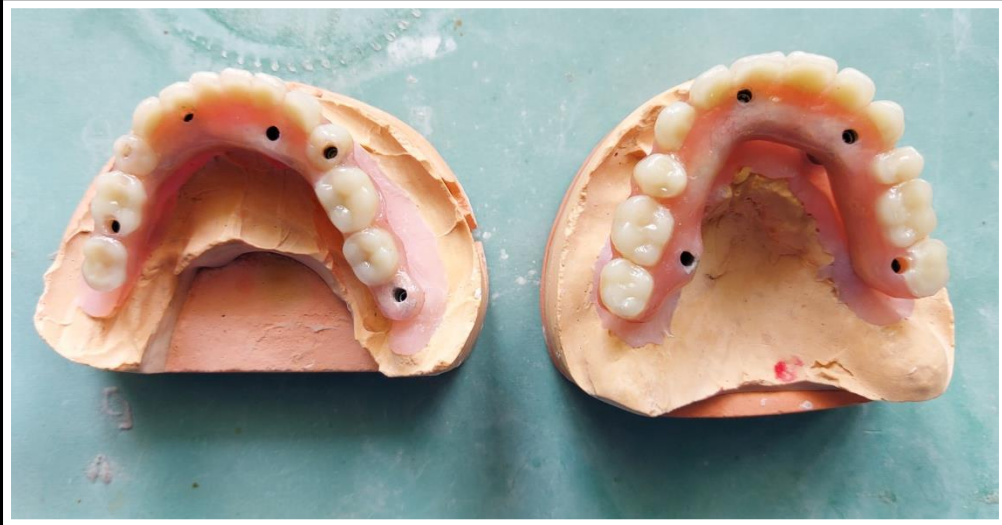JAW RELATION



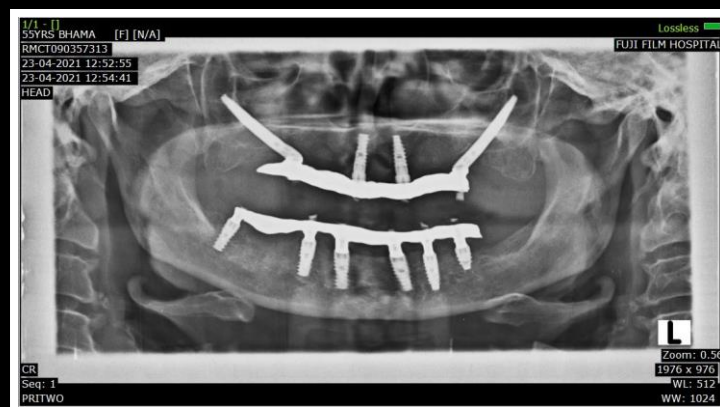
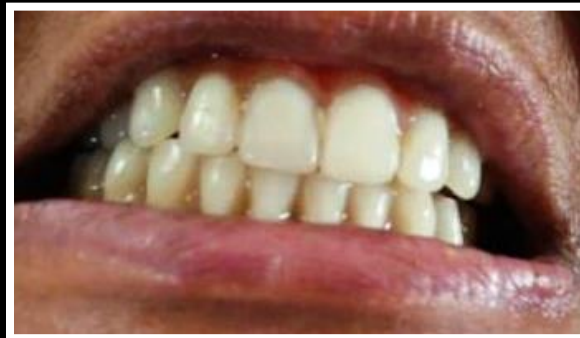WAX-TRIAL



FINAL HYBRID PROSTHESIS



POST-OP

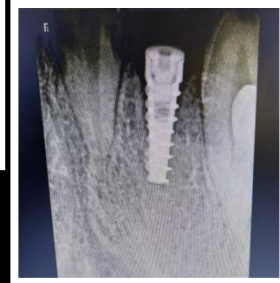
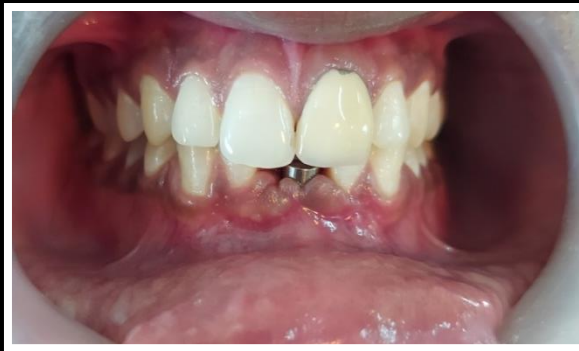
CANTILEVER IMPLANT

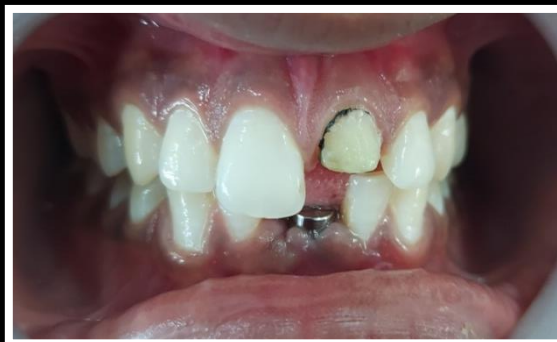Patient name: Mr. Suryaprakash

Age/sex: 24 years / male

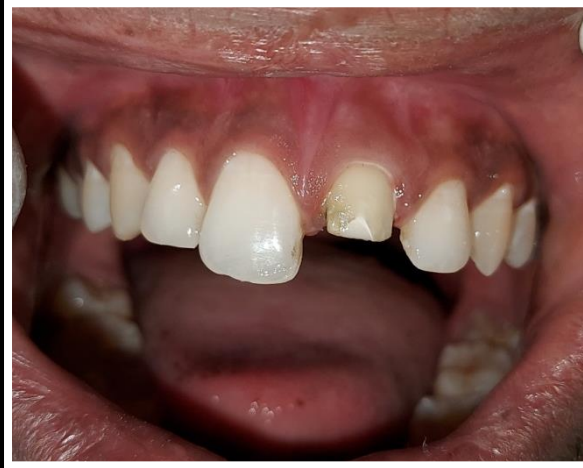PRE-OP



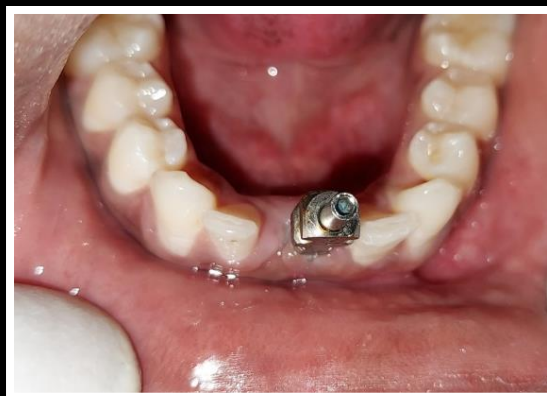CROWN REMOVAL



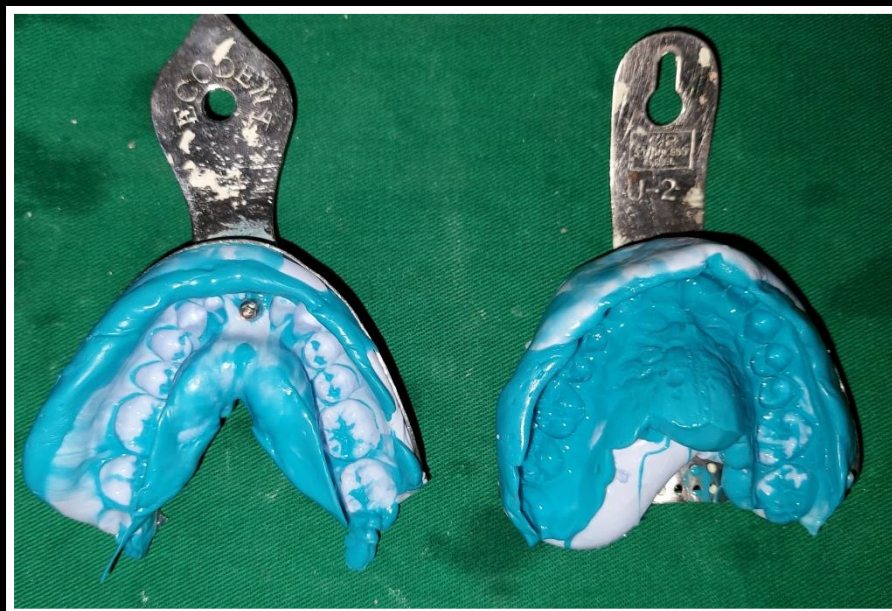
TOOTH MODIFICATION



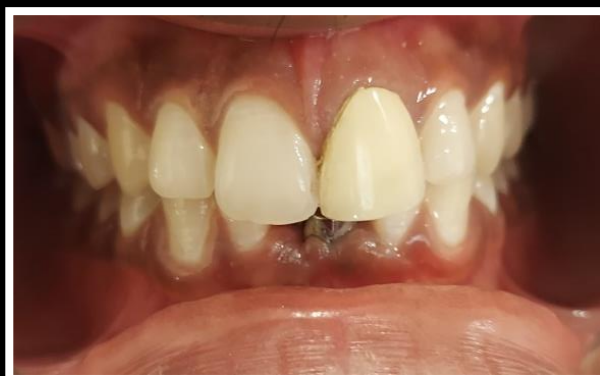IMPRESSION POST IN LOWER



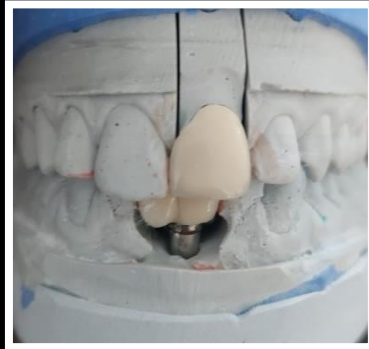
IMPRESSION



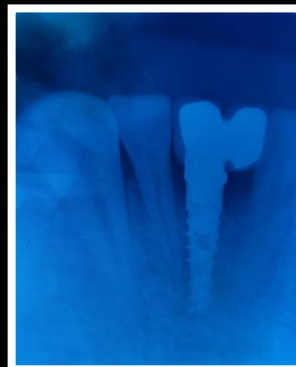
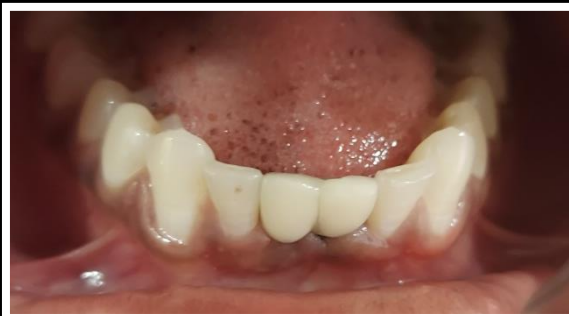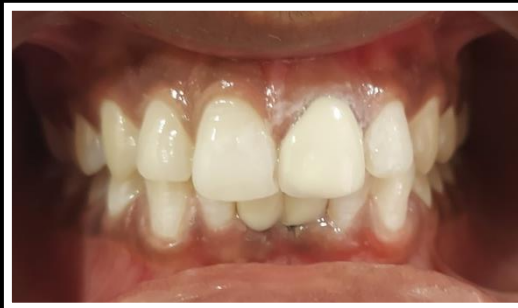TEMPORARIZATION



FINAL RESTORATION



POST-OP

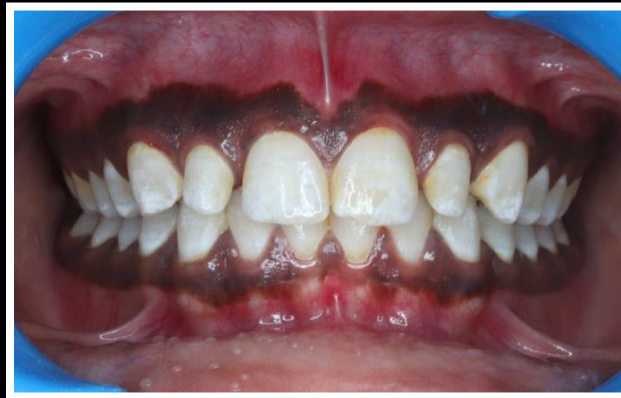

LAMINATE VENEERS

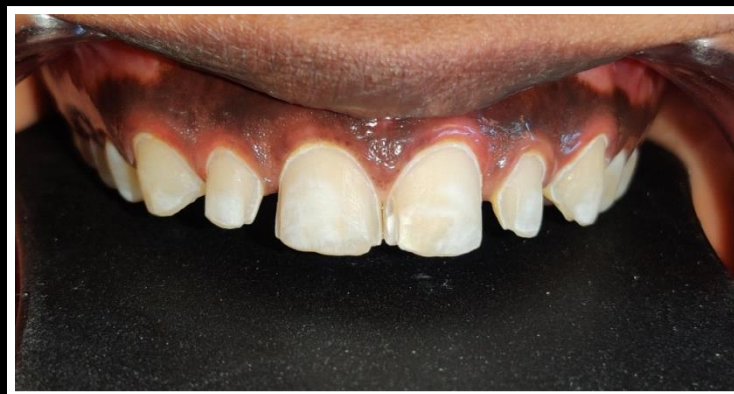Patient name: Mrs. Lakshmi

Age/sex: 34 years / female

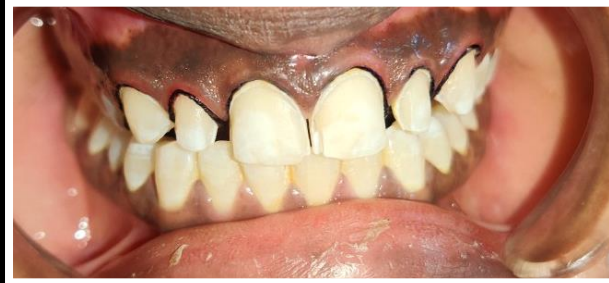PRE-OP



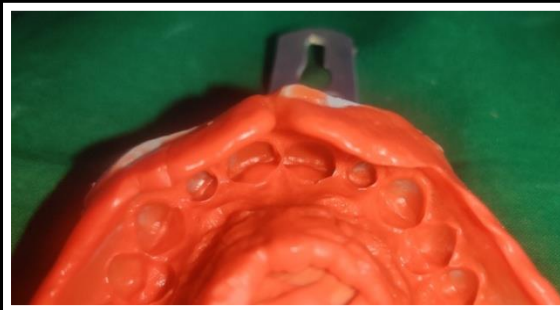
PREPARATION



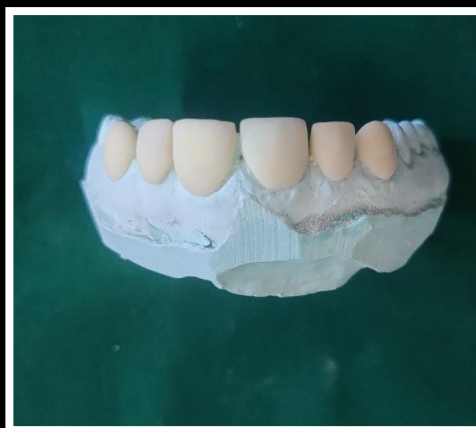GINGIVAL RETRACTION



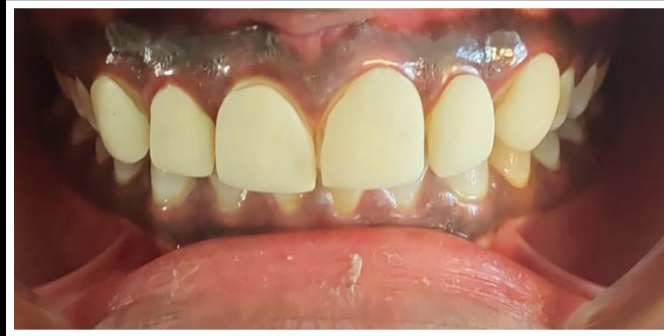IMPRESSION



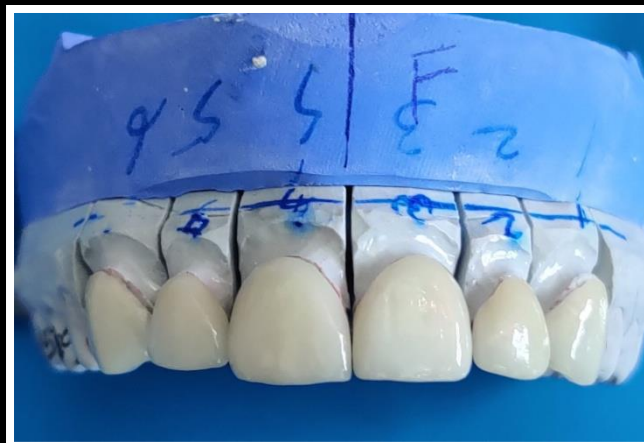TEMPORARIZATION



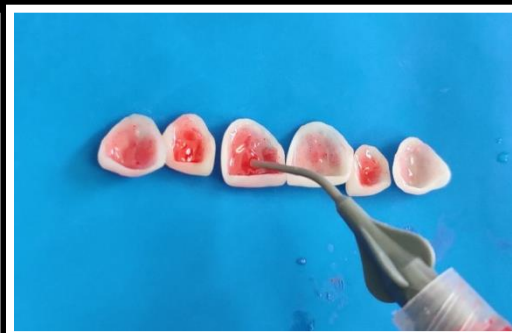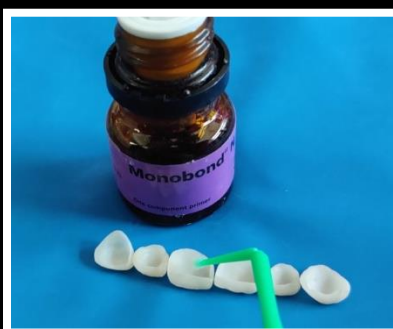TEMPORARIZATION



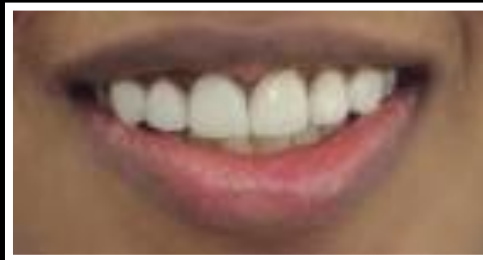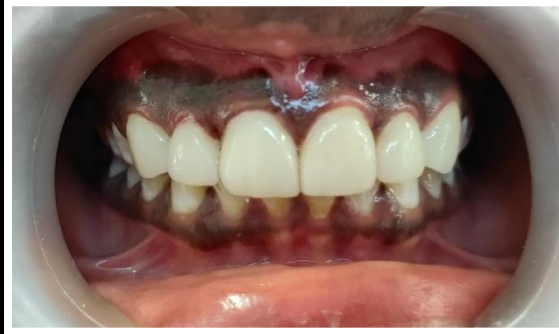LAMINATES



TREATMENT



POST-OP

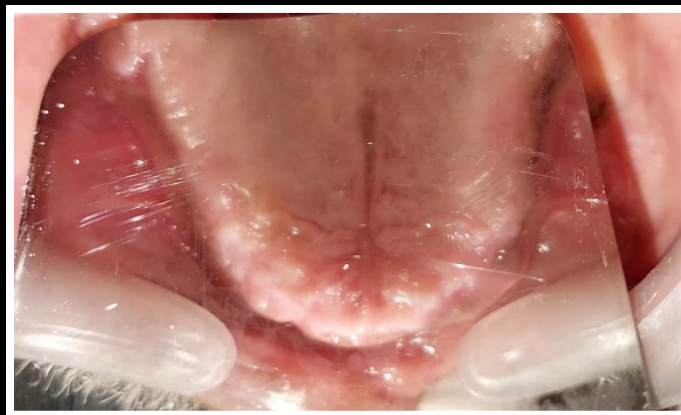
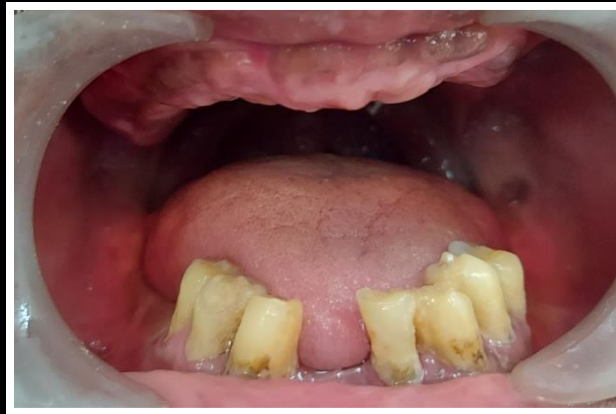
METAL BASED SINGLE COMPLETE DENTURE

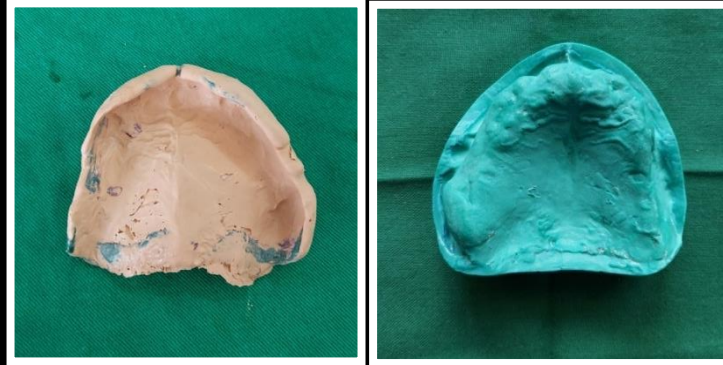
Patient name: Mr. Subramani

Age/sex: 71 years / male

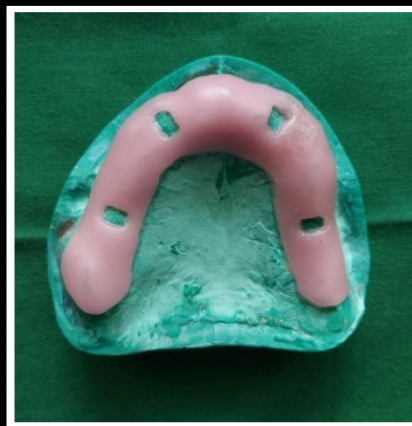PRE-OP



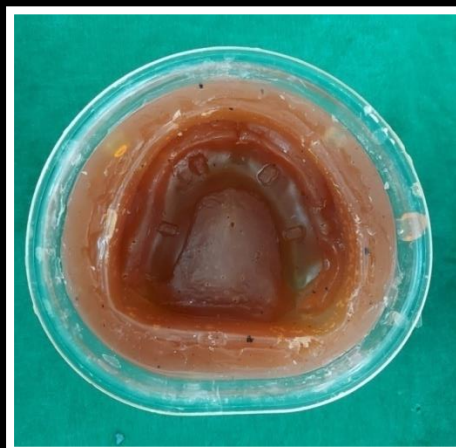
SECONDARY IMPRESSION AND MASTER CAST



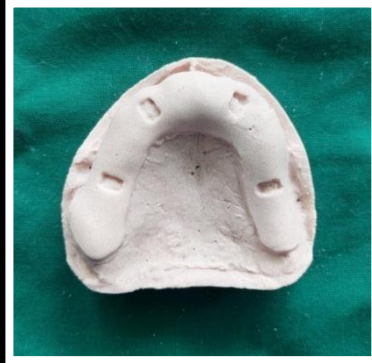SPACER



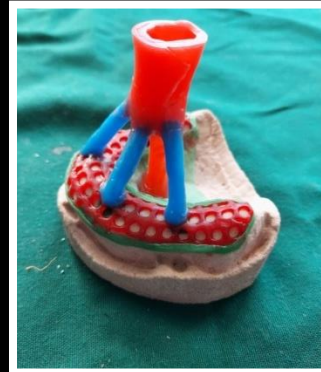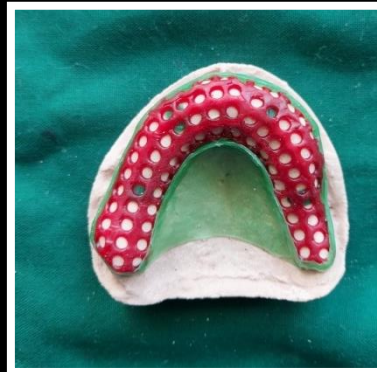DUPLICATION



REFRACTORY CAST



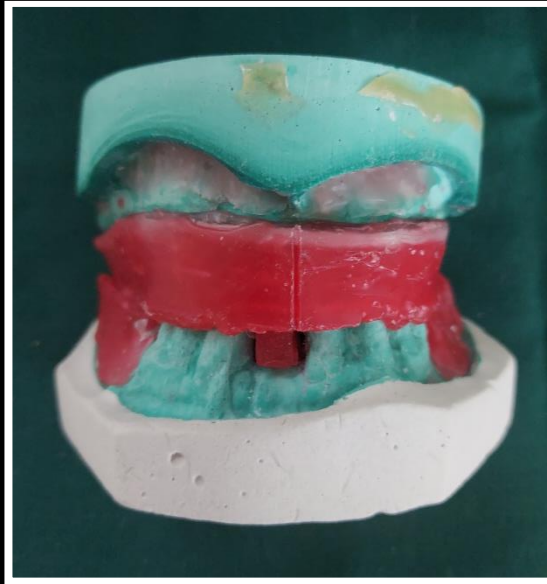WAX PATTERN AND SPRUING



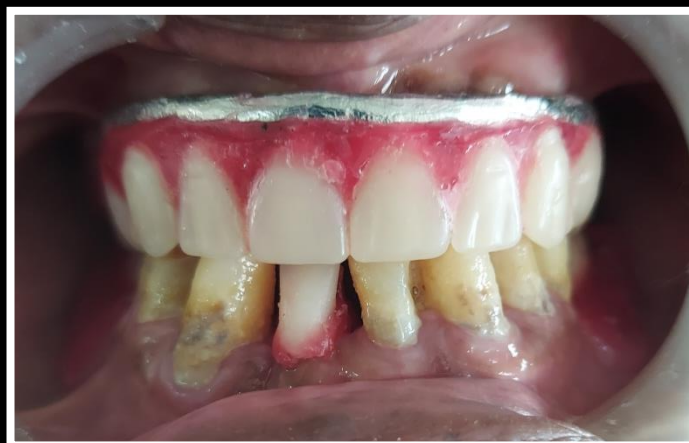METAL BASE



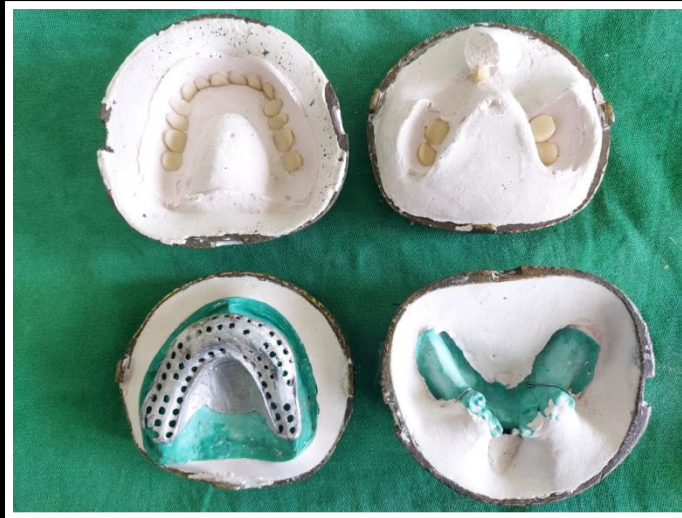JAW RELATION



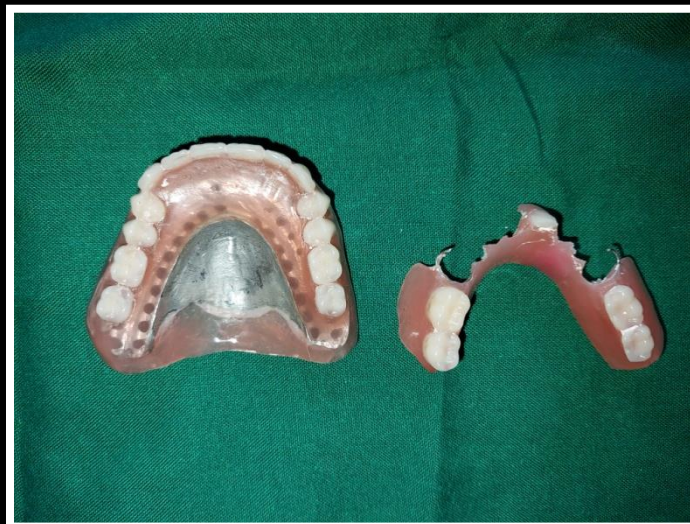
TRY-IN



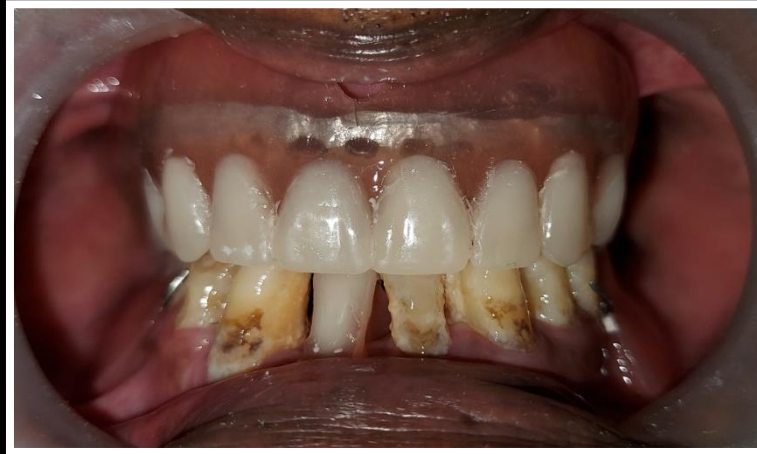PROCESSING



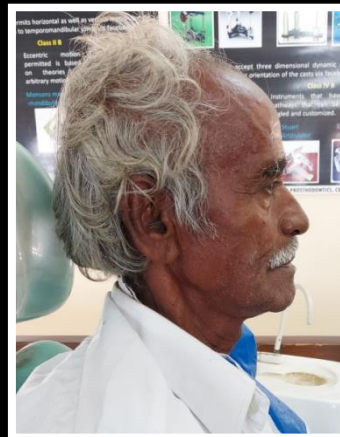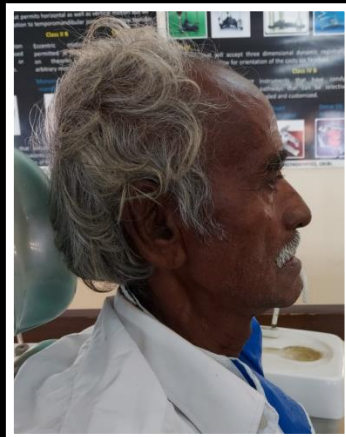FINAL DENTURES



POST-OP



PROFILES PRE-OP AND POST-OP

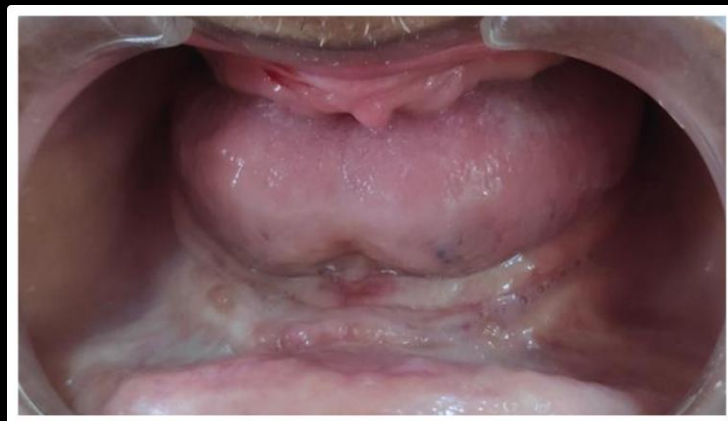
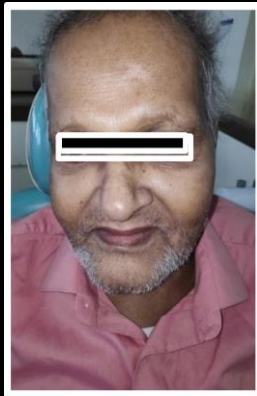
NEUTRAL ZONE

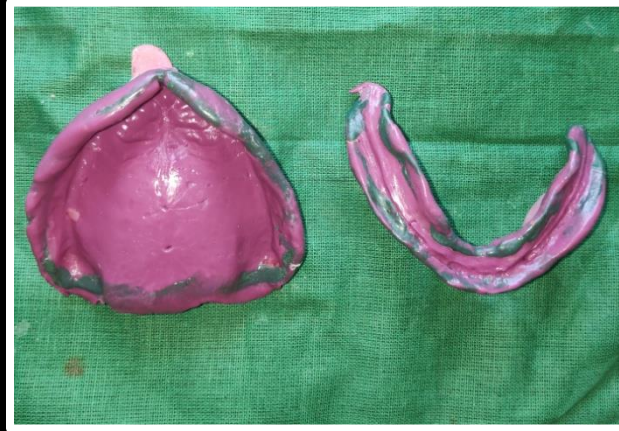Patient name: Mr. Rajasekaran Nair

Age/sex: 66 years / male

POST-OP




SECONDARY IMPRESSION



MASTER CAST



JAW RELATION



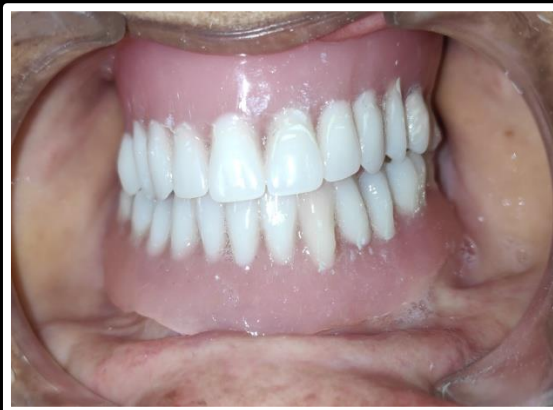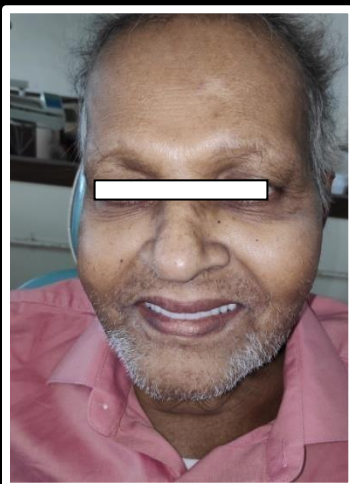NEUTRAL ZONE



INDEX FOR TEETH SETTING



POST OP

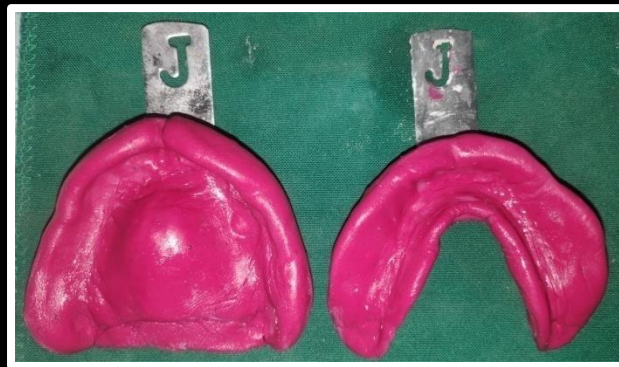

BALANCED OCCLUSION

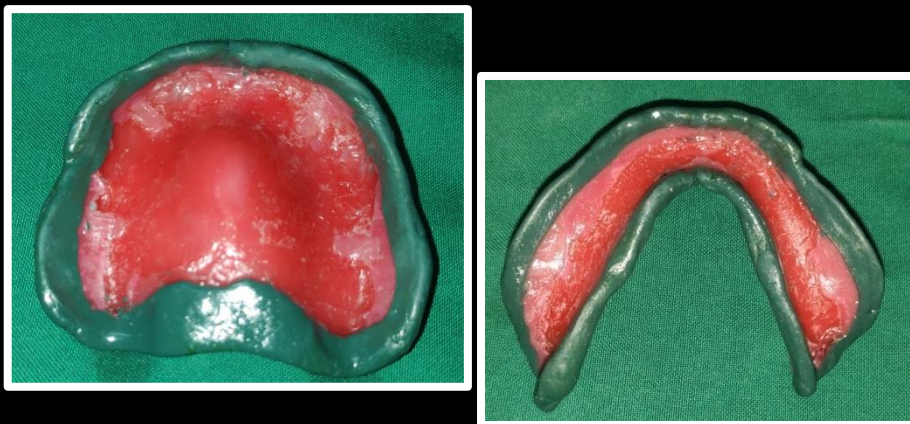
Patient name: Mr. Ganesan

Age/sex: 63 years / male

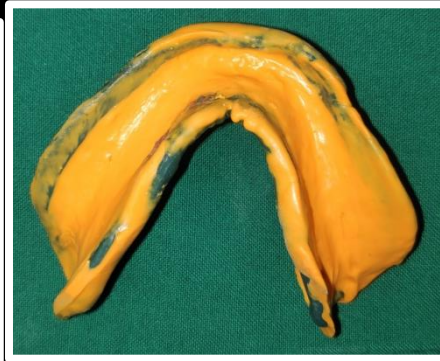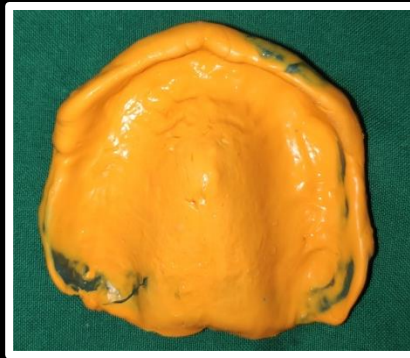PRIMARY IMPRESSION



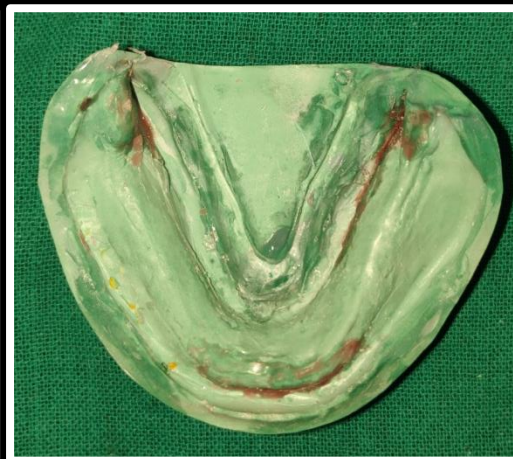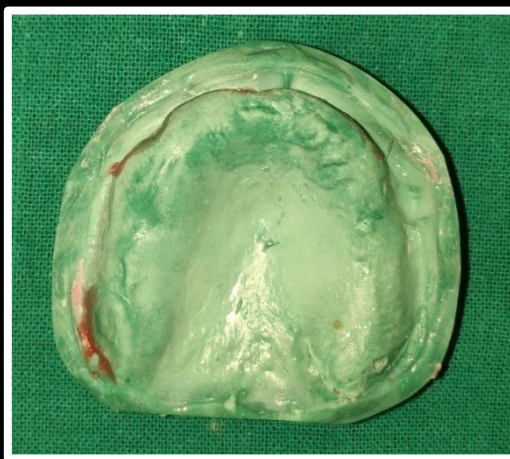BORDER MOLDING



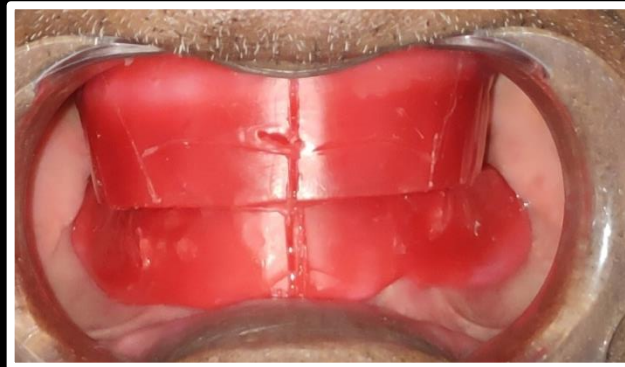
SECONDARY IMPRESSION



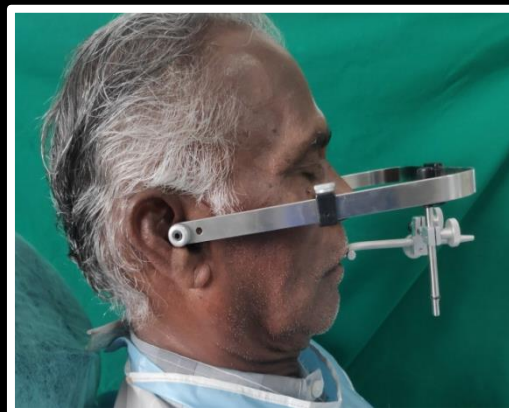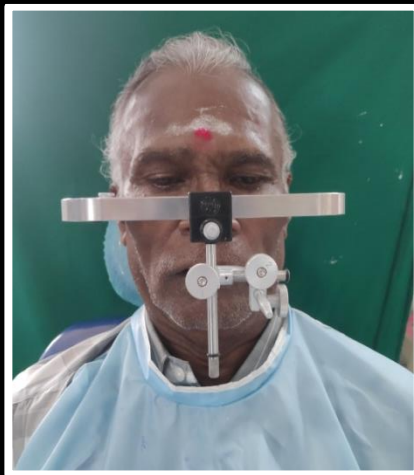MASTER CAST



TENTATIVE CENTRIC



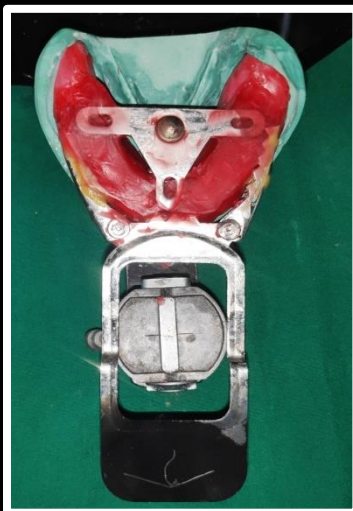
FACE BOW TRANSFER



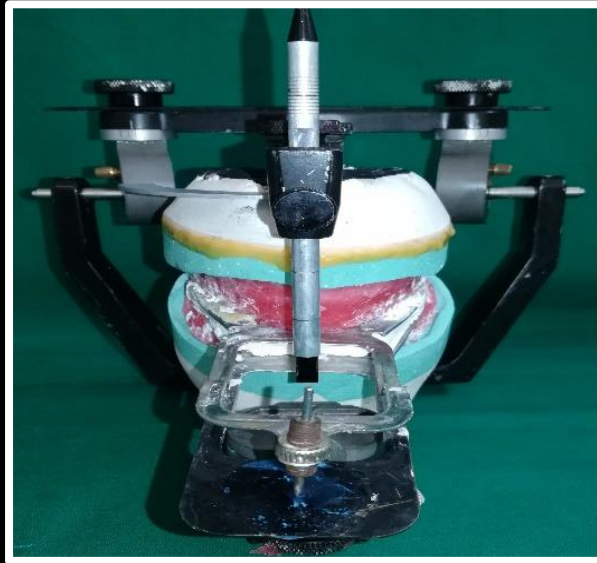FACE BOW TRANSFER



GOOTHIC ARCH TRACING



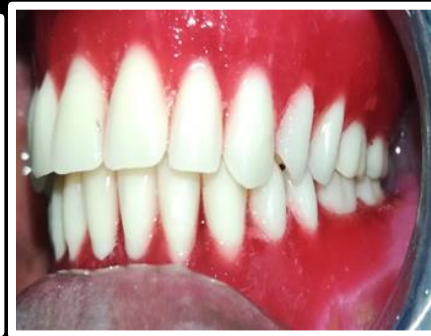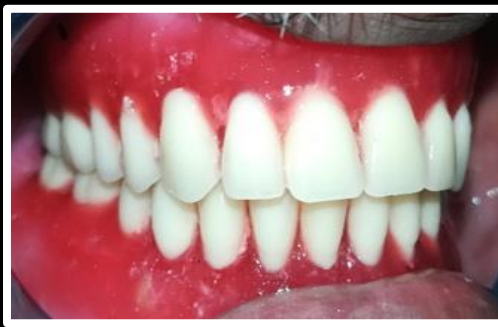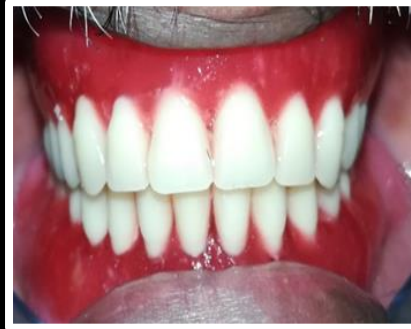INTEROCCLUSAL RECORDS



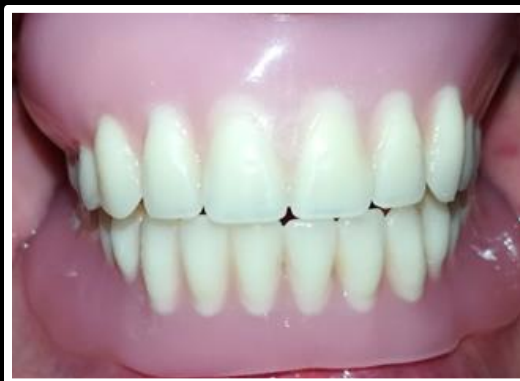TEETH SETTING

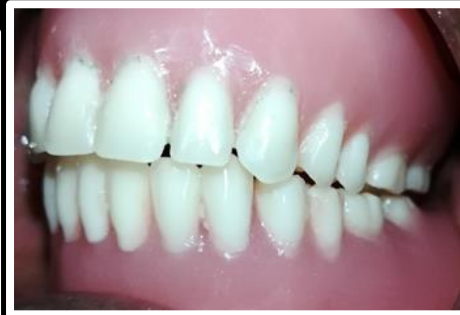
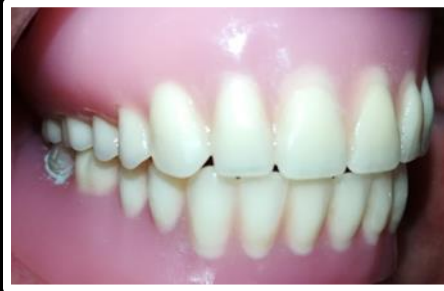
TRY-IN

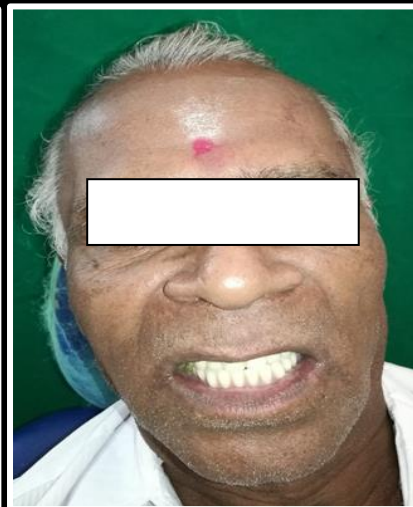
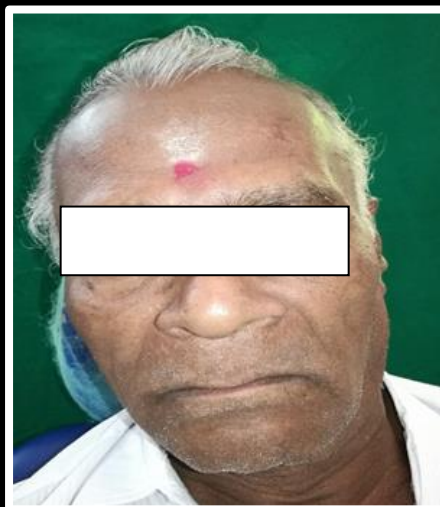
DENTURE INSERTION





PRE-OP AND POST-OP

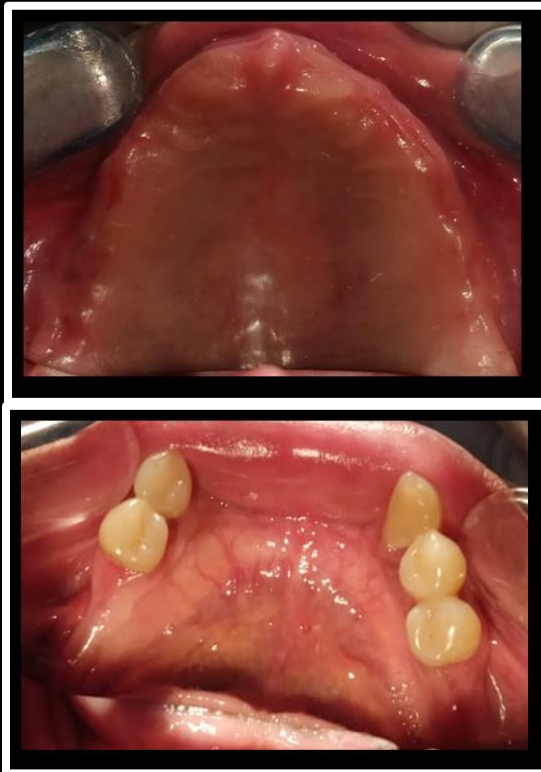

PRECISION ATTACHMENT SUPPORTED CAST PARTIAL DENTURE

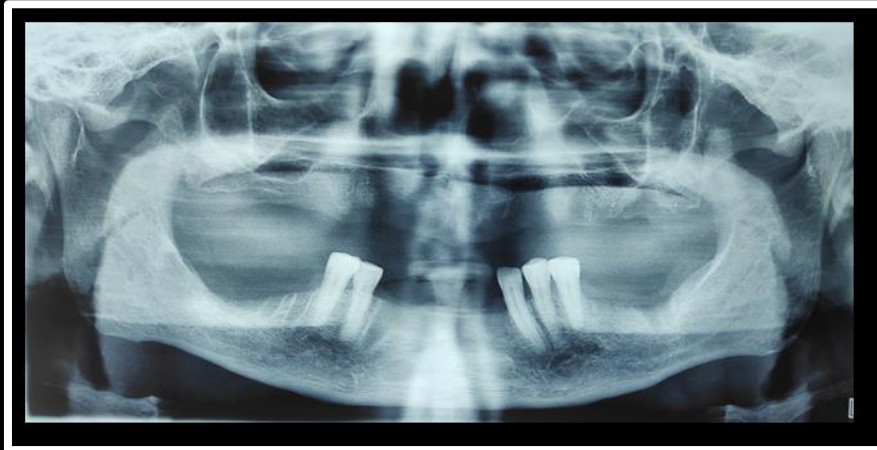Patient name: Mrs. Rajeshwari

Age/sex: 32years / female

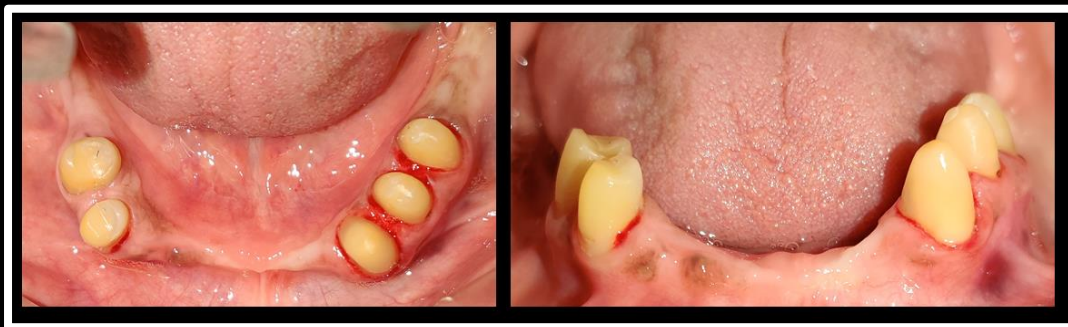
PRE-OP



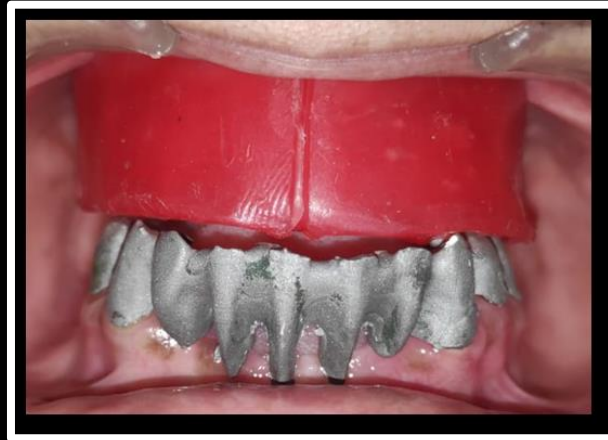X-RAY



TOOTH PREPARATION



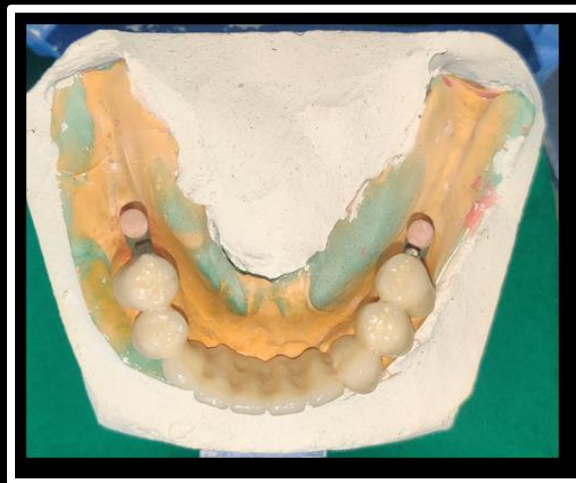METAL TRY-IN ALONG WITH BITE REGISTRATION



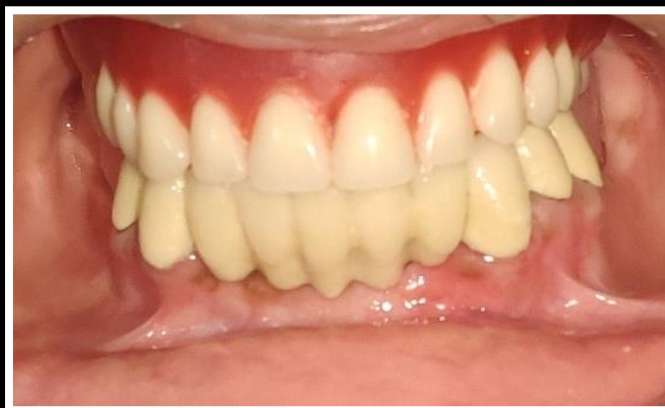TEETH SETTING



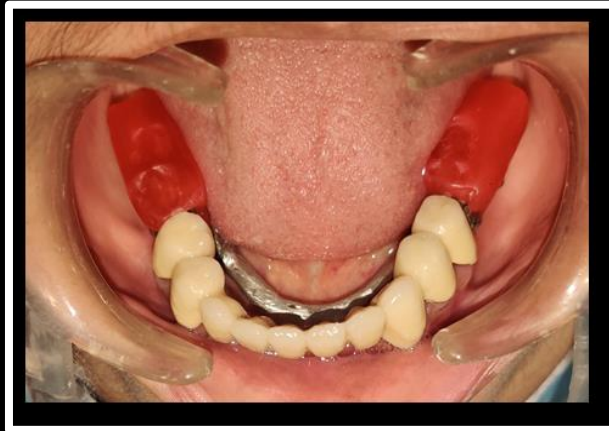PFM WITH PRECISION ATTACHMENT



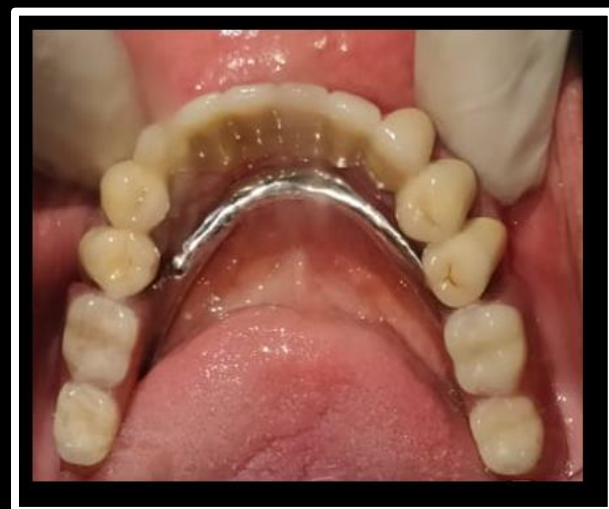TRY-IN



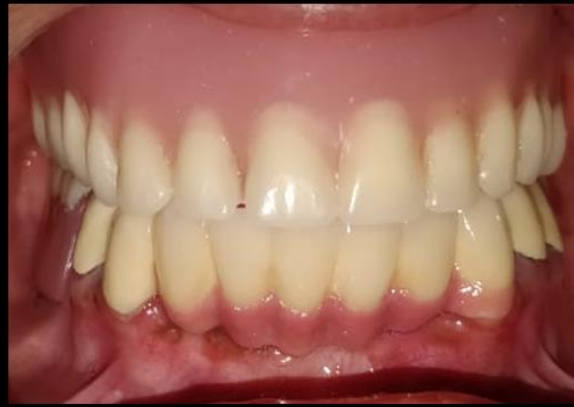BITE REGISTRATION



CAST PARTIAL DENTURE TRY-IN



POST-OP

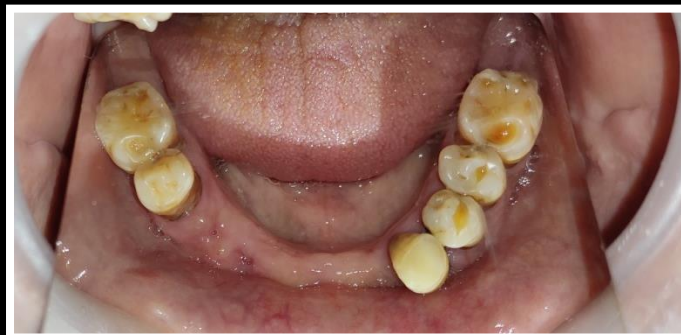
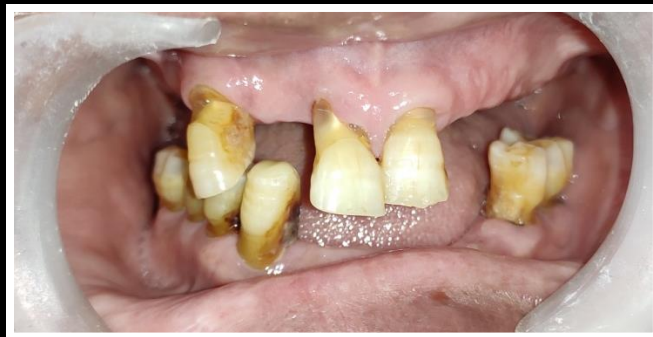
TOOTH SUPPORTED OVERDENTURE

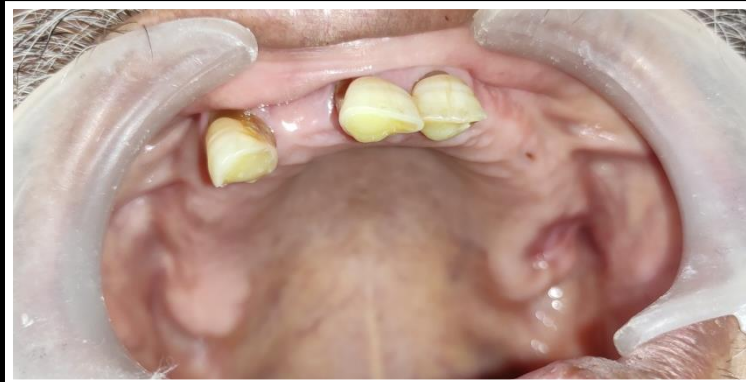Patient name: Mr. Prem singh

Age/sex: 69 years / male

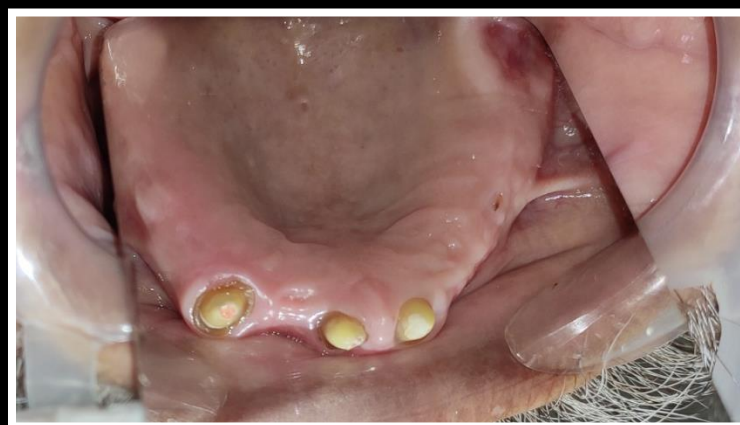PRE-OP



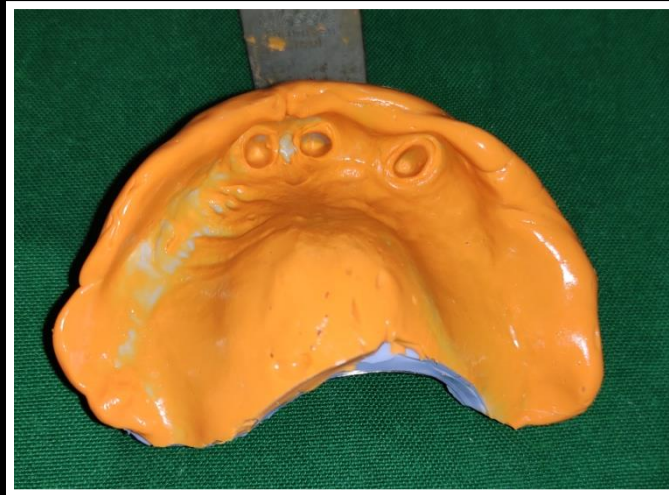POST ENDO TREATMENT



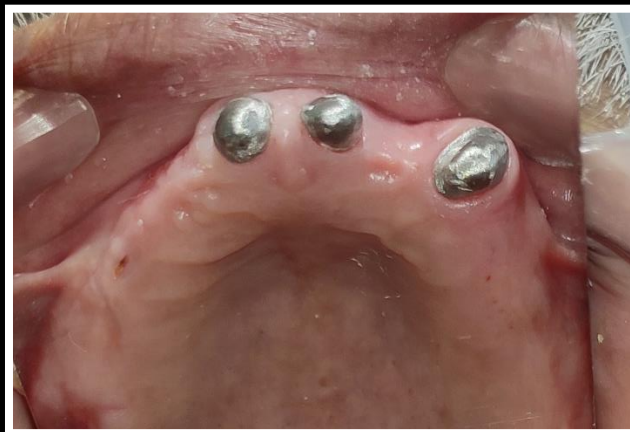PREPARATION



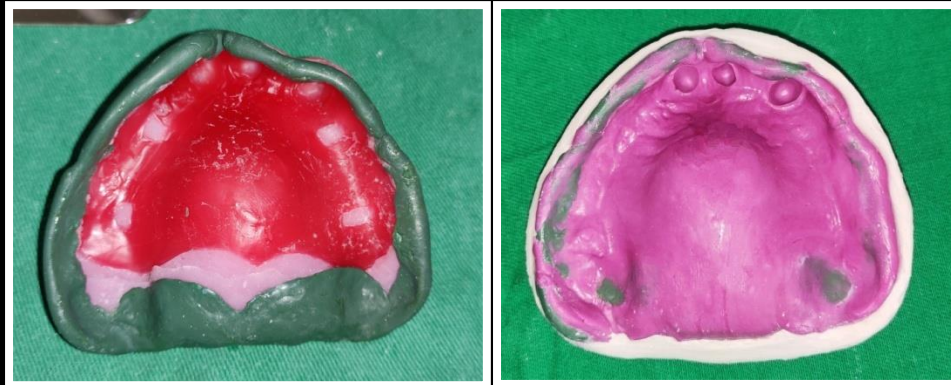
IMPRESSION



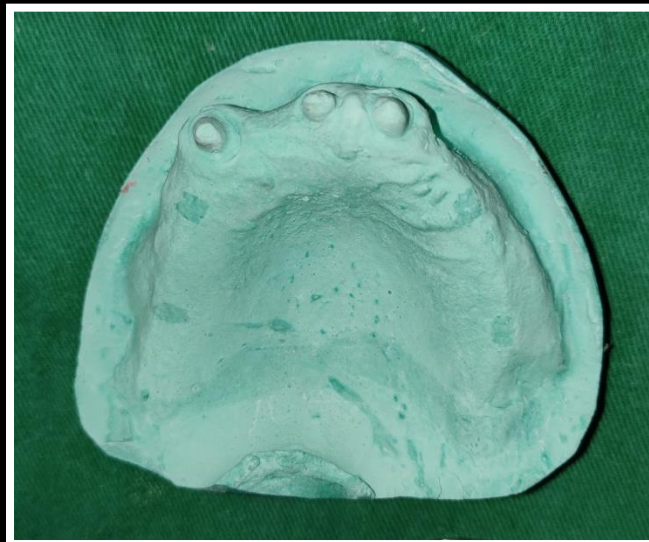COPINGS



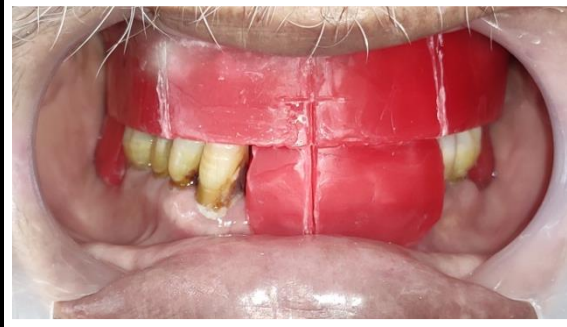
SECONDARY IMPRESSION



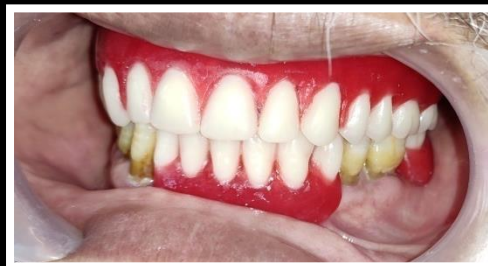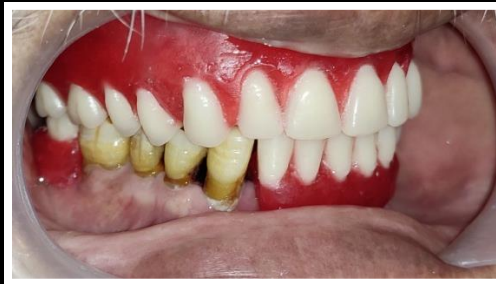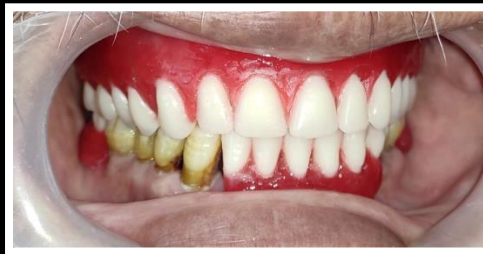MASTER CAST



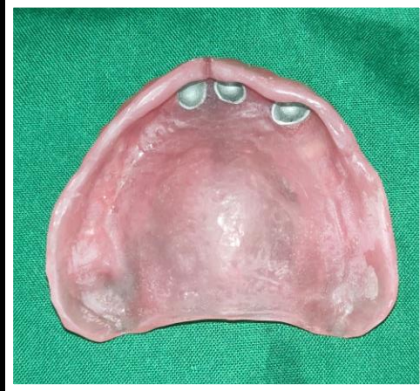BITE REGISTRATION



TRY-IN



PROCESSED DENTURE



POST-OP

