



**Chettinad**

Dental College & Research Institute

# DEPARTMENT OF PERIODONTICS

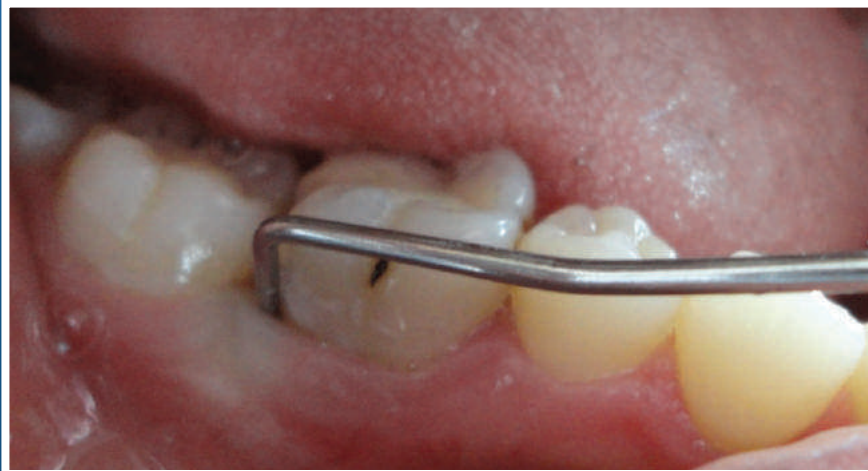# CASE ALBUM

## **BONE GRAFTING**

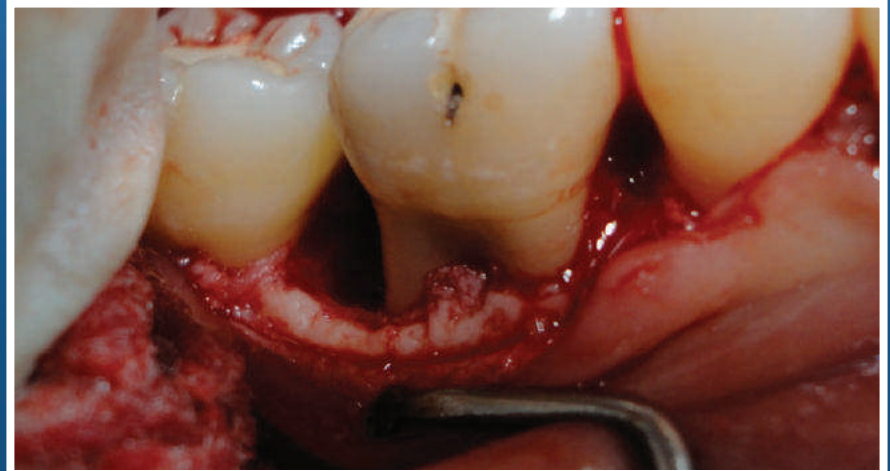
Patient Name: **MRS.MALIGA**

Age/Sex : **31Y/F**

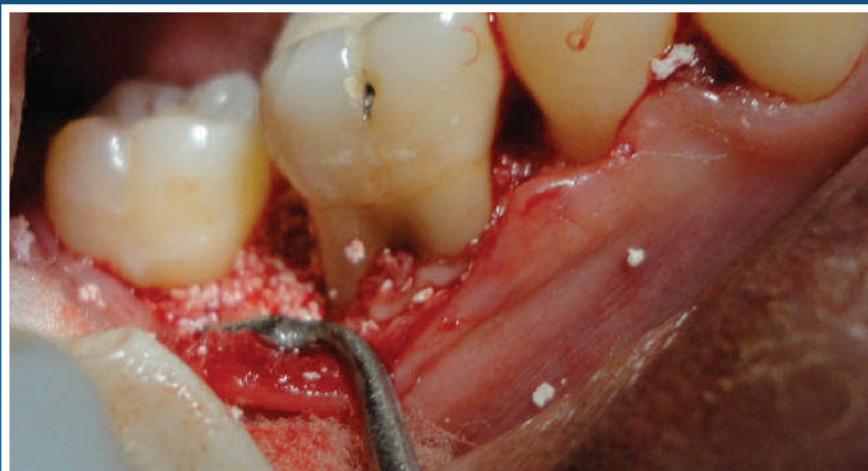Op No : **201704120123**



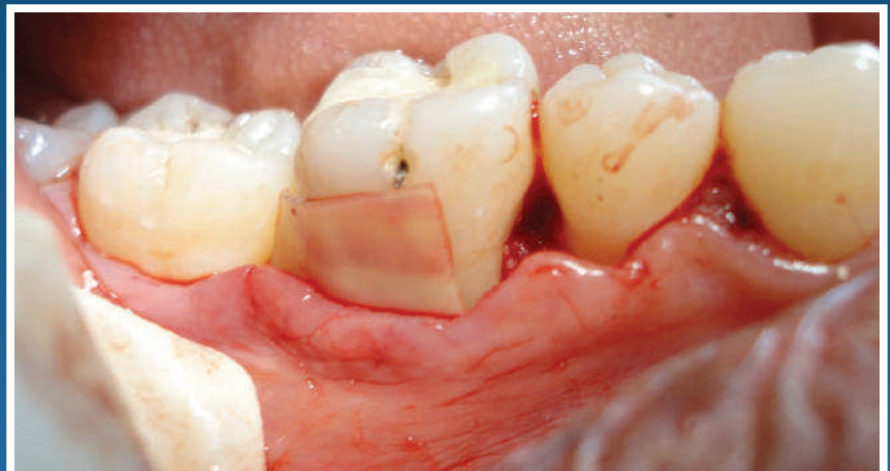Preoperative – Probing depth of 10 mm



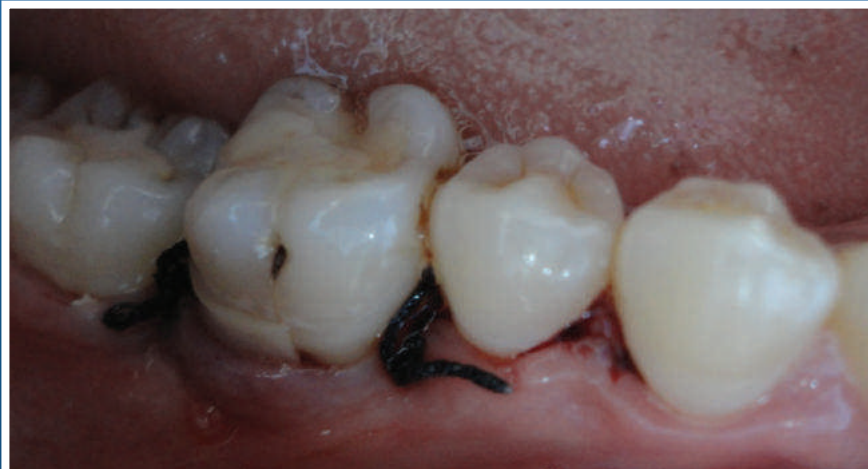Intrabony defect with grade II furcation involvement in 46



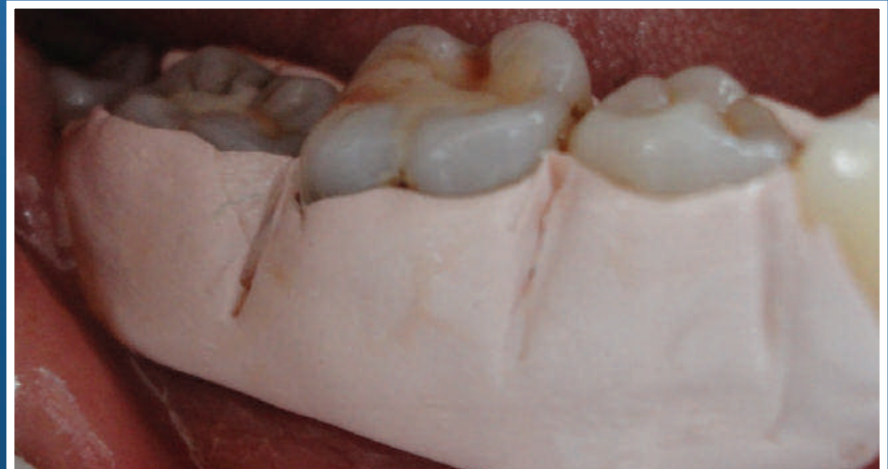Bone grafting done with Bonemedik in 46



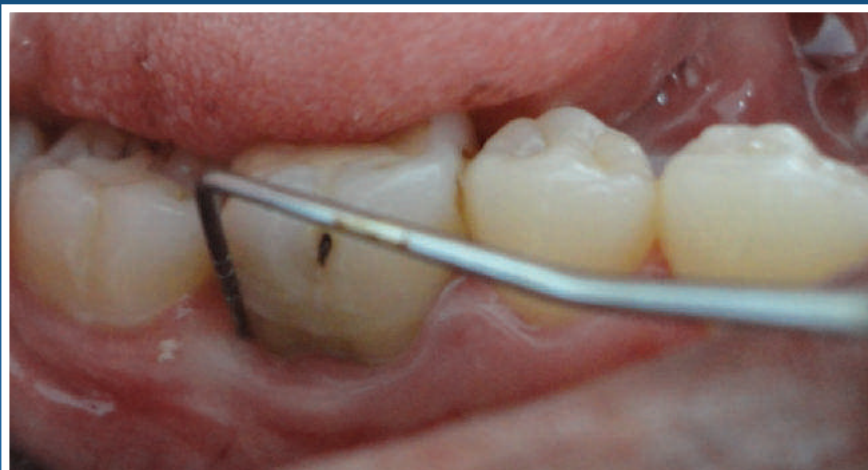GTR membrane



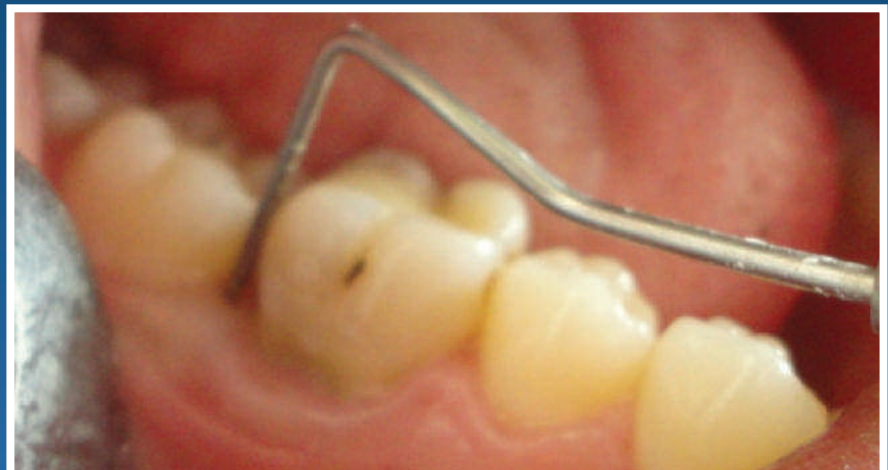After suturing



After placing periodontal pack

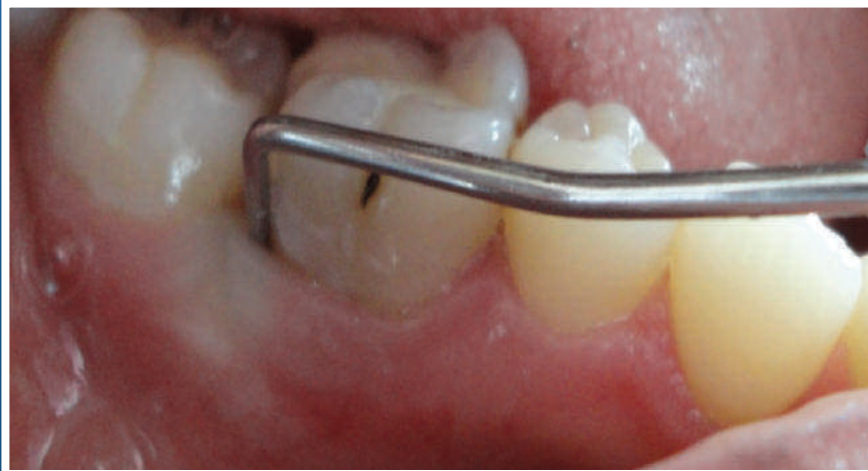

Postoperative – Three months with reduction of probing depth to 4mm in 46

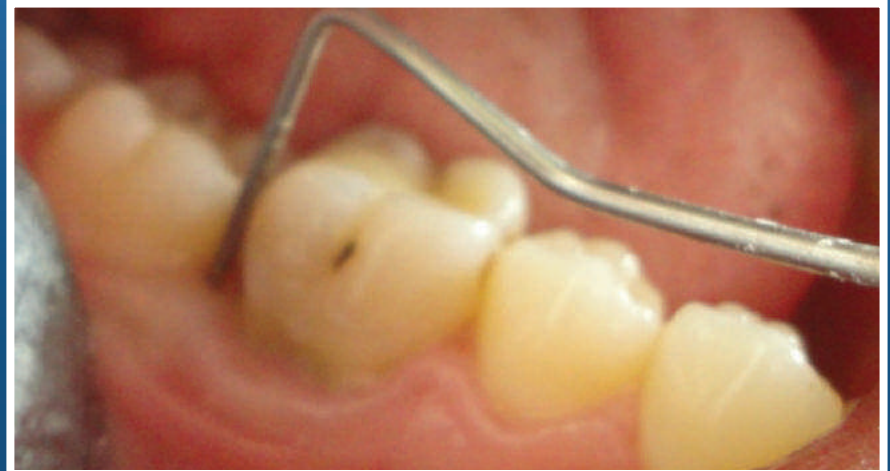

Postoperative – Six months with reduction of probing depth to 3mm in 46





Preoperative



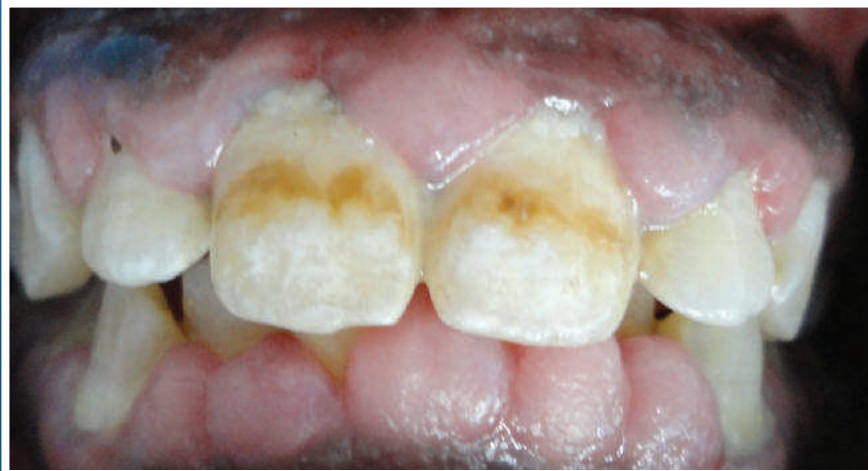Postoperative

## **PHASE I THERAPY & DRUG SUSTITUTION**

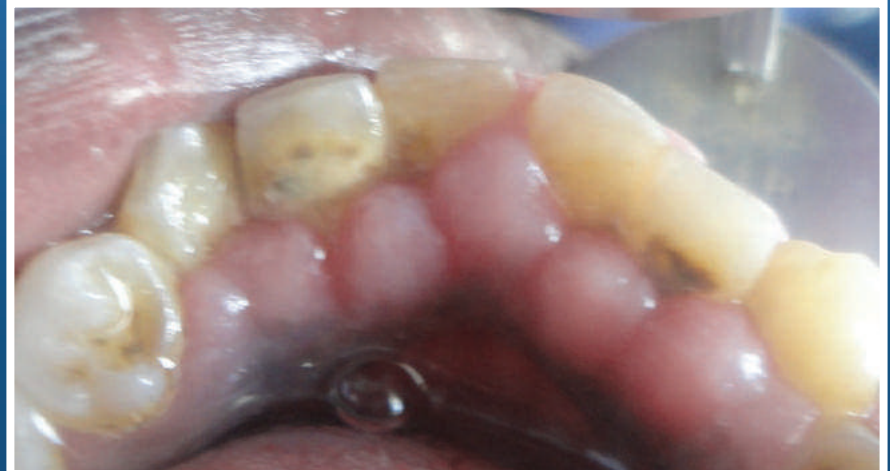Patient Name: **MR.CHANDRAN**

Age/Sex : **51Y/M**

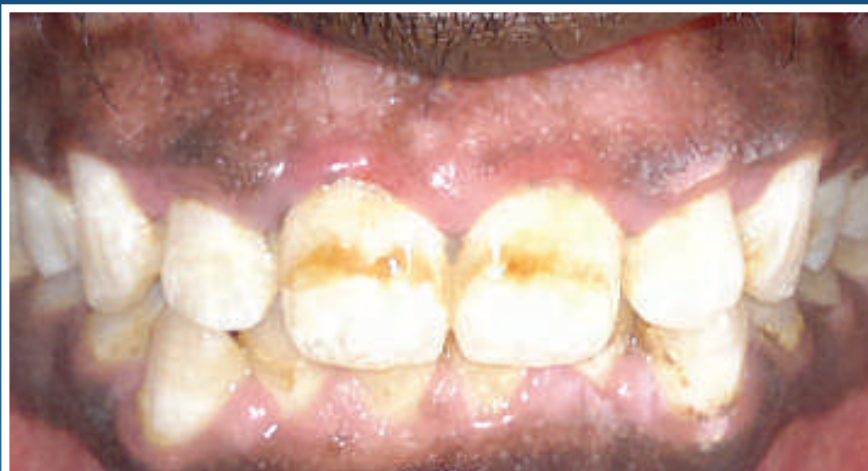Op No : **201704260039**



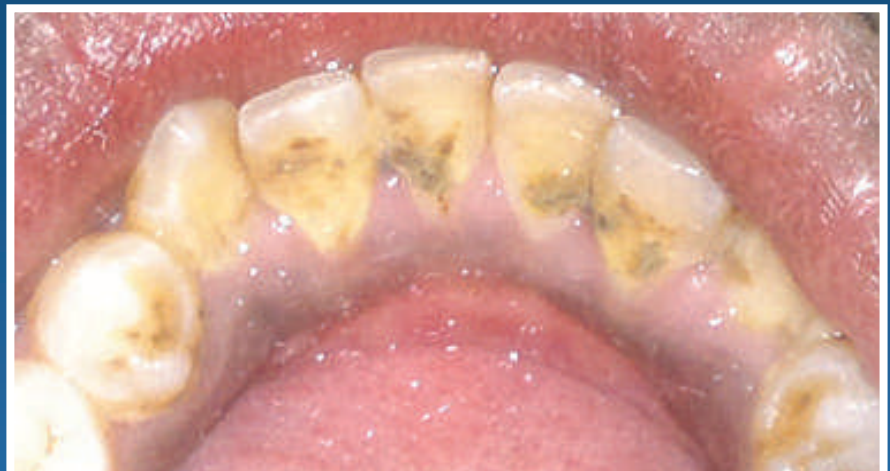Preoperative - Labial



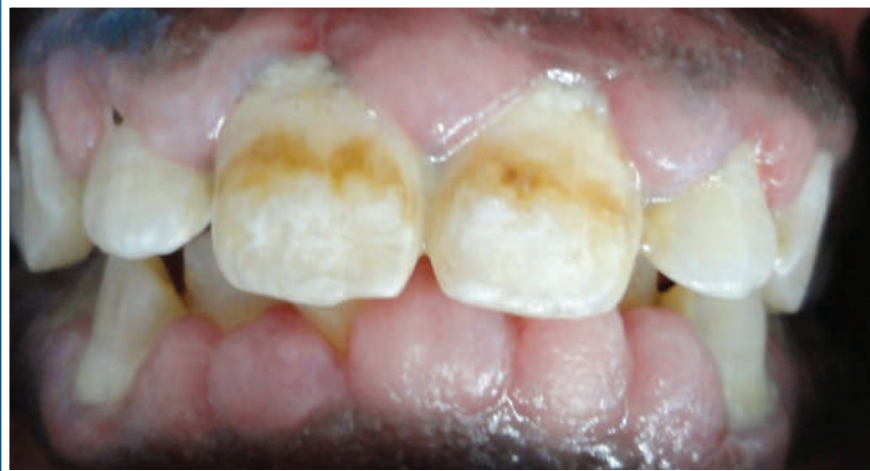Preoperative - Lingual



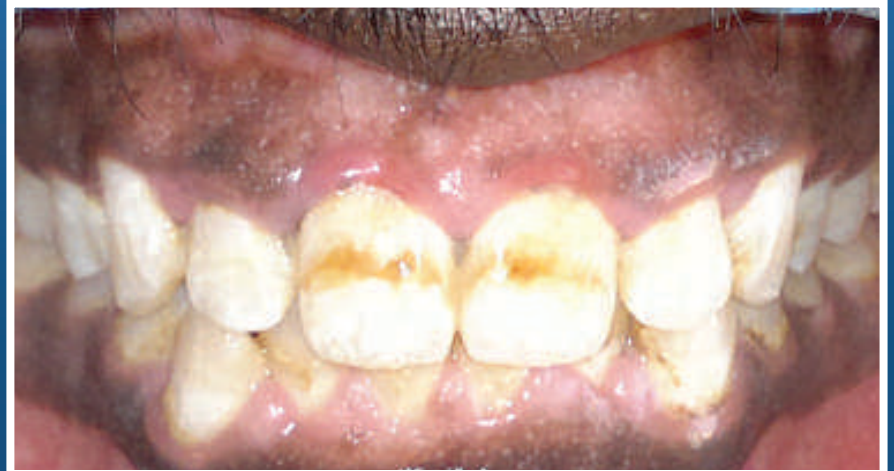Postoperative - Labial aspect After Drug substitution  
and Phase I therapy



Postoperative - Lingual aspect After Drug substitution  
and Phase I therapy



Preoperative



Postoperative

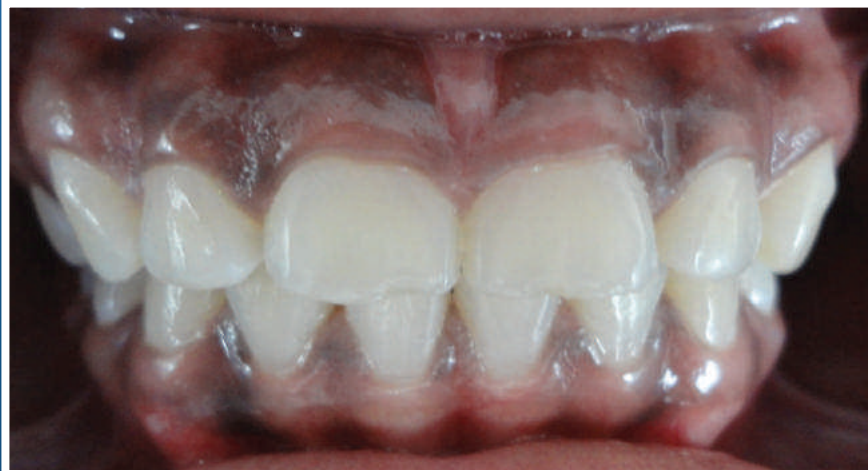

# **CROWN LENGTHENING & GINGIVAL DEPIGMENTATION**

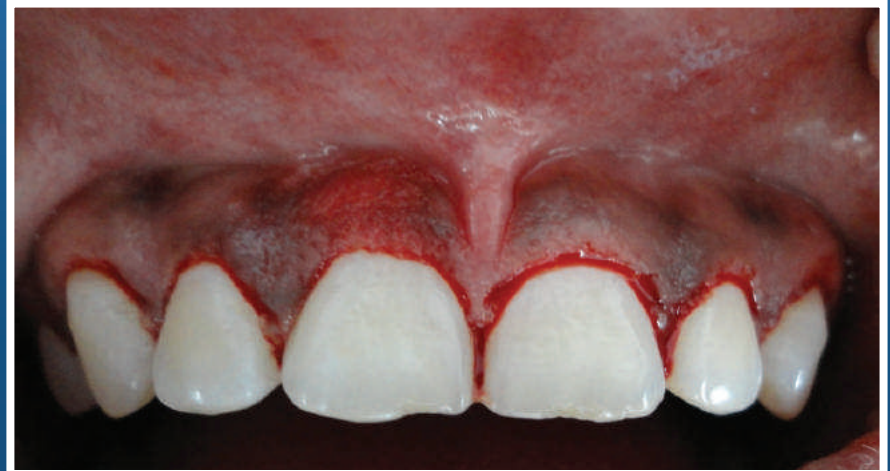Patient Name: **MRS.VASUNTHA**

Age/Sex : **28Y/F**

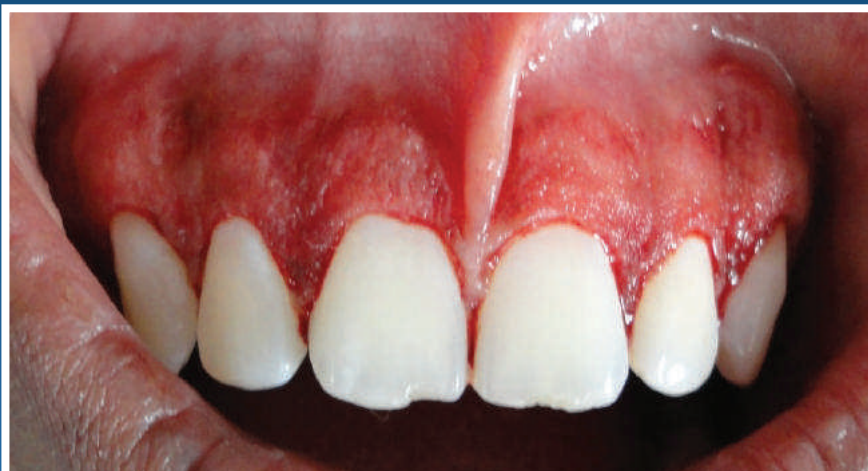Op No : **201704290030**



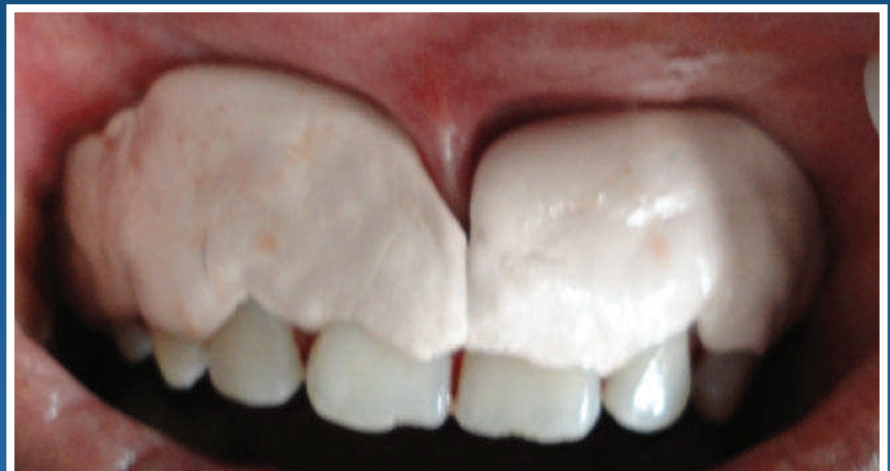Incomplete gingival retreat in relation to upper anteriors



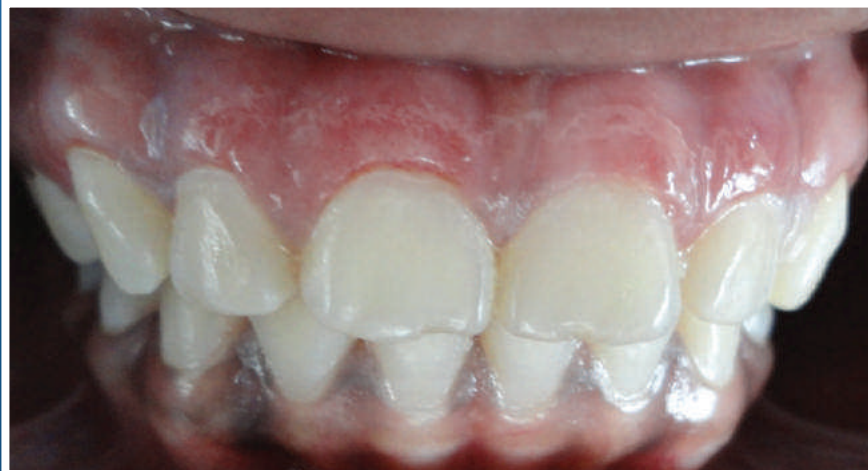Immediate postoperative view after crown lengthening



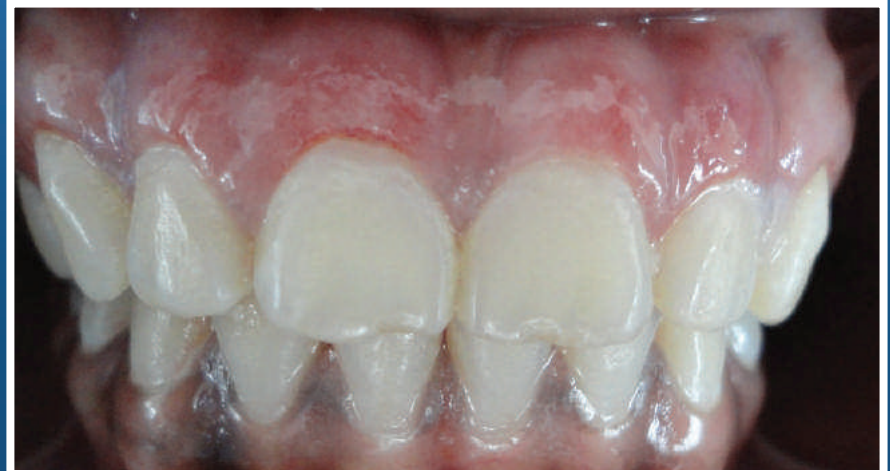After Gingival depigmentation - Scalpel method



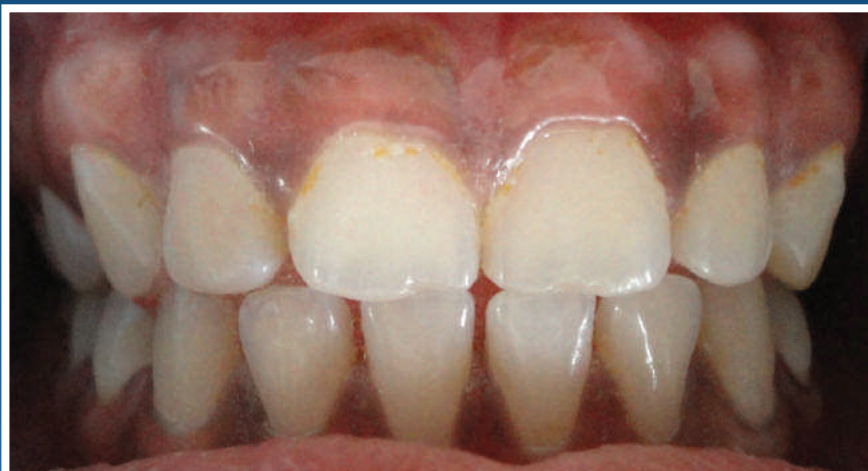After Placement of Periodontal pack



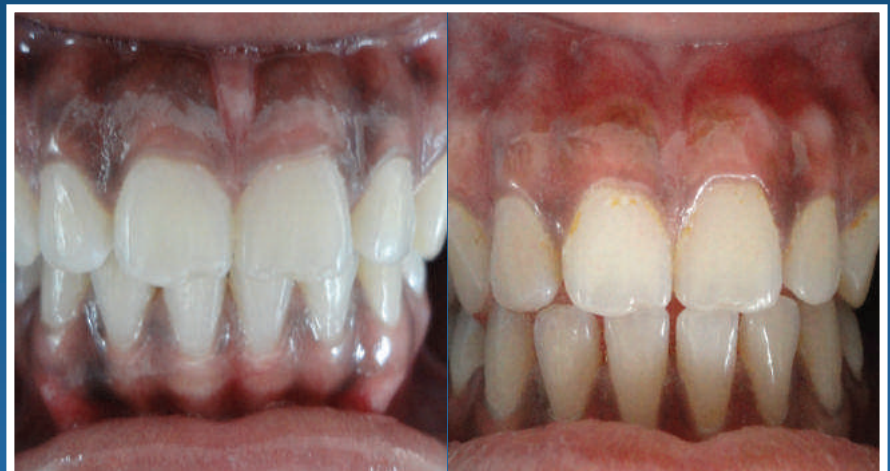Incomplete gingival retreat in relation to upper anteriors



Postoperative - one month



Postoperative - six months



Preoperative

Postoperative

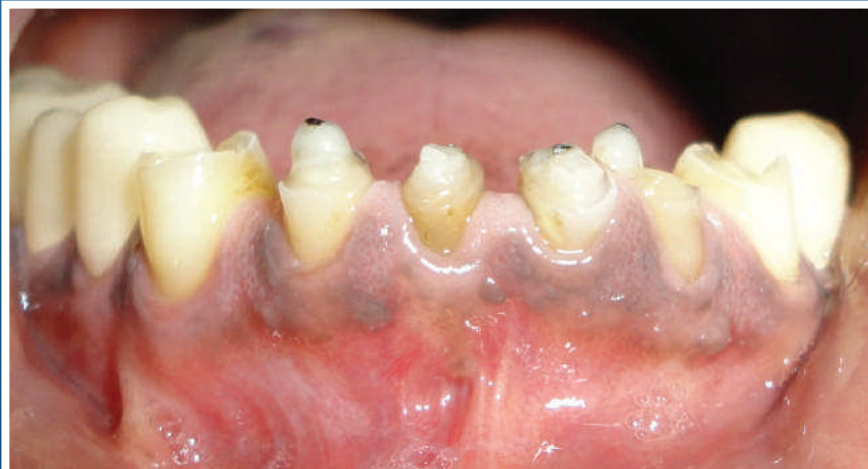## **CROWN LENGTHENING**

Patient Name: **YASAR ALI**

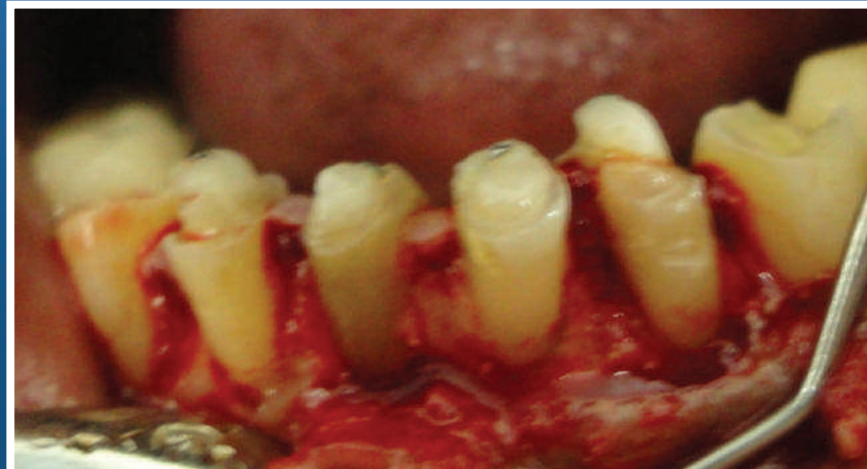Age/Sex : **25Y/M**

Op No : **201603150030**

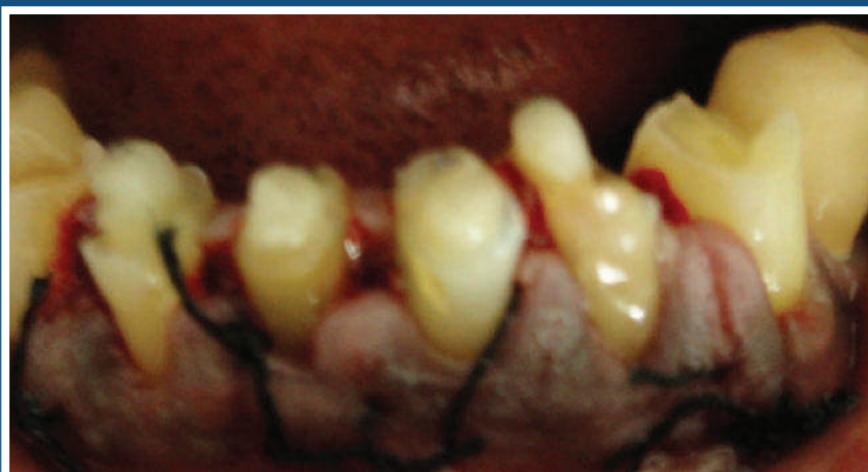



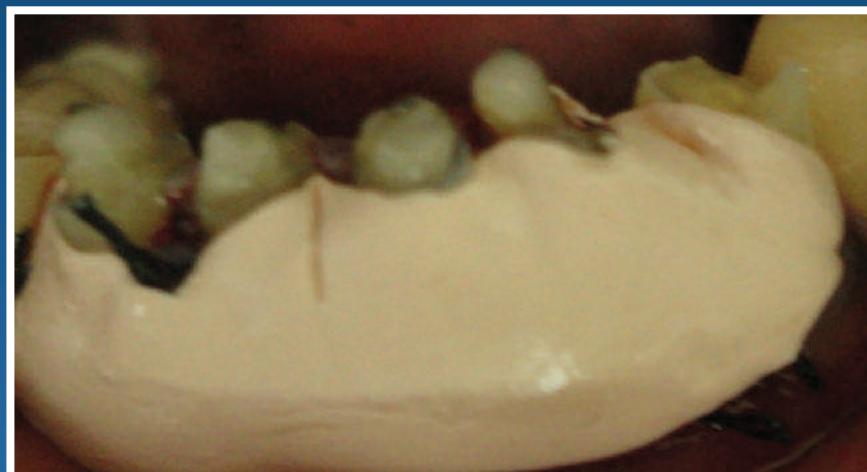Preoperative - Inadequate crown length in 31,32,41,42



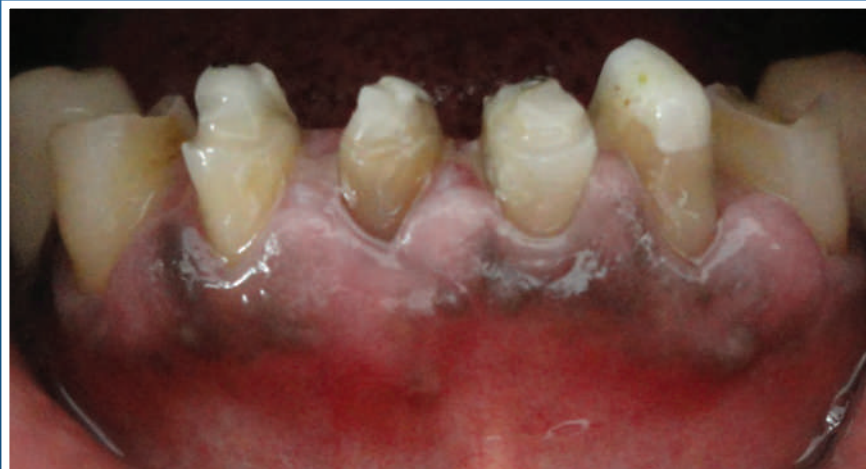After Flap elevation and Osseous recontouring



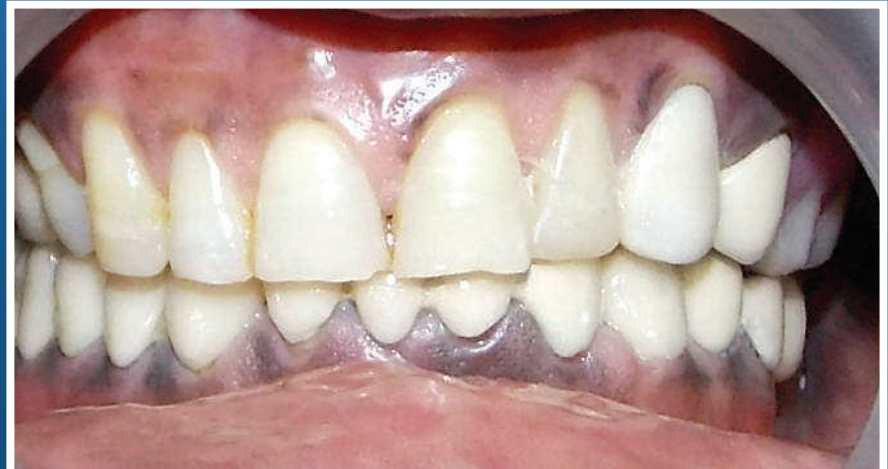After suturing



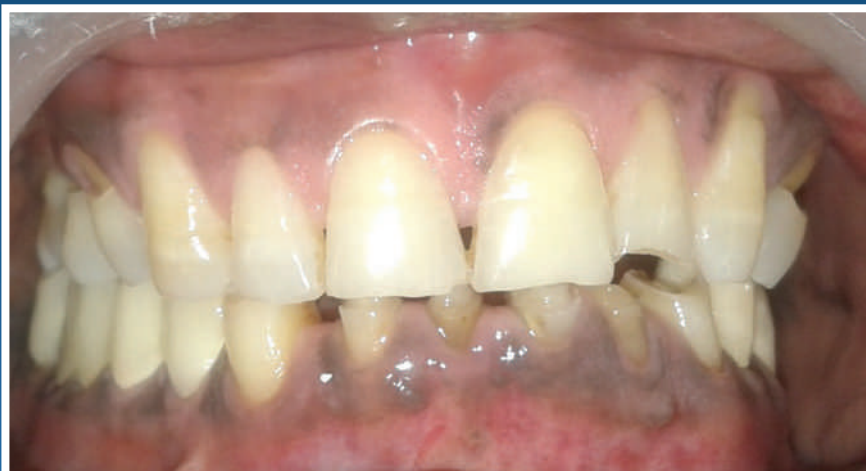After placing Periodontal pack



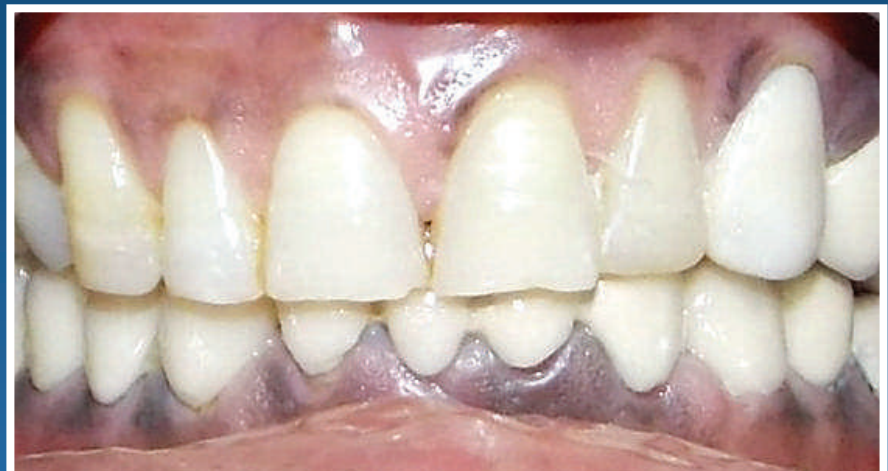Postoperative - Two weeks



After FPD



Preoperative



Postoperative

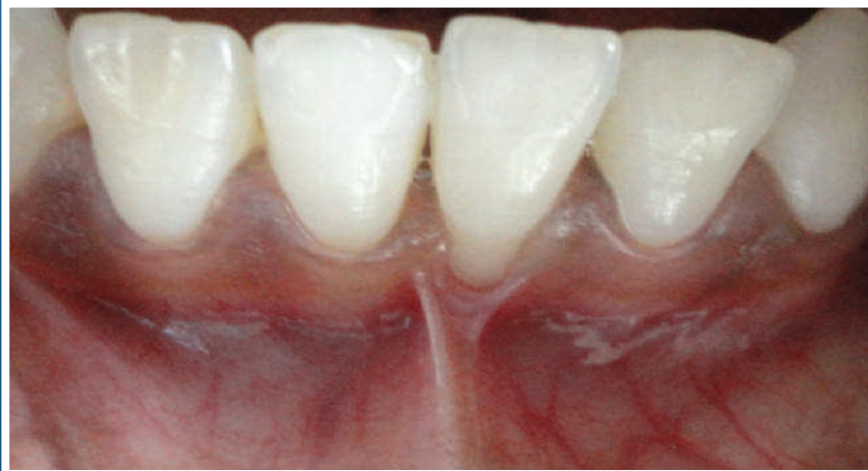# **MILLERS CLASS I GINGIVAL RECESSION FREE GINGIVAL AUTOGRAFT WITH LASERS**

Patient Name: **MR.PUTHIYARAJ**

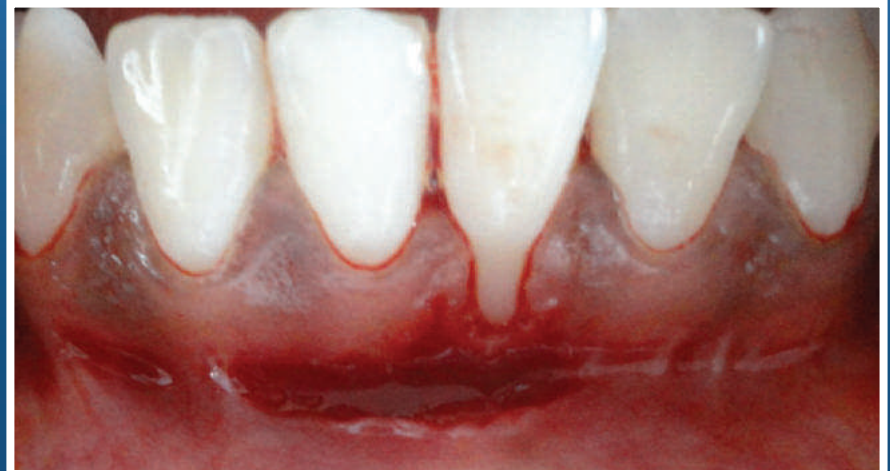Age/Sex : **35Y/M**

Op No : **201605120005**

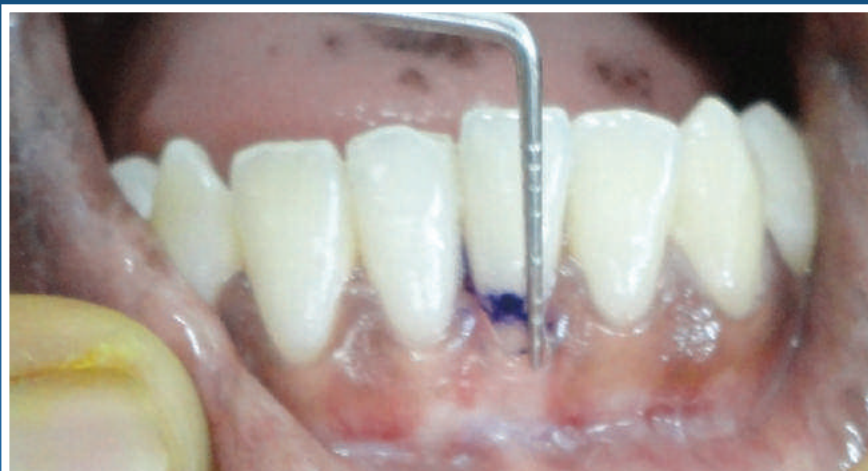



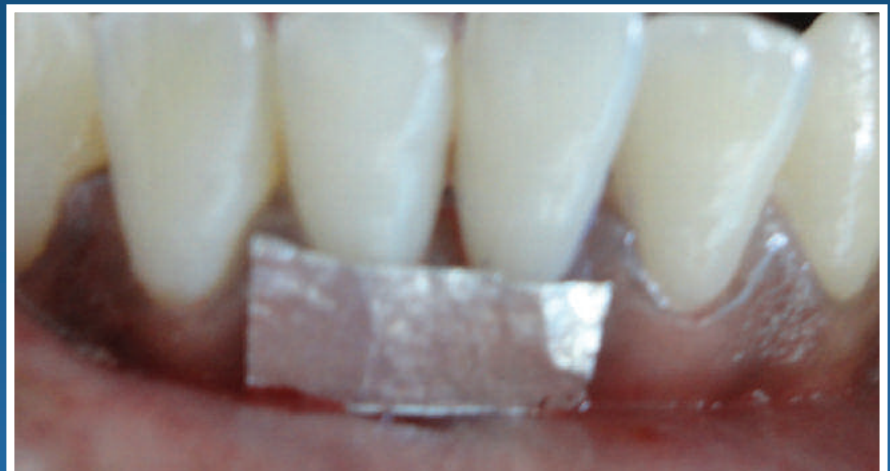Preoperative Highly placed labial frenum with tissue tension & recession of 3mm in 31



Frenotomy done under local anaesthesia

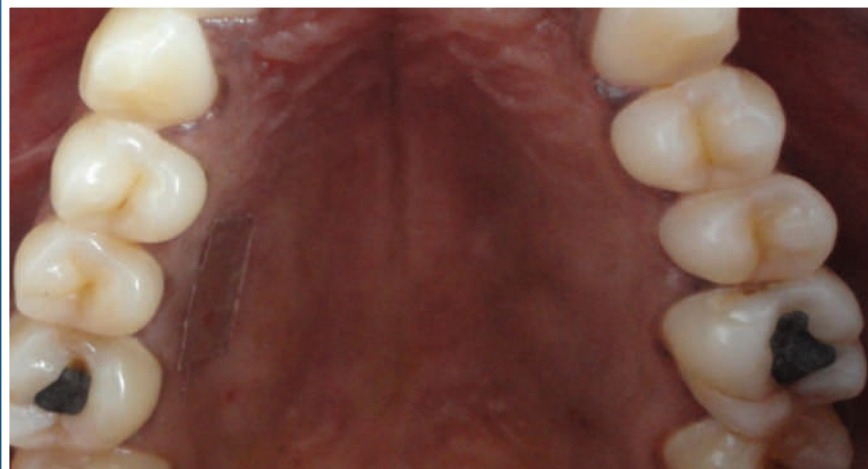

After Frenotomy with recession of 3 mm in 31

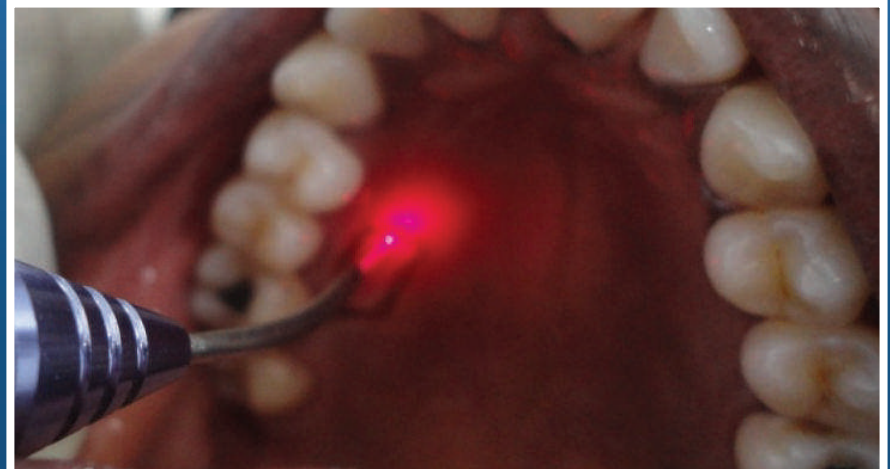


Template placed in recipient site

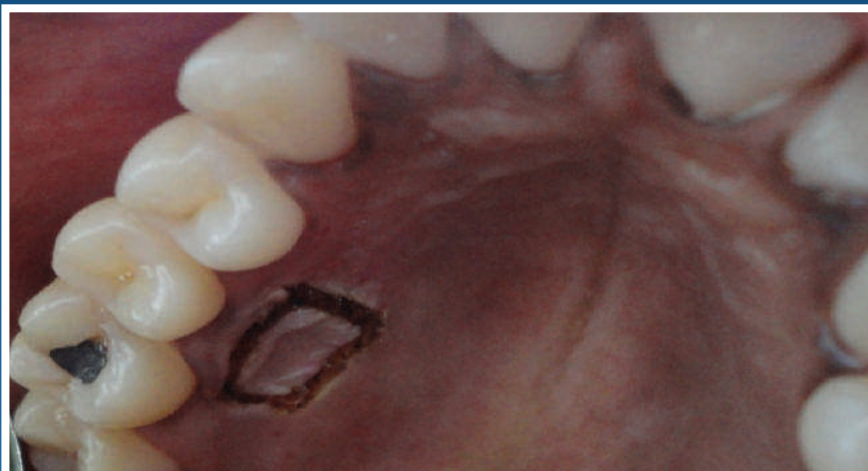



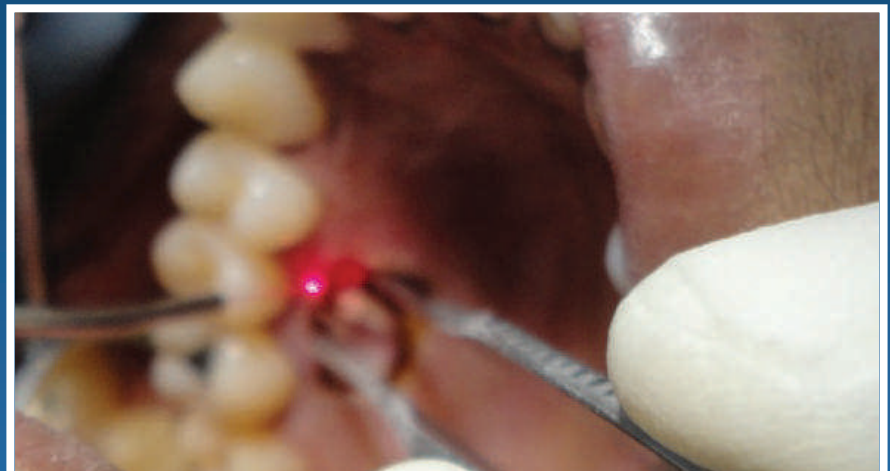Measured Template placed in Donor site - 14, 15, 16



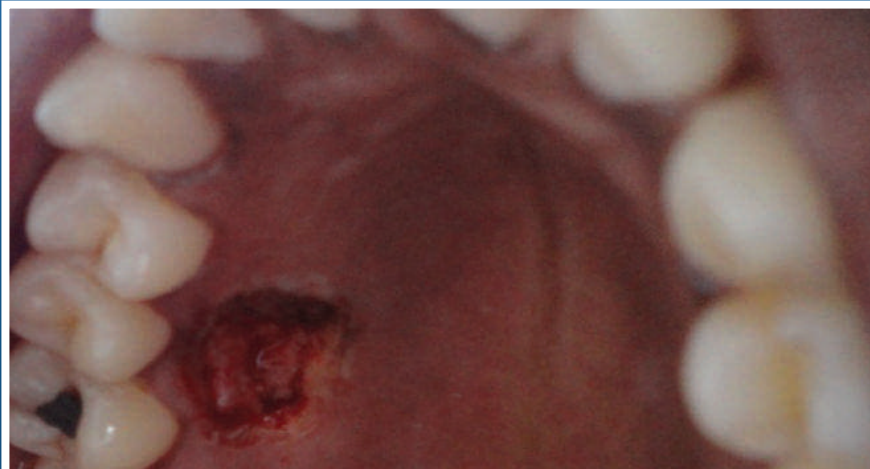
Marking the borders of Donor site with Diode Laser



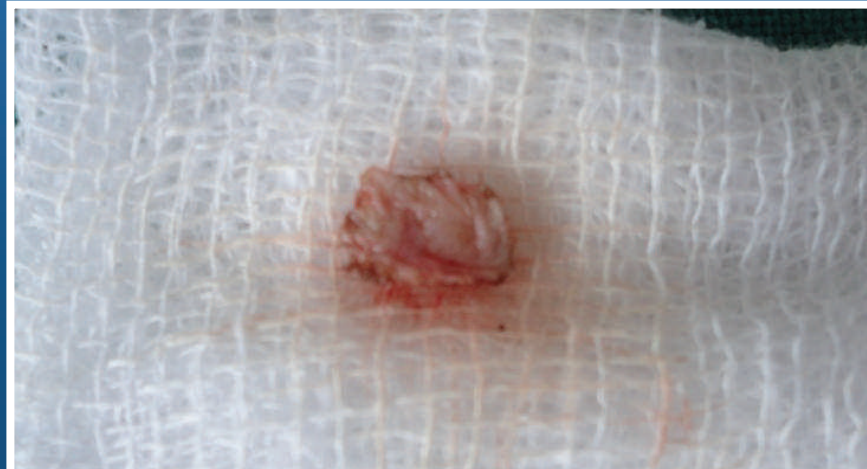
After marking the borders with Diode laser



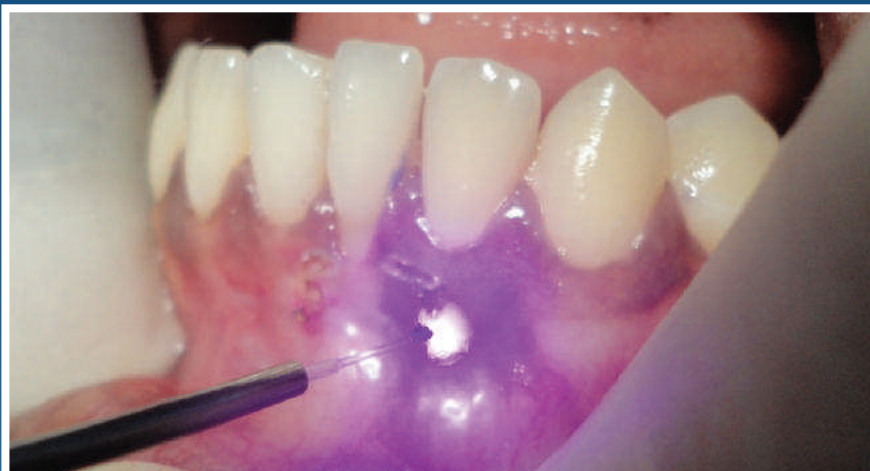Removal of the Autograft



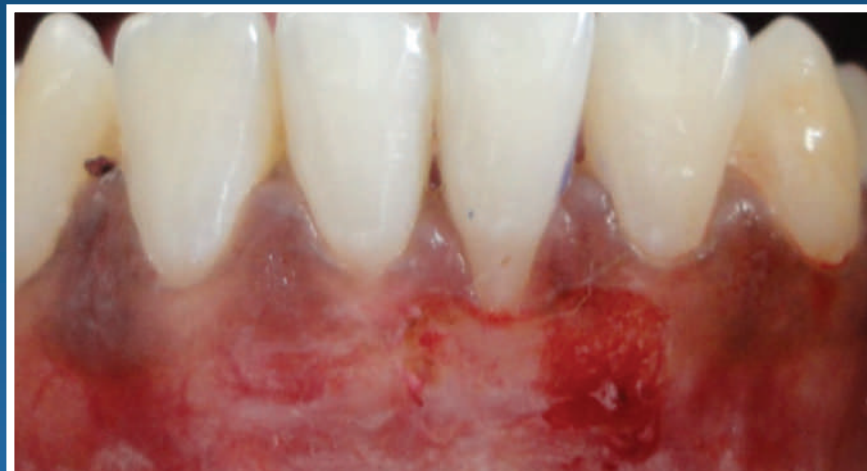After excising the graft



Harvested graft from palate

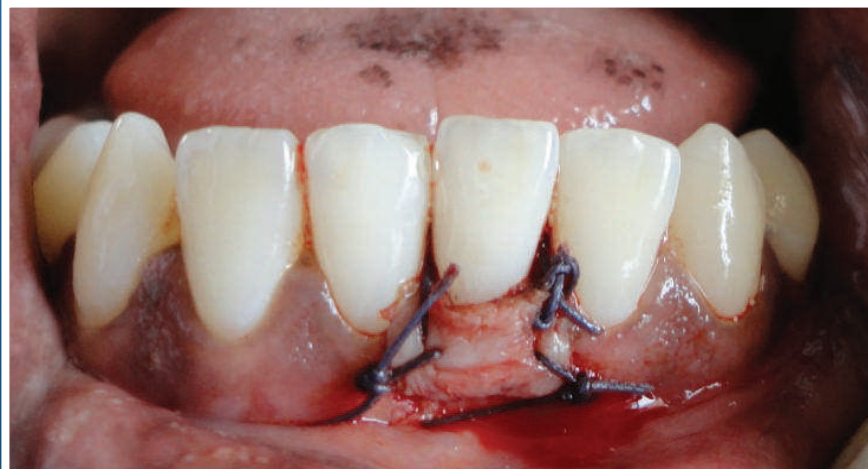

Preparation of recipient site with Diode laser

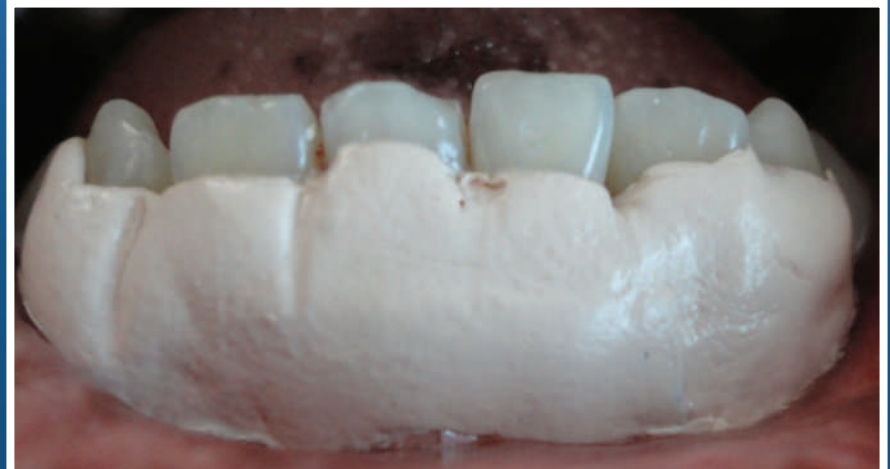

Prepared recipient site

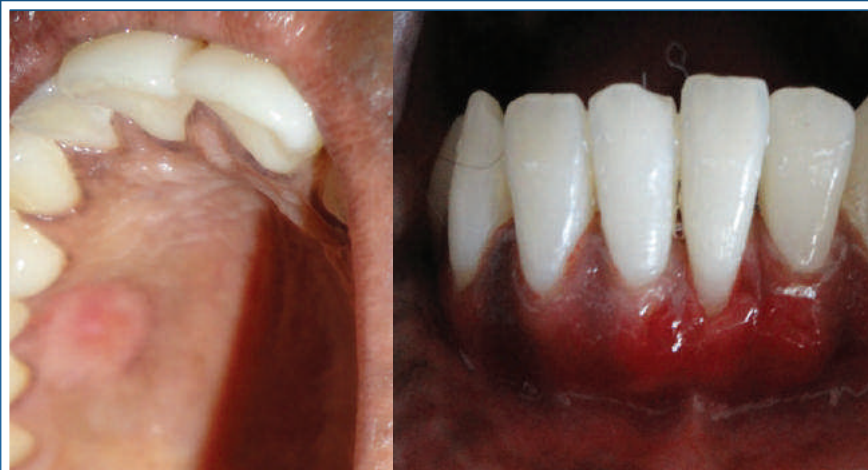



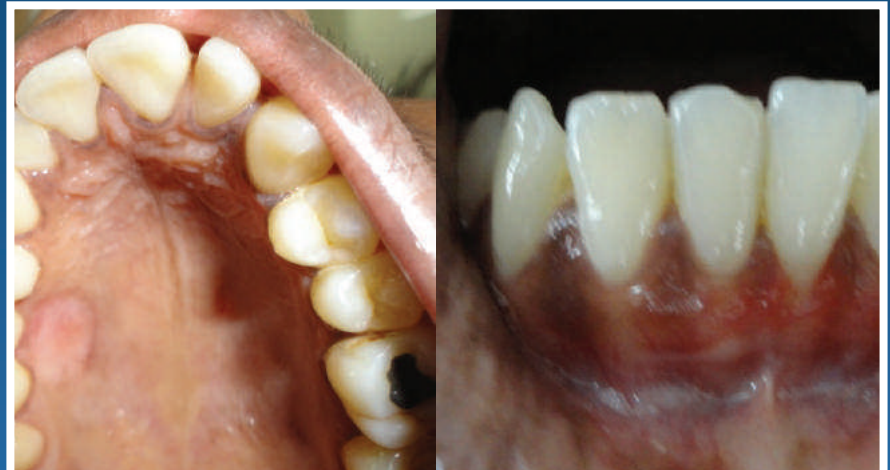Graft sutured in the recipient site



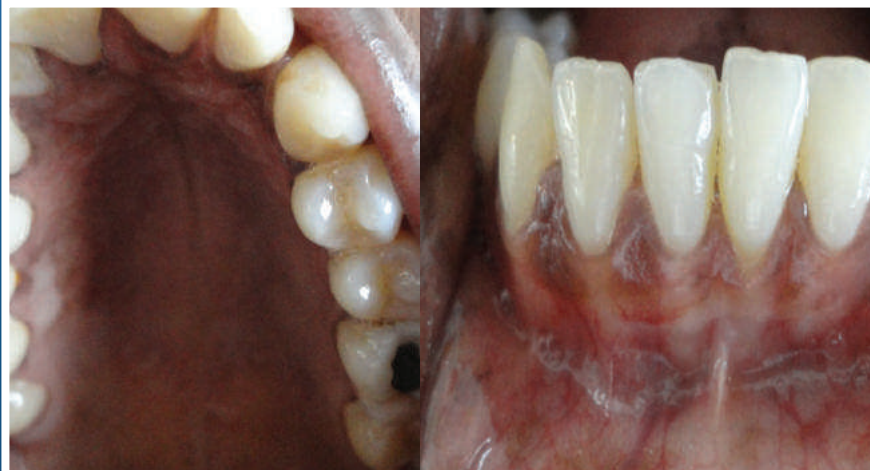After placing Periodontal pack



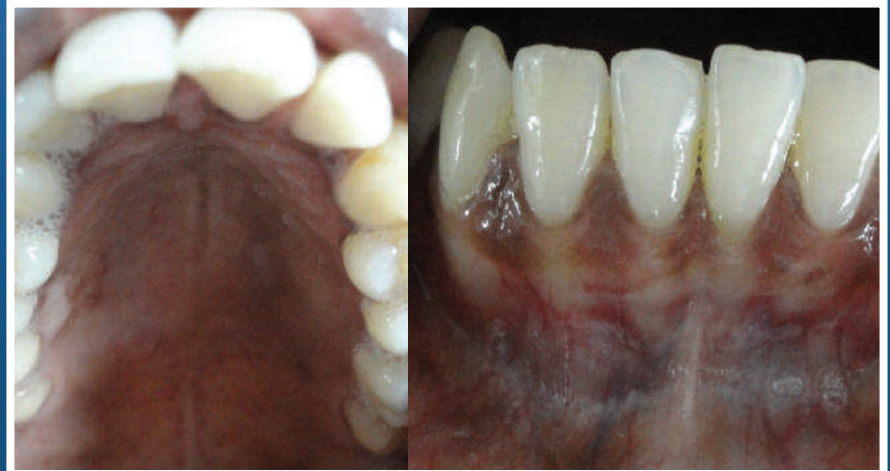Postoperative - Three weeks



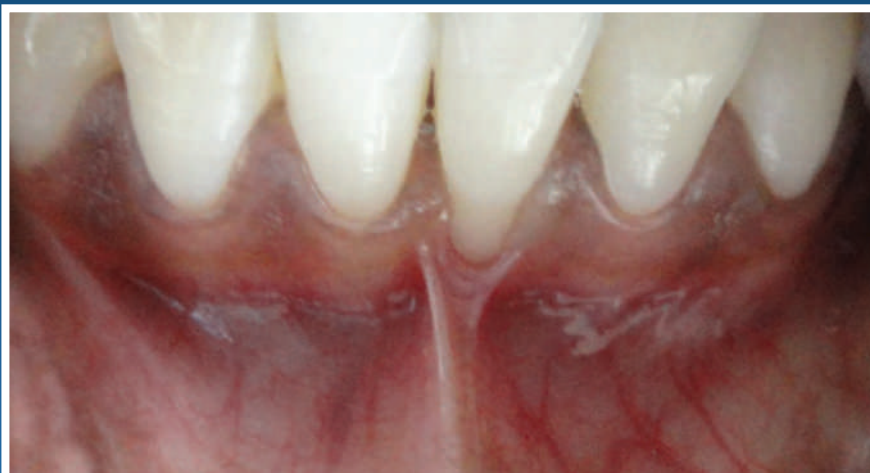Postoperative - One month



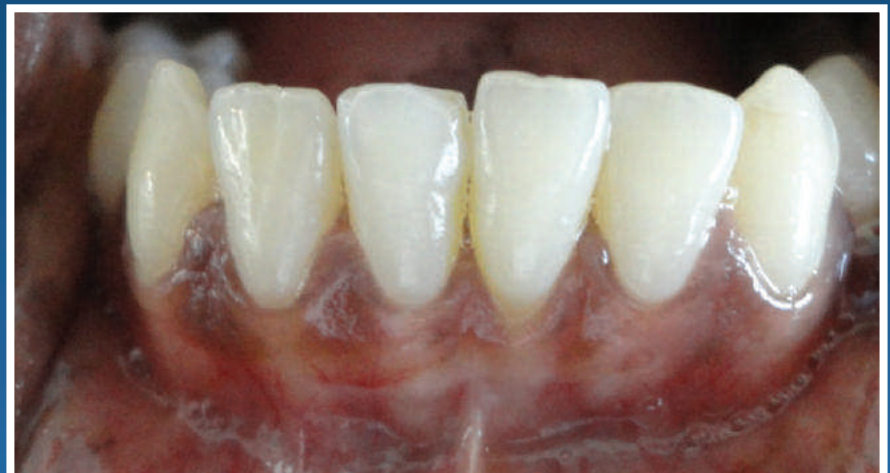Postoperative - Three months



Postoperative - Six months



Preoperative



Postoperative

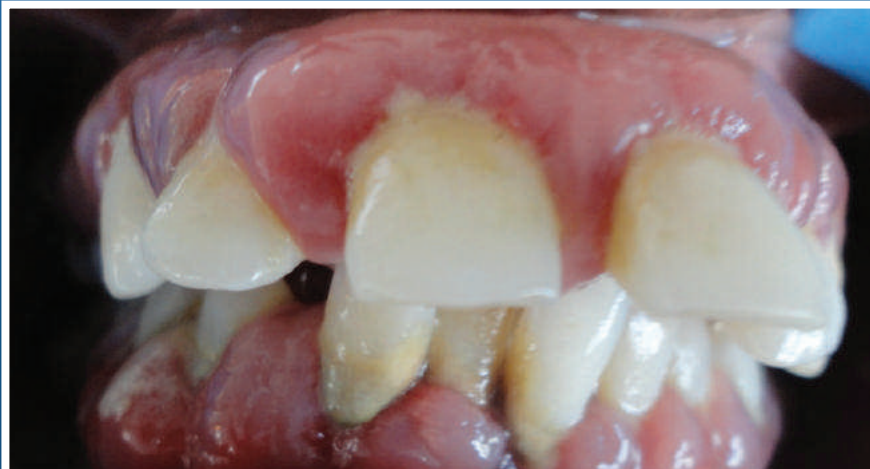

## CONVENTIONAL FLAP SURGERY

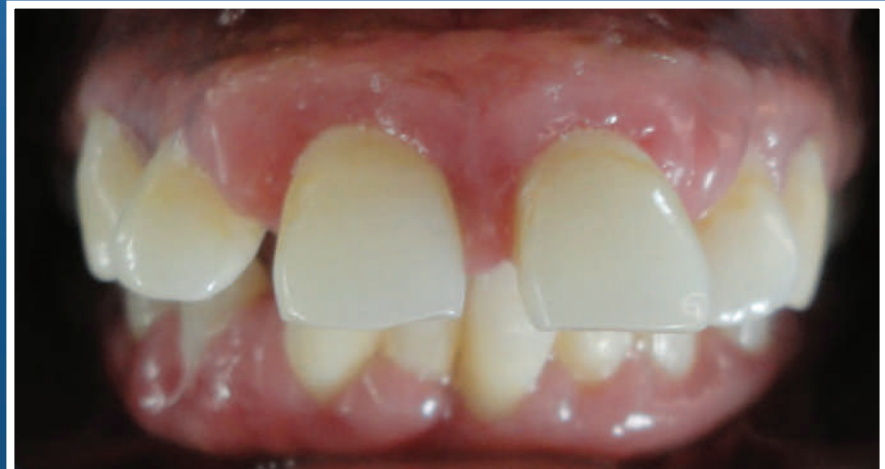Patient Name: **MR.PRAVEEN C CHANDRAN**

Age/Sex : **32y/M**

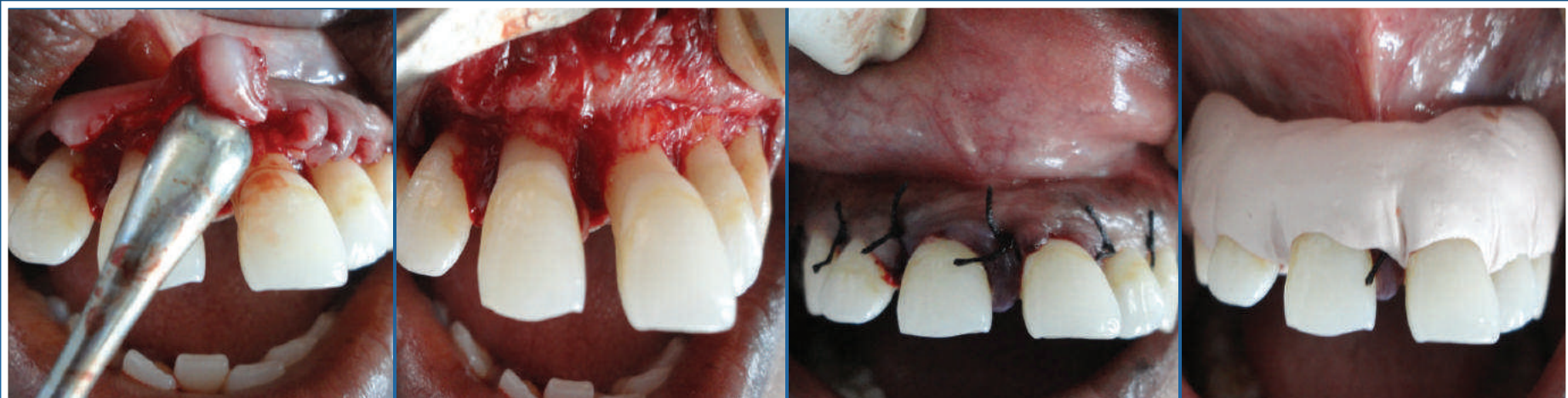Op No : **205931**



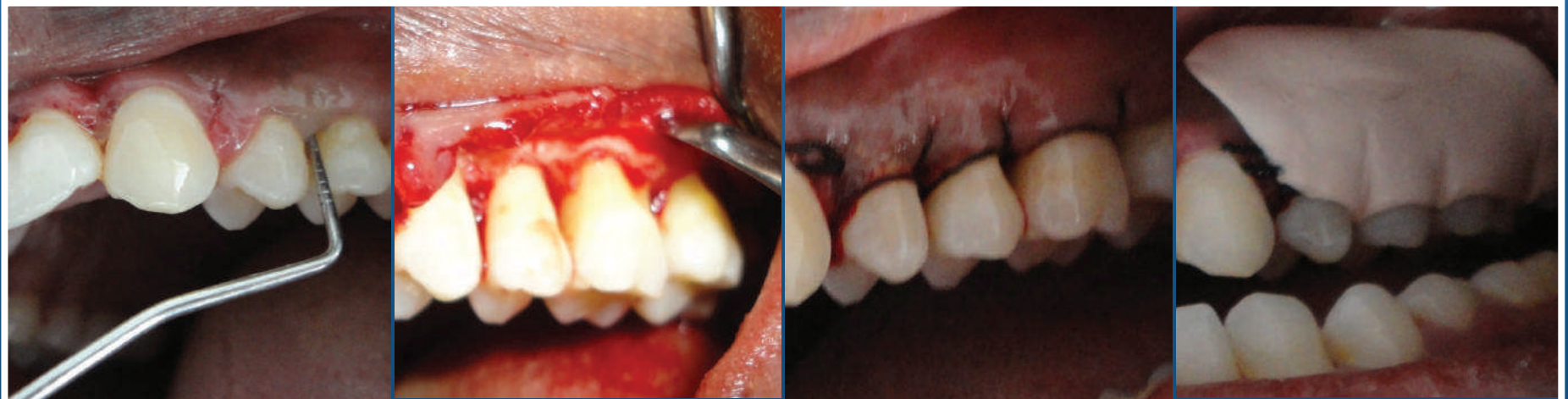Preoperative



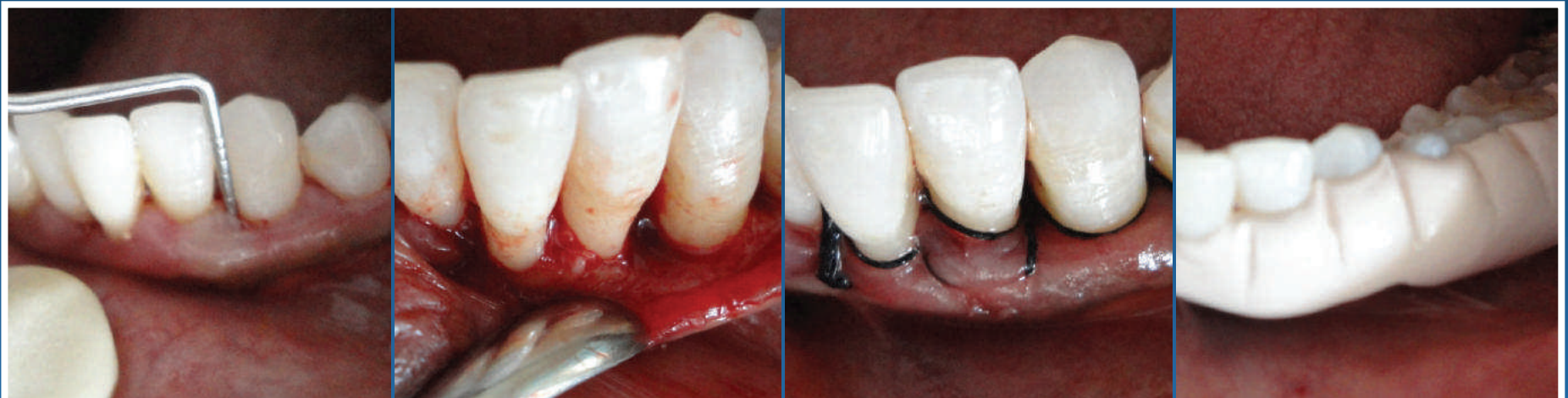After Phase I therapy



Papilla preservation flap - upper anteriors

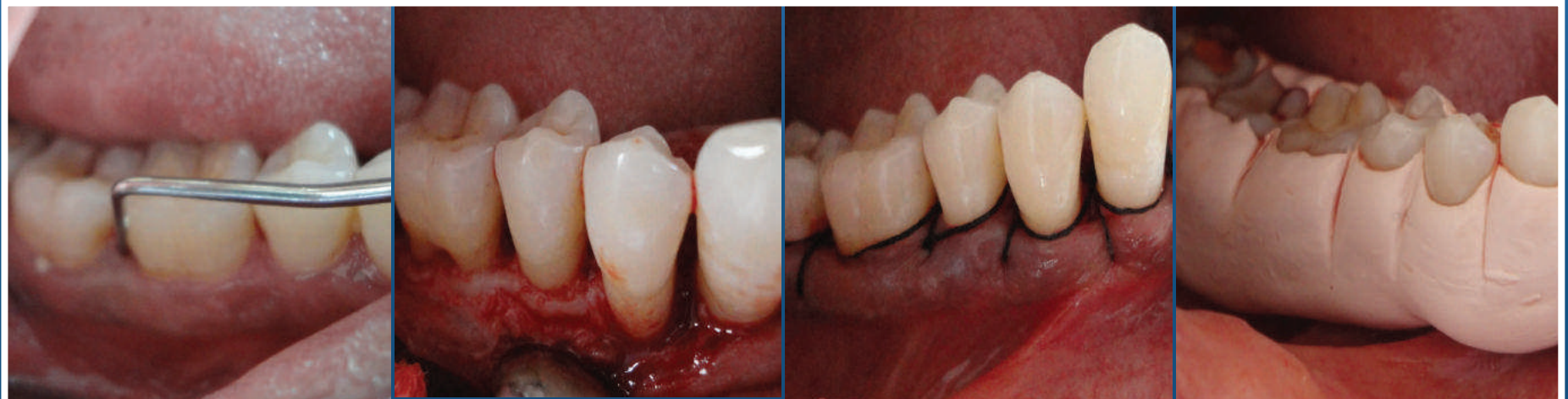

II Quadrant flap

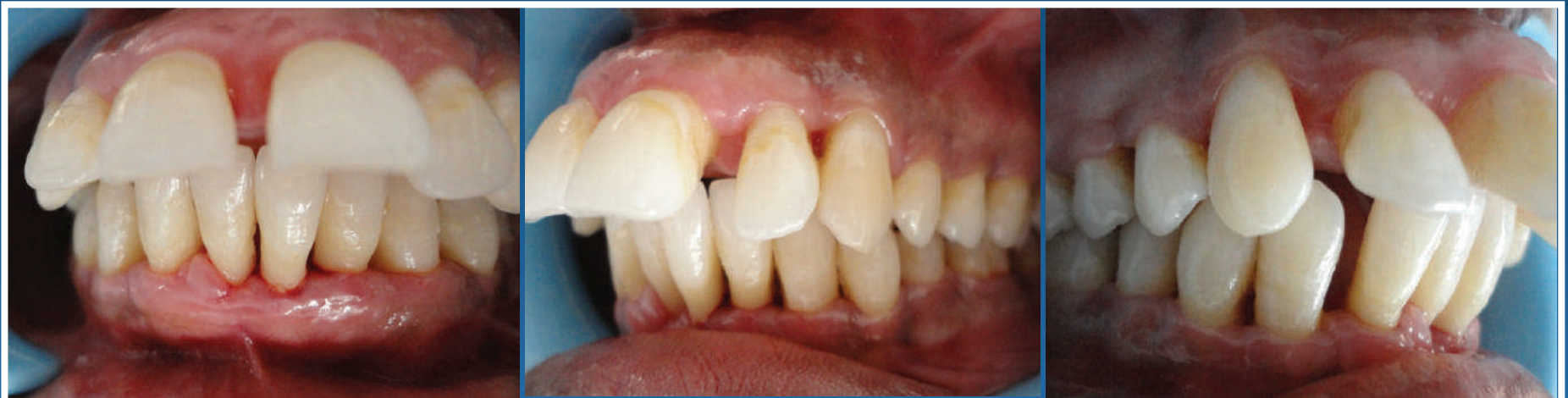

III Quadrant flap



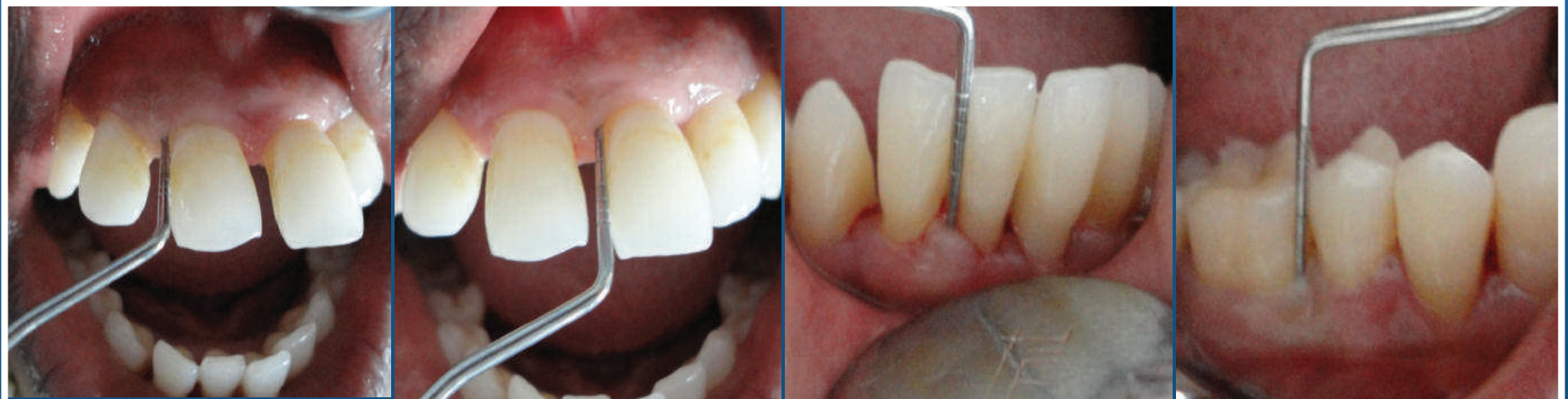

IV Quadrant flap

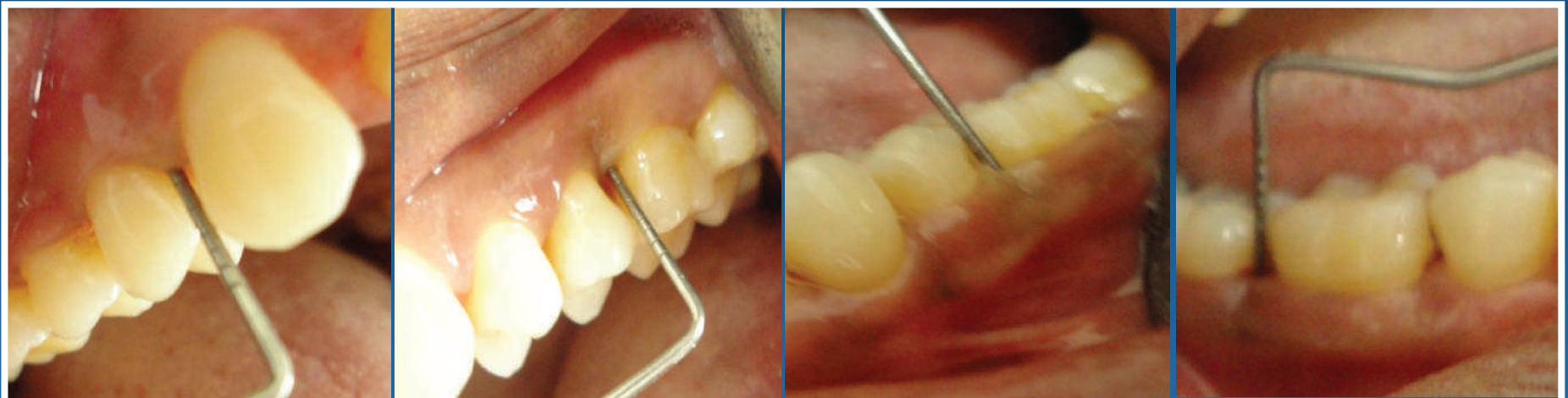

Postoperative - One month

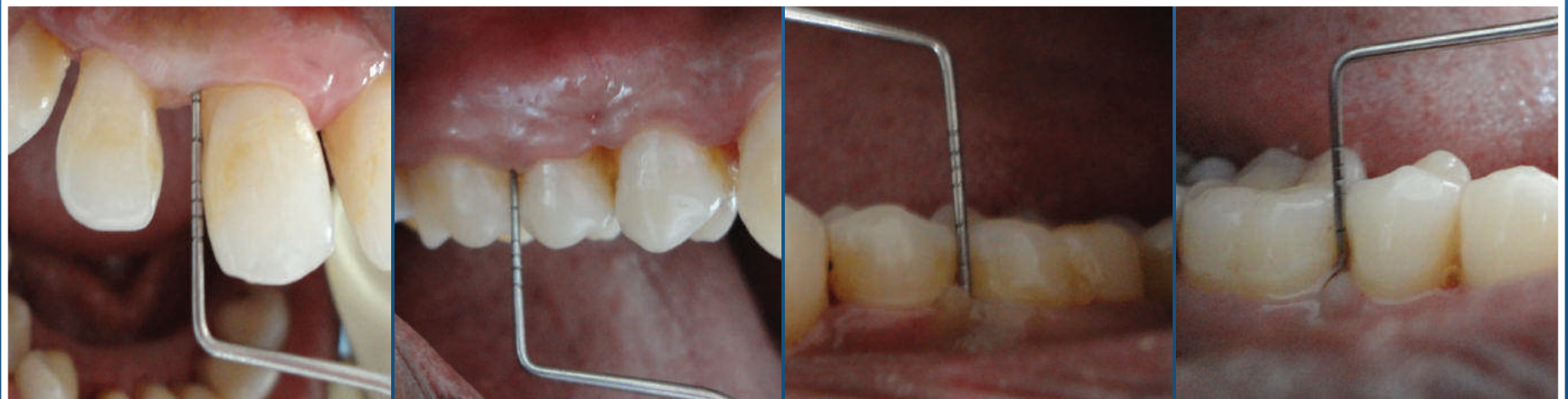



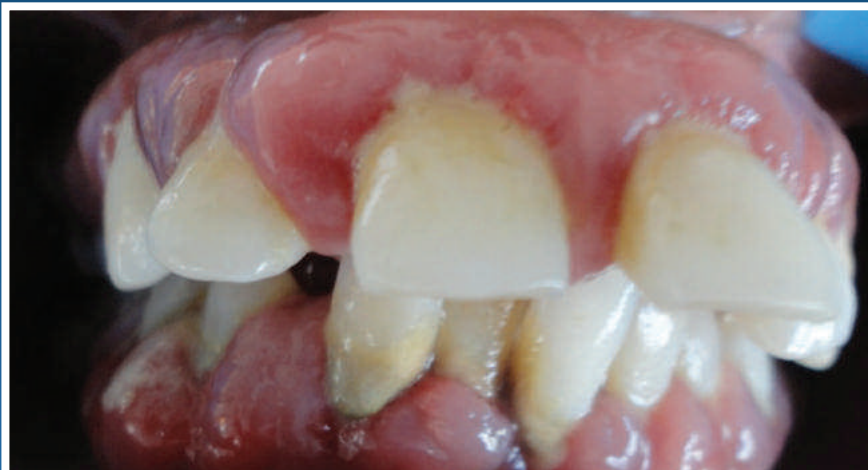Postoperative - Three months



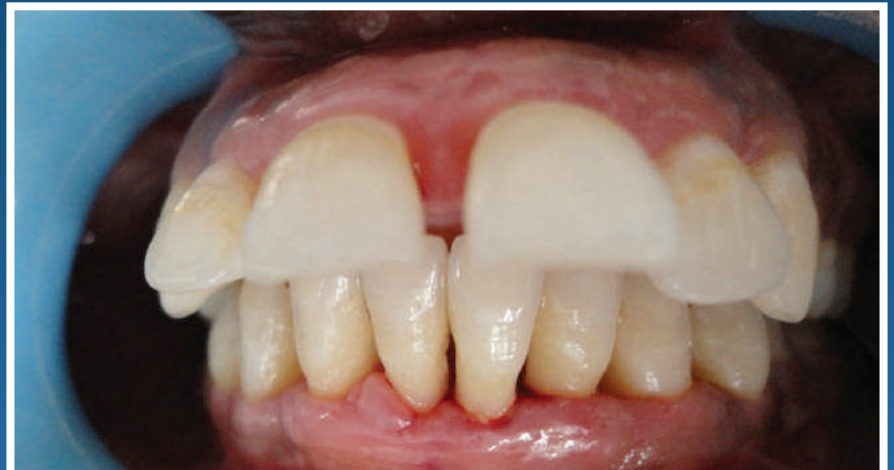Postoperative - Six months



Postoperative - Nine months



Preoperative



Postoperative

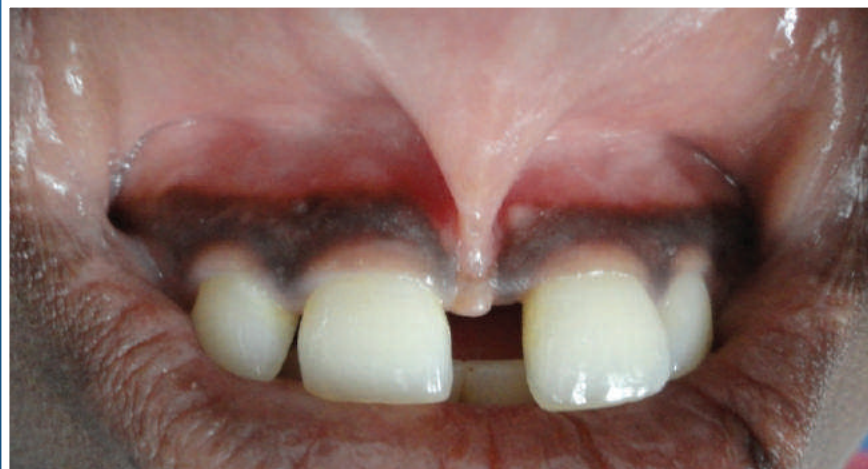# **FRENECTOMY,PAPILLA PRESERVATION FLAP & BONE GRAFTING**

Patient Name: **MS.TULASI**

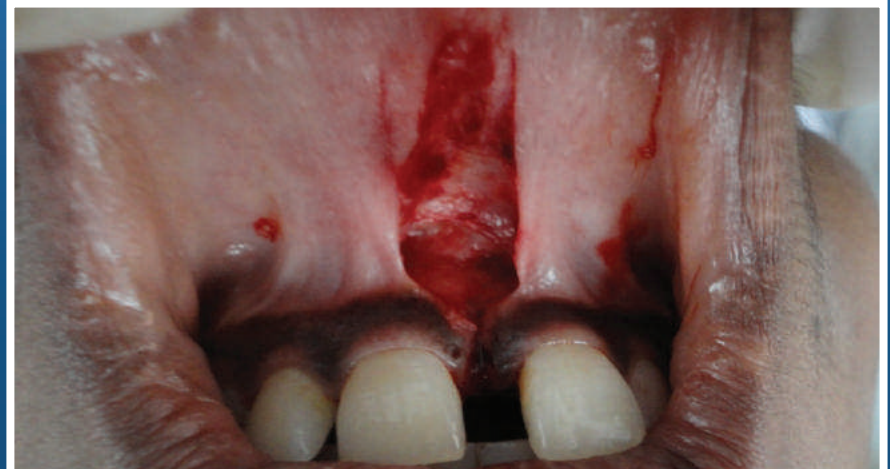Age/Sex : **25Y/F**

Op No : **201509030023**

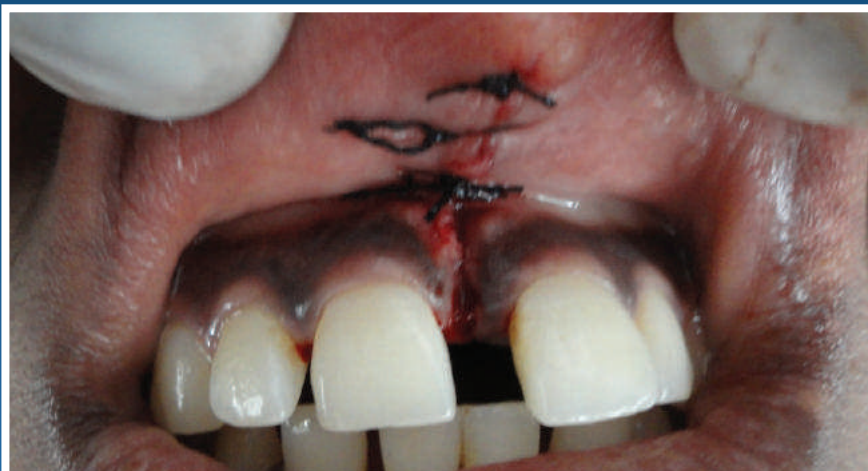



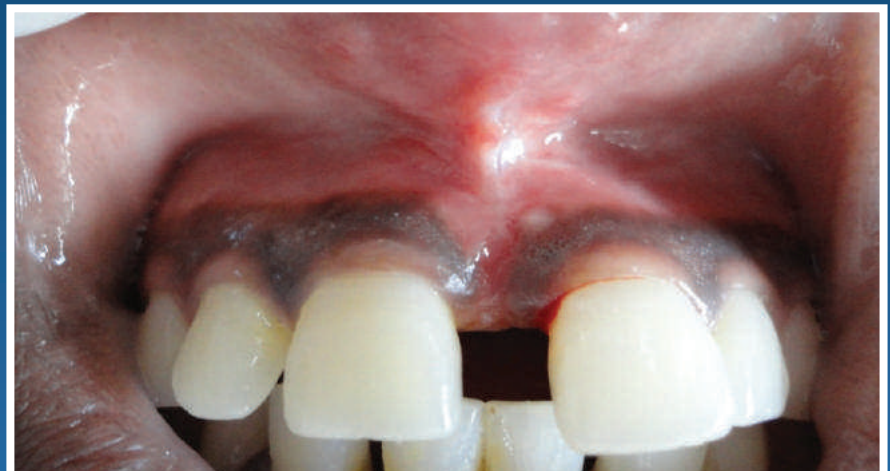Highly Placed Labial Frenum - Papilla Penetrating Type With Midline Diastema



Frenectomy Done Under Local Anaesthesia

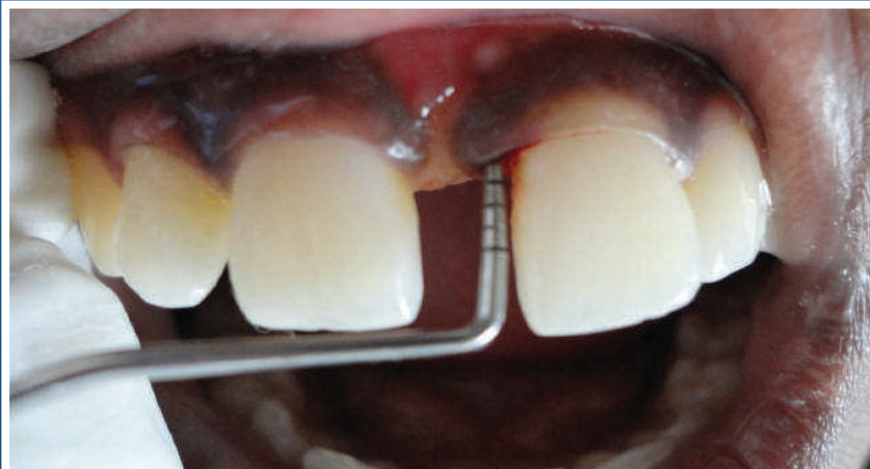

Immediate Post operative view after suturing

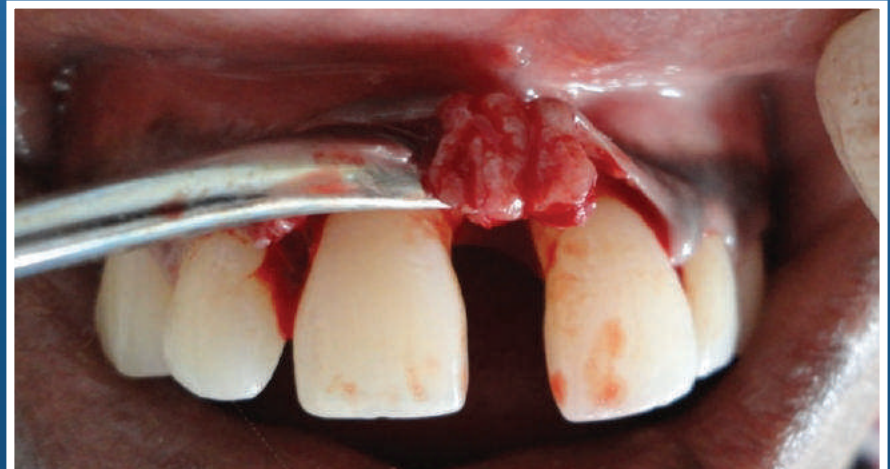


Two weeks Post operative - Frenectomy

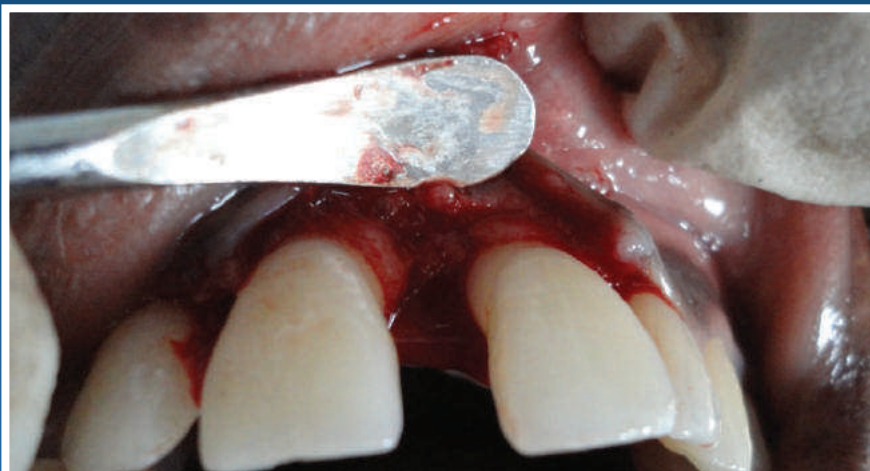




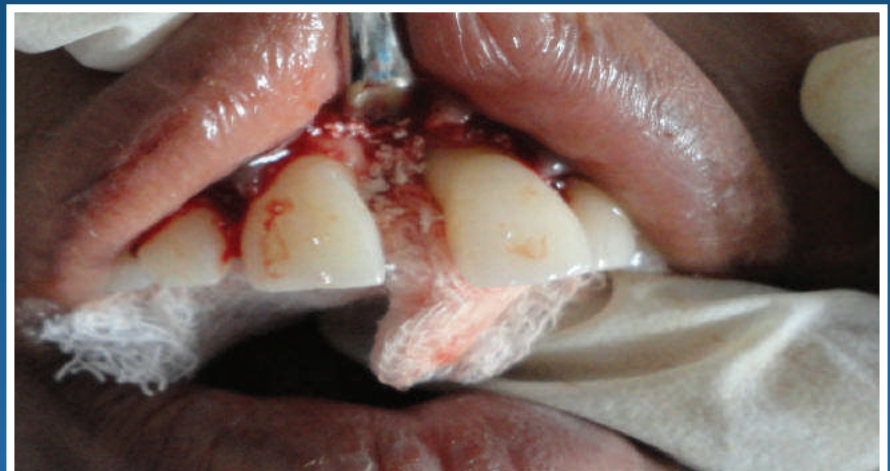Deep intrabony defect with probing depth of 8mm in 21



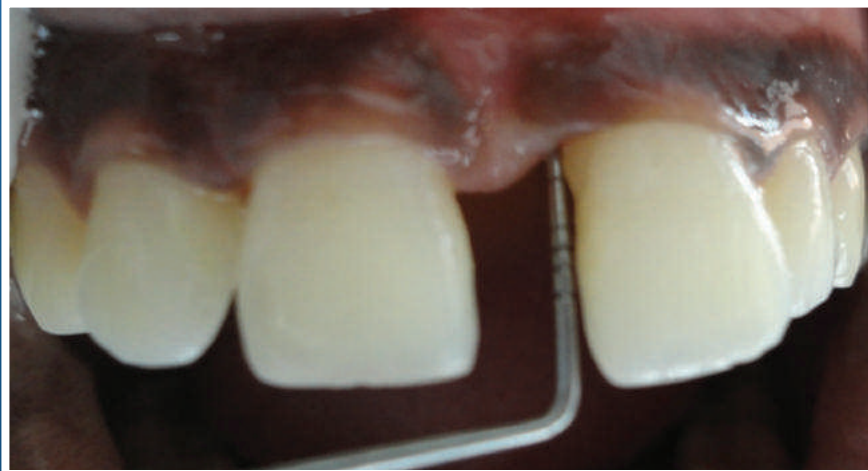Papilla preservation flap done under local anaesthesia



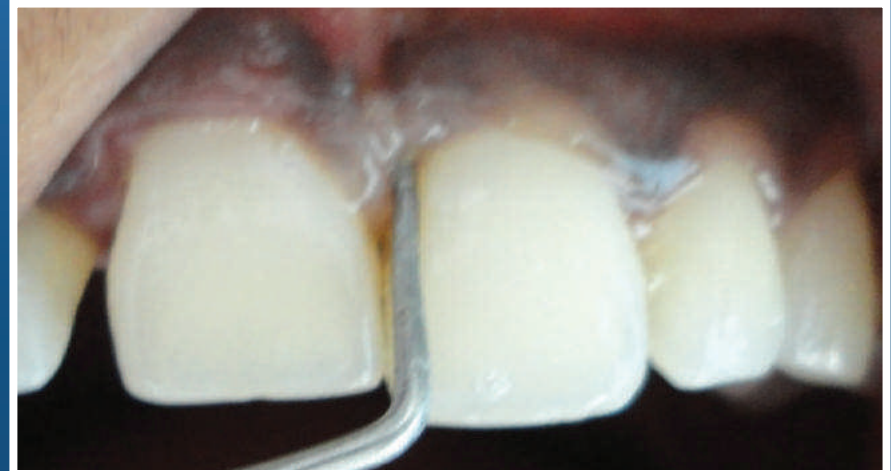Deep two wall intrabony defect on the mesial aspect of 21



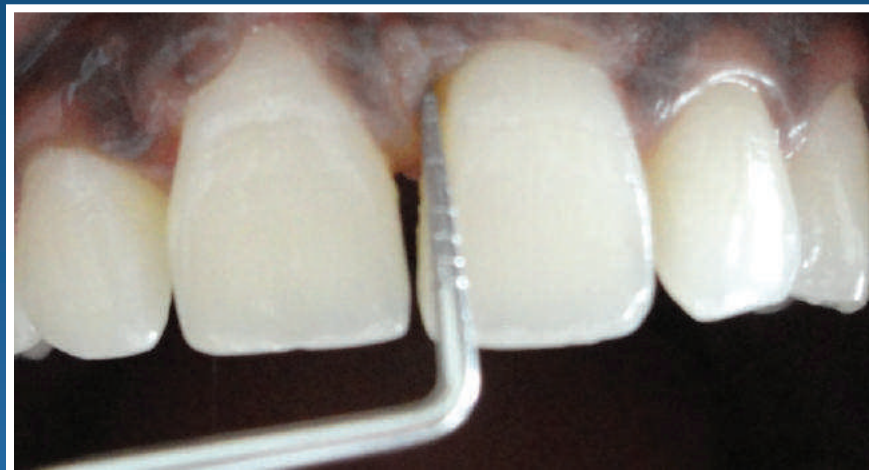Bone grafting done with Bonemedik



Post operative - Three months



Post operative - Six months



Post operative - One year

# **FRENOTOMY**

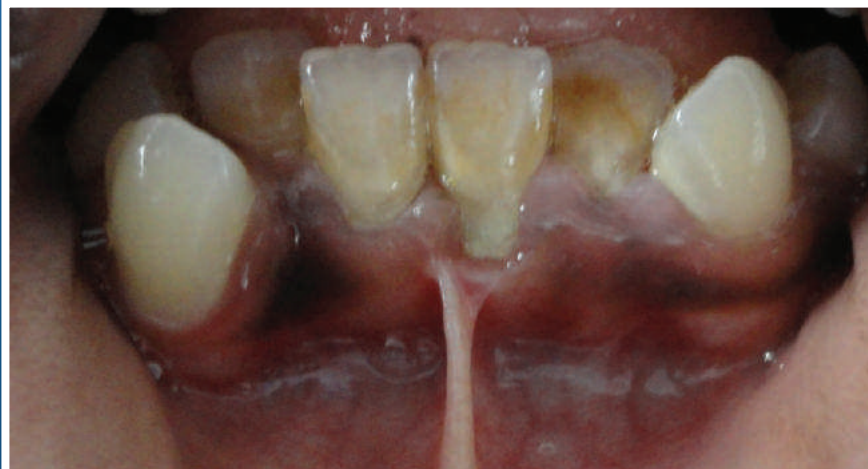Patient Name: **MR.RAJU**

Age/Sex : **28 Y/M**

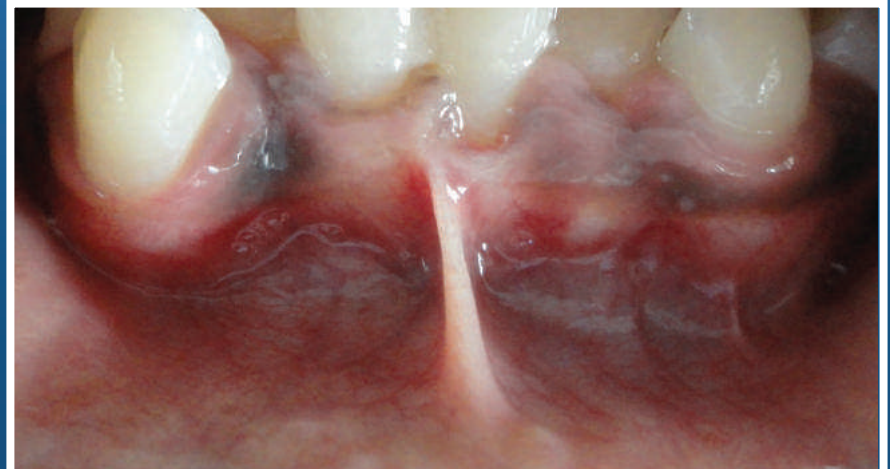
Op No : **201704190091**

**HIGH LABIAL FRENAL ATTACHMENT - 31, 41**

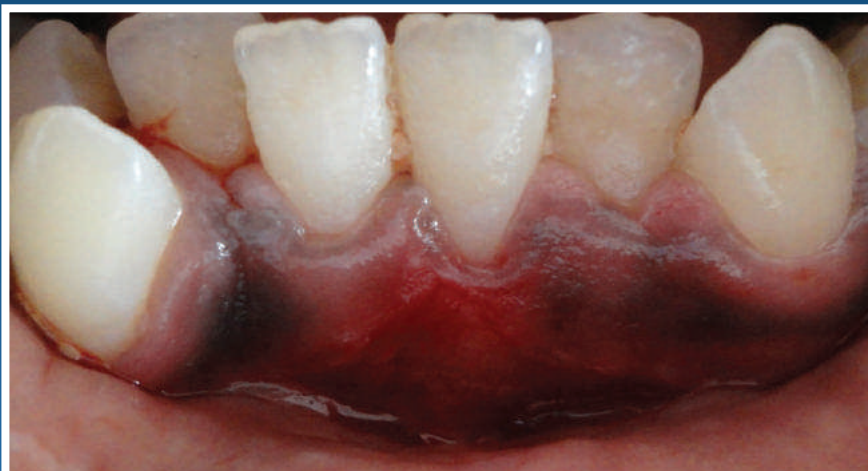



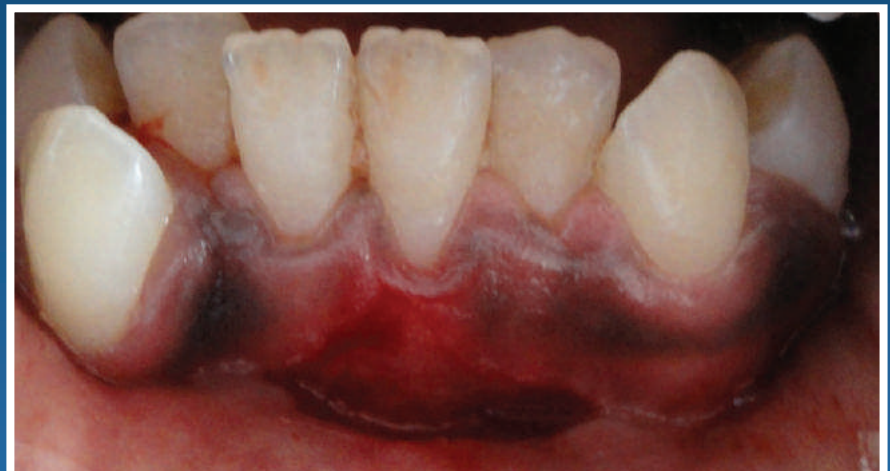High labial frenal attachment in relation to 31



After oral prophylaxis

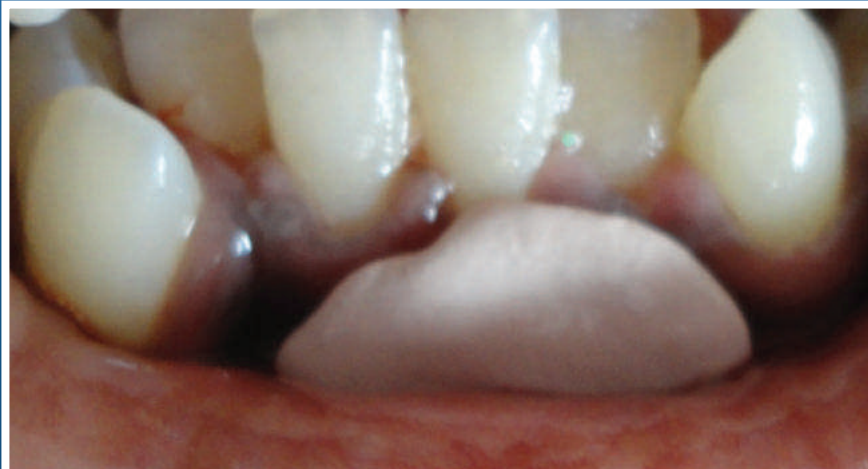

After incision

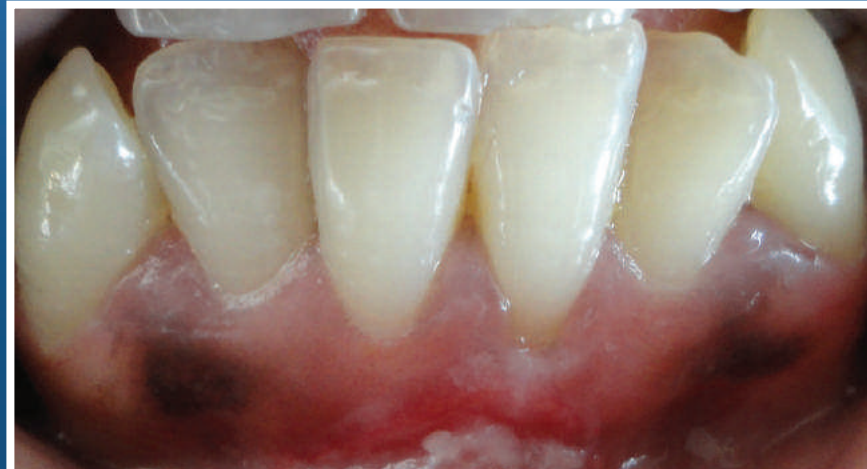

Immediate postoperative view

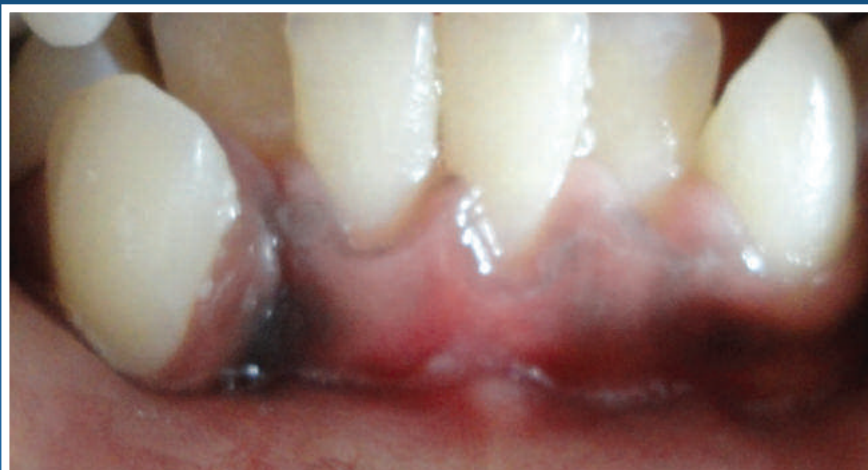



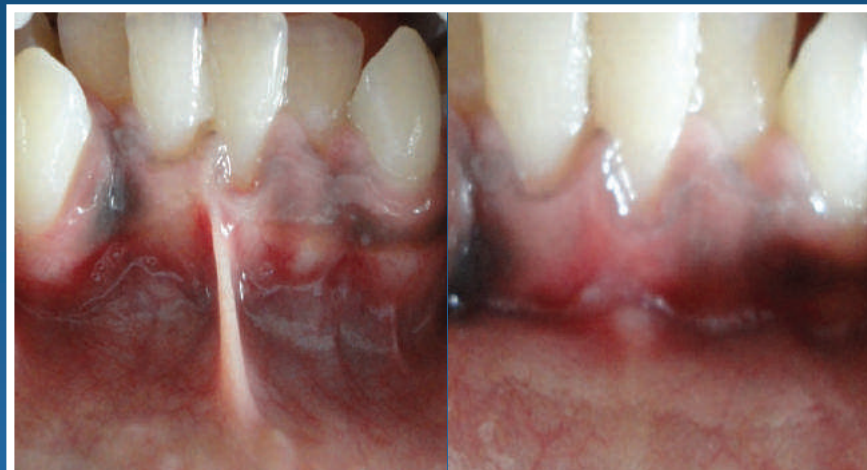After placing Periodontal pack



Postoperative - One week



Postoperative - One month



Preoperative

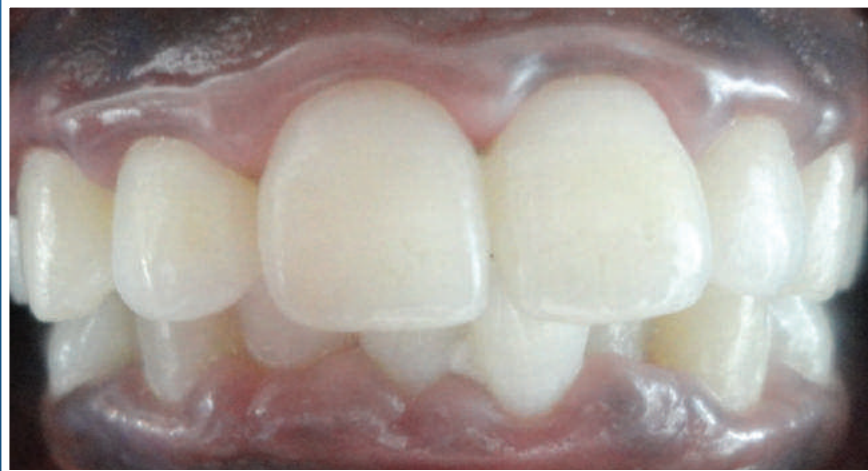Postoperative

# GINGIVECTOMY

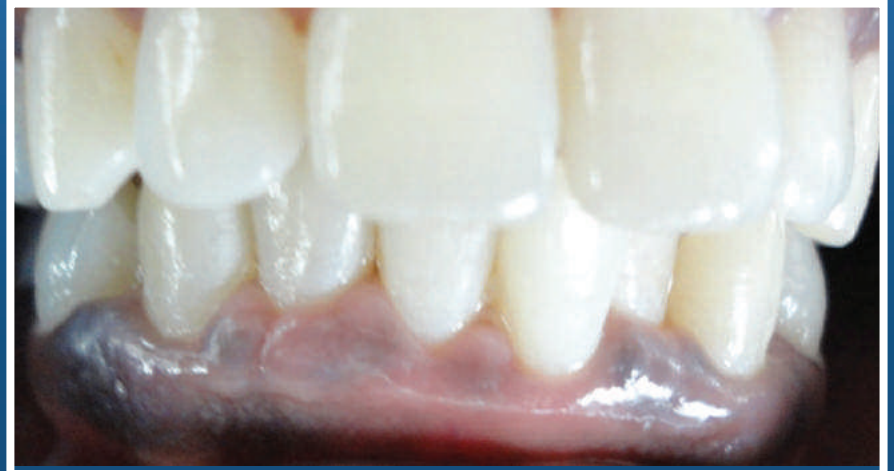Patient Name: **TEJASHRI**

Age/Sex : **24 Y/F**

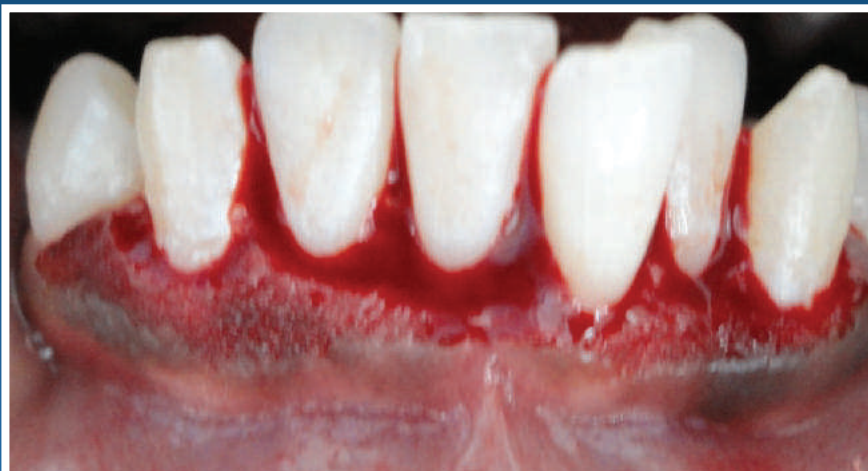Op No : **201405260037**



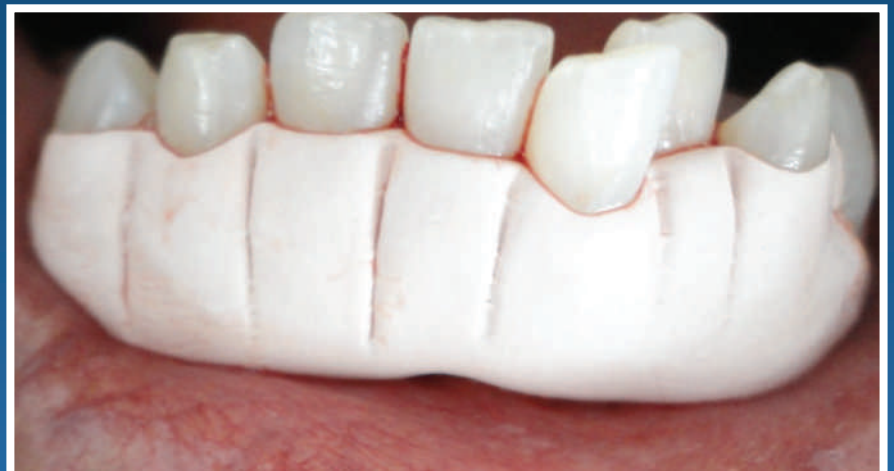Pre-operative



After Oral Prophylaxis

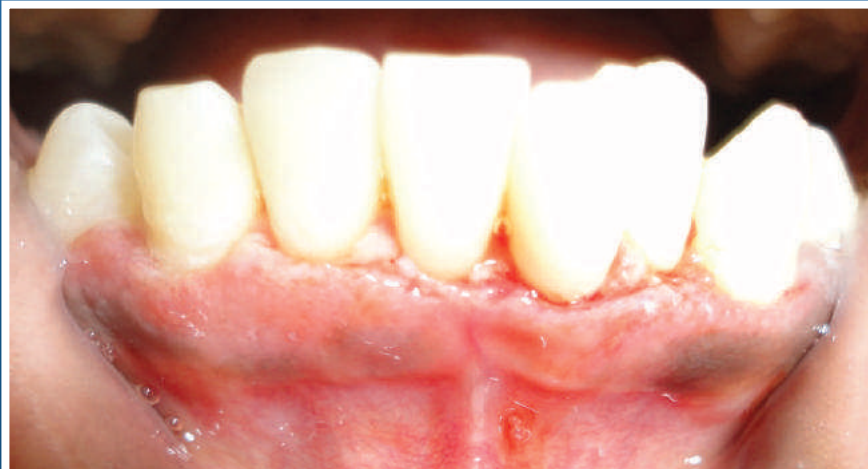

Immediately After Gingivectomy

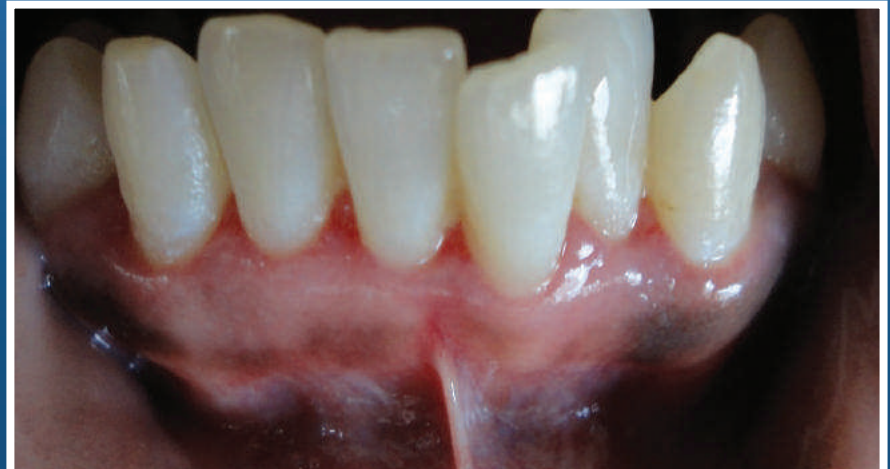

After Periodontal Pack

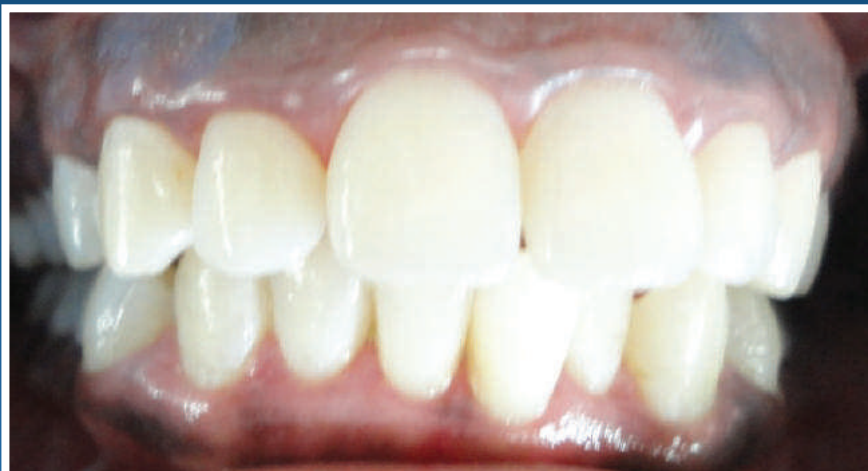



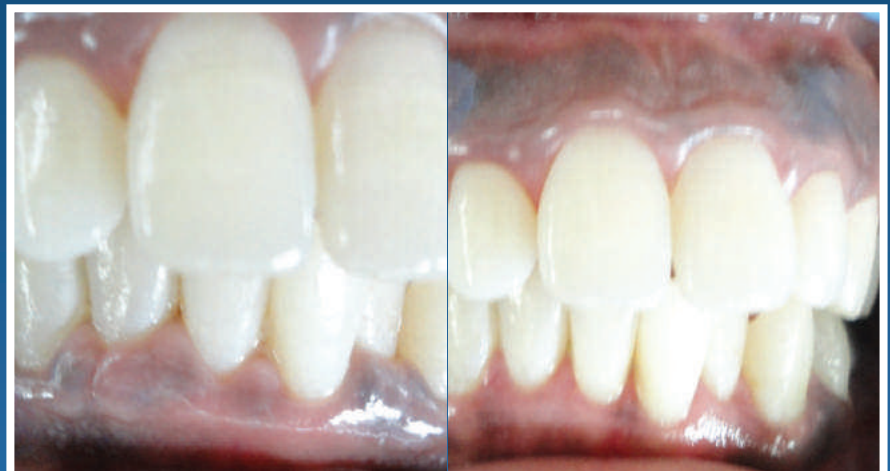Postoperative - one week



Postoperative - One month



Postoperative - Three months



Preoperative

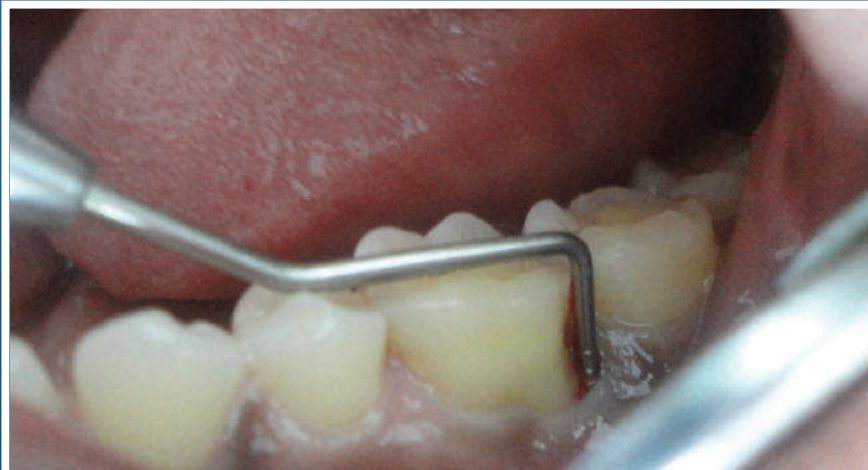Postoperative

## **HEMISECTION IN 36**

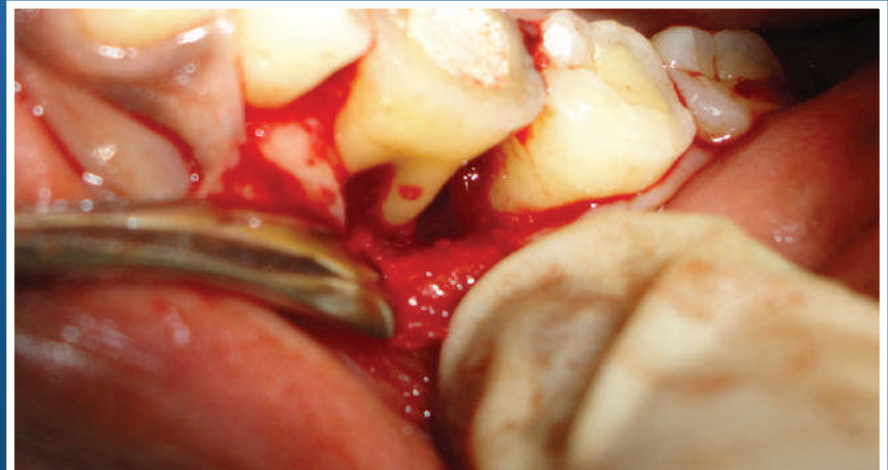Patient Name: **MR.MURUGESAN**

Age/Sex : **42Y/M**

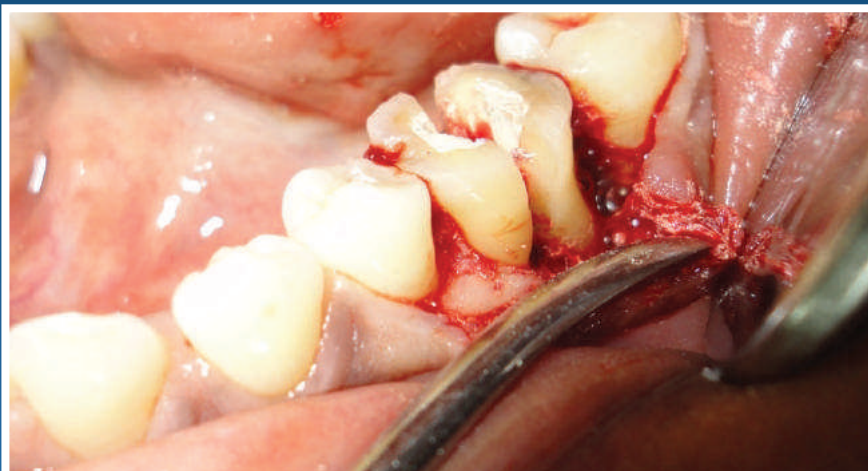Op No : **20160610005**



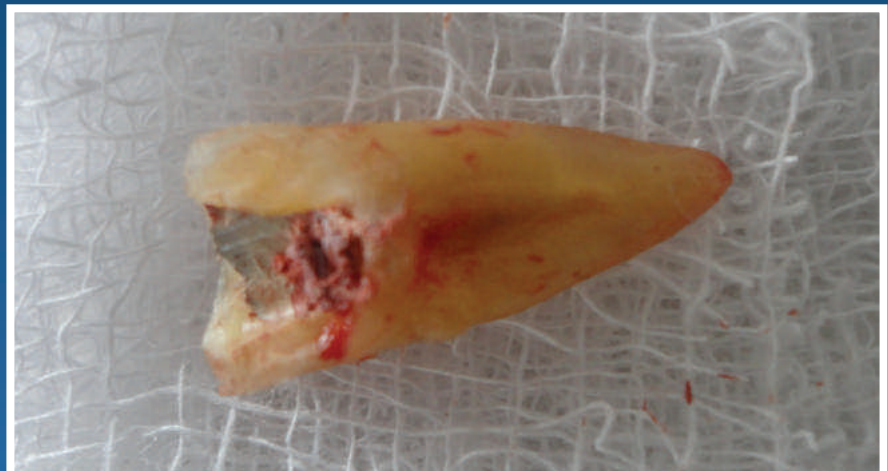Preoperative - Probing depth of 9mm in 36



After flap elevation - 36

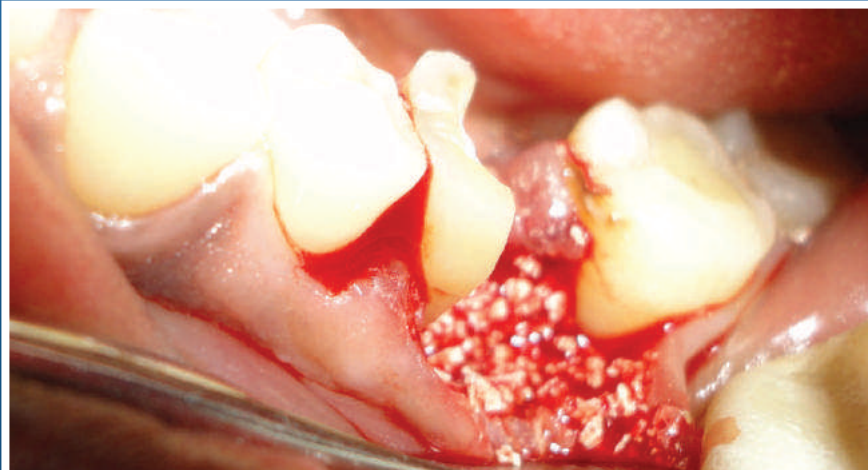

After separation of tooth - 36

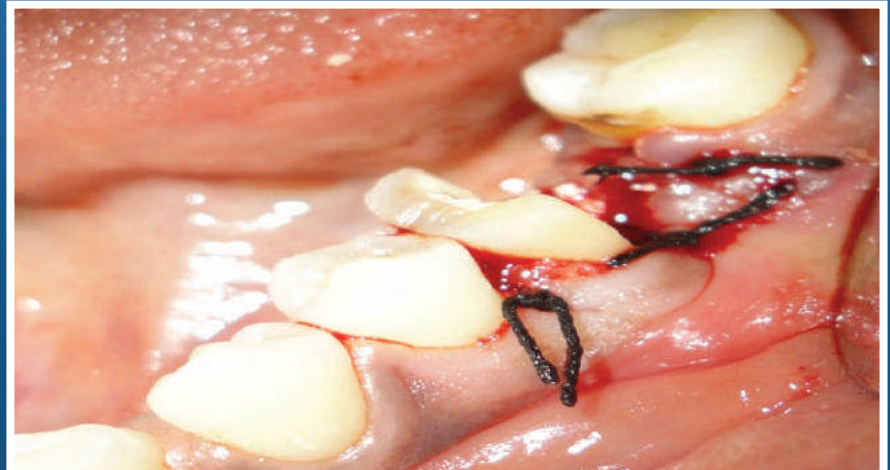

Hemisected tooth - distal portion of 36

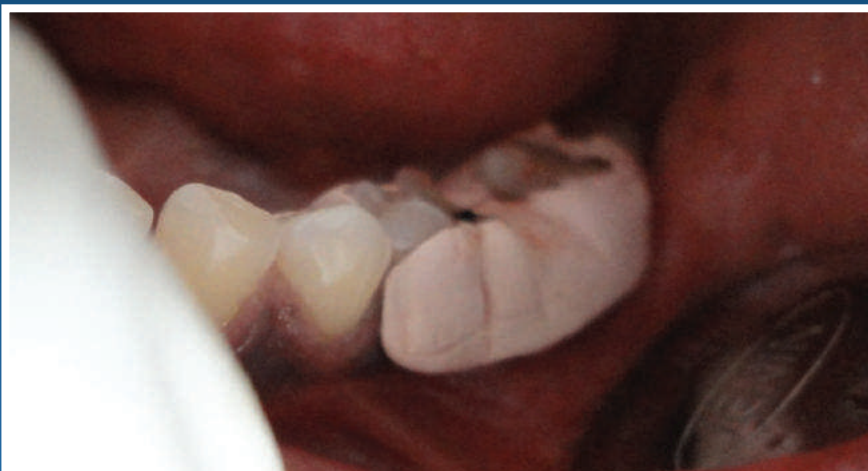



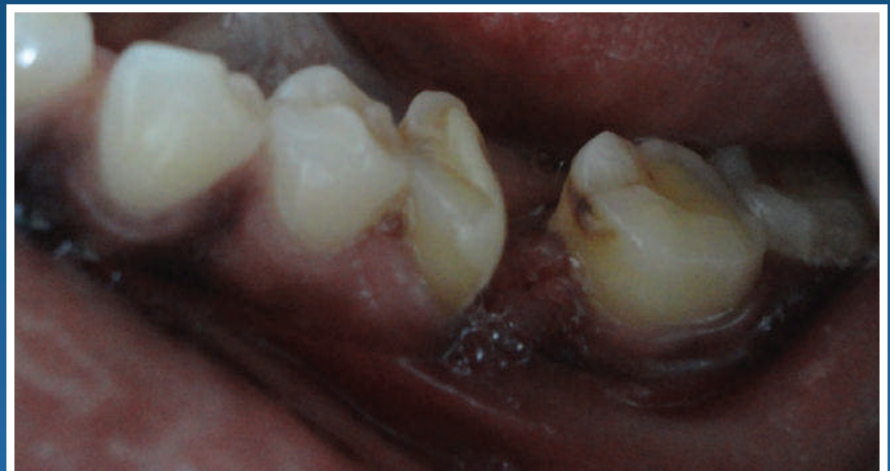Bone grafting in Distal socket of 36



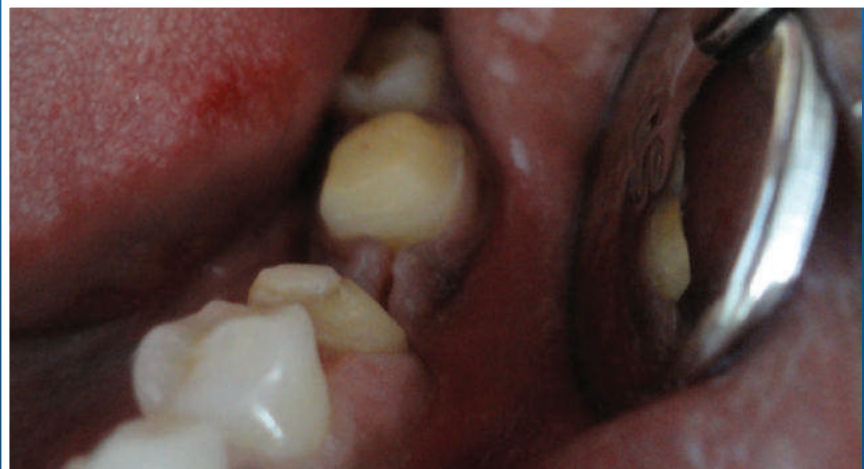After suturing -36



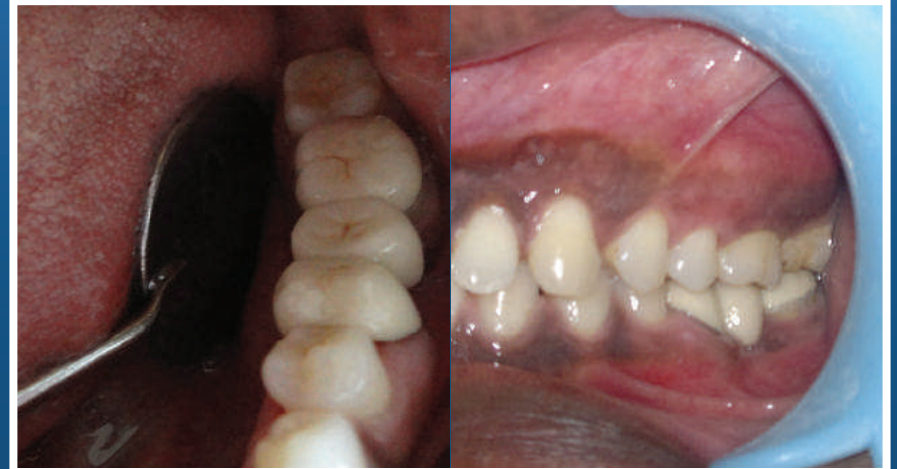After placing periodontal pack



Postoperative - One month



After tooth preparation - 36, 37



After FPD

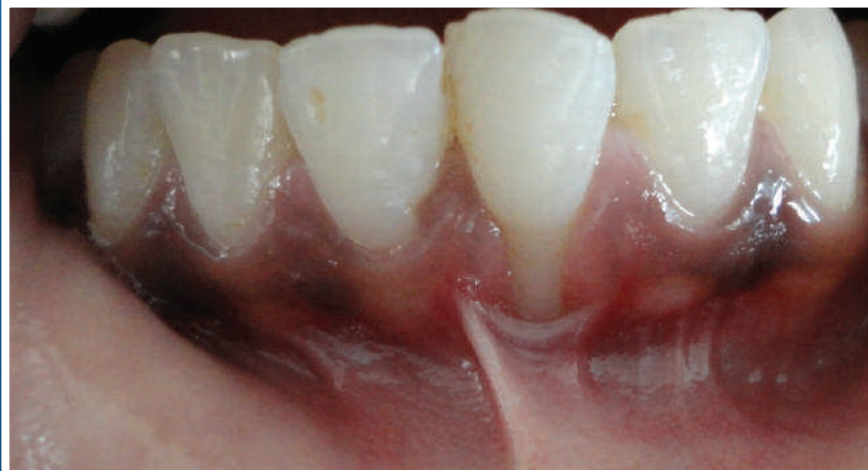# **MILLERS CLASS II GINGIVAL RECESSION LATERAL PEDICLE GRAFT**

Patient Name: **MR.VASANTH**

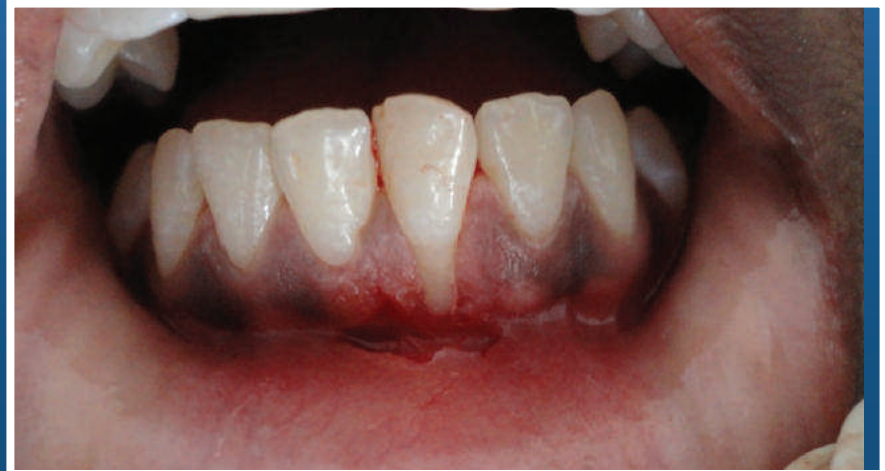Age/Sex : **35Y/M**

Op No : **201704290033**

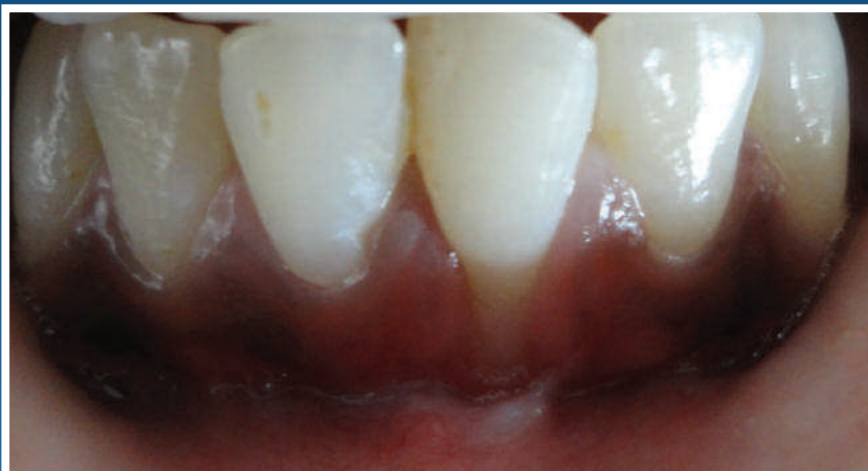



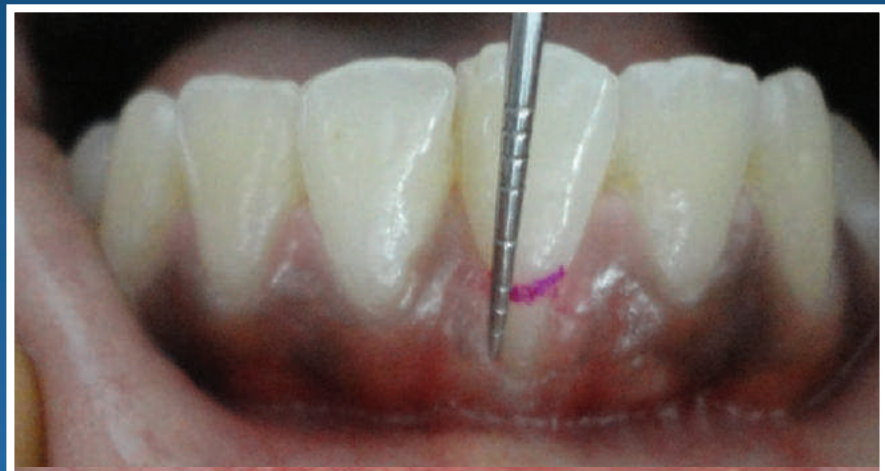Preoperative - Recession of 4mm in 31



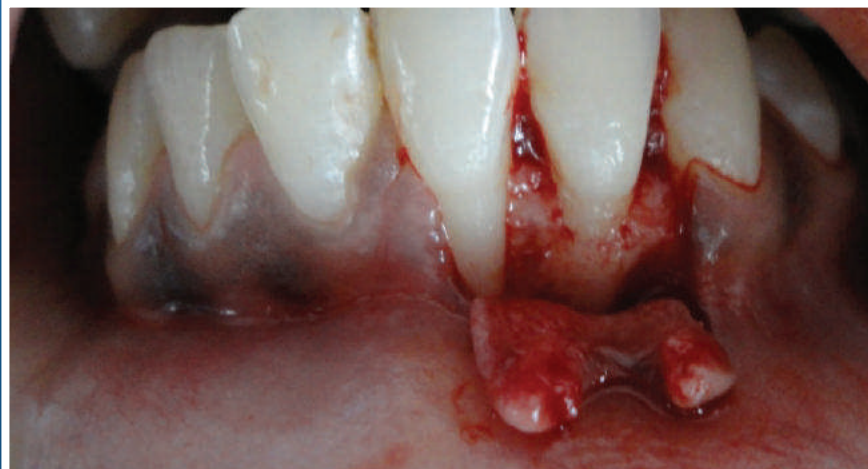
Frenotomy - 31,41



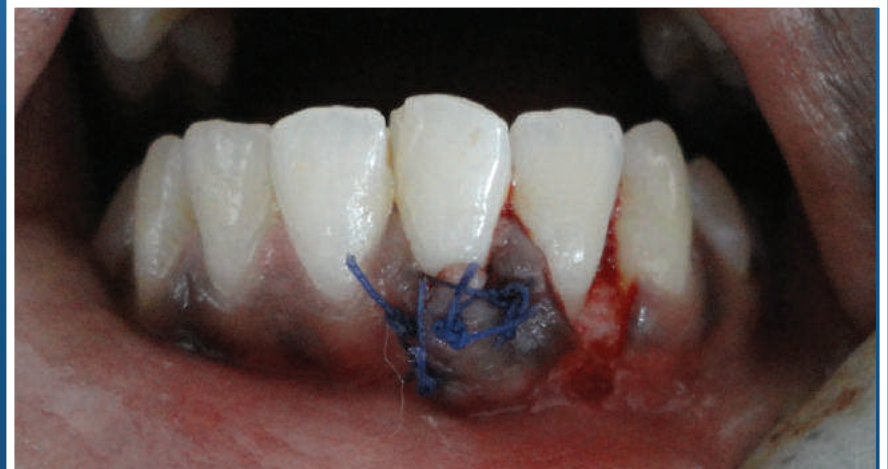1 week postoperative after Frenotomy



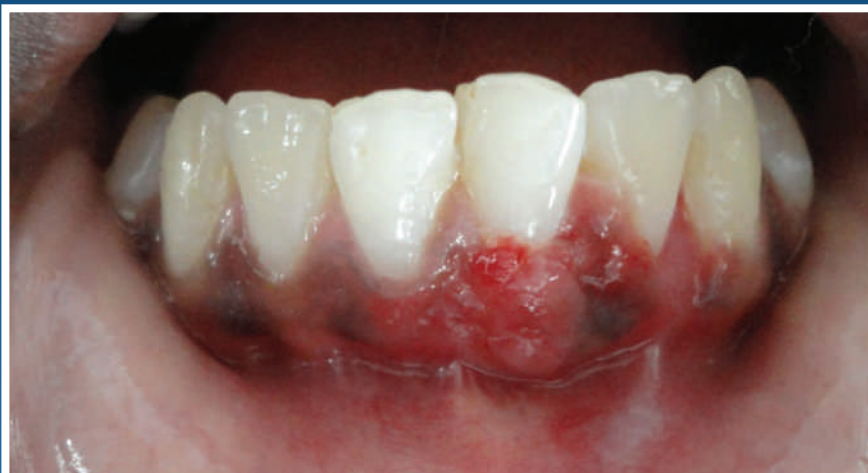Recession of 4 mm in relation to 31



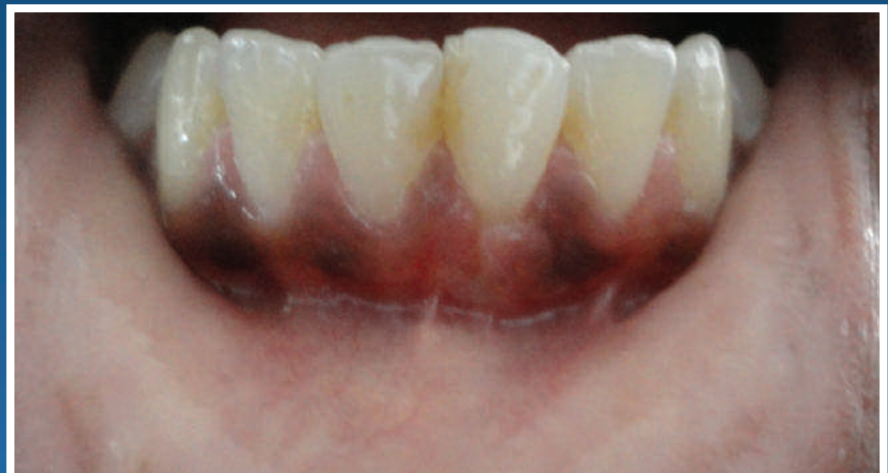After partial thickness flap - 31,32



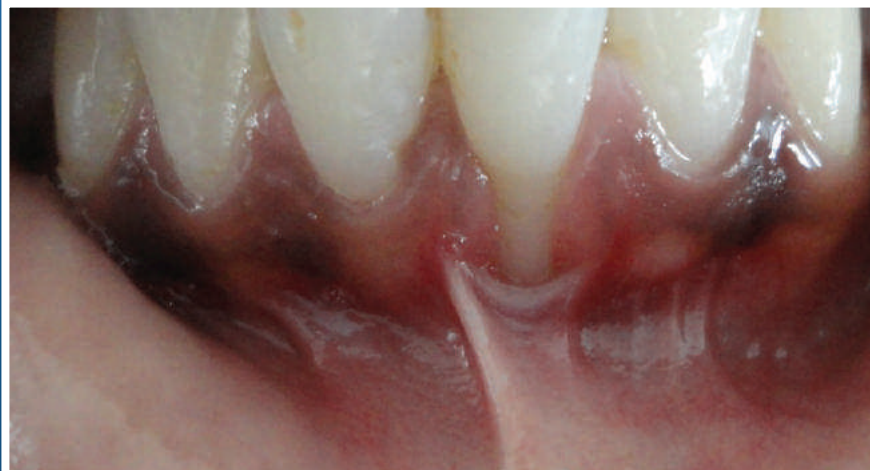
After suturing



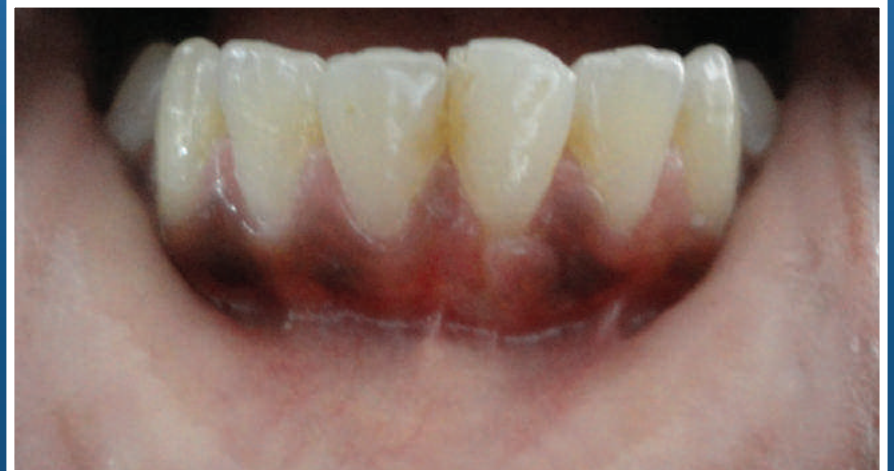Postoperative - One week



Postoperative - One months



Preoperative



One Month Postoperative

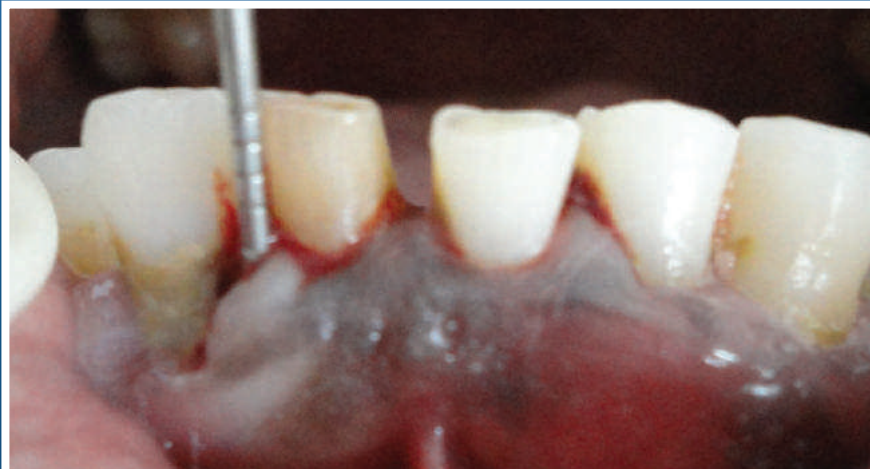

## **PERIAPICAL SURGERY**

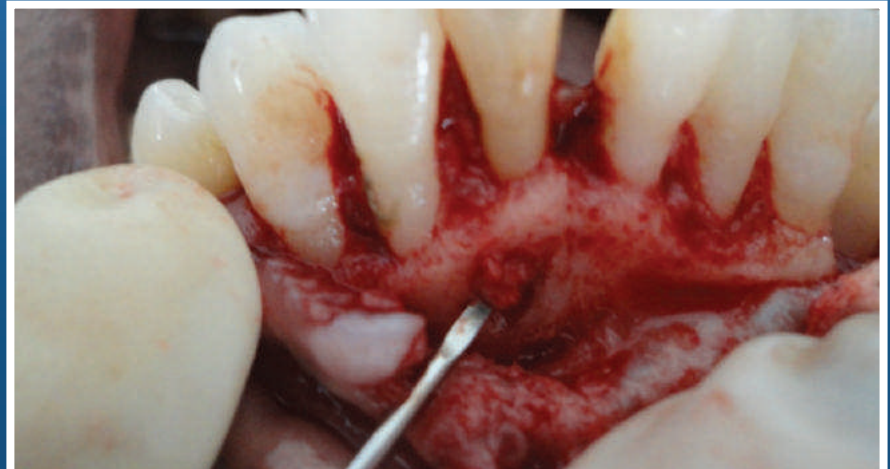Patient Name: **MR.PANDIYAN**

Age/Sex : **56 y/M**

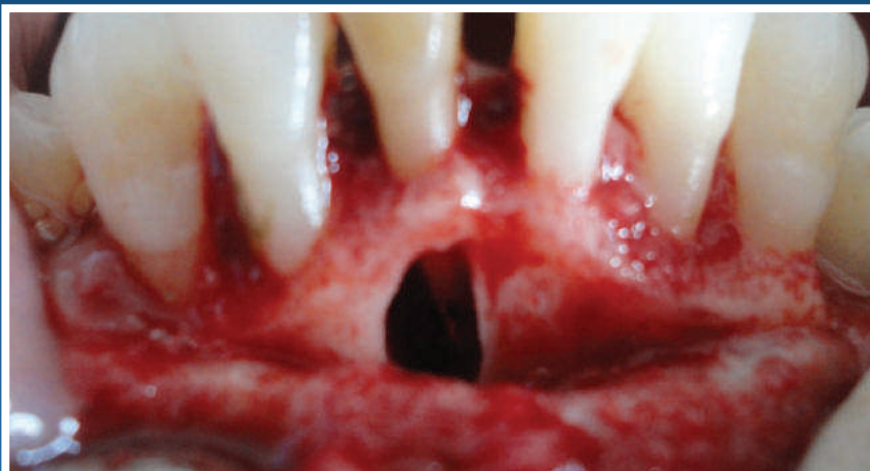Op No : **201704010078**



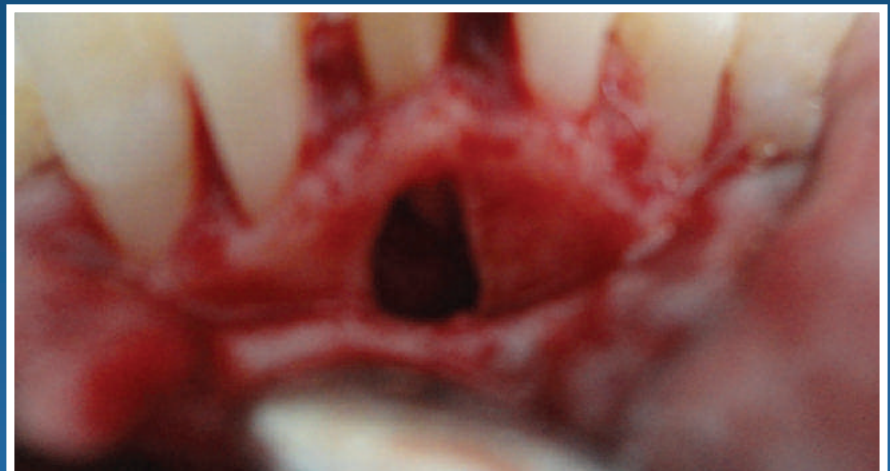Preoperative - Probing depth of 7mm



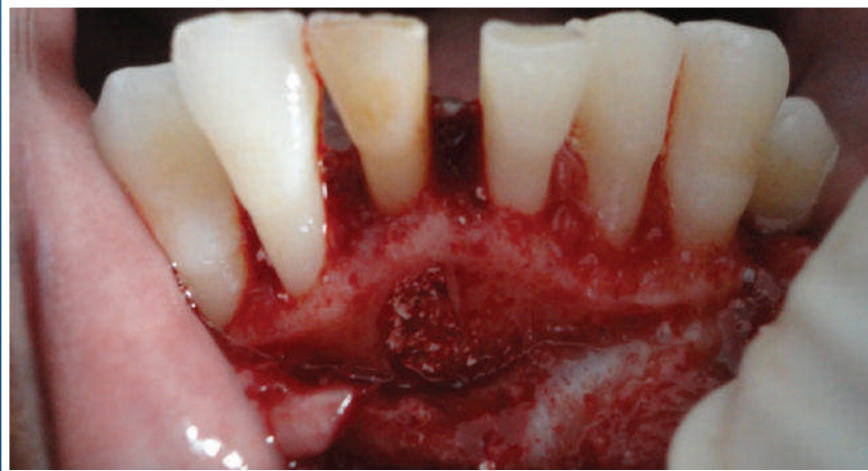After flap elevation - 41



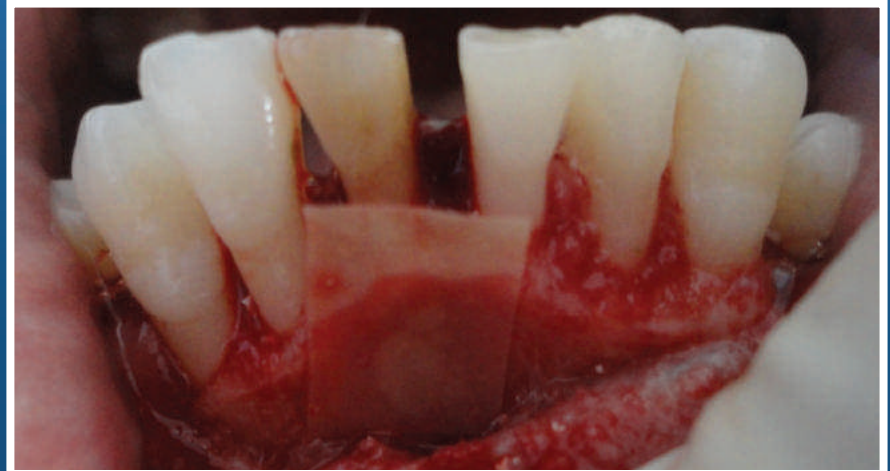Bone loss - 41



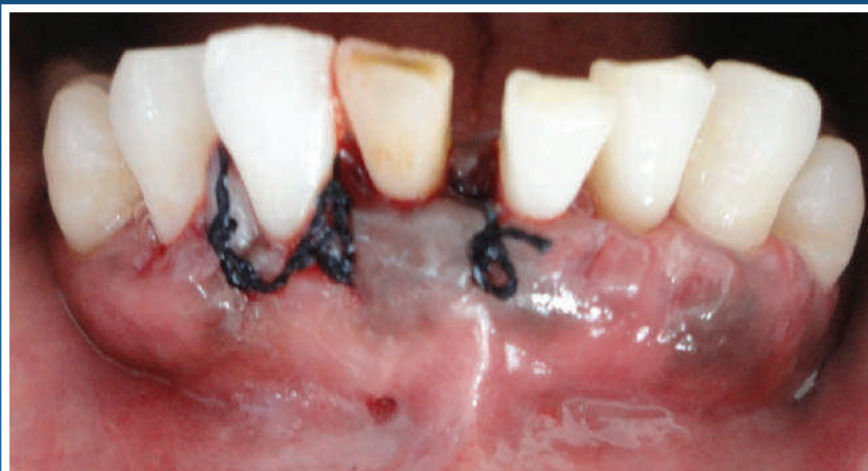After Apicoectomy - 41



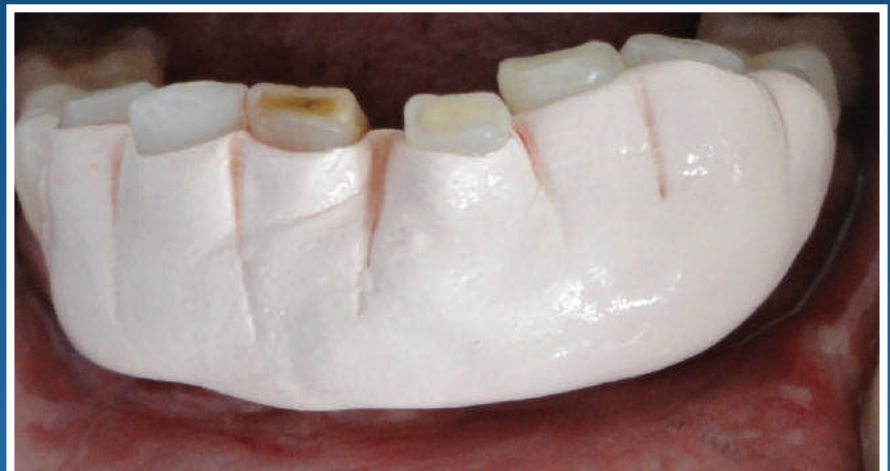Bone grafting - 41



GTR Membrane Placement

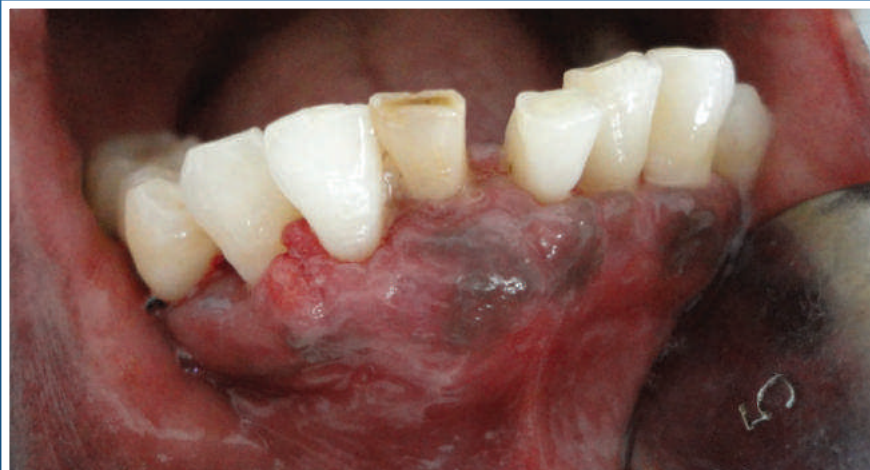

After suturing

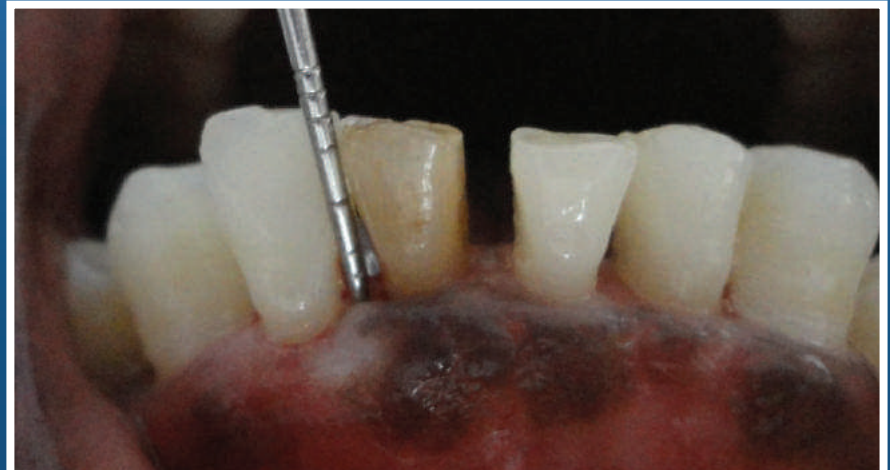

After placing periodontal pack

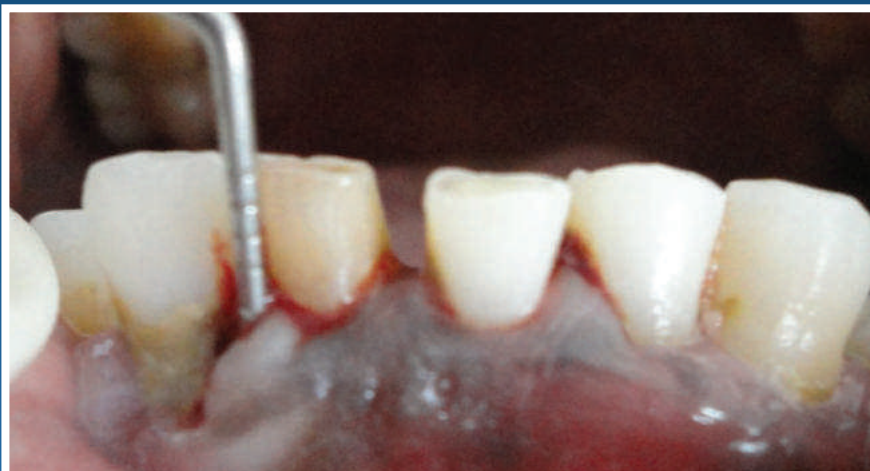



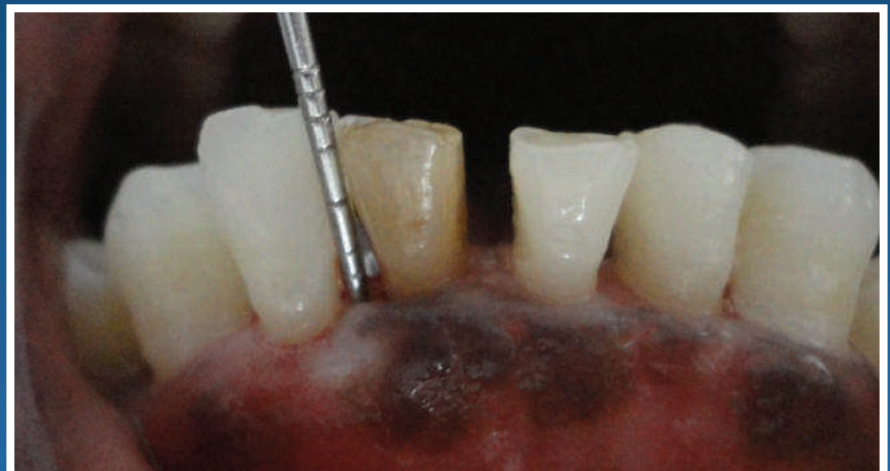Postoperative - One week



3 months postoperative - reduction of probing depth to 3mm in 41



Preoperative



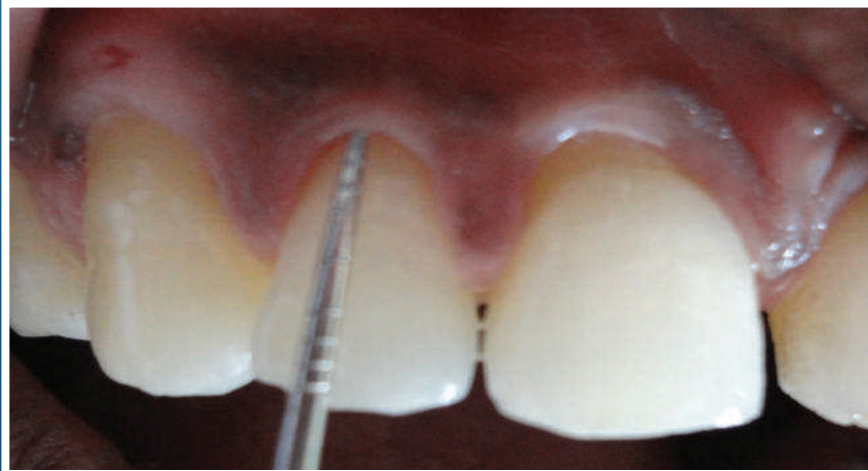Postoperative

## **SEMILUNAR CORONALLY ADVANCED FLAP**

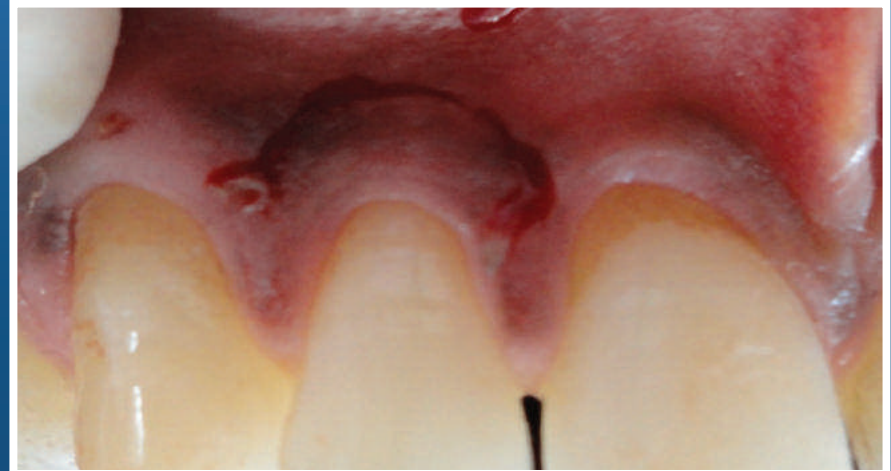Patient Name: **MR.ARULKUMARAN**

Age/Sex : **28y/M**

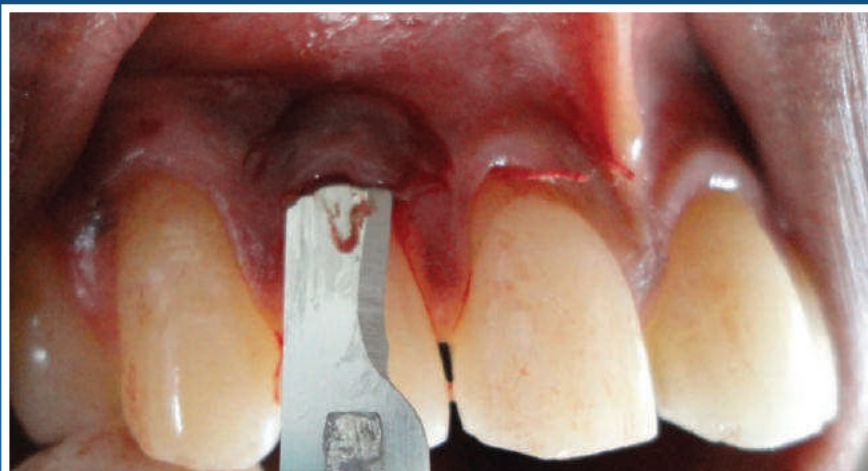Op No : **201704120118**



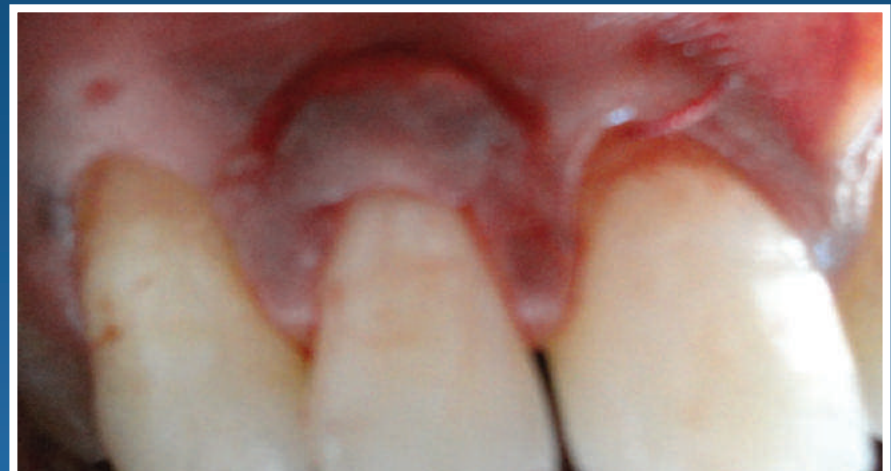Preoperative - Recession of 2mm in 12



Semilunar Incision - 12

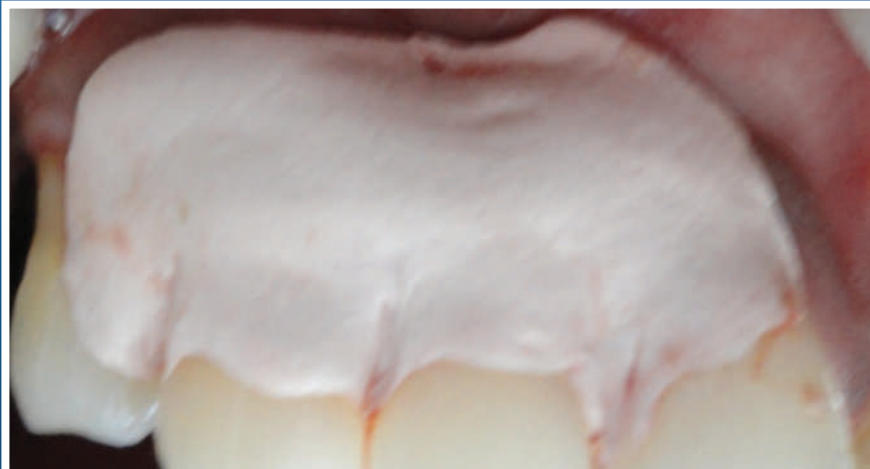

Sulcular incision - 12

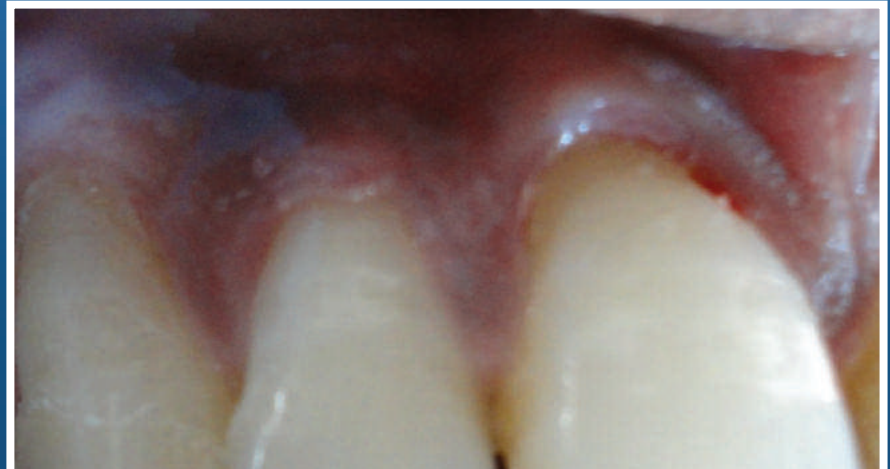

Flap advanced coronally

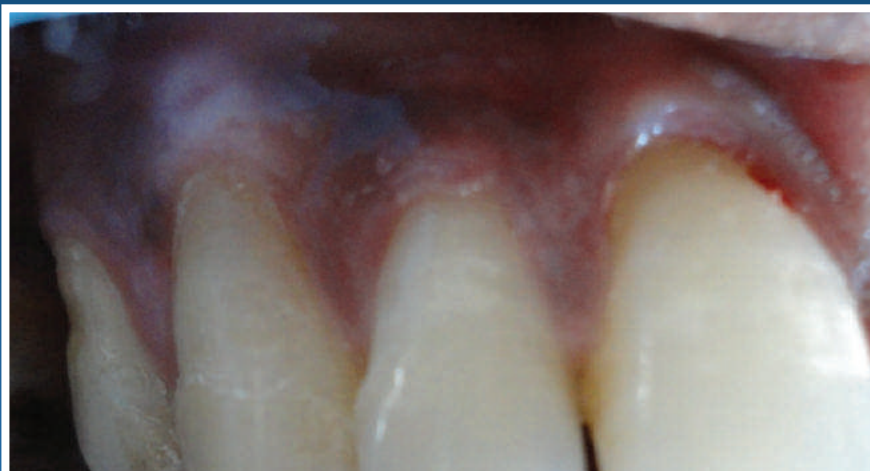



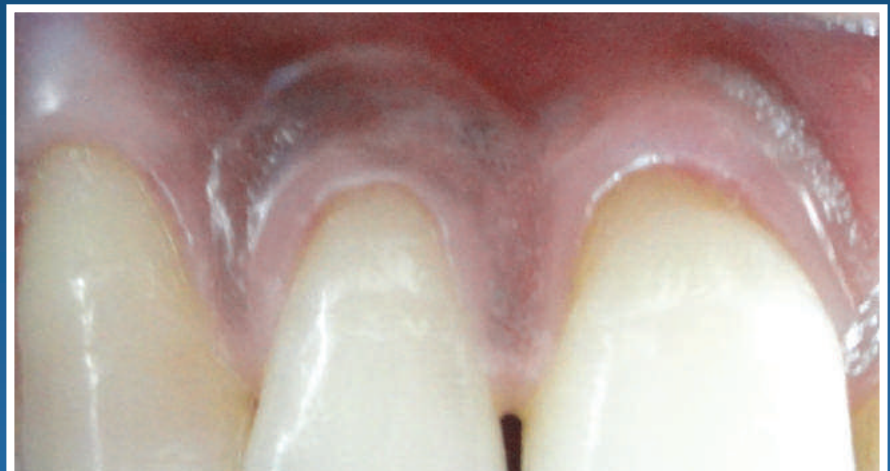After placing Periodontal pack



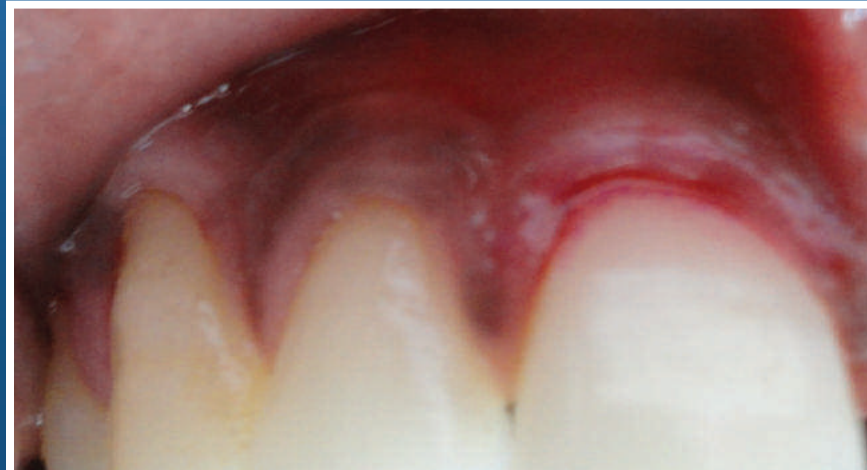Postoperative - One week



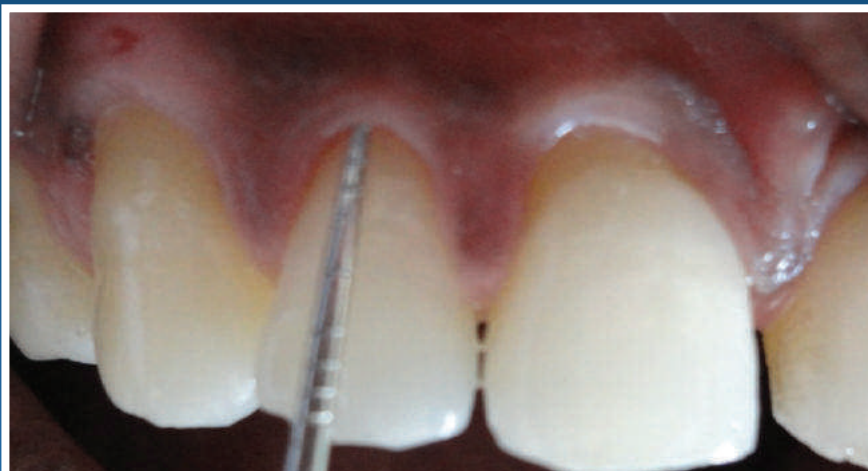Postoperative - One month



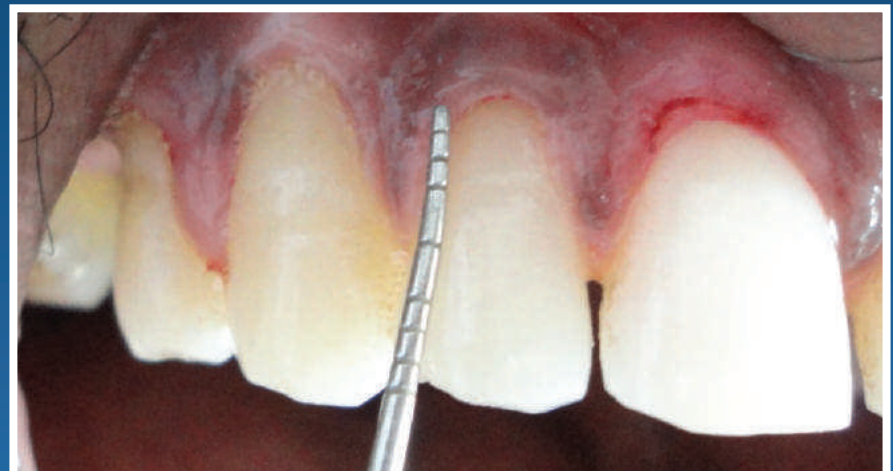Postoperative - Three months



Postoperative - Six months



Preoperative



Postoperative

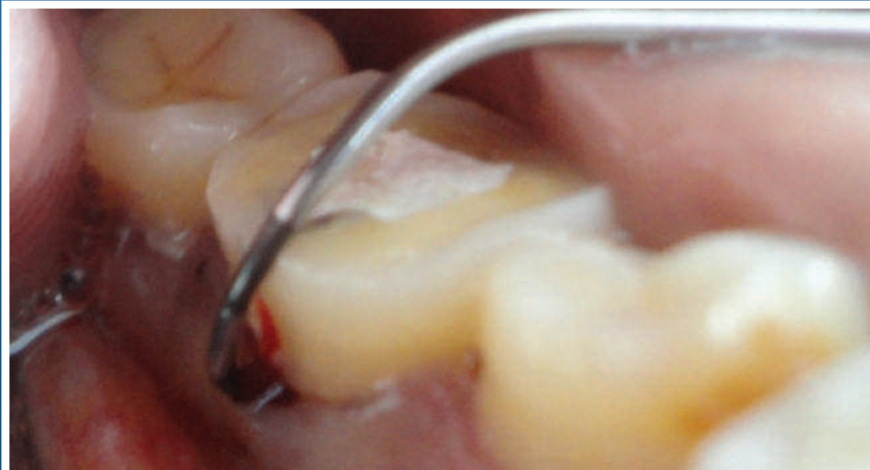## **BONE GRAFTING & GTR**

Patient Name: **MR.MANIMARAN**

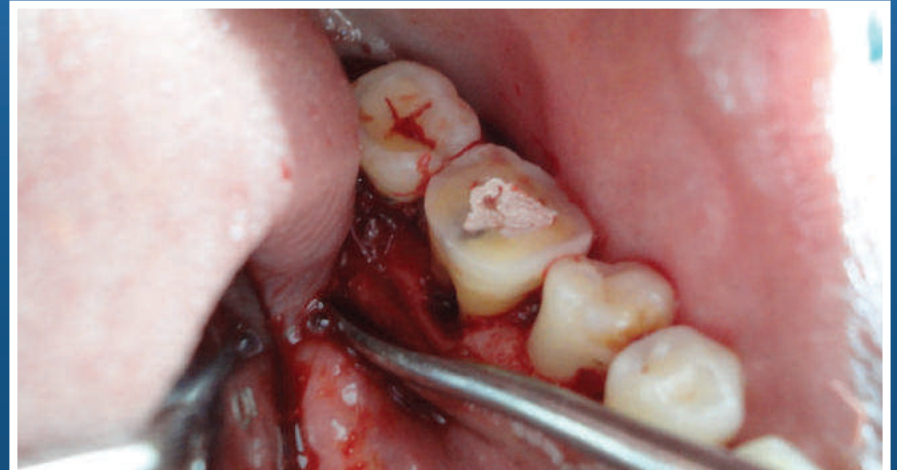Age/Sex : **31Y/M**

Op No : **137333**

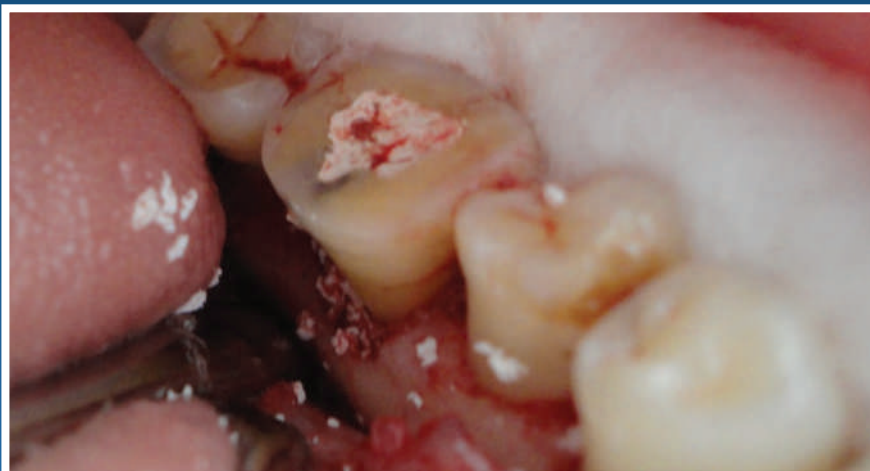



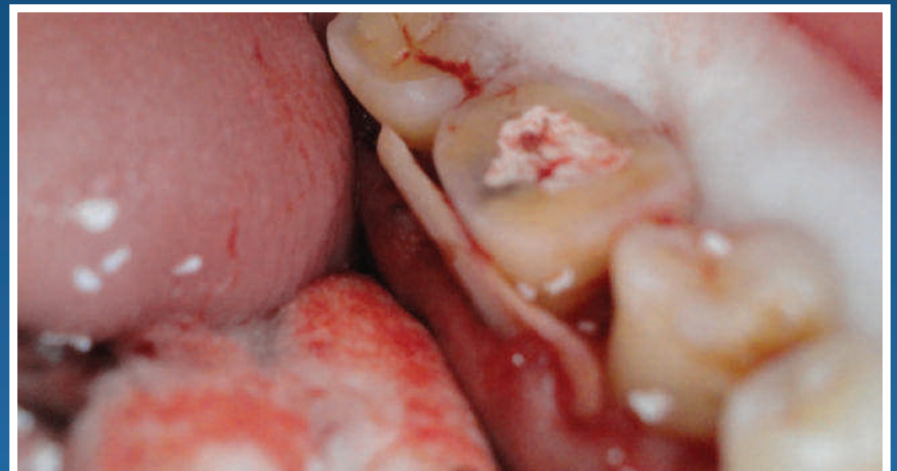After RCT - Preoperative Endo-perio Lesion - 36



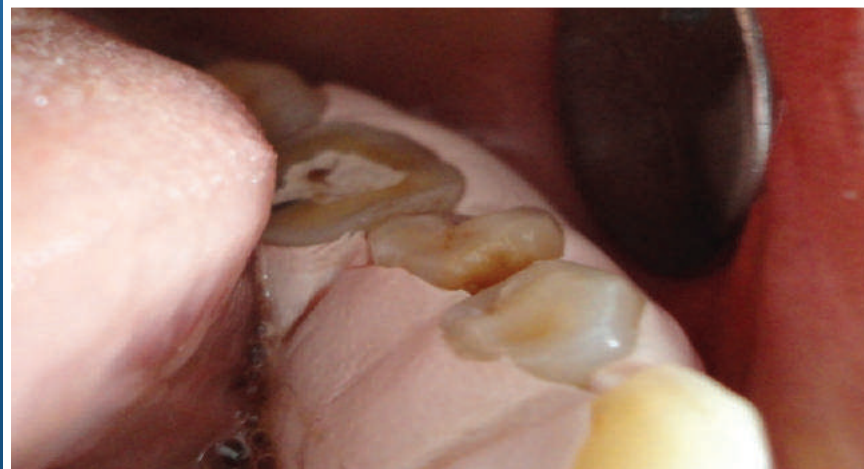Grade II Furcation - 36



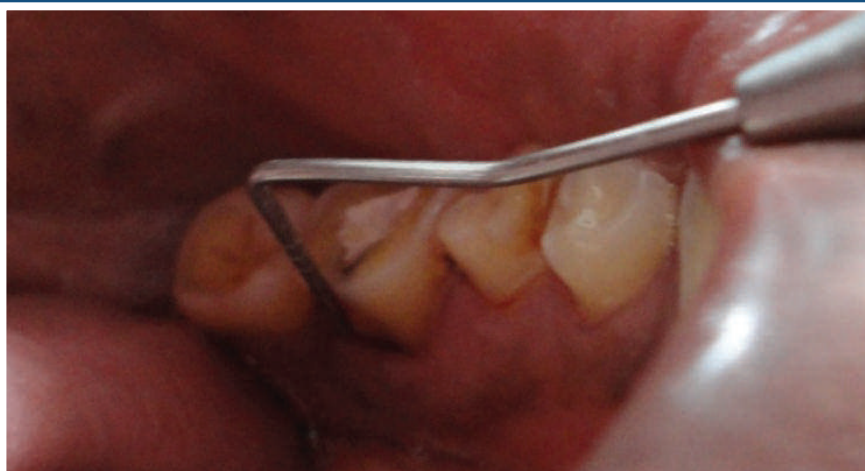Bone Grafting - 36



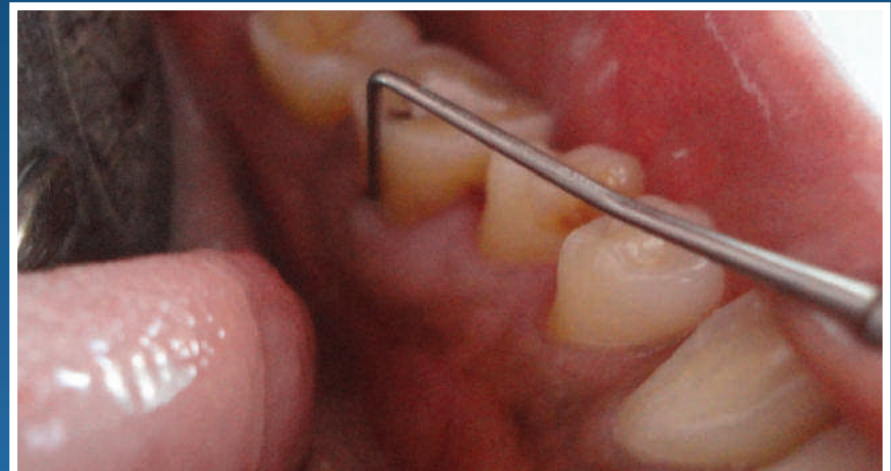GTR membrane placement - 36



After placing periodontal pack



Three months postoperative - Reduction of probing depth to 3mm in 36



Six months postoperative - Reduction of probing depth to 3mm in 36

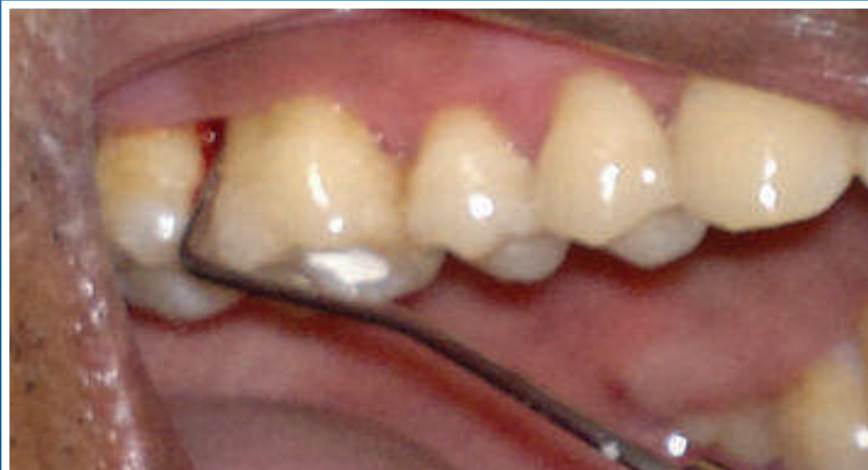## ROOT RESECTION

Patient Name: **MR.MARIMUTHU**

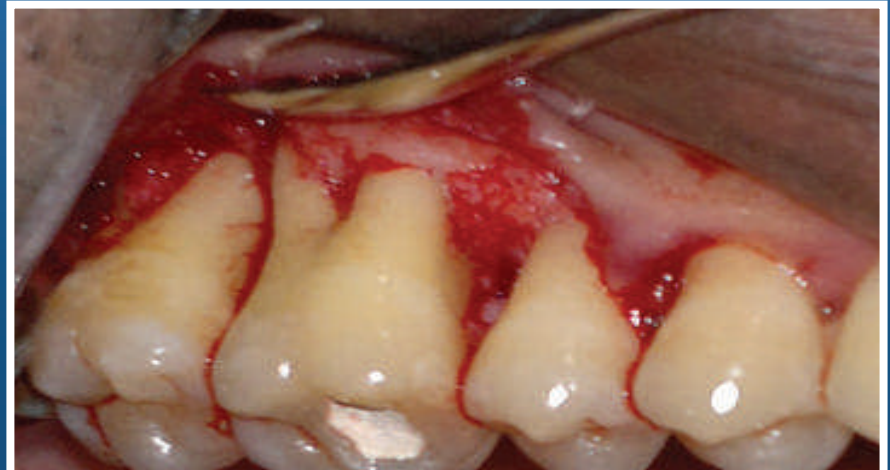Age/Sex : **45Y/M**

Op No : **201704150086**

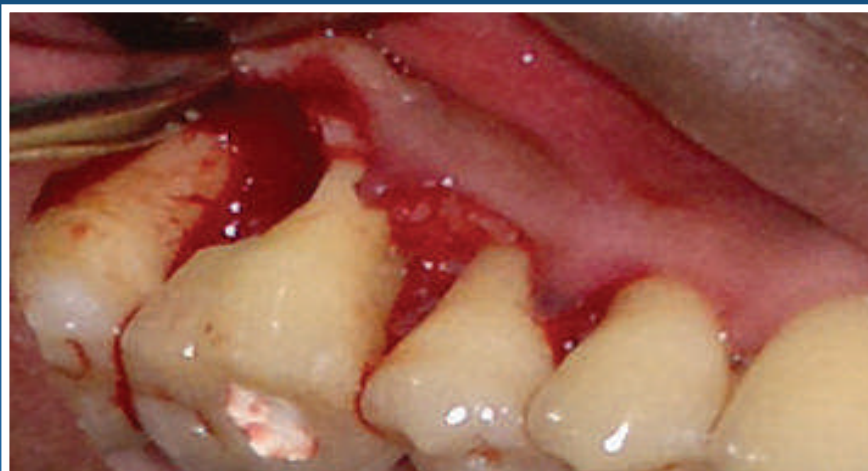




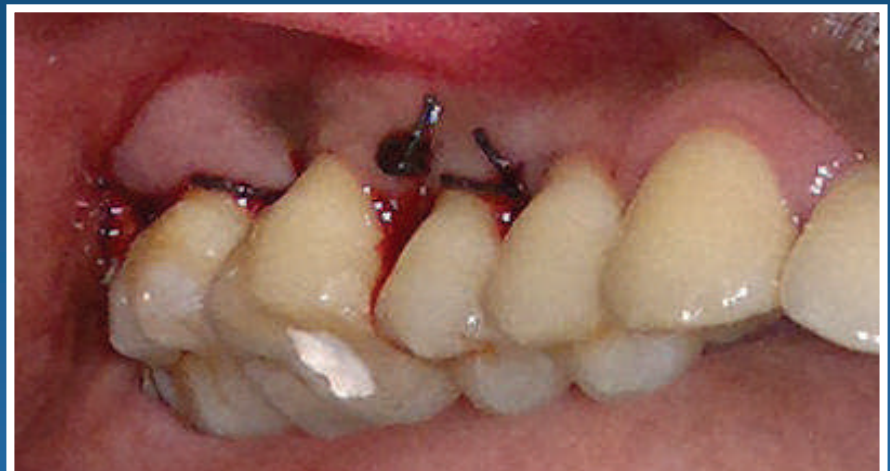Preoperative - Probing depth of 8mm in 16



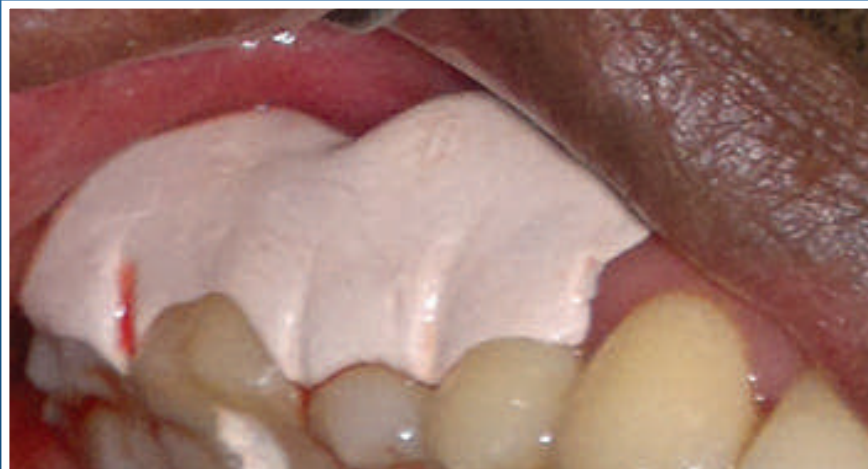After flap elevation - 16



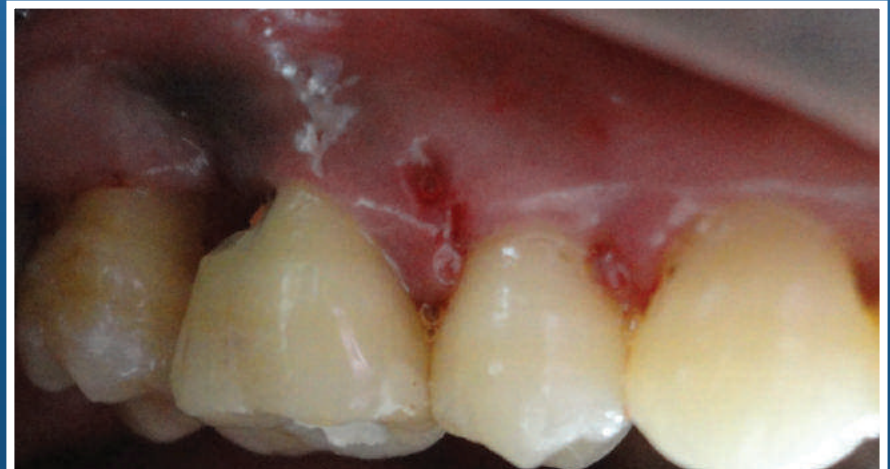After Distobuccal root resection - 16



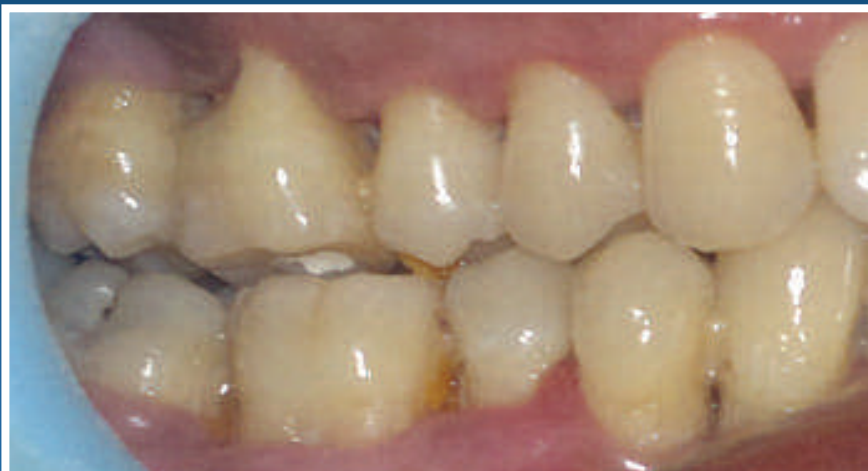After suturing



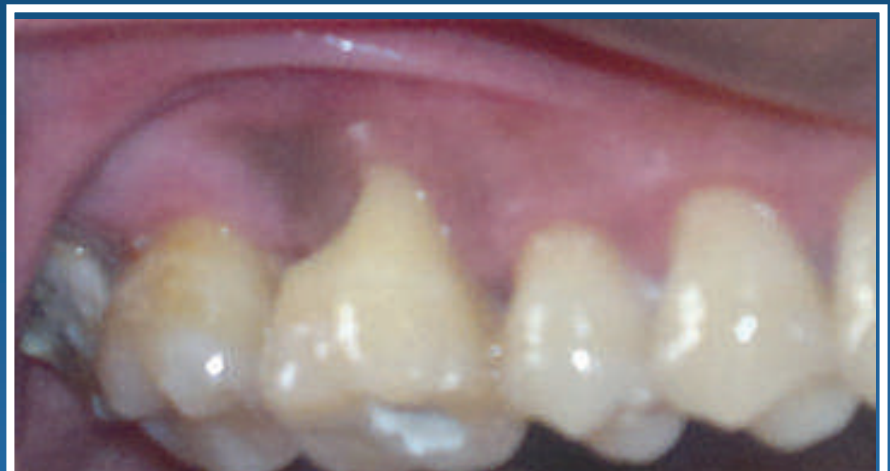After placing periodontal pack



Postoperative - One week



Postoperative - One month



Postoperative - Three months

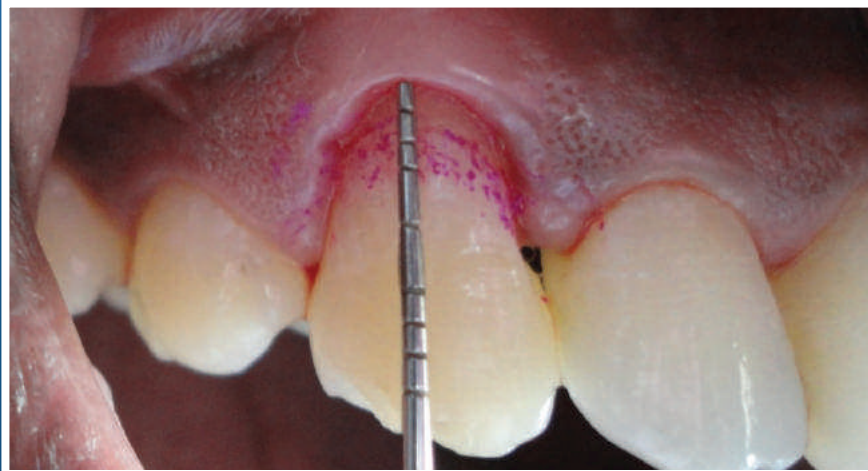# **MILLERS CLASS I GINGIVAL RECESSION CORONALLY ADVANCED FLAP**

Patient Name: **MR.SRINIVASAN**

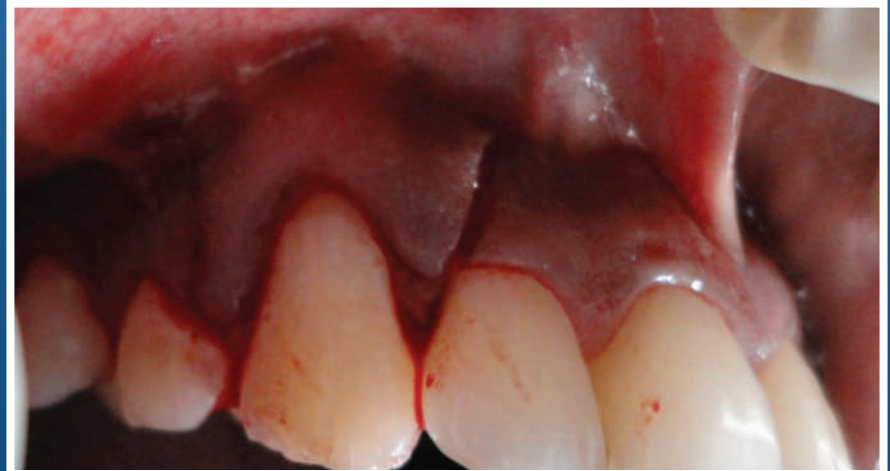Age/Sex : **35Y/M**

Op No : **207042001391**

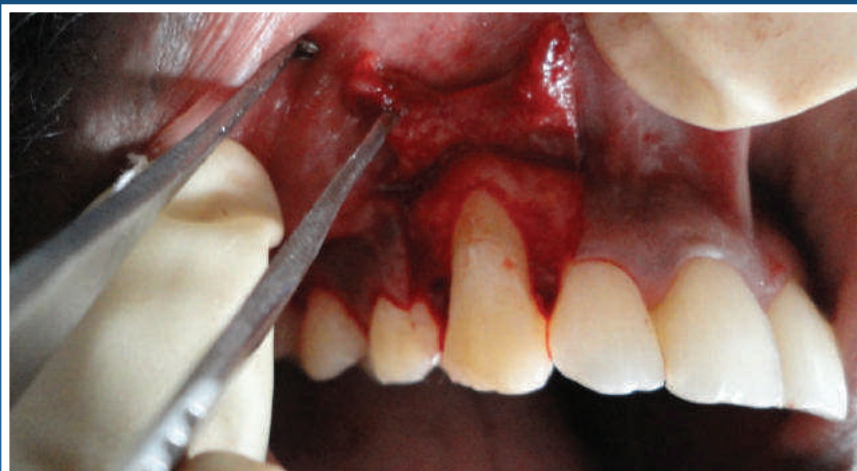



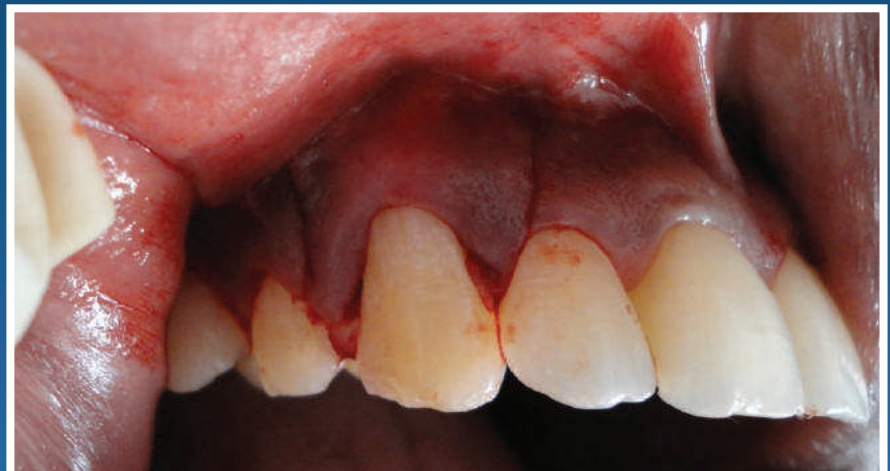After placing periodontal pack



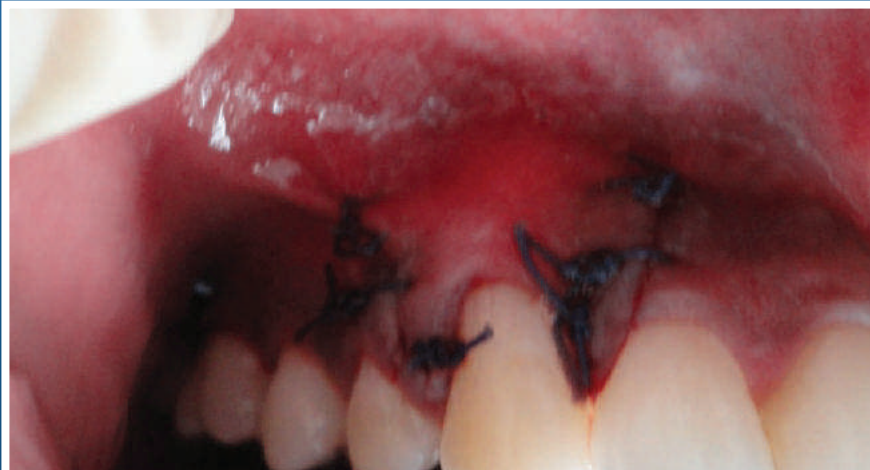After vertical incisions - 13



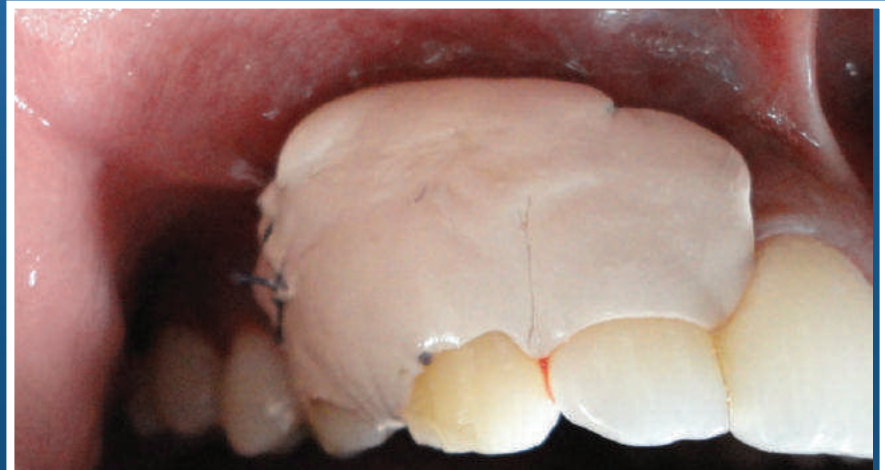After flap elevation - 13



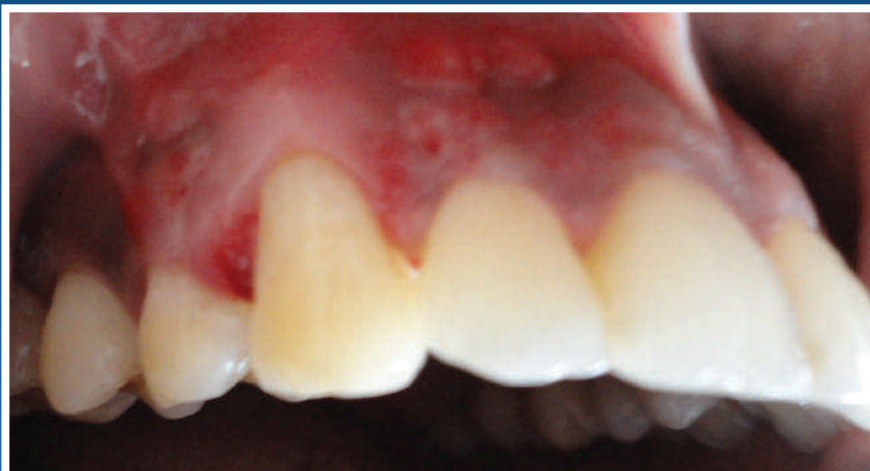After coronally advancing the flap



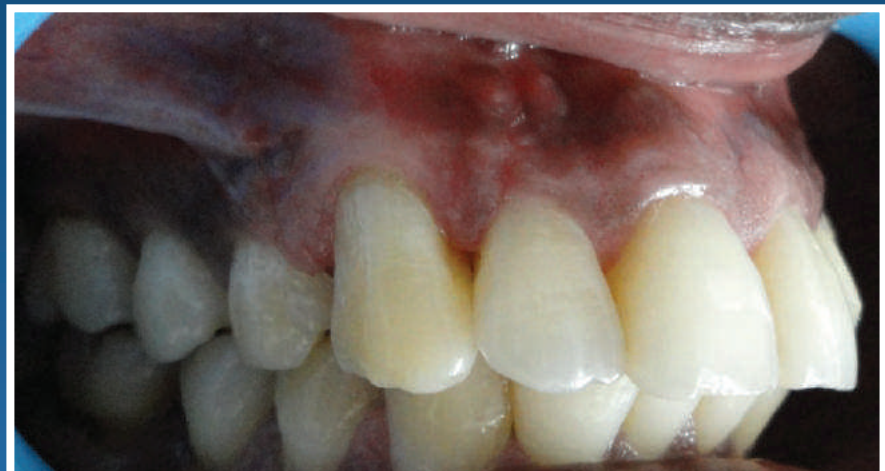After suturing



After placing periodontal pack



Postoperative - Two weeks



Postoperative - One month

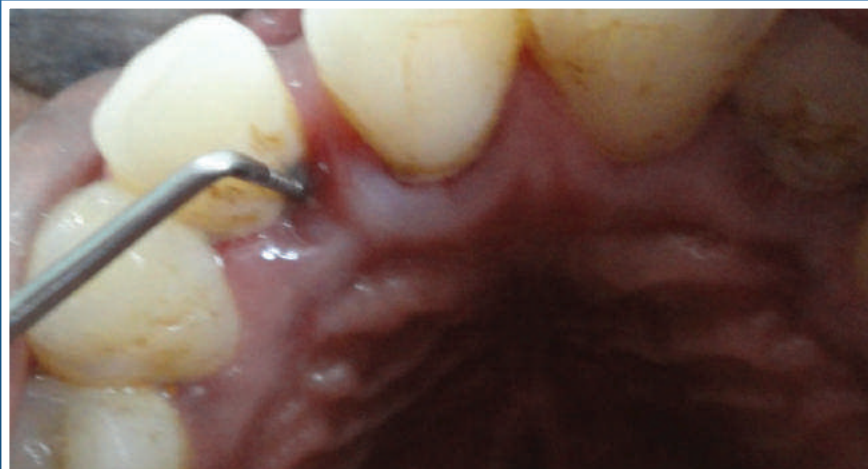# **PALATORADICULAR GROOVE**

Patient Name: **MRS.SUGANTHI**

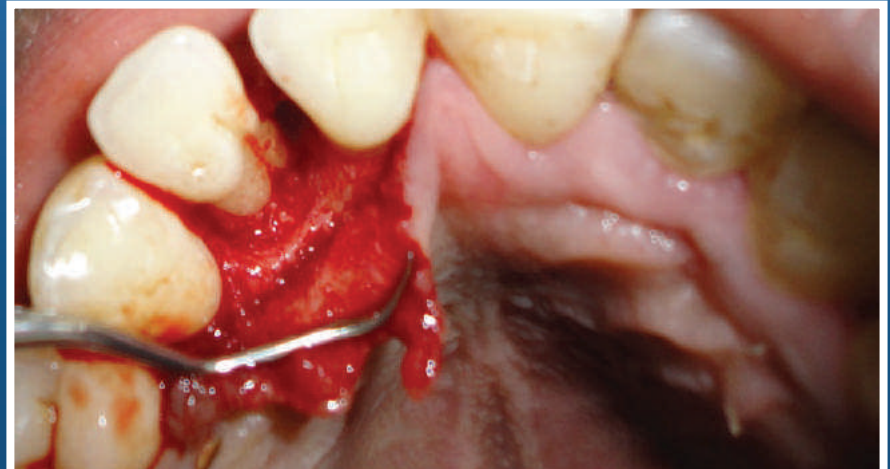
Age/Sex : **38 Y/F**

Op No : **201704180114**

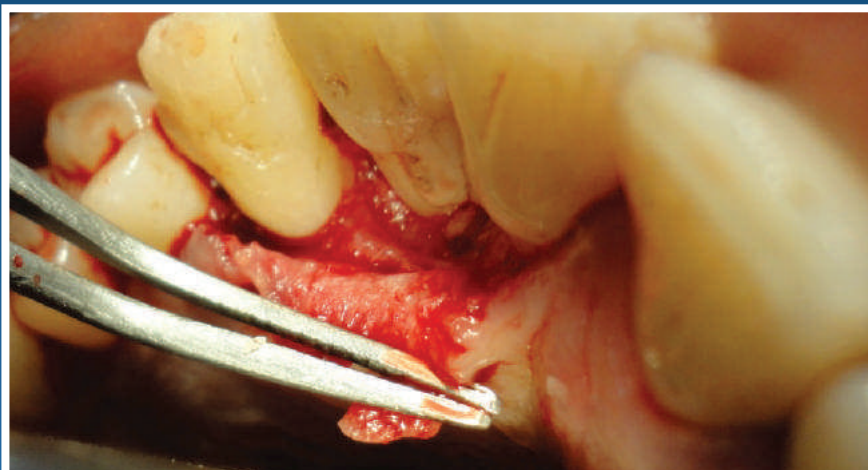



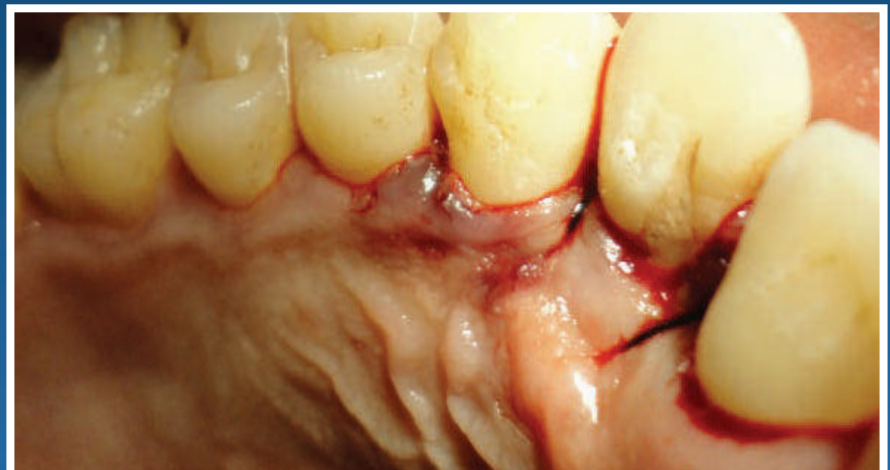Preoperative - Probing depth of 8mm in 12



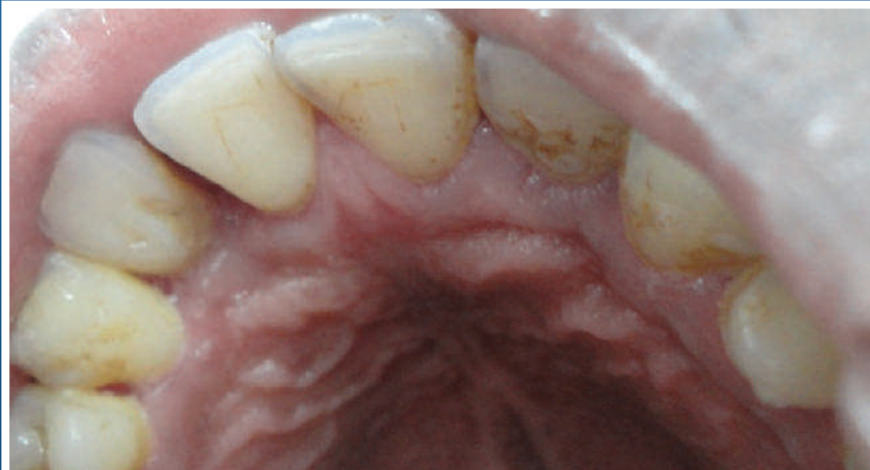Palatoradicular Groove - 12



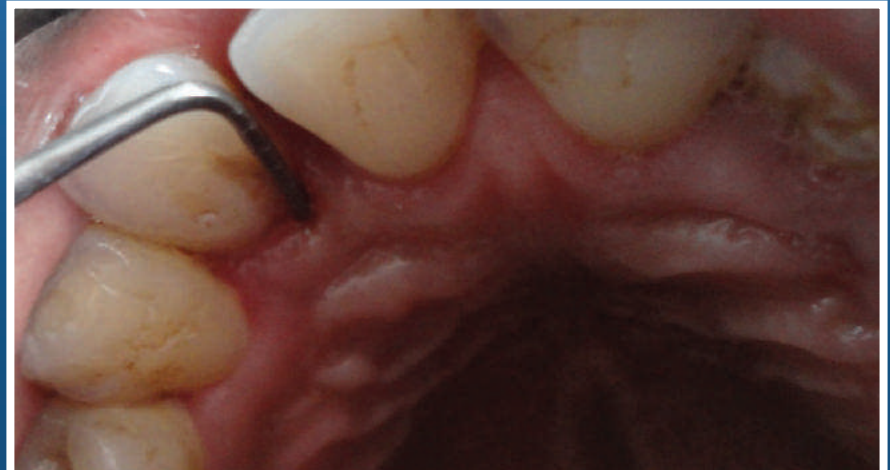After GIC Restoration -12



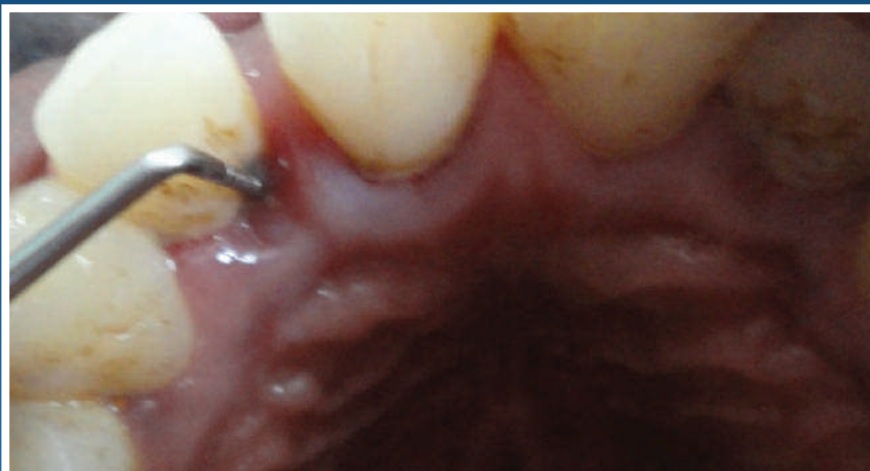After Suturing



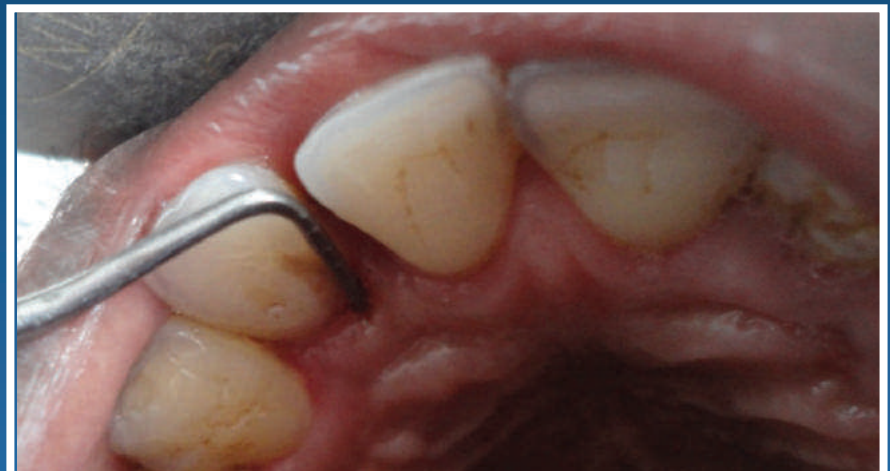Postoperative - two weeks



Postoperative - Three months Pocket Of Probing  
Depth 4mm - 12



Preoperative



Postoperative



