

CHETTINAD DENTAL COLLEGE

DEPARTMENT OF PERIODONTICS

CASE ALBUM- SPECIAL CASES

SCALING AND ROOT PLANNING

Case-1

DEMOGRAPHIC DATA

PATIENT NAME: Mr. Sahileesh yadeev

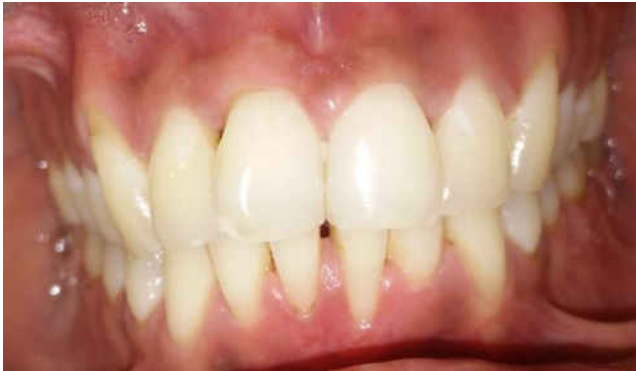DATE: 9.12.2017

OP NO: 201711110007

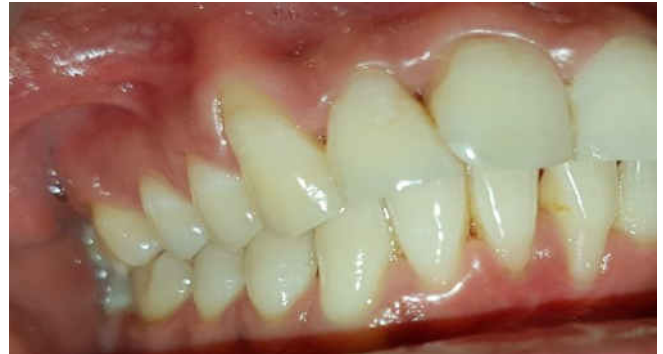AGE/SEX: 26/M

PROCEDURE: Gingival curettage done in relation to 17,47

PRE OPERATIVE PHOTO – 9.12.2017

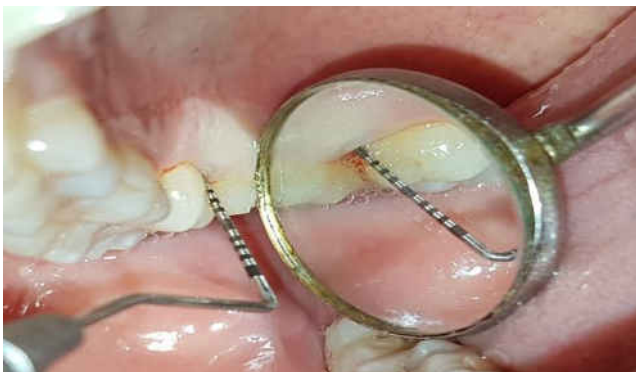

Frontal view

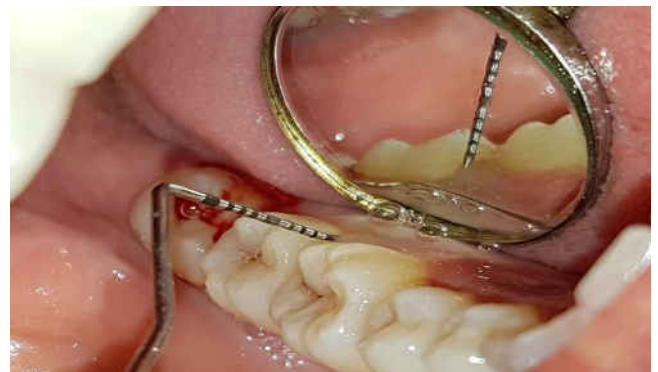

Left lateral view

PRE OPERATIVE MEASUREMENTS

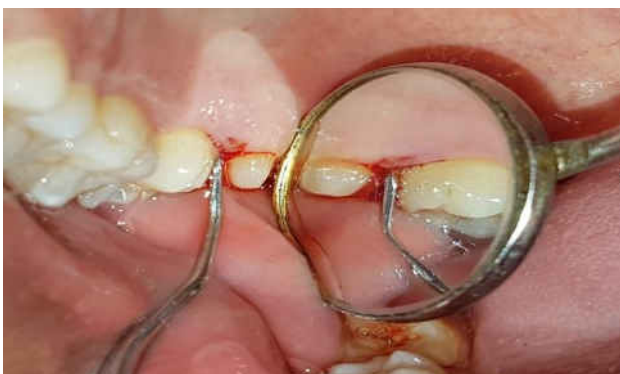

PPD –5mm in distopalatal aspect of 17

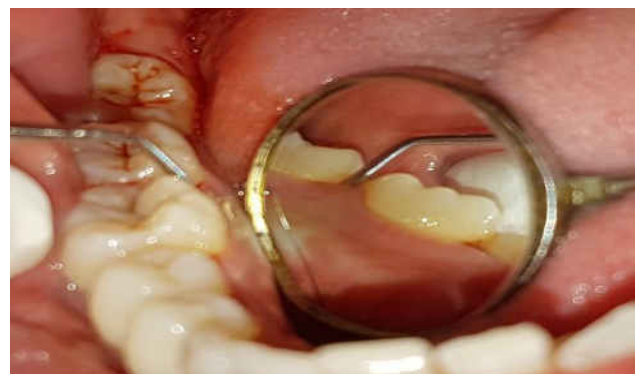


PPD –5mm in mesiolingual aspect of 47

OPERATIVE PHOTO- 2.2017

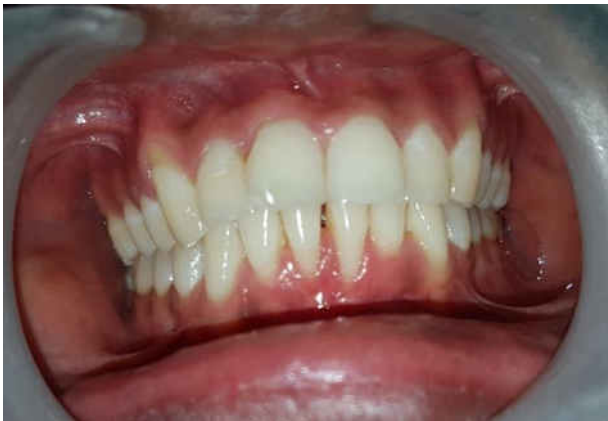

Gingival curettage in 17 distopalatal aspect

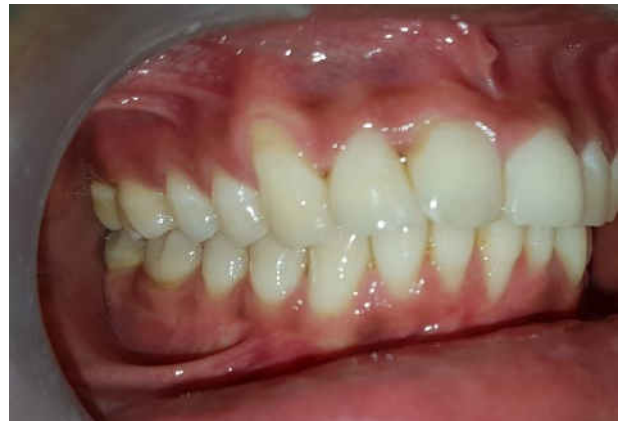

Gingival curettage in 47 mesiolingual aspect

POST OPERATIVE PHOTO – 1 MONTH

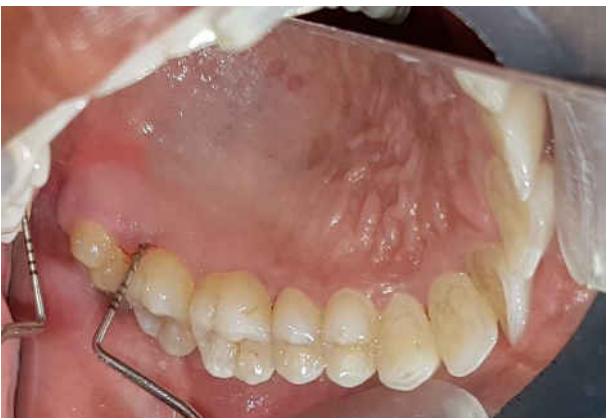

Frontal view

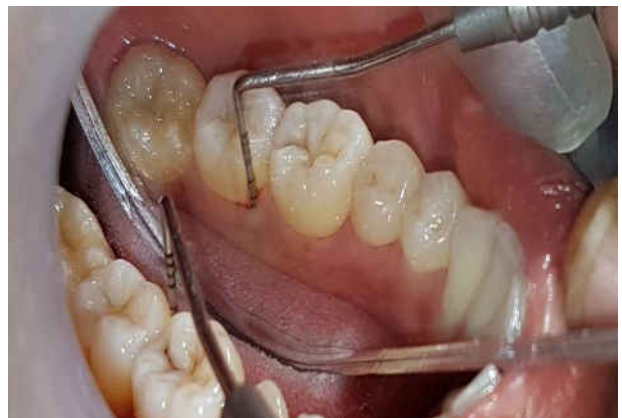

Right lateral view

POST OPERATIVE PHOTO – 3 MONTH



PPD –2mm in distobuccal aspect of 17



PPD–3 mm in mesiolingual aspect of 47

Case-2

DEMOGRAPHIC DATA

PATIENT NAME: Mr. Thomas

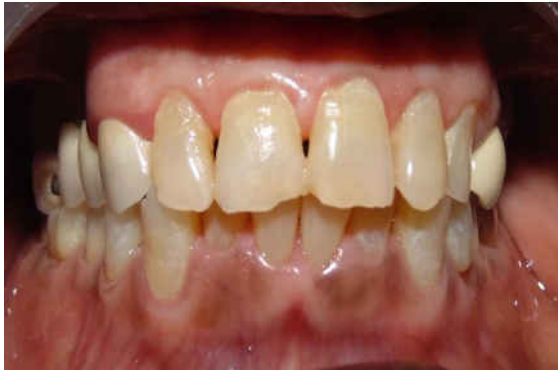DATE: 18.9.2017

OP NO: 201709180002

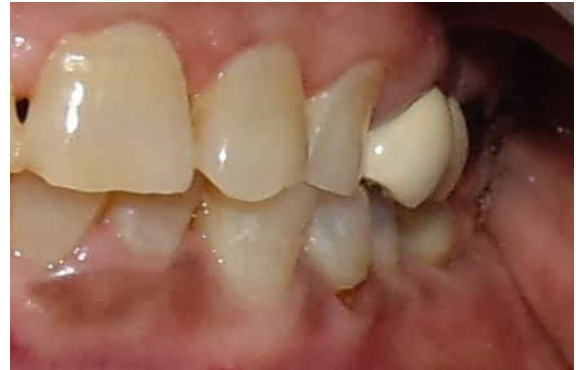AGE/SEX: 62/M

PROCEDURE: Gingival curettage done in relation to 16, 27

PRE OPERATIVE PHOTO – 18.9.2017

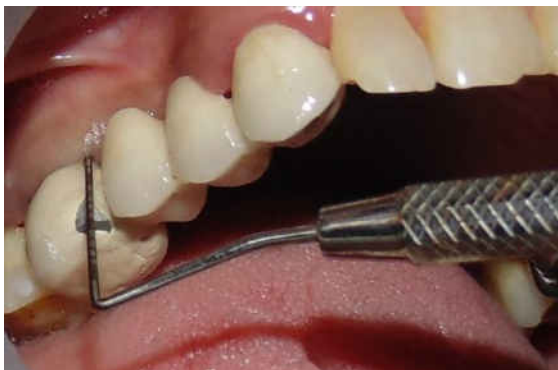

Front view

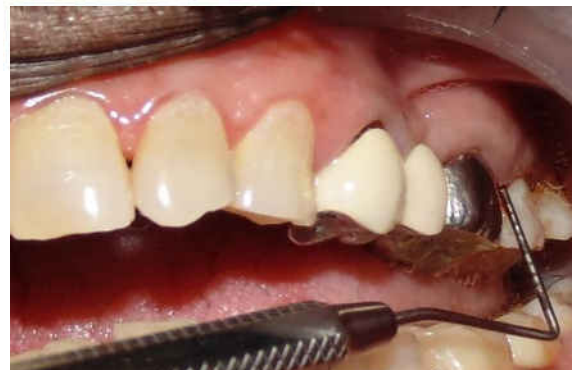

Left lateral view

PRE OPERATIVE MEASUREMENTS

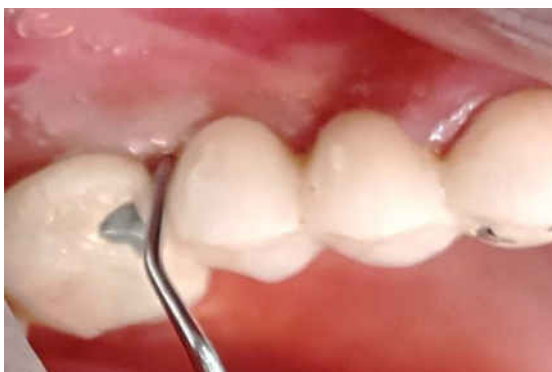

PPD –5mm in mesiobuccal aspect of 16

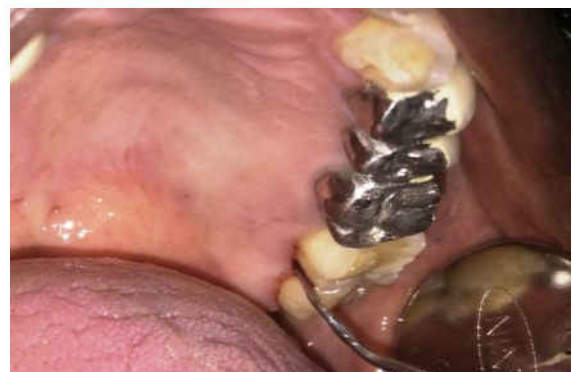

PPD–5mm in mesiobuccal aspect of 27

OPERATIVE PHOTO-25.9.2017

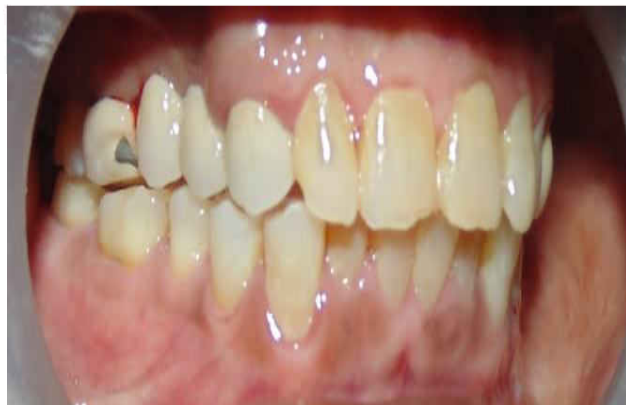

Gingival curettage in 16 –mesiobuccal aspect



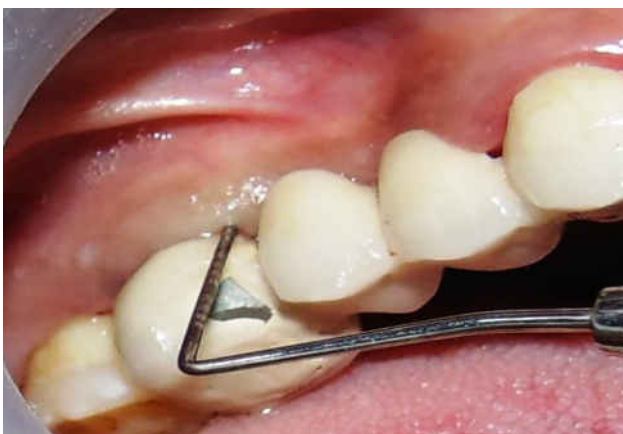Gingival curettage in 27 -distolingual aspect

POST OPERATIVE PHOTO – 1 MONTH

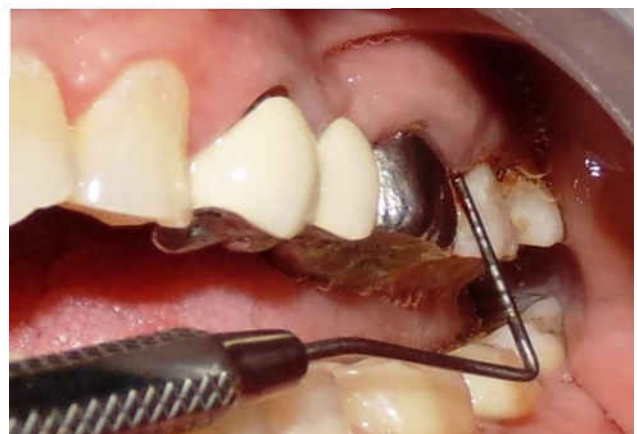

Front view

POST OPERATIVE PHOTO – 3 MONTH



PPD- 3mm in 16 mesiobuccal aspect



PPD- 3mm in 27 mesiobuccal aspect

Case-3

DEMOGRAPHIC DATA

PATIENT NAME: Mrs. Nirmala

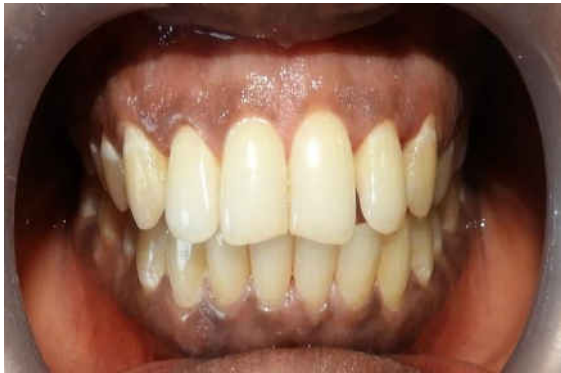DATE: 9.10.2017

OP NO: 201709260010

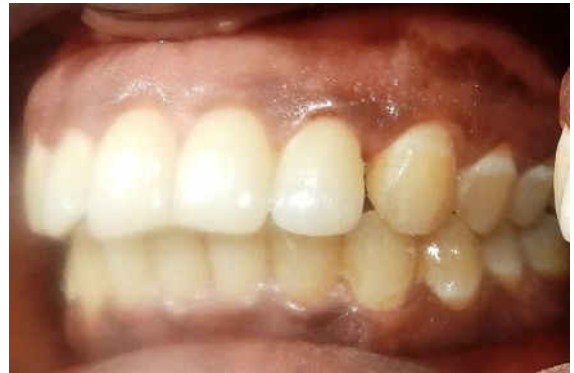AGE/SEX: 45/F

PROCEDURE: Gingival curettage done in relation to 13

PRE OPERATIVE PHOTO – 9.10.2017

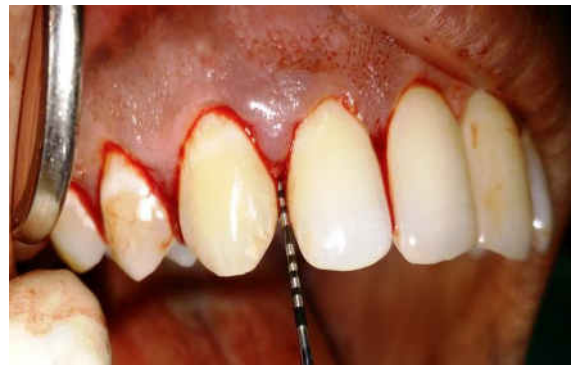

Frontal view

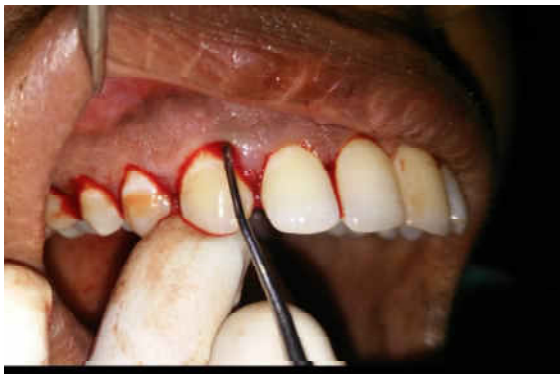

Right lateral view

PRE OPERATIVE MEASUREMENTS



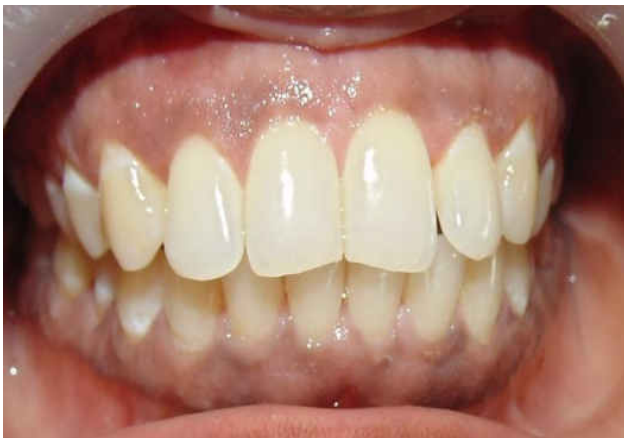PPD –6mm in mesiobuccal aspect of 13



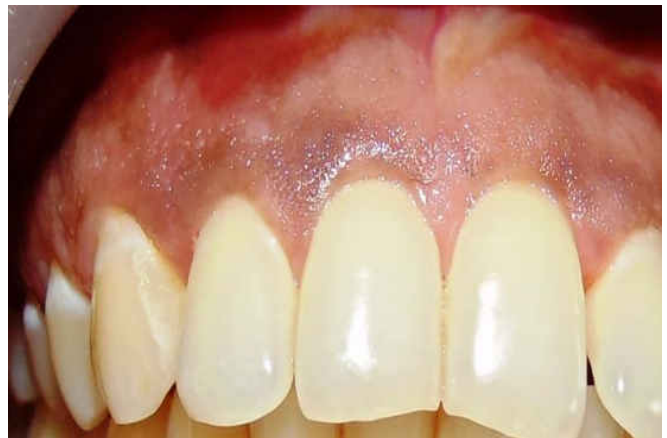Gingival curettage in 13 -mesiobuccal aspect

OPERATIVE PHOTO-13.10.2017

POST OPERATIVE PHOTO – 1 MONTH

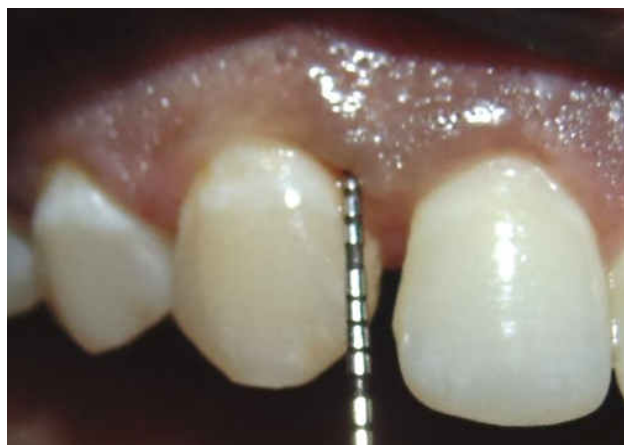

Frontal view



Right lateral view

POST OPERATIVE PHOTO – 3 MONTH



PPD –3mm in mesio Buccal aspect of 13

Case-4

DEMOGRAPHIC DATA

PATIENT NAME: Mr. Zahir Hussain

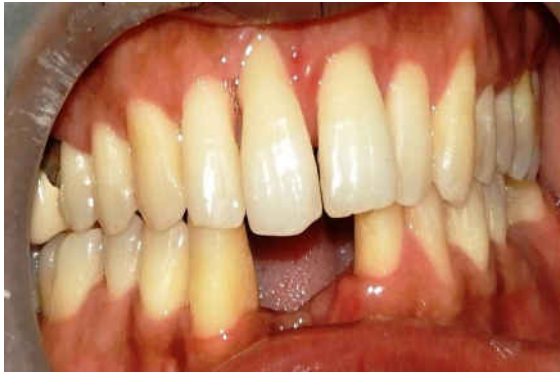DATE: 13.10.2017

OP NO: 201710120068

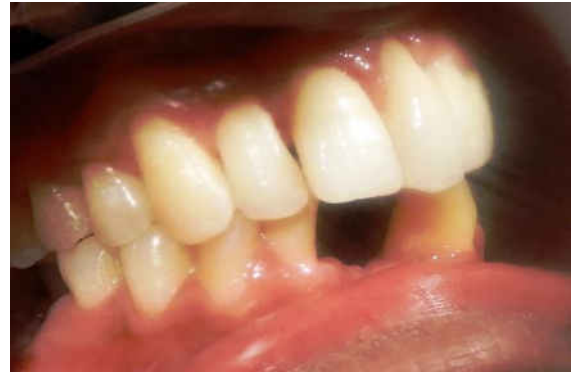AGE/SEX: 36/M

PROCEDURE: Gingival curettage done in relation to 21,37

PRE OPERATIVE PHOTO – 13.10.2017

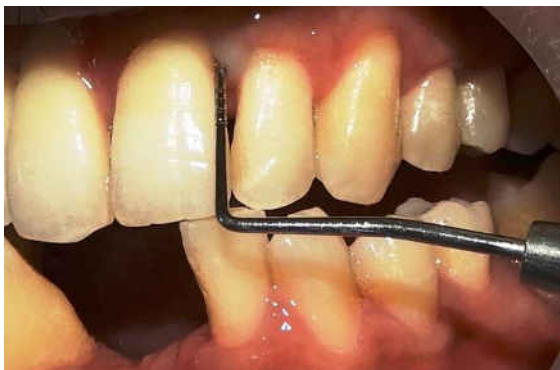

Frontal view

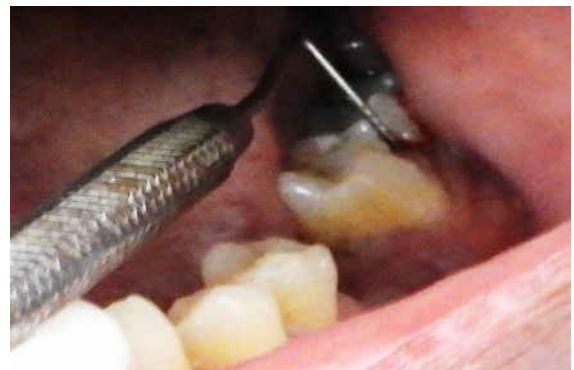

Left lateral view

PRE OPERATIVE MEASUREMENTS

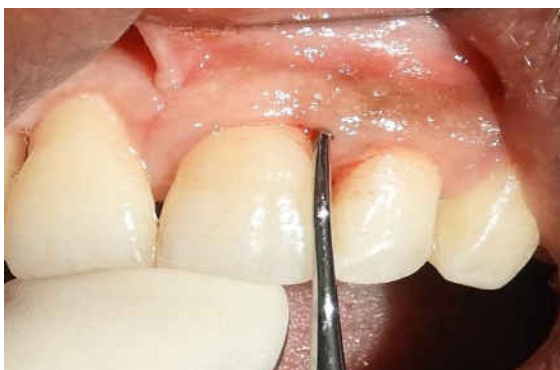

PPD -5mm in distobuccal aspect of 21

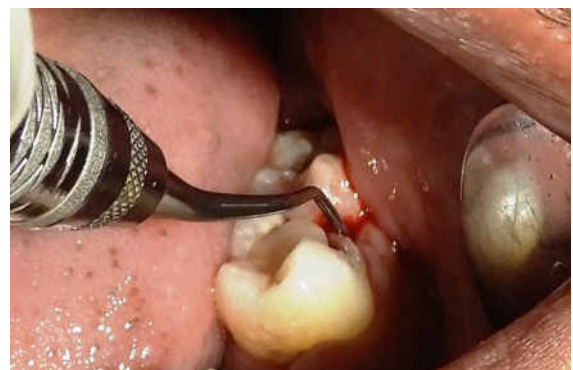

PPD- 5mm in distobuccal aspect of 37

OPERATIVE PHOTO- 17.10.2017

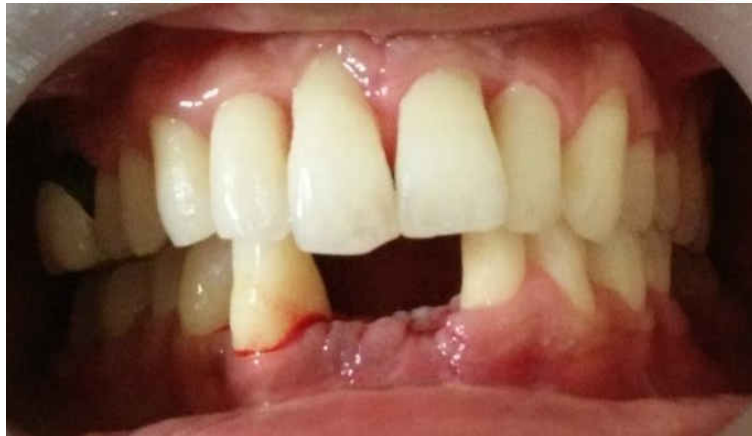

Gingival curettage in 21 distobuccal aspect



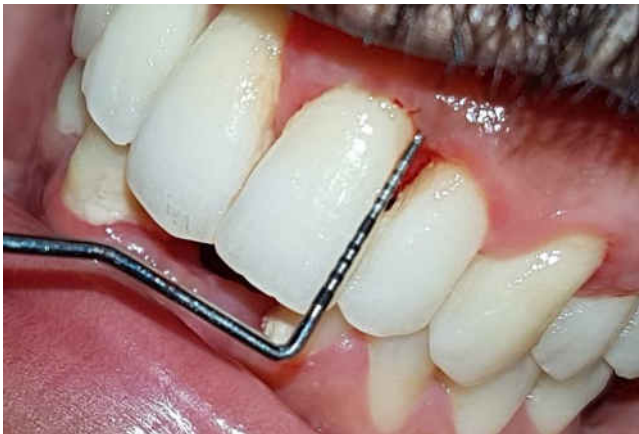Gingival curettage in 37 distobuccal aspect

POST OPERATIVE PHOTO – 1 MONTH

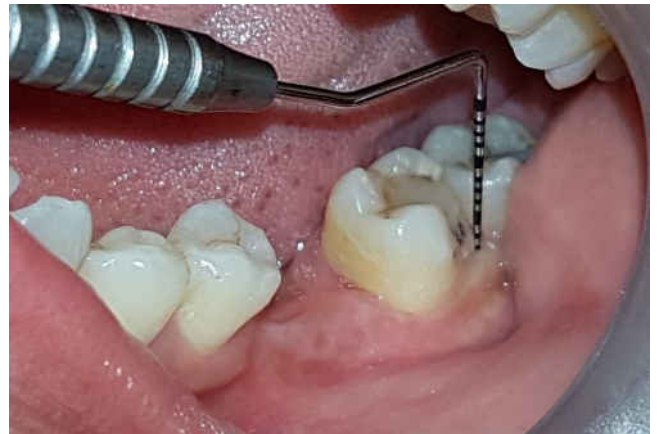

Frontal view

POST OPERATIVE PHOTO – 3 MONTH



PPD- 3mm in 21 distobuccal aspect



PPD- 3mm in 37 distobuccal aspect

Case-5

DEMOGRAPHIC DATA

PATIENT NAME: Mr. Gangadharan

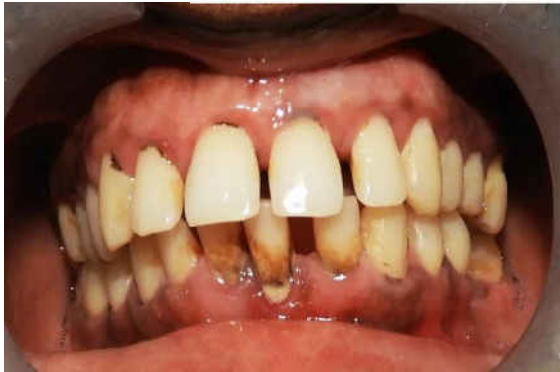DATE: 18.11.2017

OP NO: 20171110072

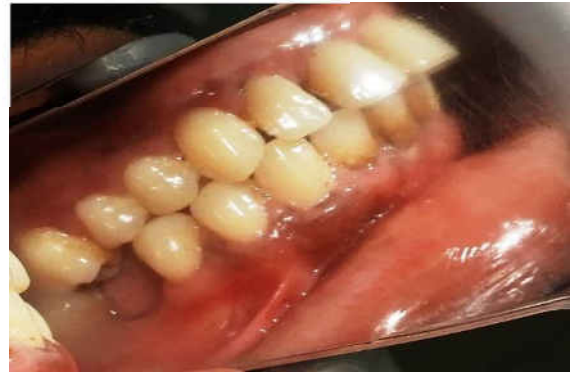AGE/SEX: 34/M

PROCEDURE: Gingival curettage done in relation to 22,26

PRE OPERATIVE PHOTO – 18.11.2017

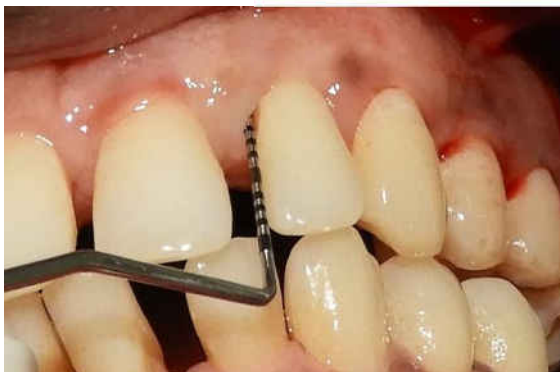

Frontal view

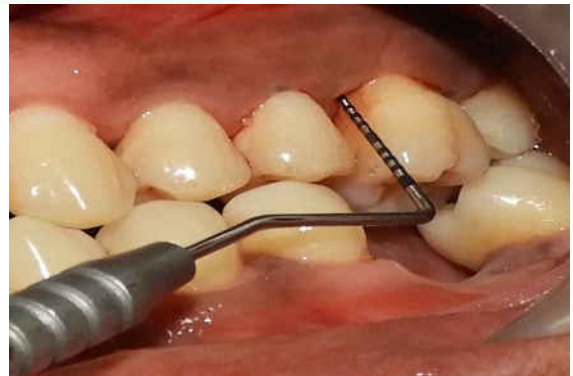

Left lateral view

PRE OPERATIVE MEASUREMENTS

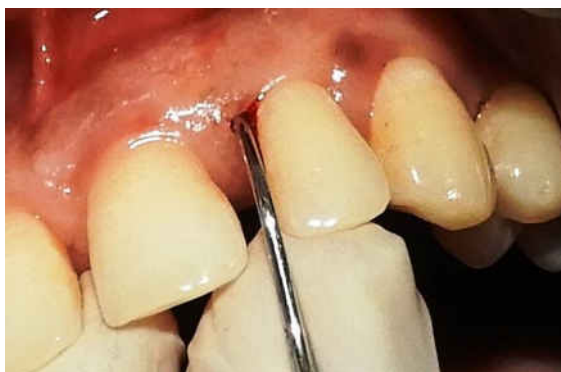

PPD –5mm in mesiobuccal aspect of 22

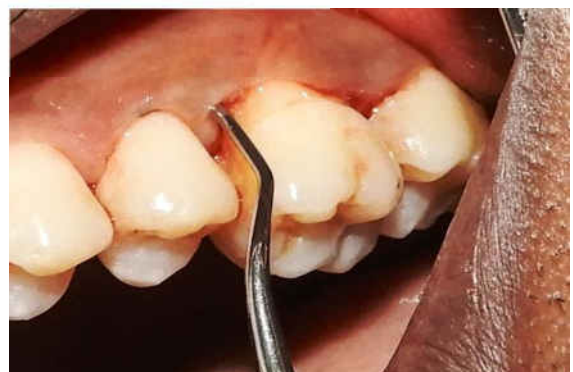

PPD –5mm in mesiobuccal aspect of 26

OPERATIVE PHOTO-25.11.2017

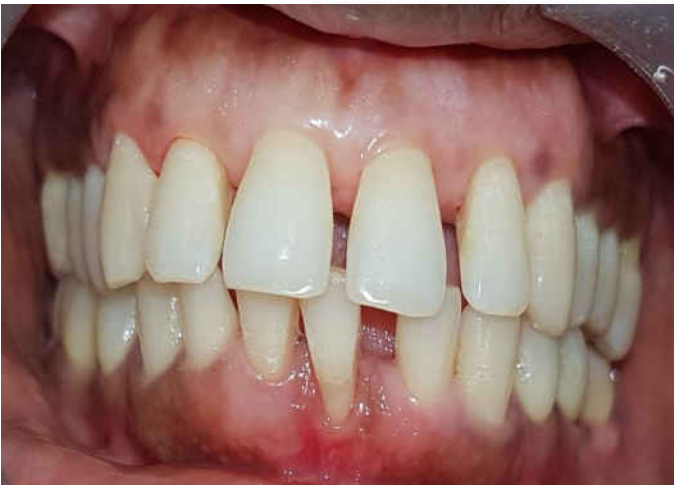

Gingival curettage in 22 mesiobuccal aspect

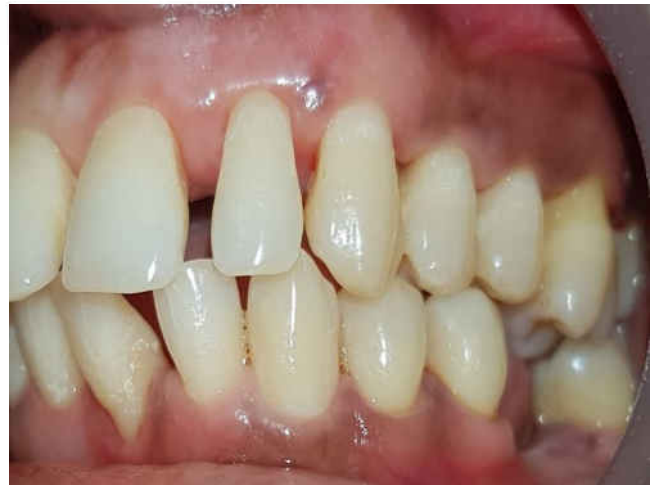

Gingival curettage in 26 mesiobuccal aspect

POST OPERATIVE PHOTO – 1 MONTH

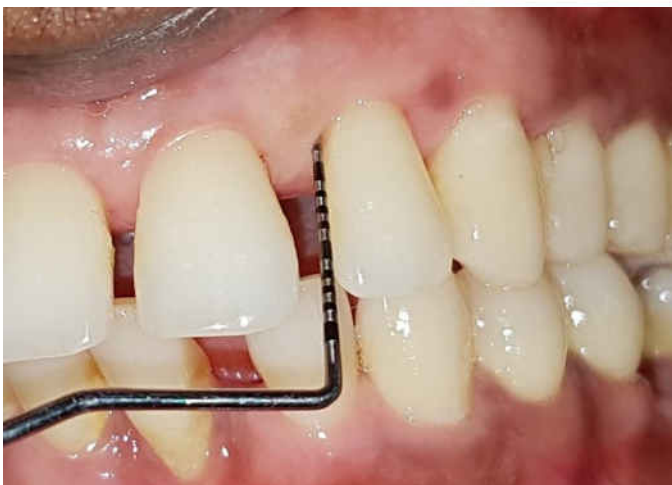

Frontal view

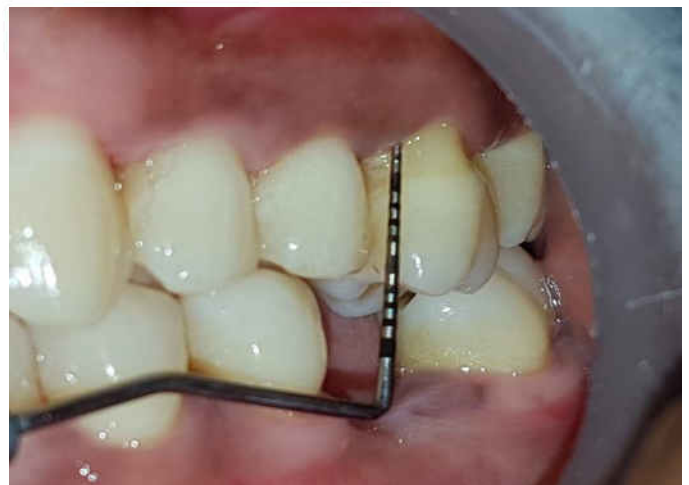

Left lateral view

POST OPERATIVE PHOTO – 3 MONTH



PPD –3mm in mesiobuccal aspect of 22



PPD –3mm in mesiobuccal aspect of 26

Case-6

DEMOGRAPHIC DATA

PATIENT NAME: Mrs. Indira

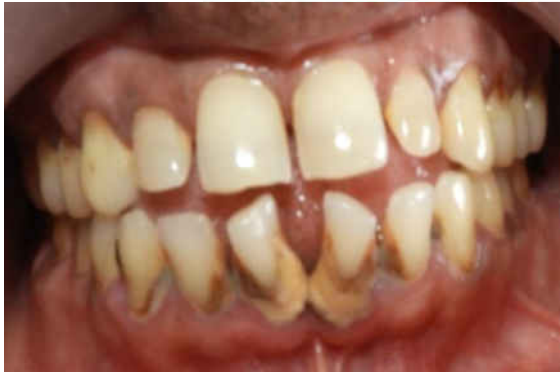DATE: 20.11.2017

OP NO: 20171120002

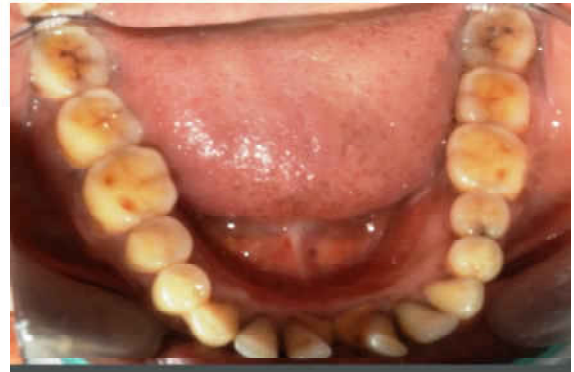AGE/SEX: 62/F

PROCEDURE: Gingival curettage done in relation to 46

PRE OPERATIVE PHOTO – 20.11.2017

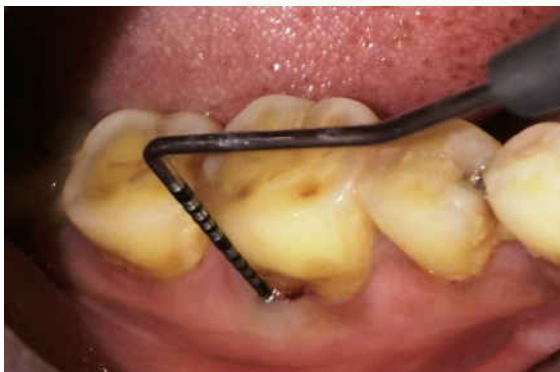

Frontal view

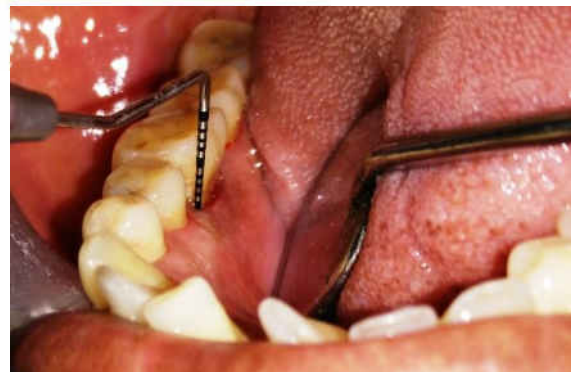

Lower occlusal view

PRE OPERATIVE MEASUREMENTS

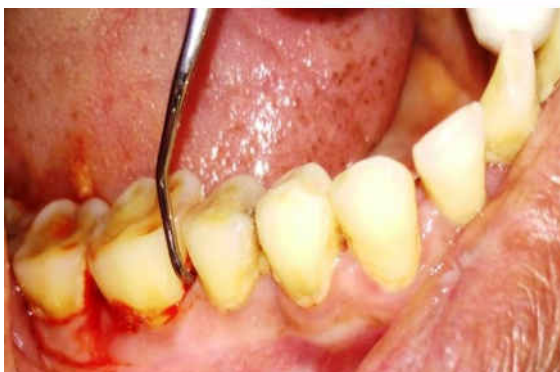

PPD–5mm in distobuccal aspect of 46

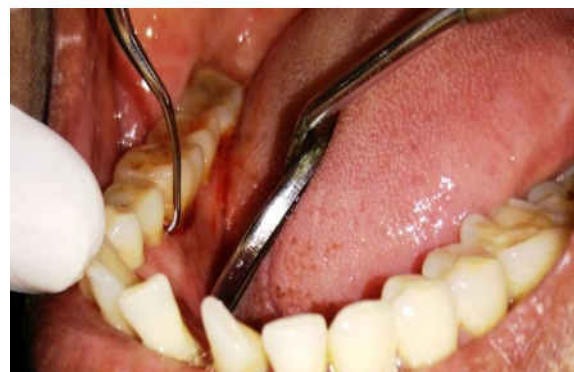

PPD–5mm in mesiolingual aspect of 46

OPERATIVE PHOTO-27.11.2017

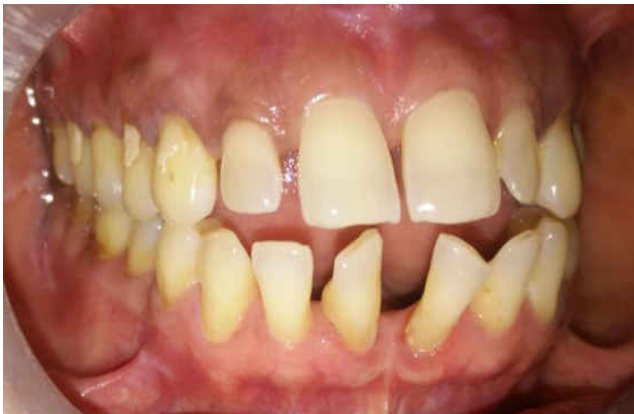

Gingival curettage in 46 mesiobuccal aspect

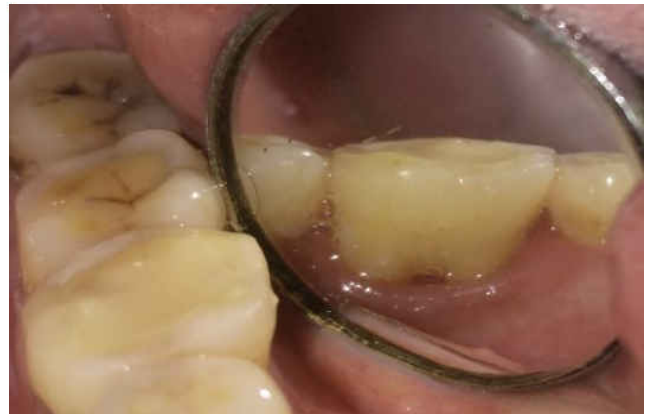

Gingival curettage in 46 mesiolingual aspect

POST OPERATIVE PHOTO -1 MONTH

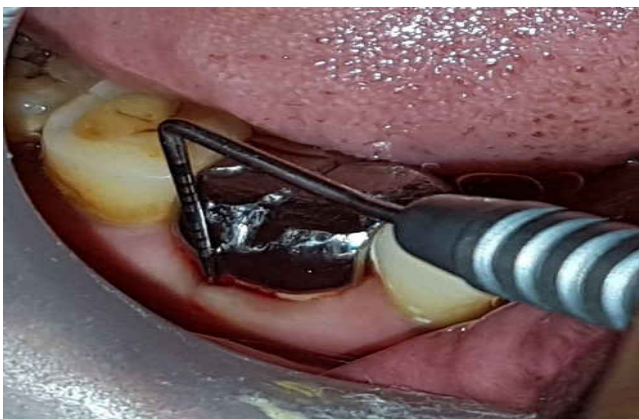


Frontal view

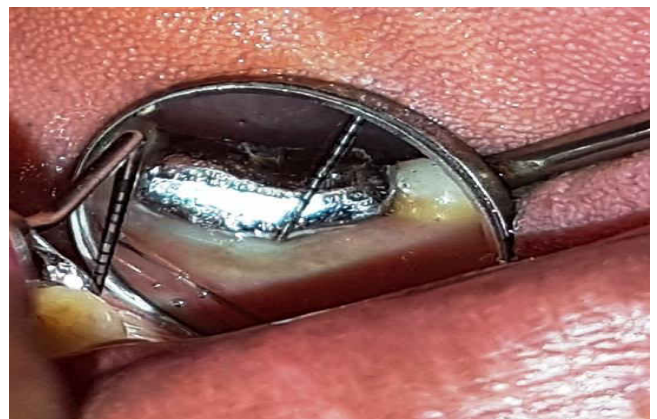

Lingual aspect of 46

POST OPERATIVE PHOTO – 3 MONTH



PPD- 3mm in midbuccal aspect of 46



PPD- 3mm in midlingual aspect of 46

Case-7

DEMOGRAPHIC DATA

PATIENT NAME : Mr. Krishnamoorthy

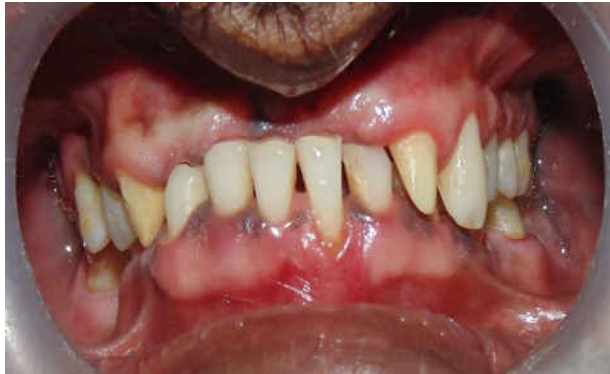DATE: 5.1.2018

OP NO: 201712110007

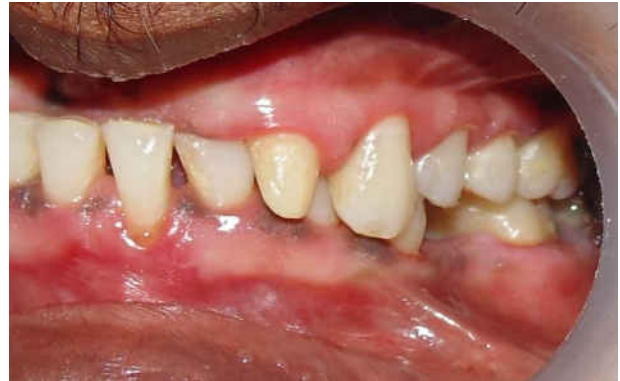AGE/SEX: 33/M

PROCEDURE: Gingival curettage done in relation to 31,36

PRE OPERATIVE PHOTO – 5.1.2018

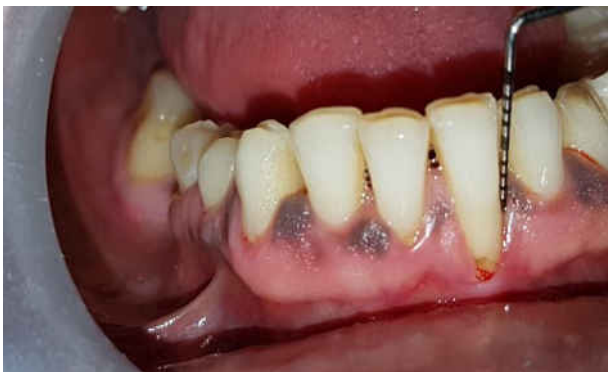

Frontal view

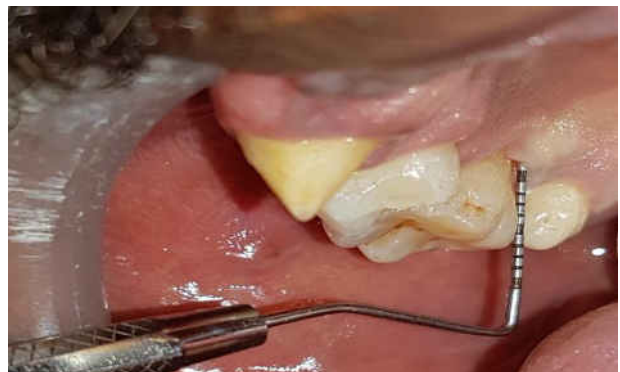


Left lateral view

PRE OPERATIVE MEASUREMENTS

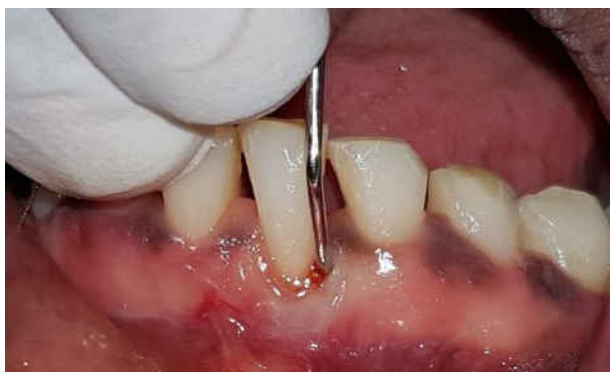

PPD–5mm in distobuccal aspect of 31

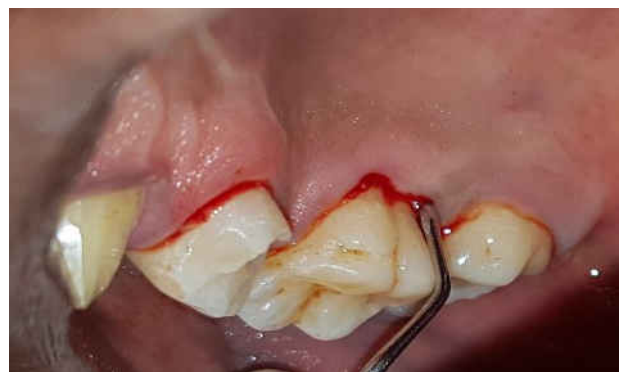

PPD –5mm in distopalatal aspect of 16

OPERATIVE PHOTO-8.1.2018

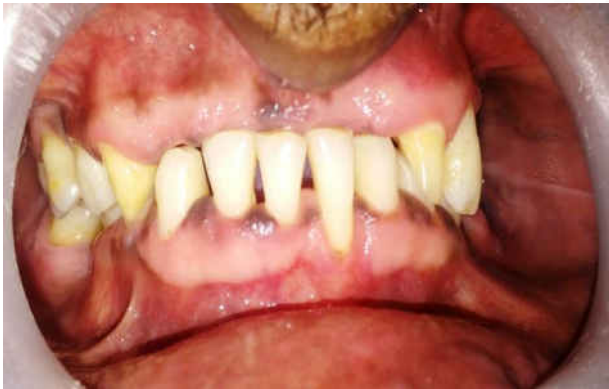

Gingival curettage in 31-distobuccal aspect

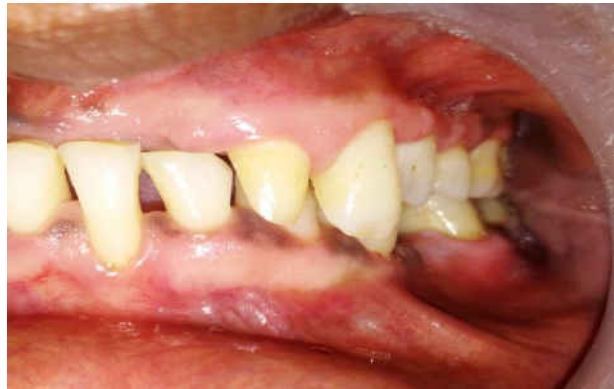

Gingival curettage in 16 distopalatal aspect

POST OPERATIVE PHOTO

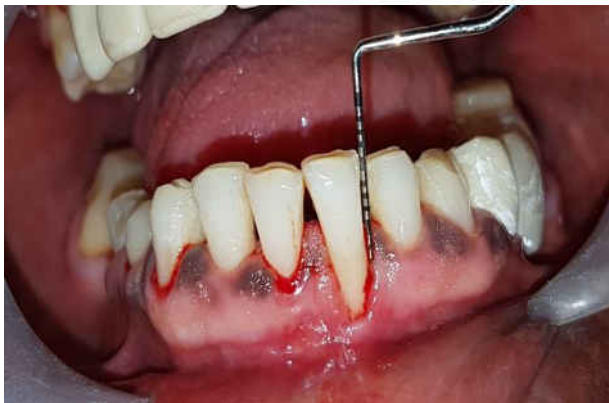

Frontal view

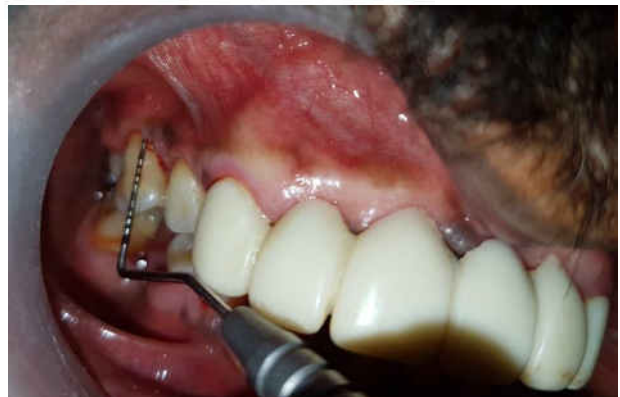

Left lateral view

POST OPERATIVE PHOTO – 3 MONTH



PPD–3mm in distobuccal aspect of 31



PPD –3mm in mesiobuccal aspect of 16

Case-8

DEMOGRAPHIC DATA

PATIENT NAME: Mr. Karunanidhi

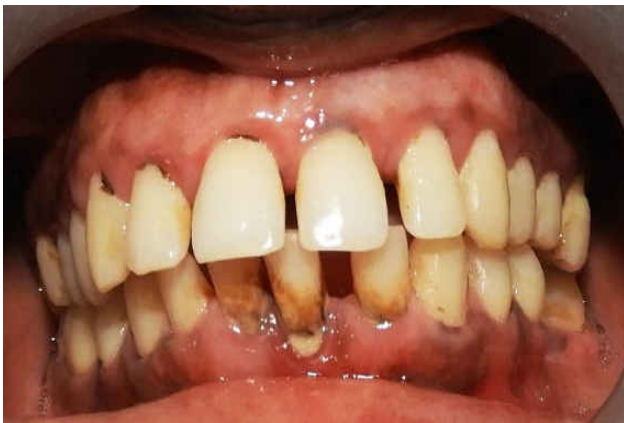DATE: 18.11.2017

OP NO: 20170090028

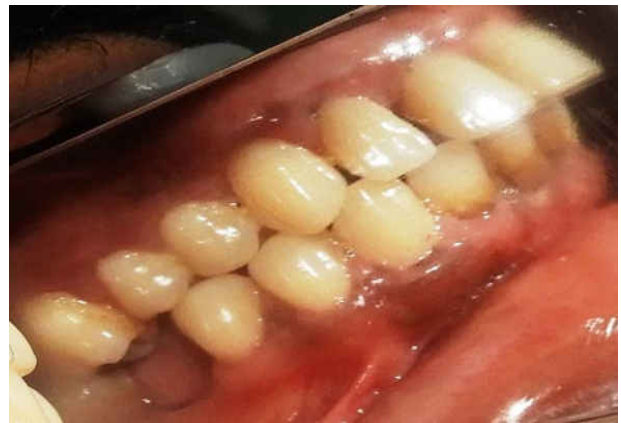AGE/SEX: 38/M

PROCEDURE: Gingival curettage done in relation to 37

PRE OPERATIVE PHOTO

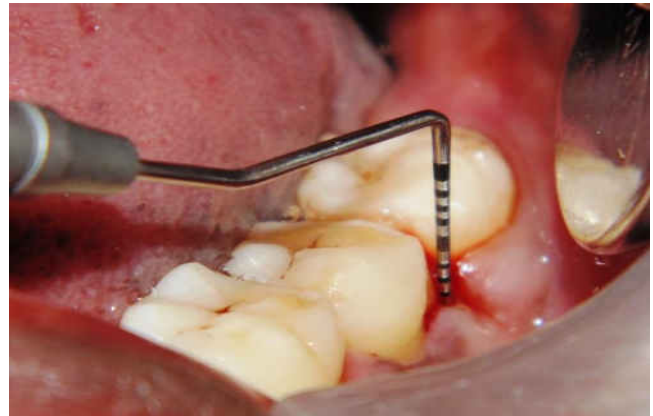


Frontal view

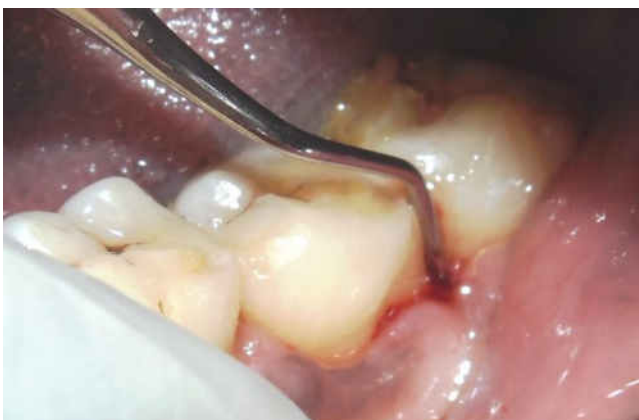

Left lateral view

PRE OPERATIVE MEASUREMENTS



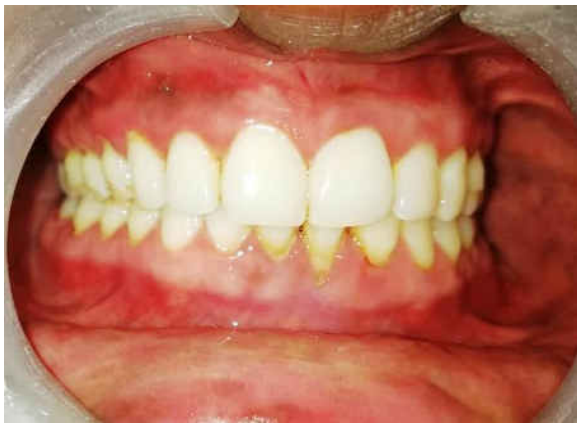PPD - 6mm in distobuccal aspect of 37



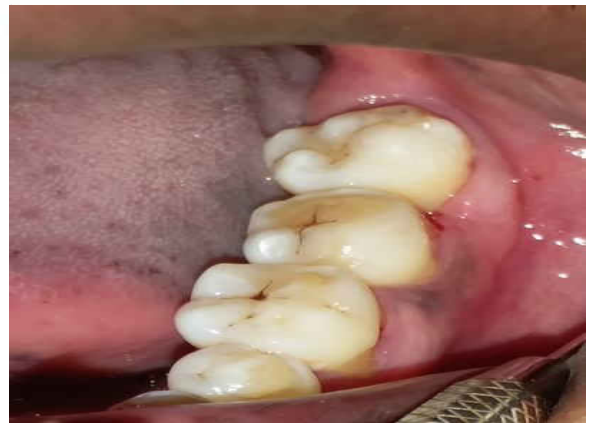Gingival curettage in 37 distobuccal aspect

OPERATIVE PHOTO-

POSTOPERATIVE PHOTO – 1 MONTH

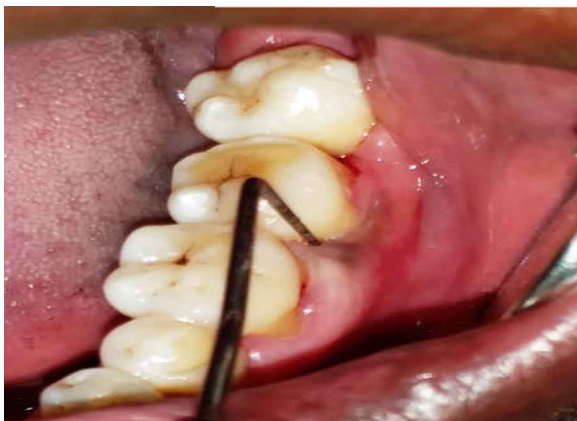

Frontal view

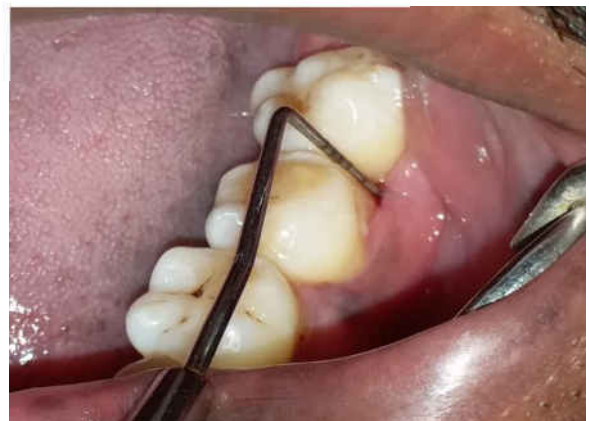

Occlusal view

POSTOPERATIVE PHOTO – 3 MONTH



PPD - 3mm in mesiobuccal aspect of 37



PPD - 3mm in distobuccal aspect of 37

Case-9

DEMOGRAPHIC DATA

PATIENT NAME: Mr. Natarajan

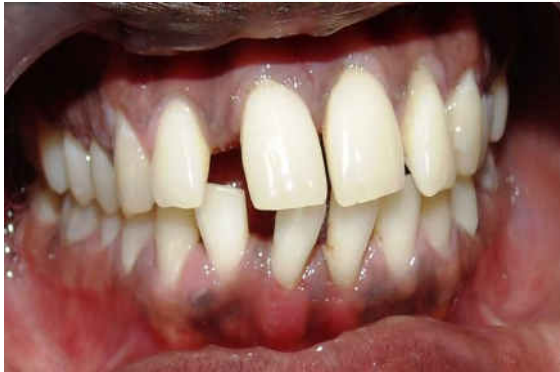DATE: 6.12.2017

OP NO: 201712060002

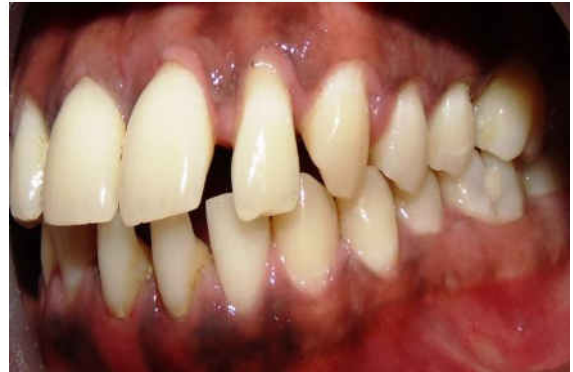AGE/SEX: 27/M

PROCEDURE: Gingival curettage done in relation to 21,36

PRE OPERATIVE PHOTO – 6.12.2017

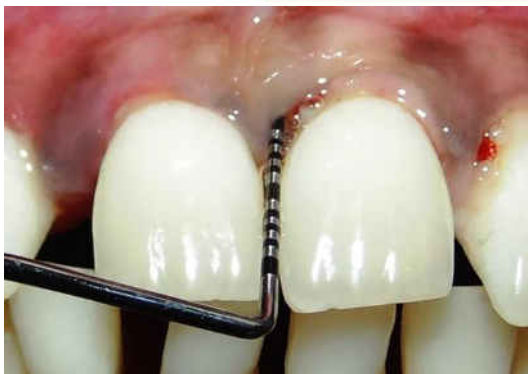

Occlusal view

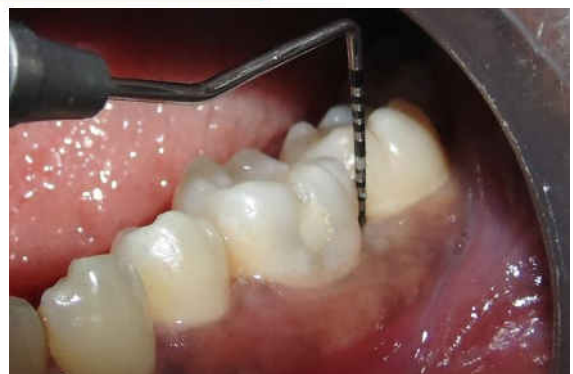

Left lateral view

PRE OPERATIVE MEASUREMENTS

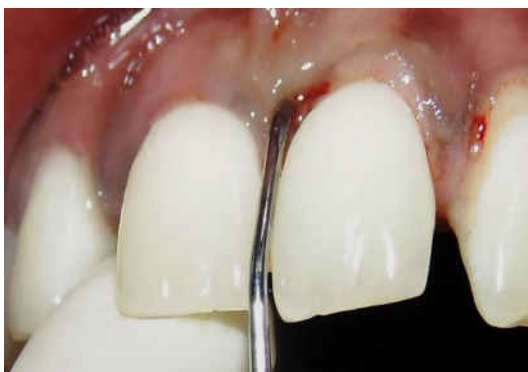

PPD–5mm in mesiobuccal aspect of 21

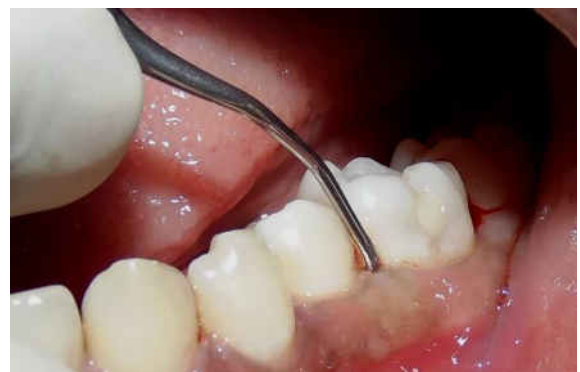

PPD–5mm in distobuccal aspect of 36

OPERATIVE PHOTO-19.12.2017

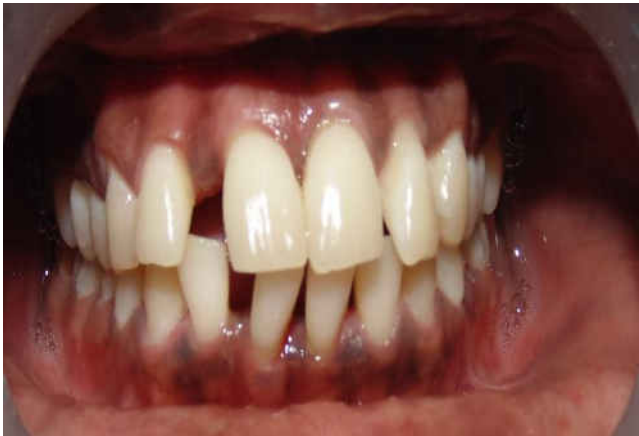

Gingival curettage in 21-mesiobuccal aspect

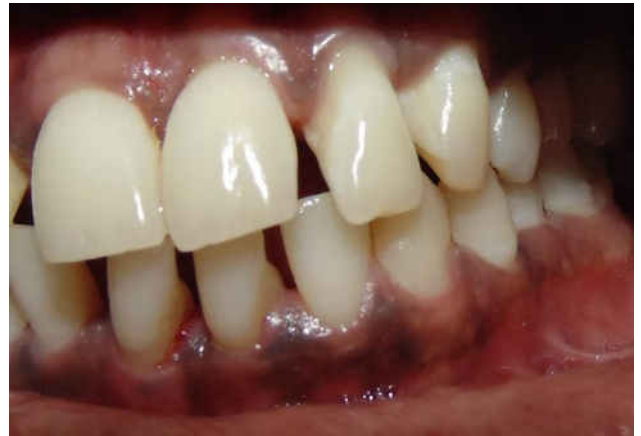

Gingival curettage in 36 mesiobuccal aspect

POST OPERATIVE PHOTO – 1 MONTH

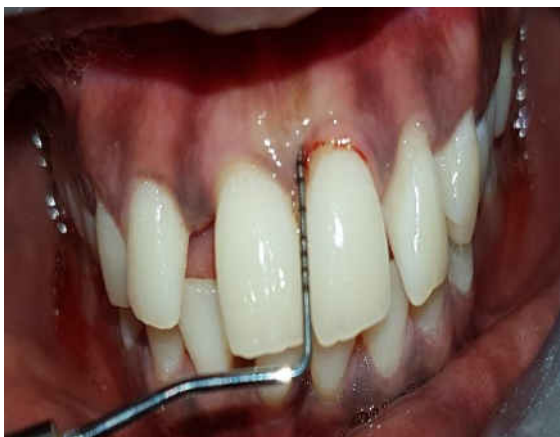

Frontal view

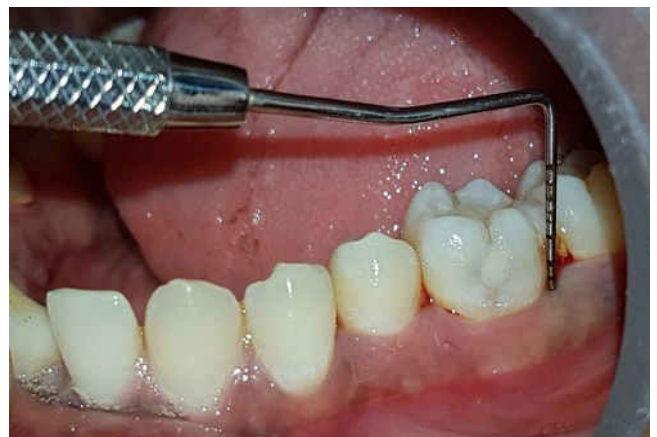

Left lateral view

POST OPERATIVE PHOTO – 3 MONTH



PPD–2mm in mesiobuccal aspect of 21



PPD–2mm in distobuccal aspect of 36

Case-10

DEMOGRAPHIC DATA

PATIENT NAME: Miss. Farheen sana

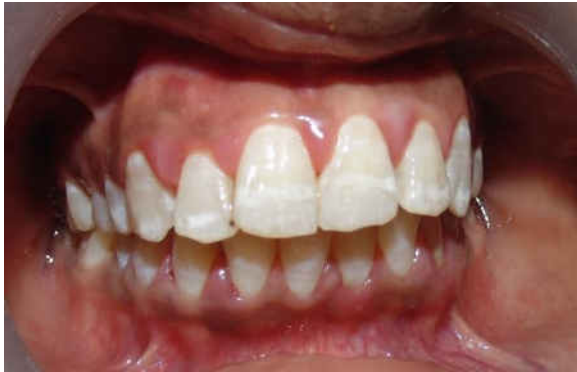DATE: 6.2.2018

OP NO: 201802060035

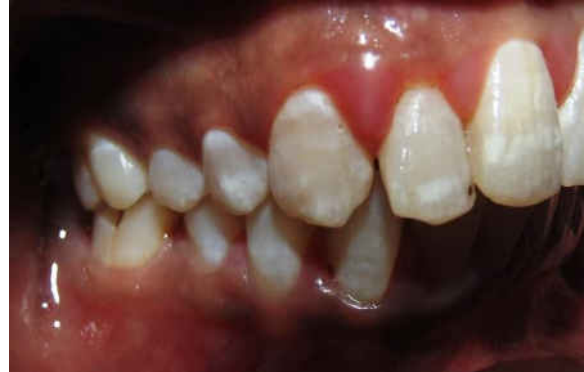AGE/SEX: 24/F

PROCEDURE: Scaling and root planning done in relation to 13,16

PRE OPERATIVE PHOTO – 6.2.2018

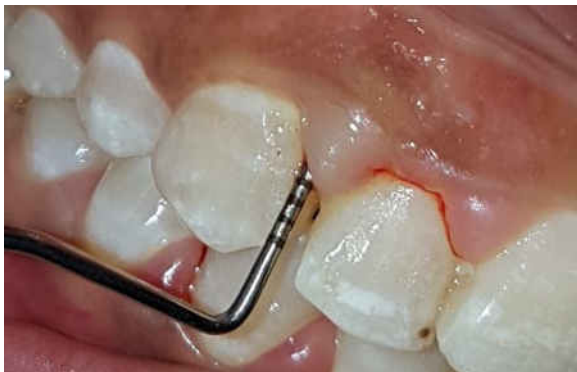

Front view

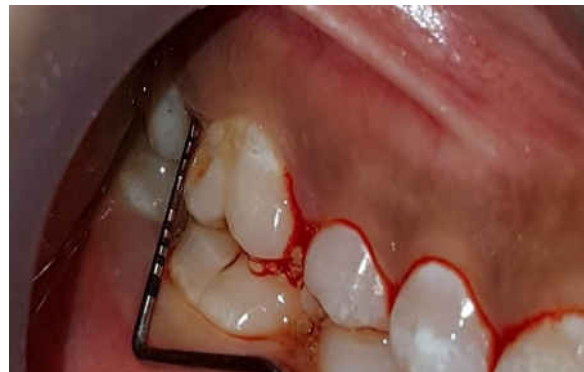

Right lateral view

PRE OPERATIVE MEASUREMENTS

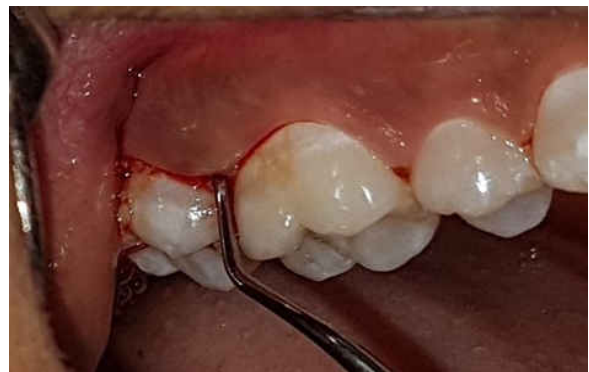
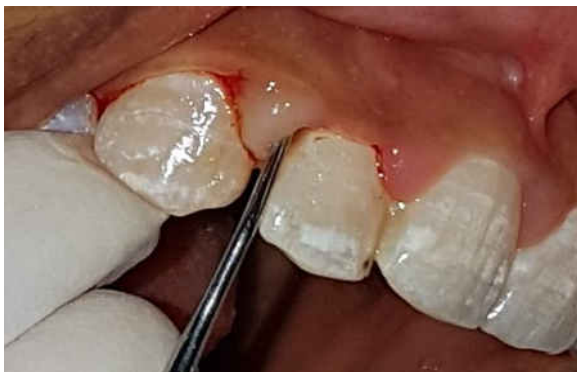
PPD –11 mm in mesiolabial aspect of 13



PPD– 5mm in distobuccal aspect of 16

OPERATIVE PHOTO



Scaling and root planning in mesiolabial aspect of 13 and in distobuccal aspect of 16

Case-11

DEMOGRAPHIC DATA

PATIENT NAME: Mr. Elumalai

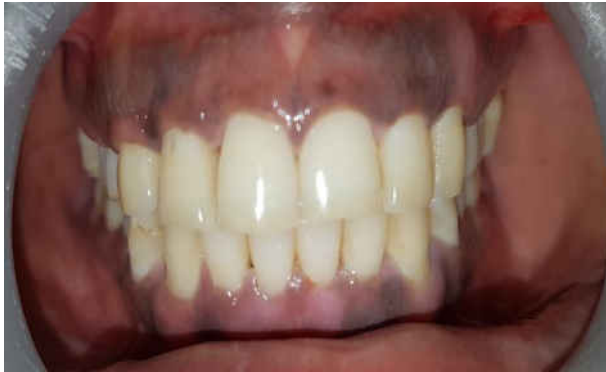DATE: 24.3.2018

OP NO: 201709180002

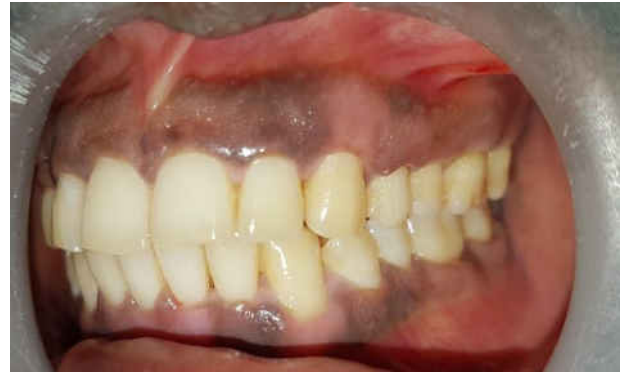AGE/SEX: 62/M

PROCEDURE: Scaling and root planning done in relation to 23,33

PRE OPERATIVE PHOTO – 24.3.2018

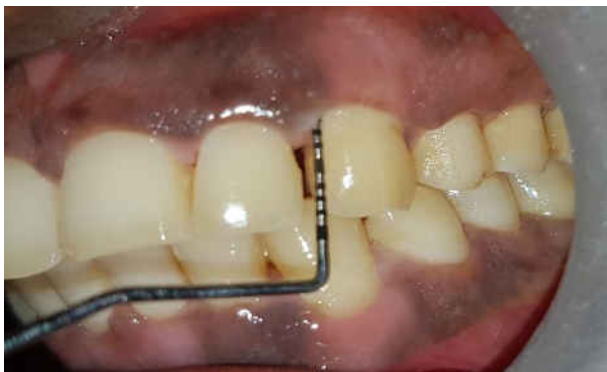

Front view

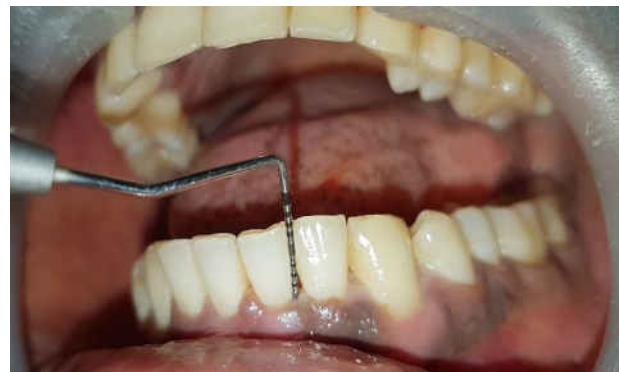

Left lateral view

PRE OPERATIVE MEASUREMENTS

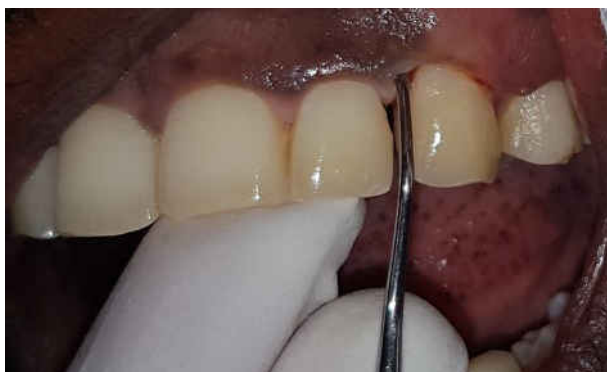

PPD –5mm in mesiolabial aspect of 23

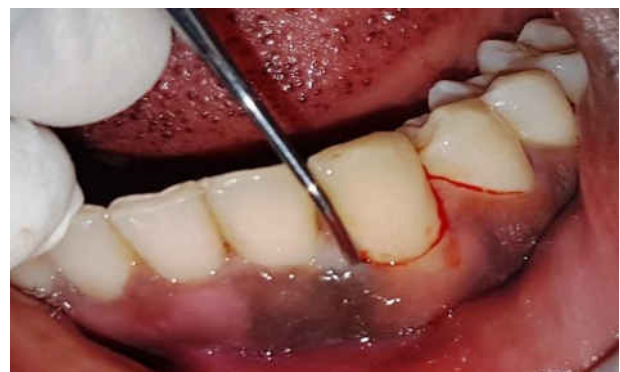

PPD–5mm in mesiolabial aspect of 33

OPERATIVE PHOTO-25.9.2017

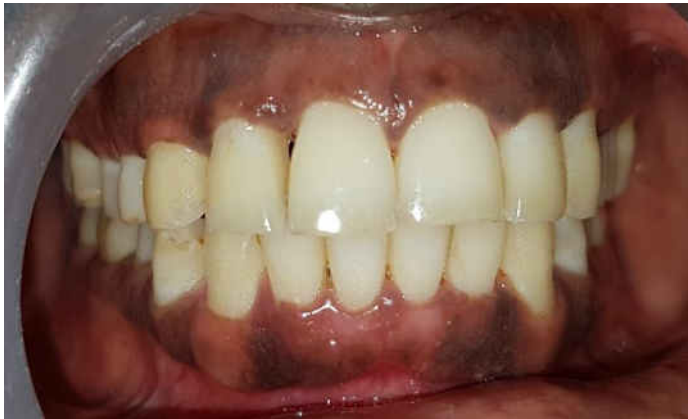

Scaling & root planning in 23 mesiolabial aspect

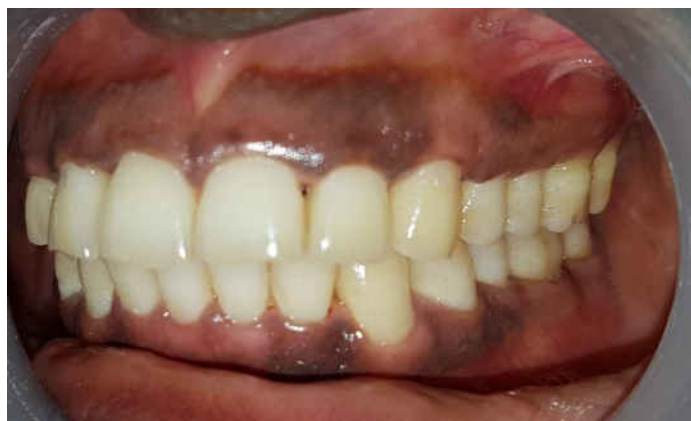

Scaling & root planning in 33 mesiolabial aspect

POST OPERATIVE PHOTO



Front view



Left lateral view

Case-12

DEMOGRAPHIC DATA

PATIENT NAME: Mrs. Kamatchi

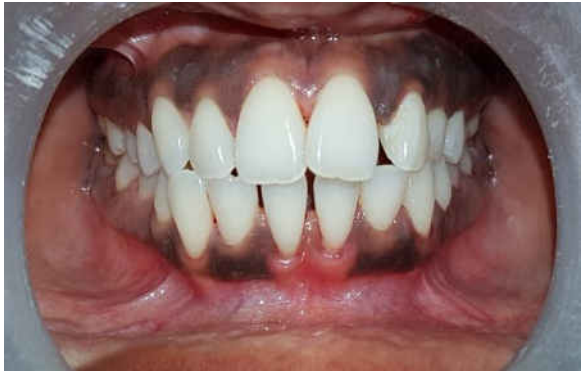DATE: 23.4.2018

OP NO: 201703200030

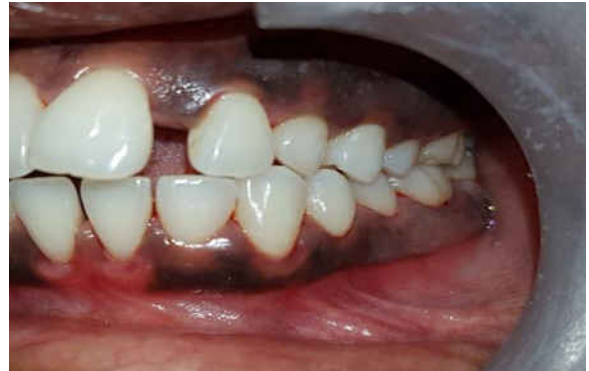AGE/SEX: 28/F

PROCEDURE: Scaling and root planning done in relation to 26

PRE OPERATIVE PHOTO – 23.4.2018

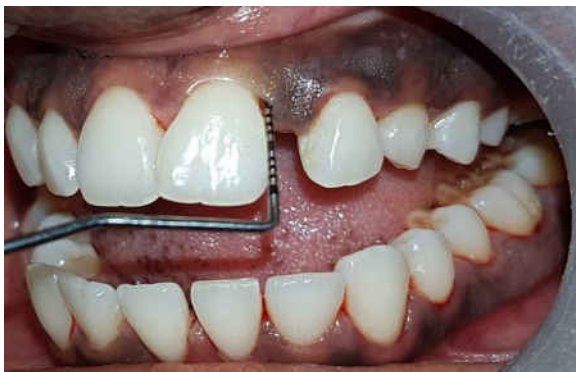

Frontal view

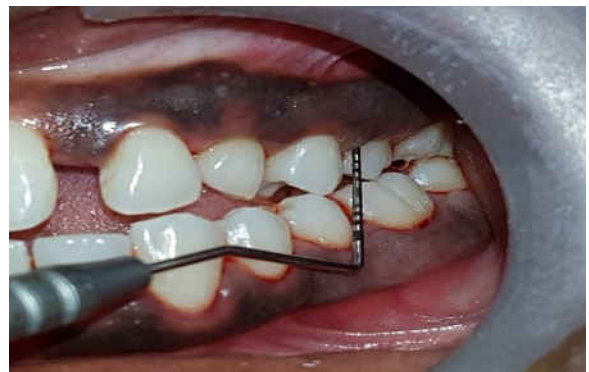

Left lateral view

PRE OPERATIVE MEASUREMENTS

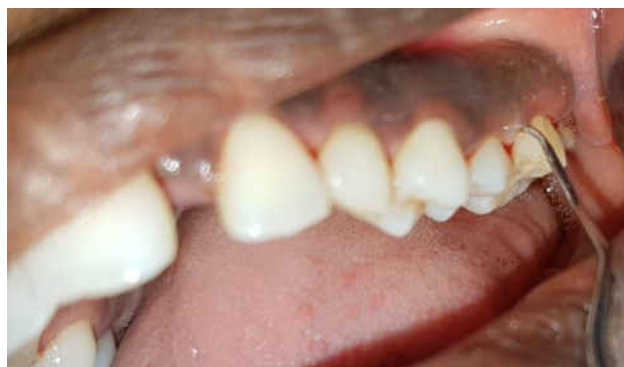

PPD – 5 mm in distolabial aspect of 21



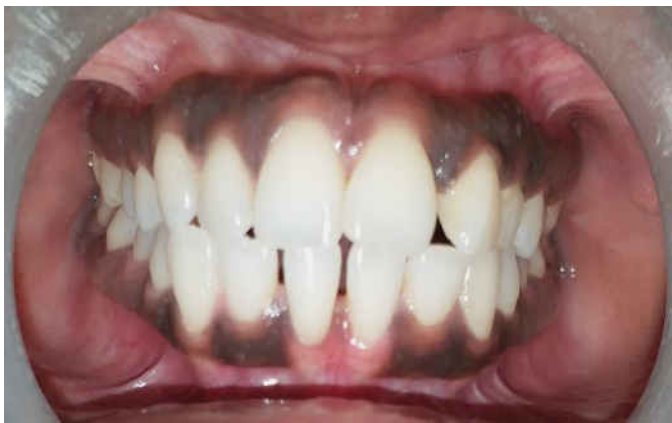PPD – 5 mm in mesiobuccal aspect of 26

OPERATIVE PHOTO

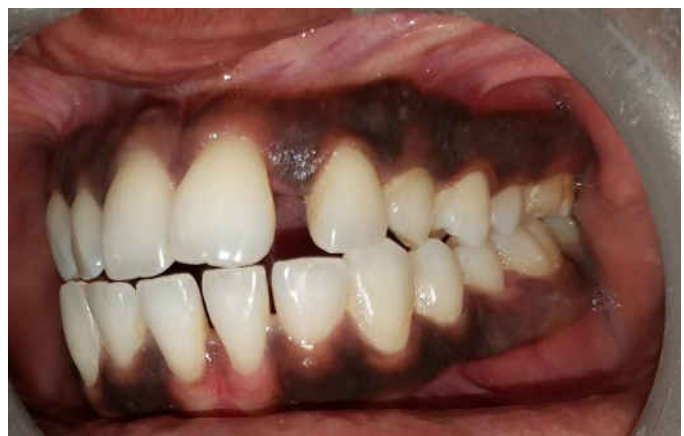

Scaling and root planning done in mesiobuccal aspect of 26

POST- OPERATIVE PHOTO



Frontal view



Left lateral view

Case-12

DEMOGRAPHIC DATA

PATIENT NAME: Mr. Sathish kumar

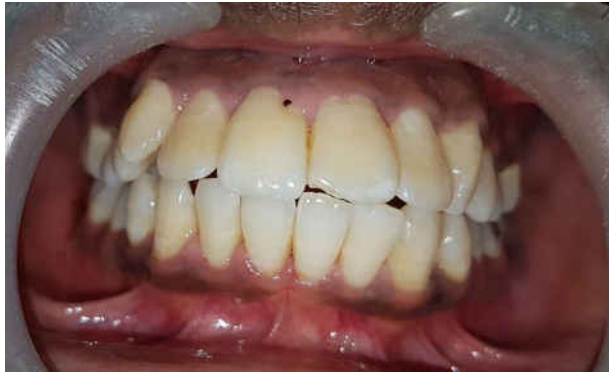DATE: 24.3.2017

OP NO: 201710010003

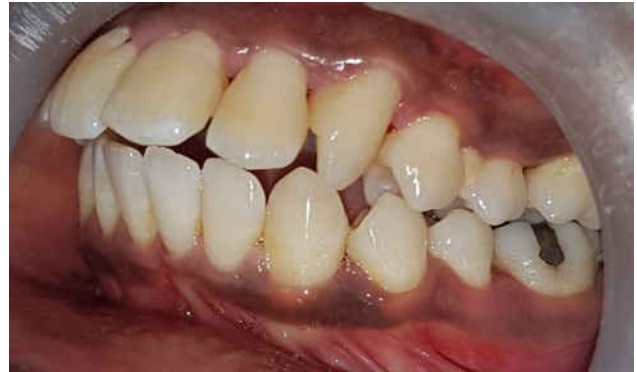AGE/SEX: 25/M

PROCEDURE: scaling and root planning done in relation to 36,46

PRE OPERATIVE PHOTO – 24.3.2017

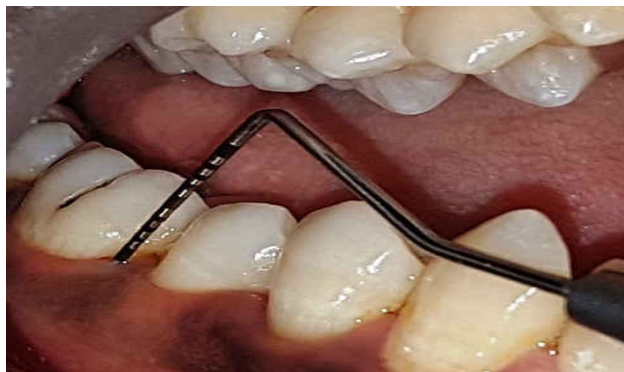

Front view

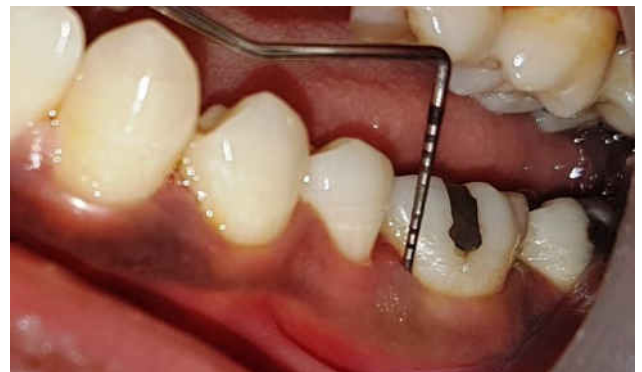

Left lateral view

PRE OPERATIVE MEASUREMENTS

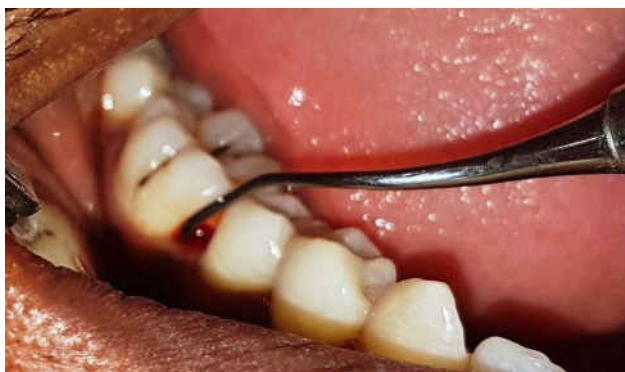

PPD –5mm in mesiobuccal aspect of 46

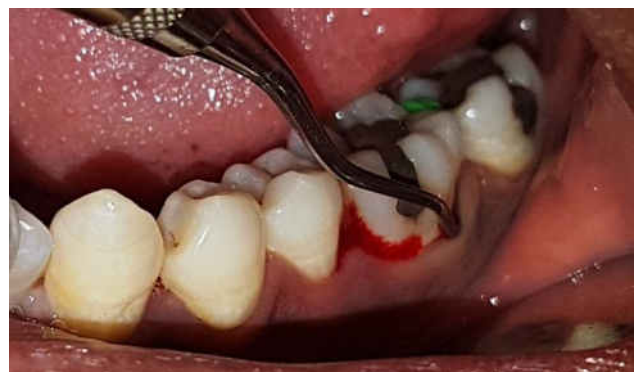

PPD–5mm in mesiobuccal aspect of 36

OPERATIVE PHOTO

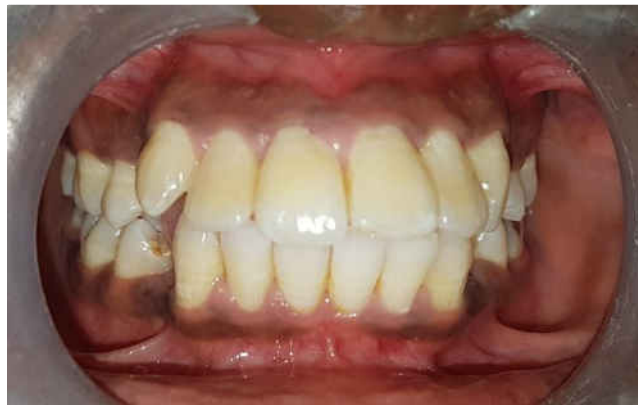

Scaling & root planning in 46 mesiobuccal aspect



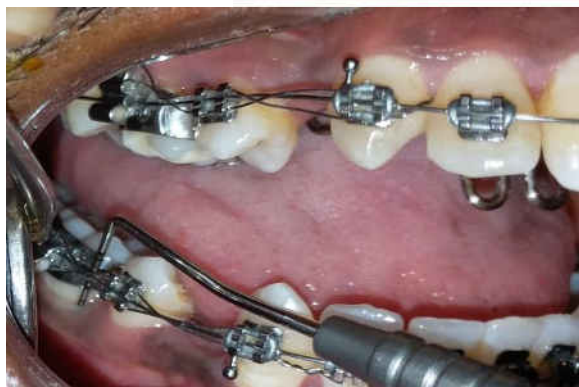Scaling & root planning in 36distobuccal aspect

POST OPERATIVE PHOTO- 1 MONTH

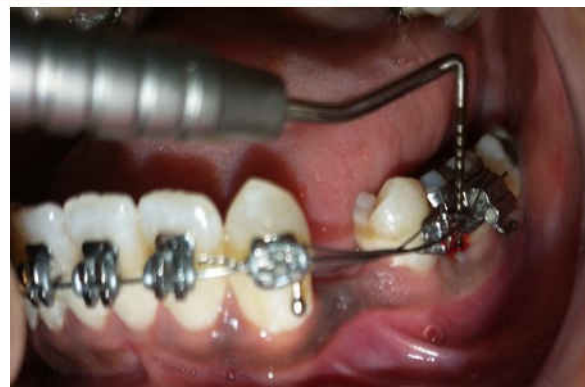

Front view

POST OPERATIVE PHOTO- 3 MONTH



PPD –3mm in mesiobuccal aspect of 46



PPD –3mm in mesiobuccal aspect of 36

Case-13

DEMOGRAPHIC DATA

PATIENT NAME: Mrs. Gunasundari

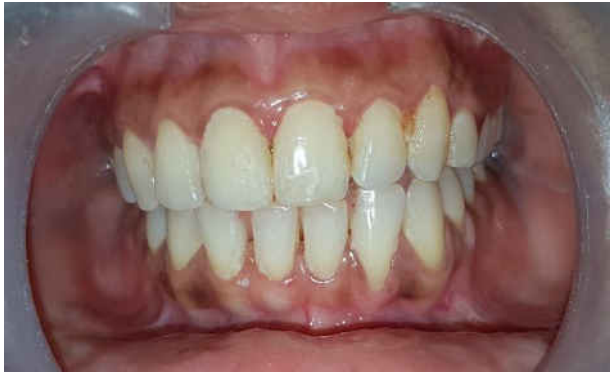DATE: 24.3.2018

OP NO: 201707270011

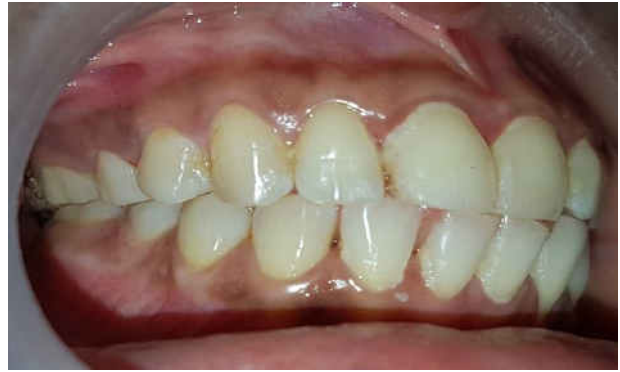AGE/SEX: 33/F

PROCEDURE: Scaling & root planning done in relation to 16

PRE OPERATIVE PHOTO – 24.3.2018

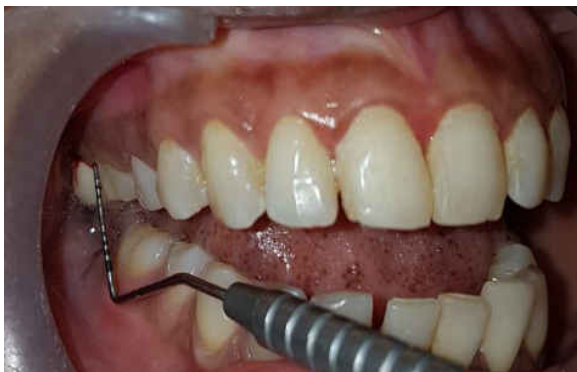

Front view

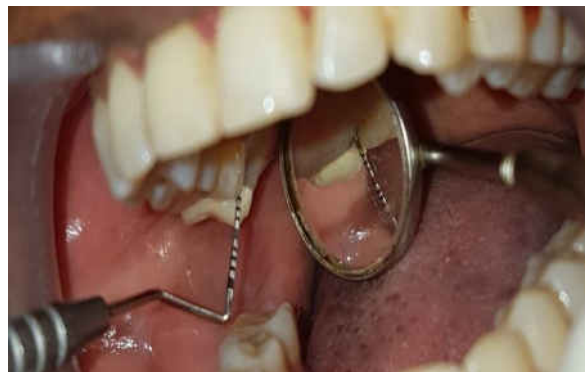

Right lateral view

PRE OPERATIVE MEASUREMENTS

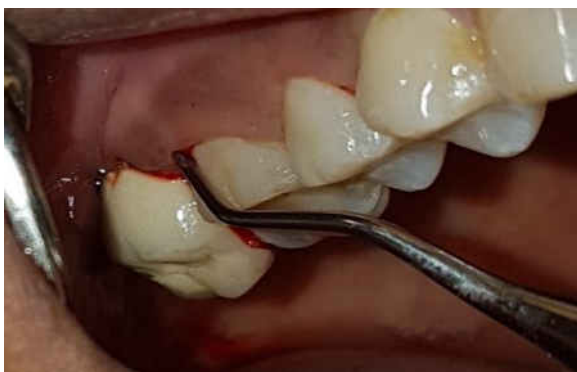

PPD –5mm in mesiobuccal aspect of 16

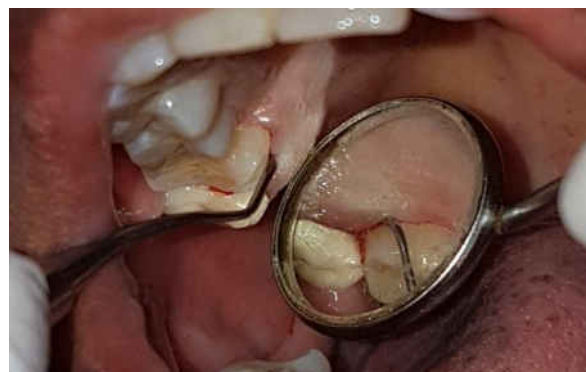

PPD–5mm in mesiolingual aspect of 16

OPERATIVE PHOTO



Scaling & root planning in 16 distobuccal aspect



Scaling & root planning in 16 distolingual aspect

Case-14

DEMOGRAPHIC DATA

PATIENT NAME: Mr. Mohammed nainar

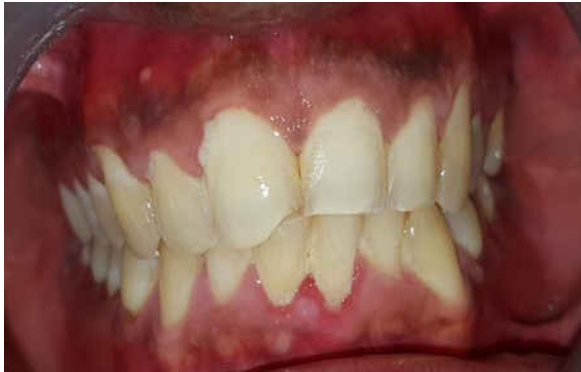DATE: 24.3.2018

OP NO: 201703180110

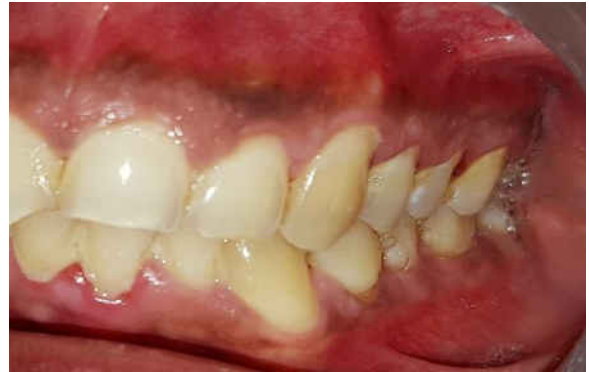AGE/SEX: 32/M

PROCEDURE: Scaling and root planning done in relation to 25,26, 27

PRE OPERATIVE PHOTO – 24.3.2018

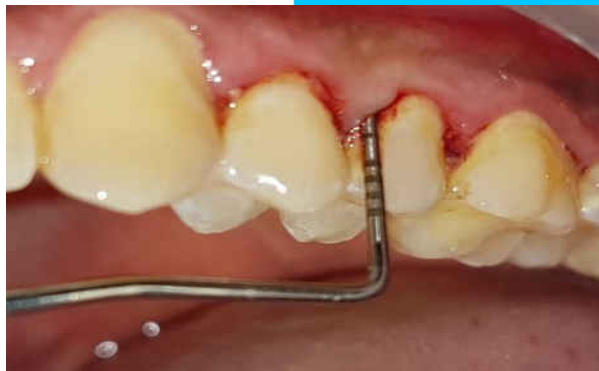

Front view

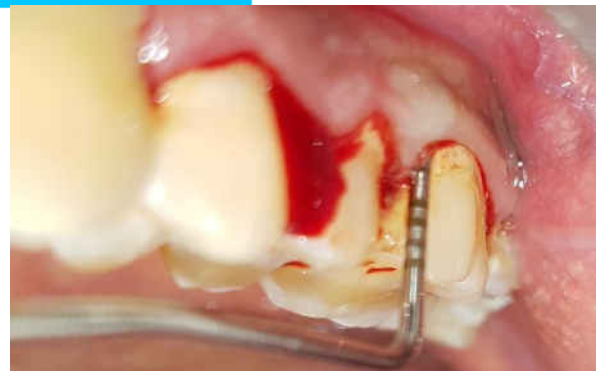

Left lateral view

PRE OPERATIVE MEASUREMENTS

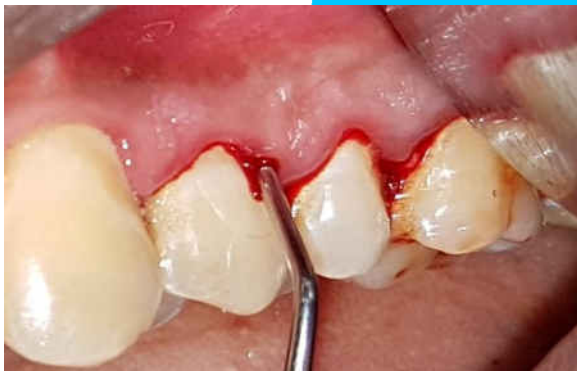

PPD –5mm in mesiolabial aspect of 25

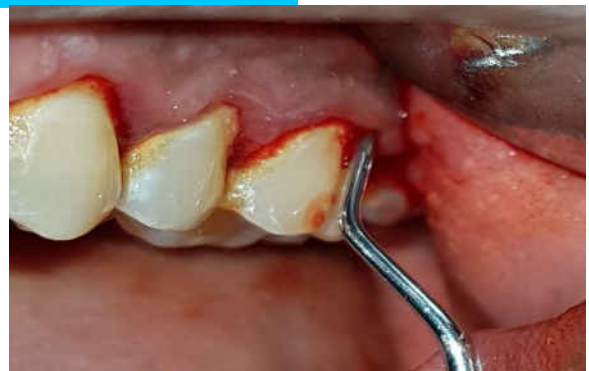

PPD–5mm in mesiolabial aspect of 26

OPERATIVE PHOTO

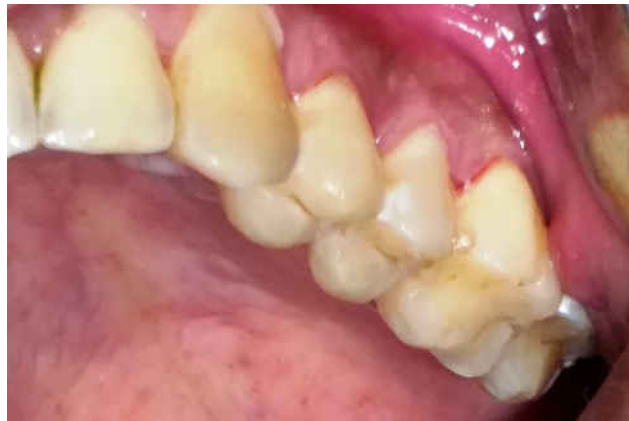

Scaling & root planning in 25 mesiolabial aspect



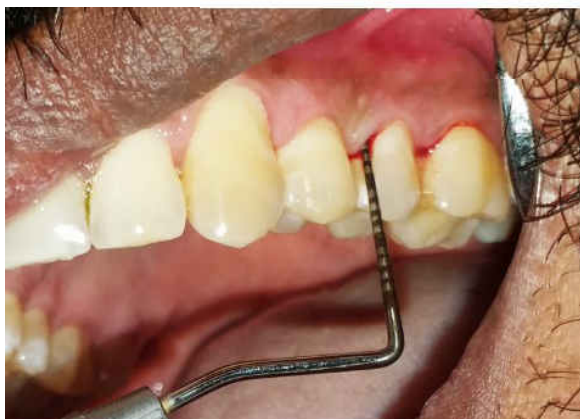Scaling & root planning in 26 distobuccal aspect

POSTOPERATIVE PHOTO – 1 MONTH

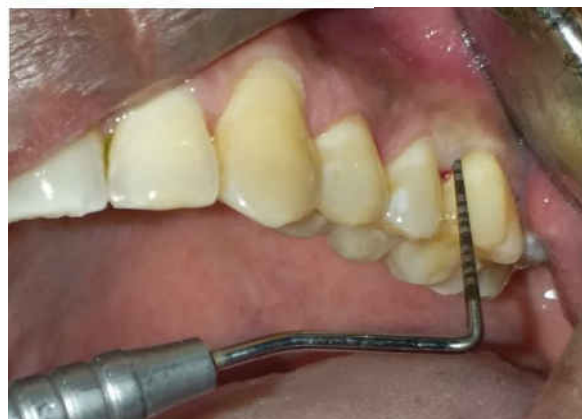

Left lateral view

POSTOPERATIVE PHOTO – 3 MONTH



PPD –2 mm in mesiolabial aspect of 25



PPD–2mm in mesiolabial aspect of 26

Case-15

DEMOGRAPHIC DATA

PATIENT NAME :Mr. Siva

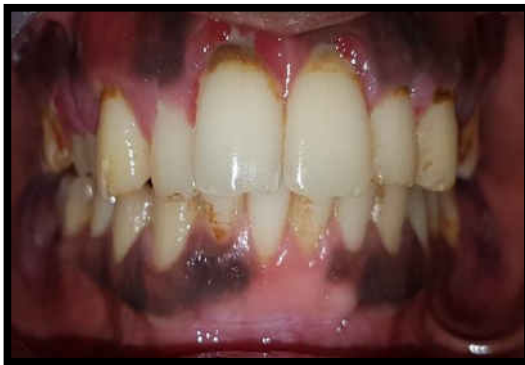DATE: 28.2.18

OP NO: 201802260096

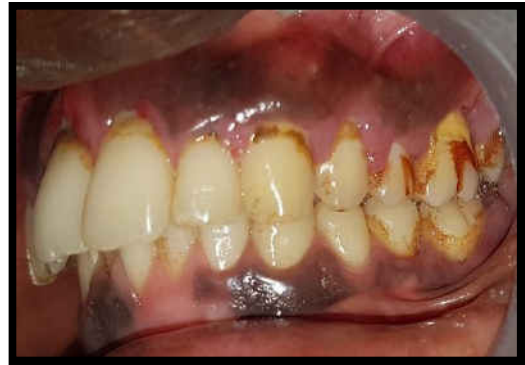AGE/SEX: 36/M

PROCEDURE: Splinting done in relation to 11,12,13,21,22,23- composite wire splint

PRE OPERATIVE PHOTO – 28.2.18

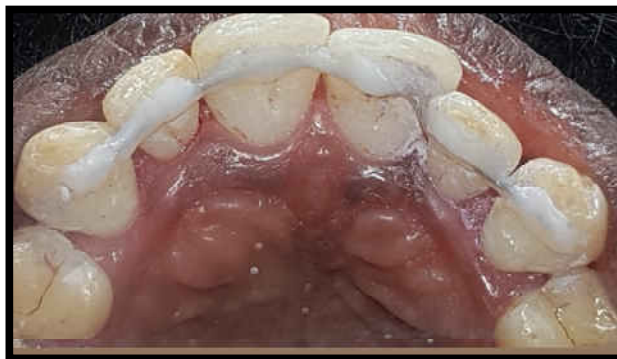

Frontal view



Left lateral view

SPLINTING



Splinting 11,12,13,21,22,23

Case-16

DEMOGRAPHIC DATA

PATIENT NAME :Mr. Suresh Babu

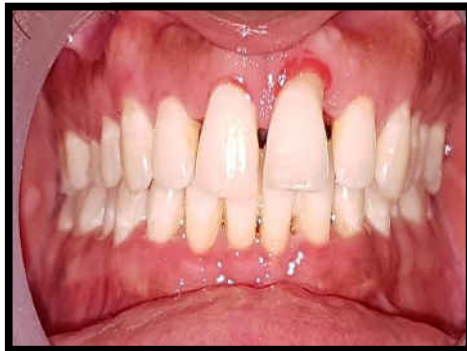DATE: 21.4.18

OP NO: 201804190124

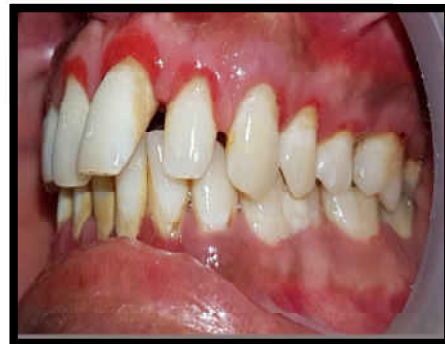AGE/SEX: 30/M

PROCEDURE: Splinting done in relation to 31,32,33,41,42,43- composite wire splint

PRE OPERATIVE PHOTO – 21.4.18

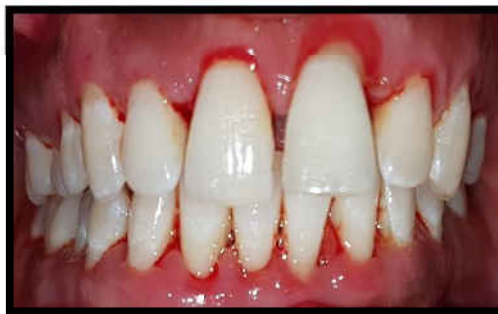

Frontal view

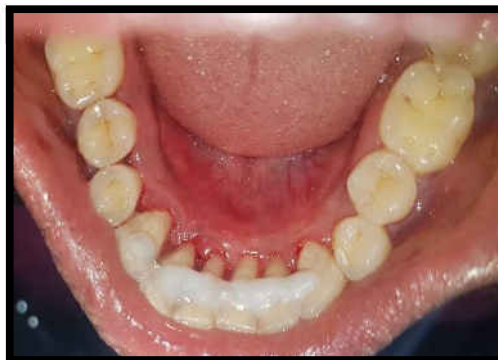

Left lateral view

POST SCALING



SPLINTING



Splinting 31,32,33,41,42,43

Case-17

DEMOGRAPHIC DATA

PATIENT NAME :Mr. Abraham NOP

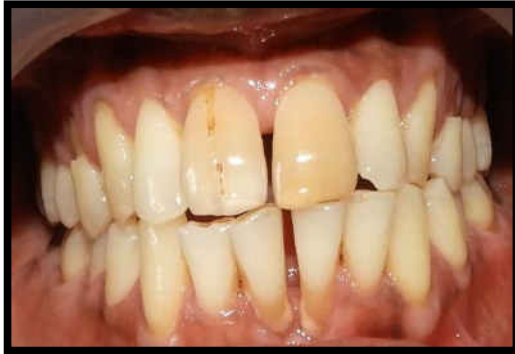DATE: 3.10.17

OP NO: 201709280057

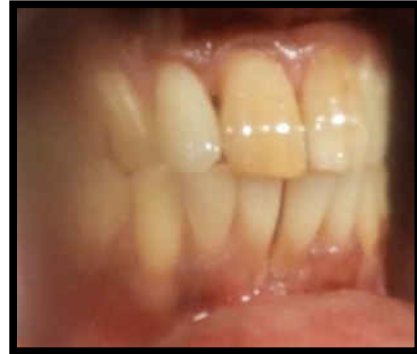AGE/SEX: 51/M

PROCEDURE: Gingival curettage done in relation to 31,41

PRE OPERATIVE PHOTO – 3.10.17

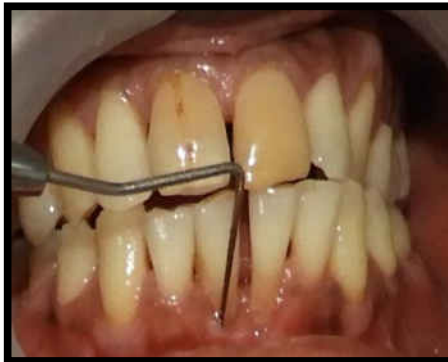

Occlusal view



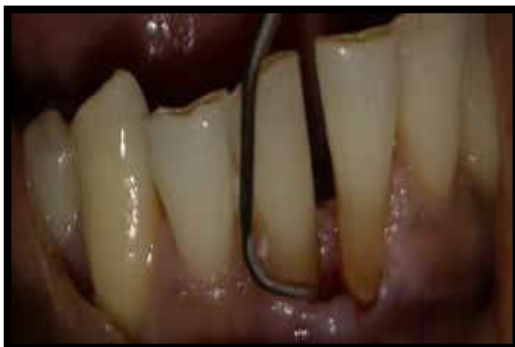Left lateral view

PRE OPERATIVE MEASUREMENTS

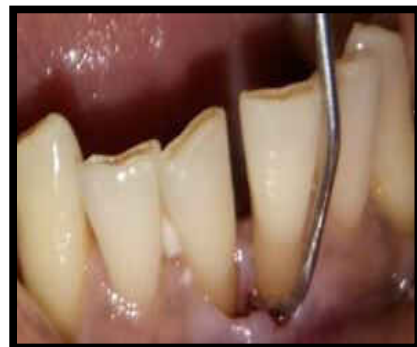

PPD –6mm in mesiobuccal aspect of 41

OPERATIVE PHOTO-5.10.17

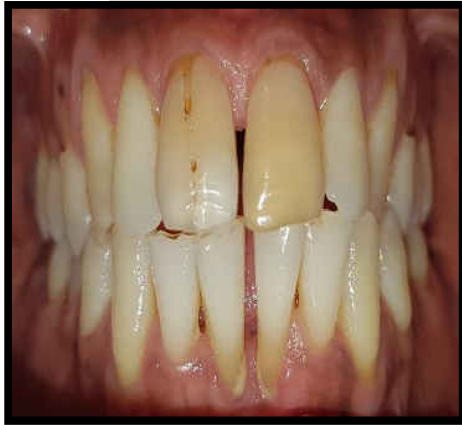

Gingival curettage in 41-distobuccal aspect

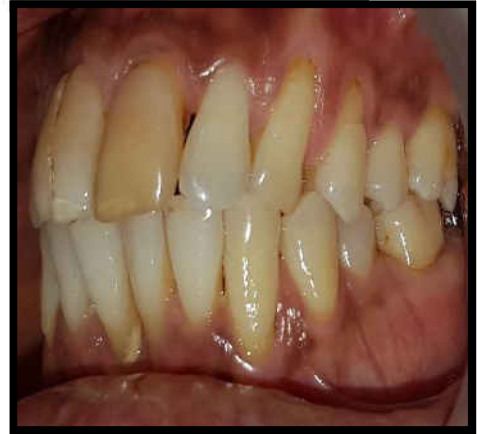

Gingival curettage in 31 mesiobuccal aspect

1 MONTH POST OPERATIVE PHOTO

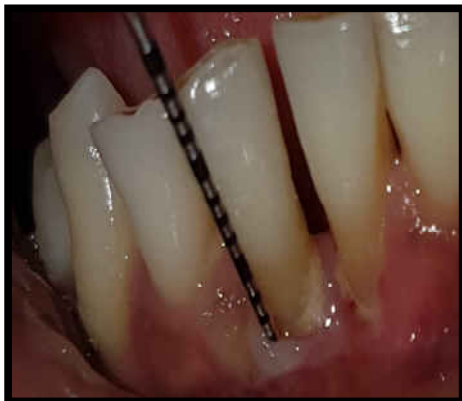

Occlusal view

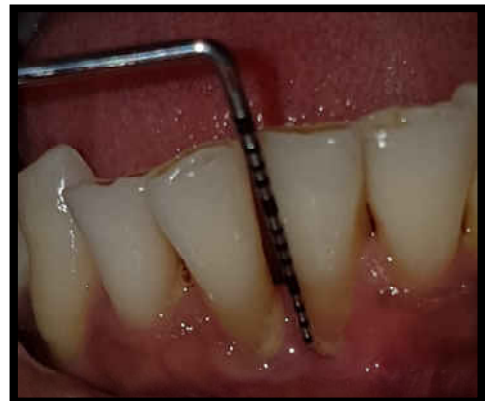

Left lateral view

3 MONTHS POST OPERATIVE PHOTO



41



31

Case-18

DEMOGRAPHIC DATA

PATIENT NAME : Mrs. Alice Paulin Mary

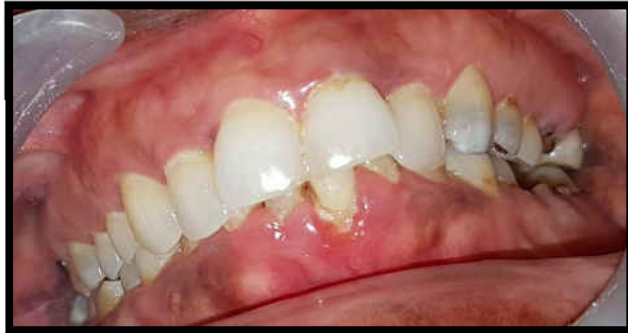DATE: 10.3.18

OP NO: 201708070001

AGE/SEX: 46/F

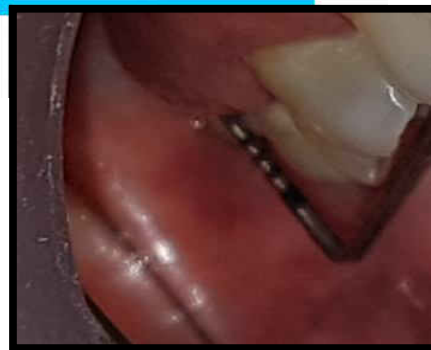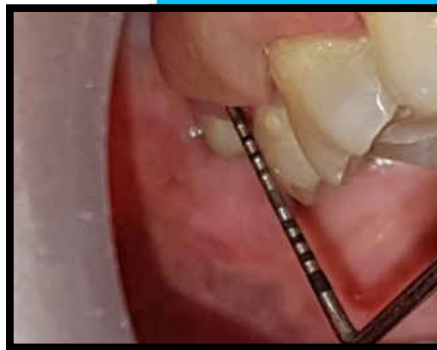
PROCEDURE: SRP done in relation to 17,18

PRE OPERATIVE PHOTO – 10.3.18



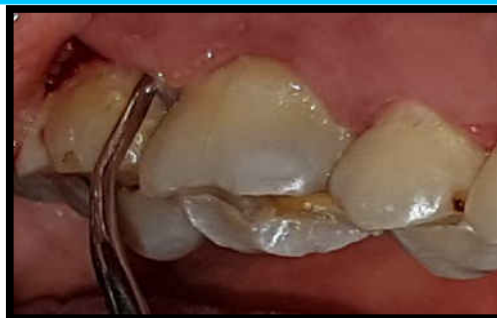Frontal view

PRE OPERATIVE MEASUREMENTS



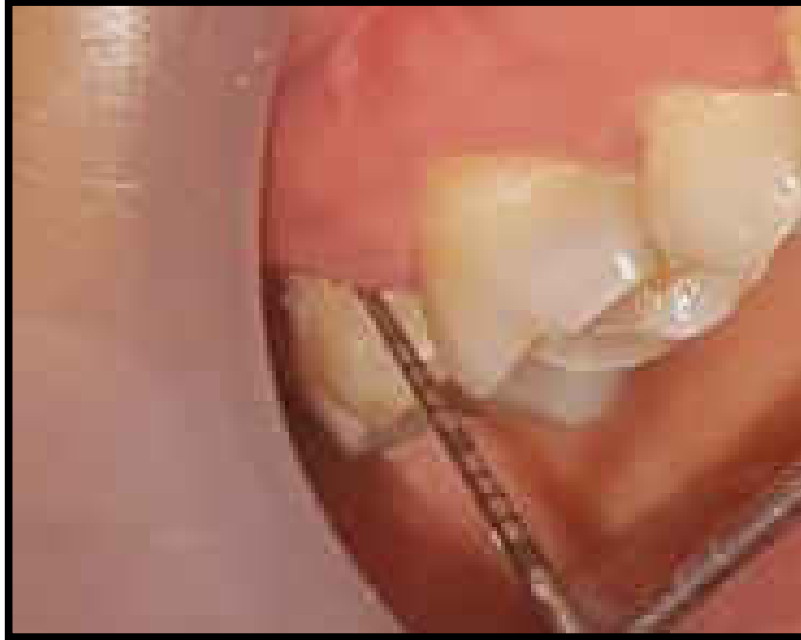
Periodontal Probing Pocket Depth
6mm 17, 10 mm 18

OPERATIVE PHOTO-10.3.18



Mesio Buccal aspect 17

POST OPERATIVE 3 MONTHS -
17.7.18



Mesiobuccal aspect 17

Case-18

DEMOGRAPHIC DATA

PATIENT NAME : Mrs Mary Jyothi

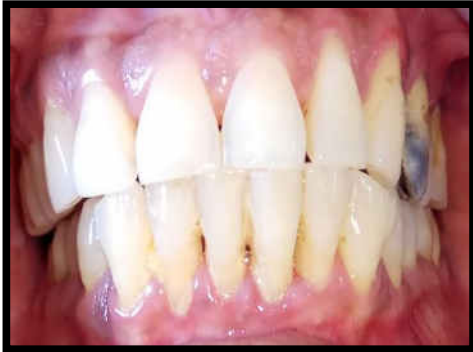DATE: 29.8.17

OP NO: 201712110007

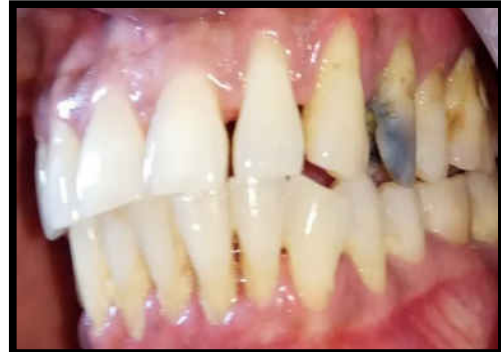AGE/SEX: 45/F

PROCEDURE: Gingival curettage done in relation to 14-17,21-27,34-37,46

PRE OPERATIVE PHOTO – 29/8/17

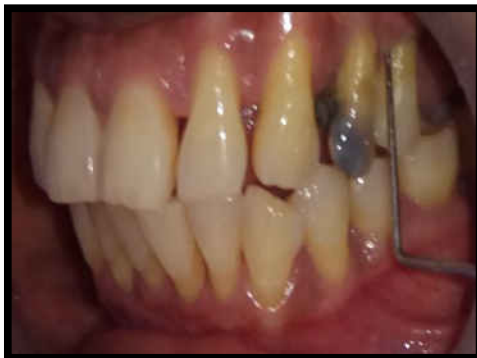

Occlusal view

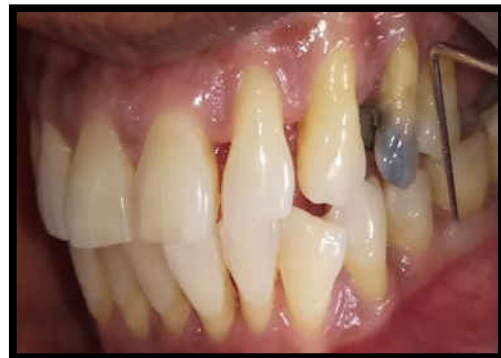

Left lateral view

PRE OPERATIVE MEASUREMENTS

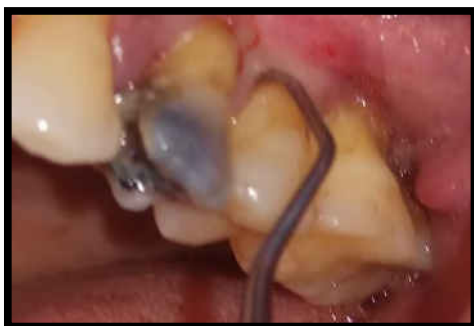

PPD –5 mm PPD mesiobuccal-25

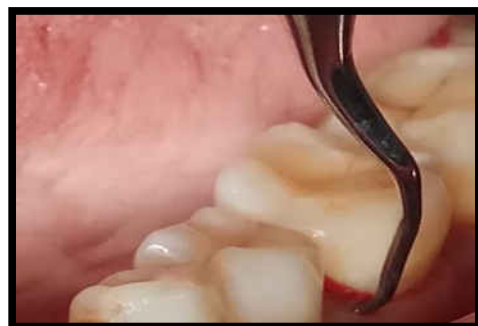

PPD – 5 mm mesiobuccal -36

OPERATIVE PHOTO-7/10/17



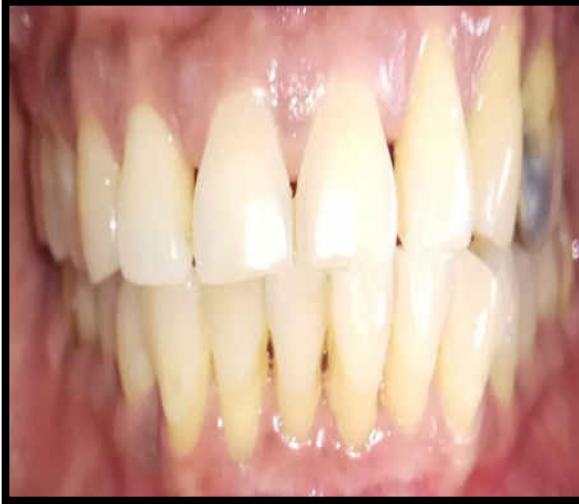Gingival curettage in 25



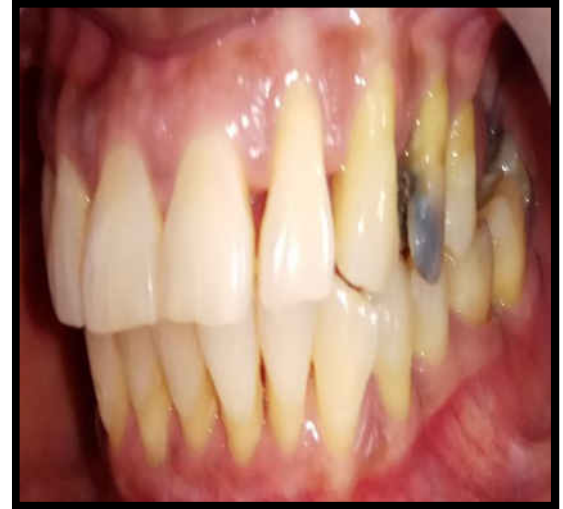Gingival curettage in 36

POST OPERATIVE PHOTOS

1 MONTH

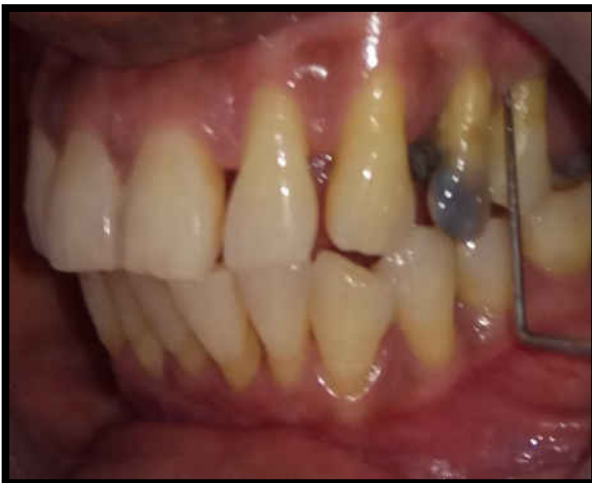

Occlusal view

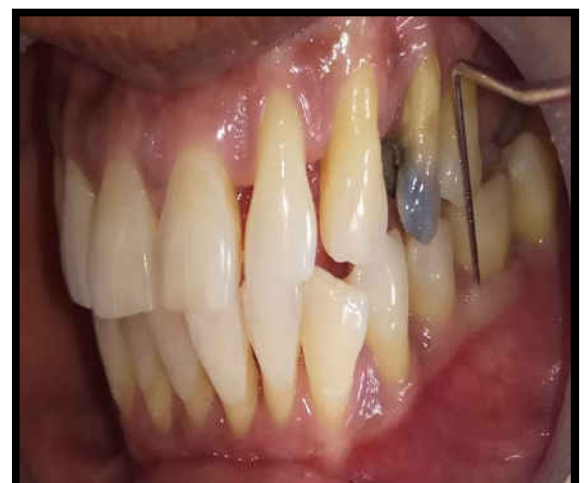

Left lateral view

3 MONTHS



25



36

Case-19

DEMOGRAPHIC DATA

PATIENT NAME :Mr. Saravana Kumar

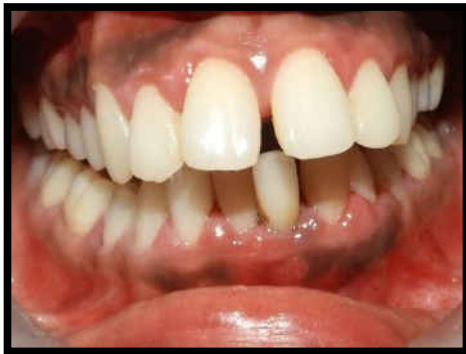DATE: 15.11.17

OP NO: 201711060010

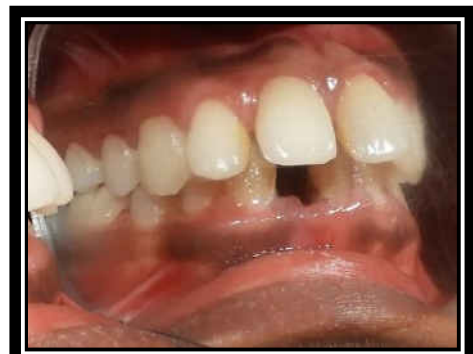AGE/SEX: 22/M

PROCEDURE: Gingival curettage done in relation to
11-16,22-27,34-36,43,44-46

PRE OPERATIVE PHOTO – 15.11.17

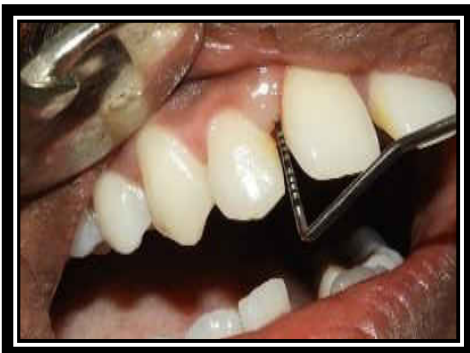

Frontal view

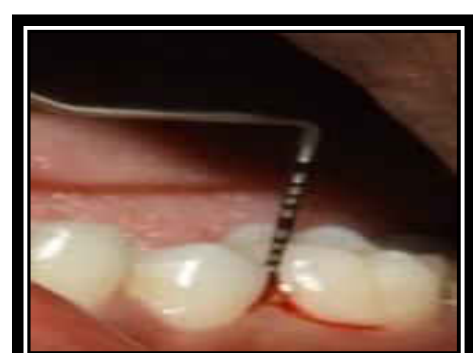

Left lateral view

PRE OPERATIVE MEASUREMENTS

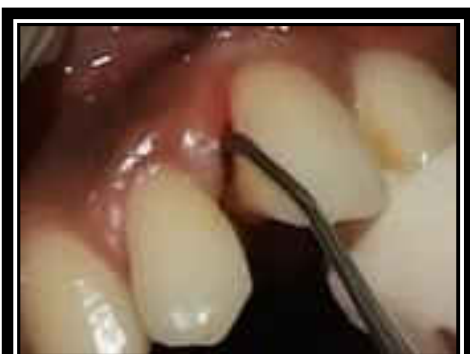

PPD –7mm in mesiobuccal aspect of 11

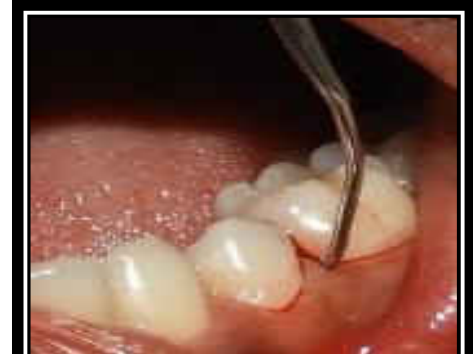

PPD –5mm in mesiobuccal aspect of 36

OPERATIVE PHOTO-18.11.17

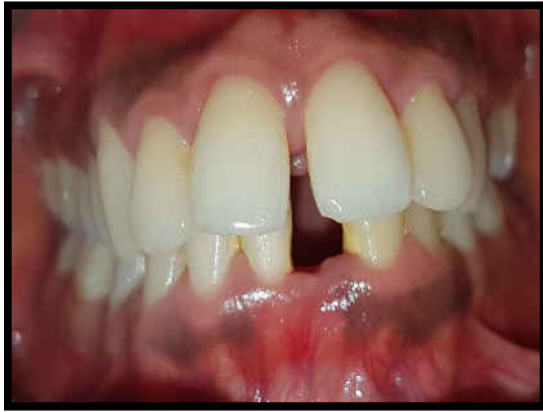

Gingival curettage in 11-distobuccal aspect

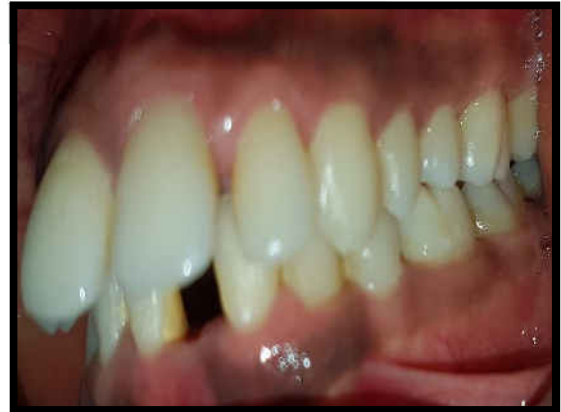

Gingival curettage in 36 mesiobuccal aspect

POST OPERATIVE PHOTOS – 1 MONTH

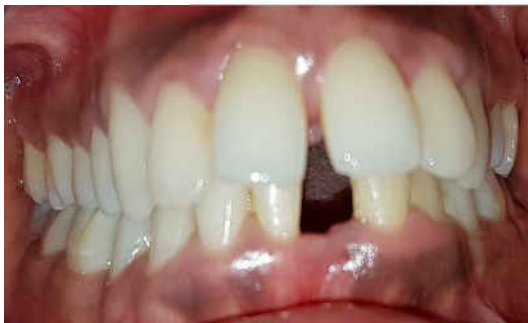

Frontal view

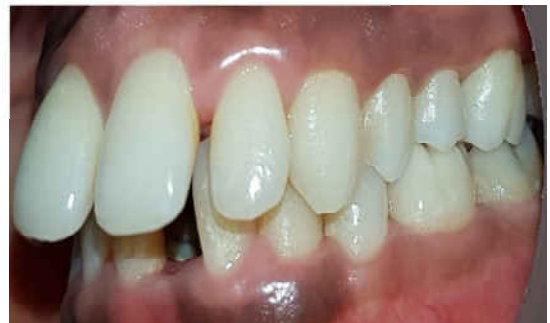

Left lateral view

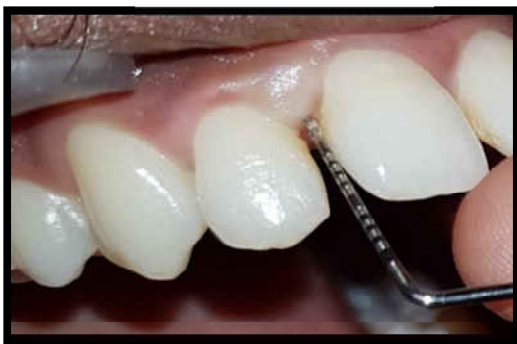**POST OPERATIVE PHOTOS – 3rd MONTH
13/3/18**



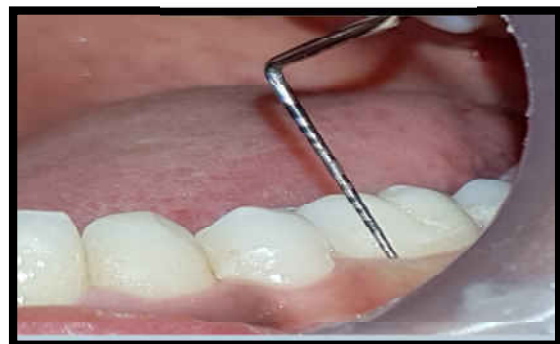Frontal view



Left lateral view



Distobuccal aspect of 11



Mesiobuccal aspect of 36

Case-20

DEMOGRAPHIC DATA

PATIENT NAME :Mr. Selvaraja

DATE: 8.5.18

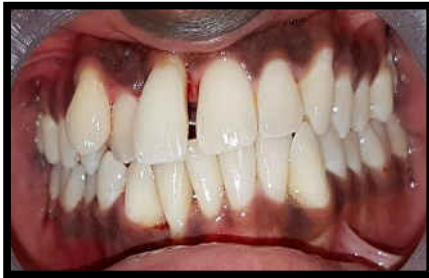OP NO: 201805050100

AGE/SEX: 27//M

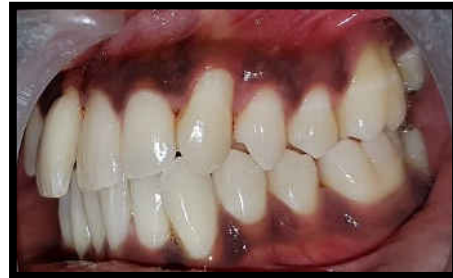PROCEDURE: Gingival curettage done in relation to

11,14,16,23,26,32,36,43,46

PRE OPERATIVE PHOTO – 8.5.18

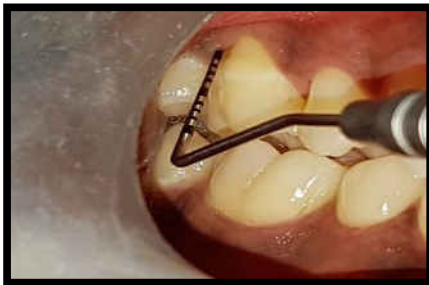


Frontal view

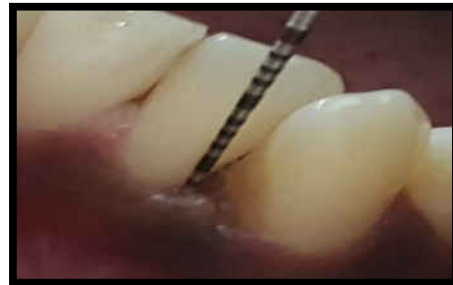


Left lateral view

PRE OPERATIVE MEASUREMENTS

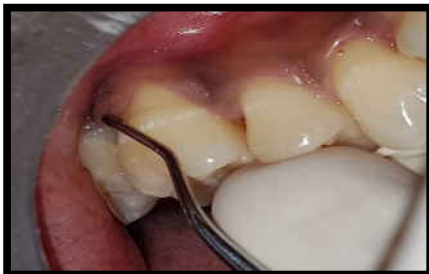

PPD –5 mm mesiobuccal aspect of 16

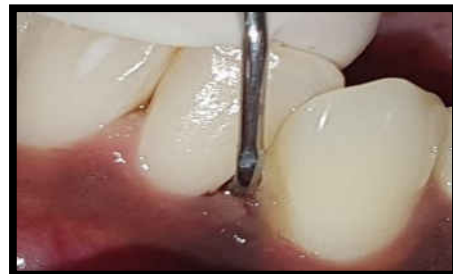

PPD –5mm in distobuccal aspect of 32

OPERATIVE PHOTO-12.5.18, 16.5.18

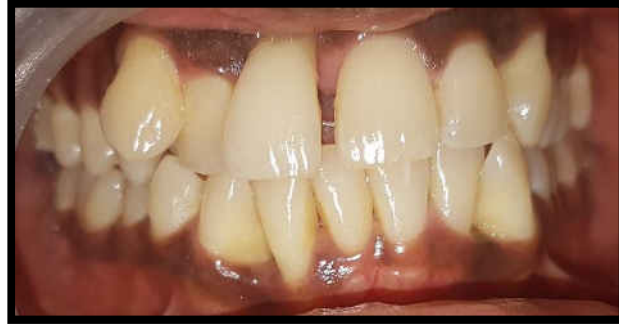

Gingival curettage in 16 distobuccal aspect

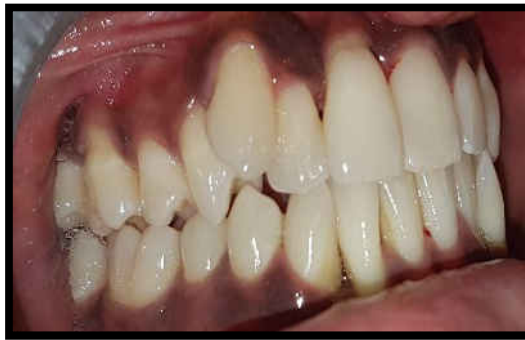

Gingival curettage in 32 distobuccal aspect

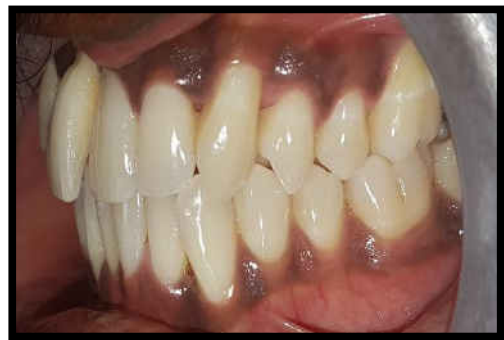POST OPERATIVE PHOTOS – 1 WEEK



Frontal view



Right Lateral view



Left lateral view

Case-21

DEMOGRAPHIC DATA

PATIENT NAME : Mrs. Narayani

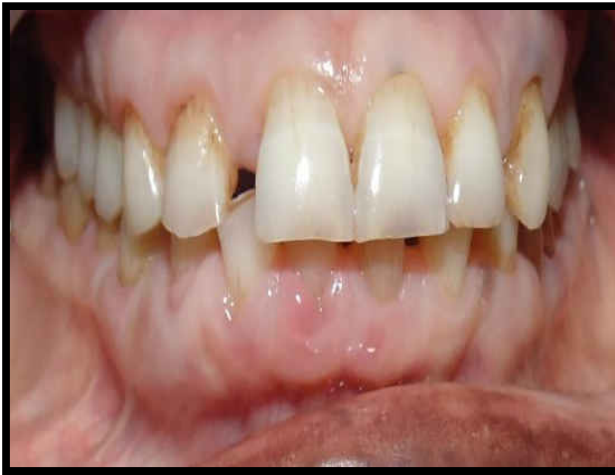DATE: 30.12.17

OP NO: 201712190038

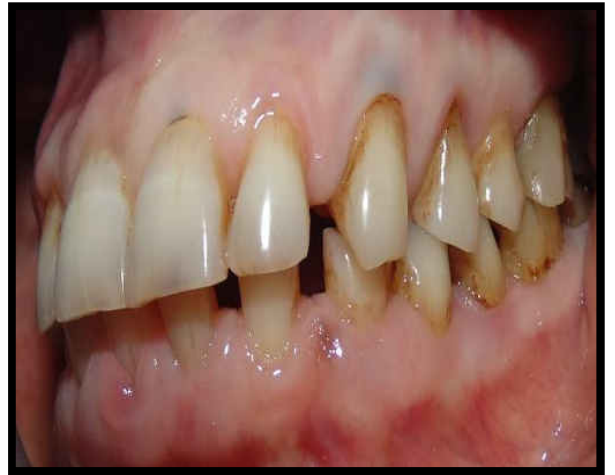AGE/SEX: 65/F

PROCEDURE: Gingival curettage done in relation to 11

PRE OPERATIVE PHOTO -30.12.17

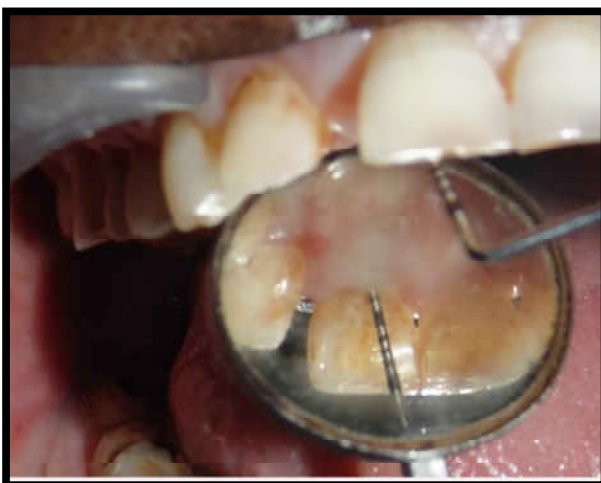

Frontal view



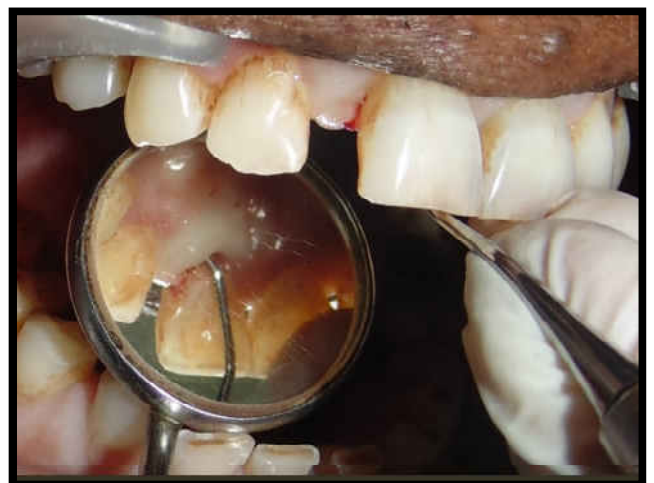Left lateral view

PRE OPERATIVE MEASUREMENTS



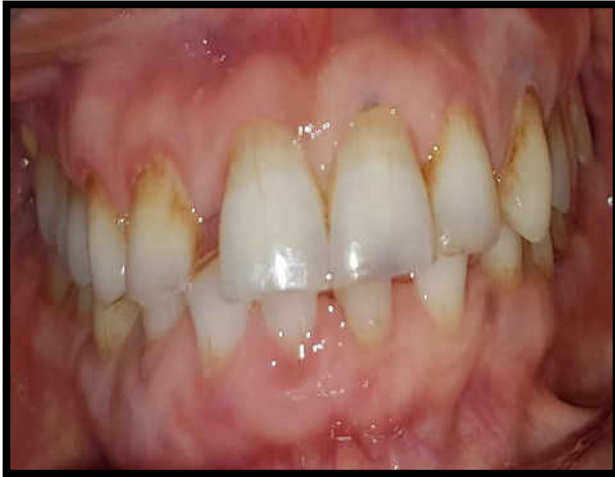PPD -7mm palatal aspect 11

OPERATIVE PHOTO-3.1.2018

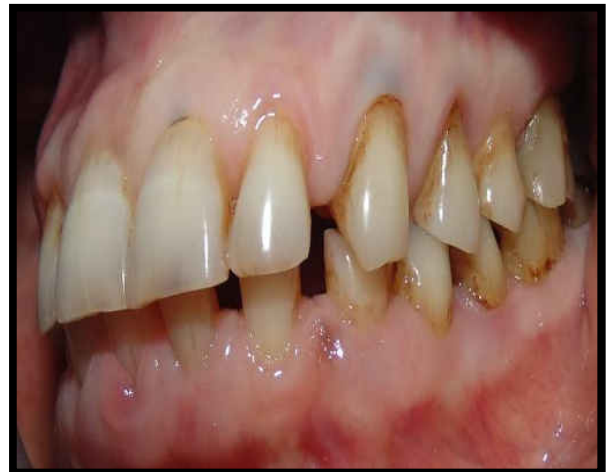

Gingival curettage in 11 palatal aspect

POST OPERATIVE PHOTO- 1 MONTH

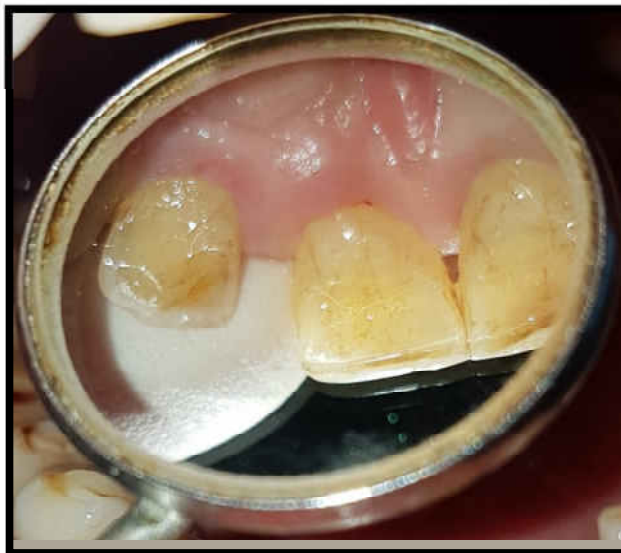

Frontal view



Left lateral view

POST OPERATIVE PHOTO- 3rd MONTH



Palatal aspect 11

Case-22

DEMOGRAPHIC DATA

PATIENT NAME :Mr. Venkat Rao

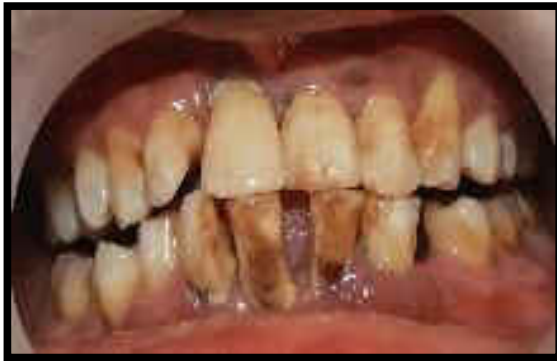DATE: 20.11.17

OP NO: 201711090006

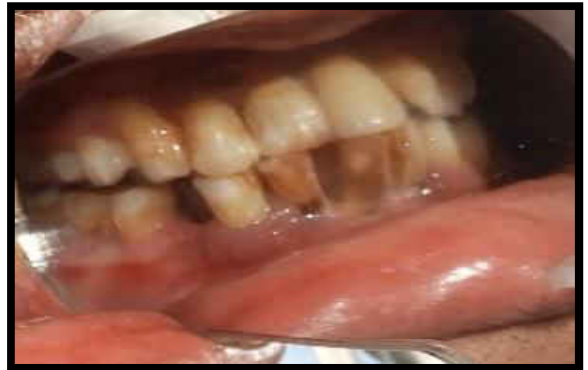AGE/SEX: 45/M

PROCEDURE: Gingival curettage done in relation to 11-17,21-27,33-37,44-46

PRE OPERATIVE PHOTO – 20.11.17

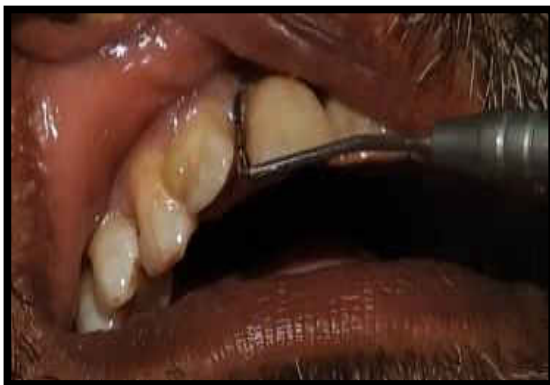

Frontal view

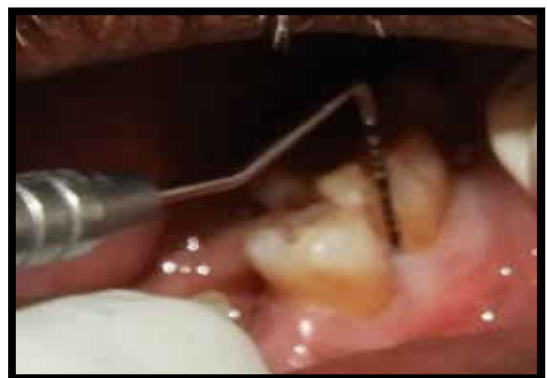

Left lateral view

PRE OPERATIVE MEASUREMENTS

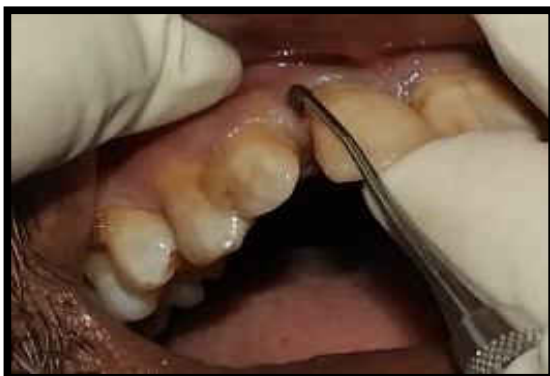

PPD –5mm in distobuccal aspect of 11

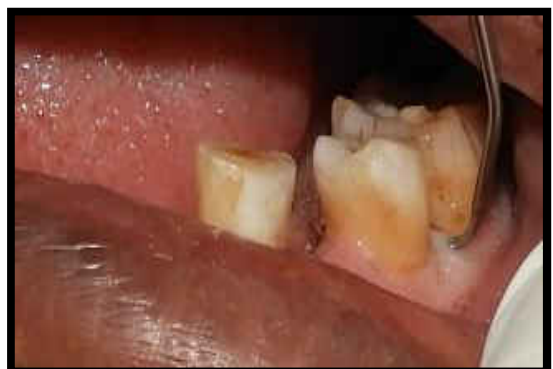

PPD –5mm in mesiobuccal aspect of 36

OPERATIVE PHOTO-7.12.17

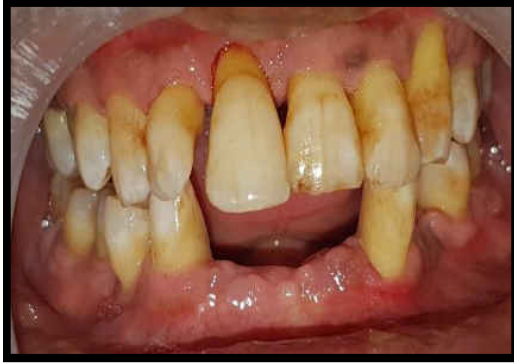

Gingival curettage in 11-distobuccal aspect

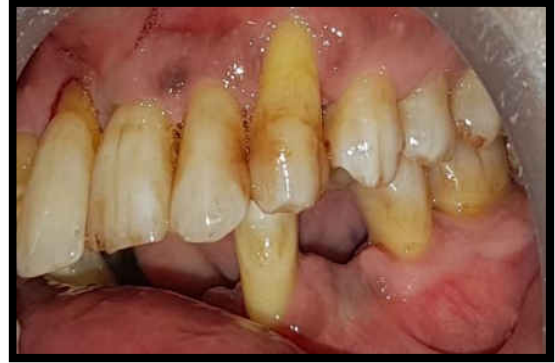

Gingival curettage in 36 mesiobuccal aspect

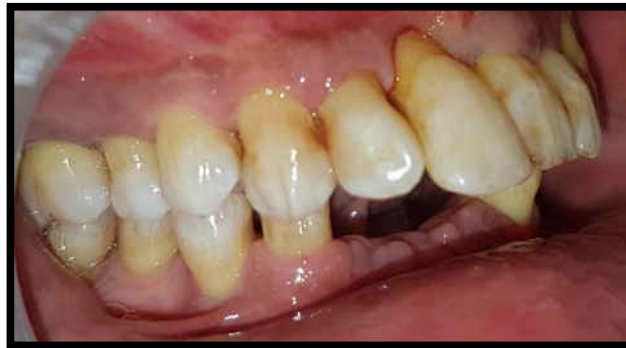POST OPERATIVE PHOTOS – 1 MONTH(21.1.18)



Frontal view

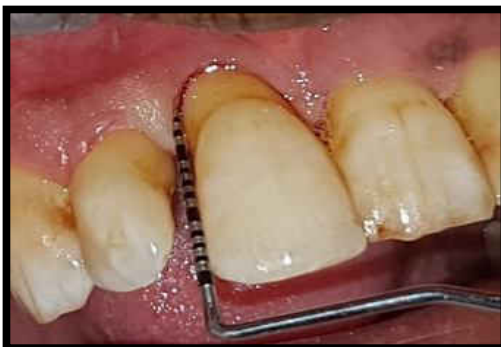

Left lateral view

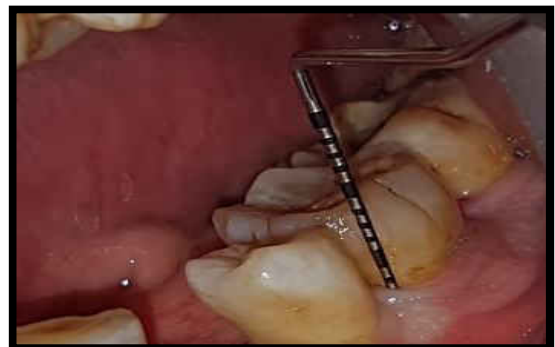


Right Lateral

POST OPERATIVE PHOTOS -3 MONTHS(13.4.18)



11-DISTOBUCCAL ASPECT



36- MESIOBUCCAL ASPECT

Case-23

DEMOGRAPHIC DATA

PATIENT NAME :Mr. Nibash Das

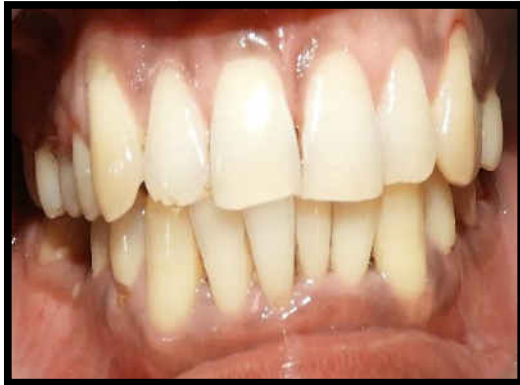DATE: 28.11.17

OP NO: 201711270161

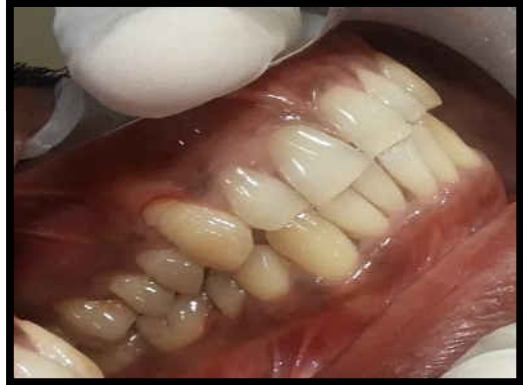AGE/SEX: 34/M

PROCEDURE: Gingival curettage done in relation to 25,26,27

PRE OPERATIVE PHOTO – 28.11.17

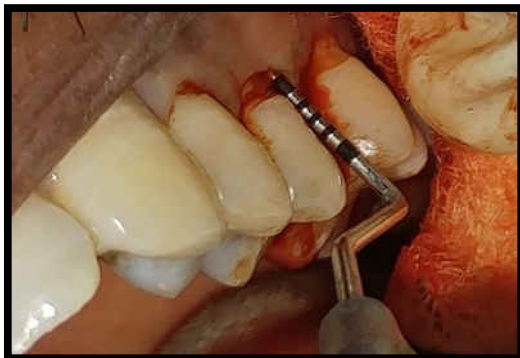


Frontal view

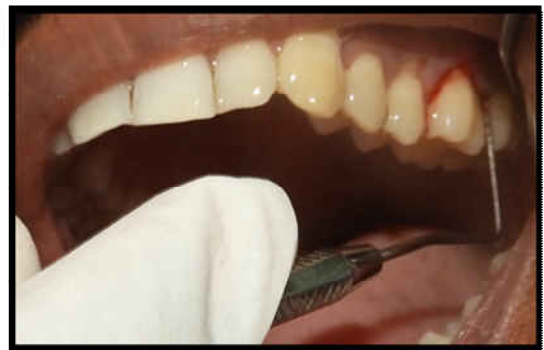


Left lateral view

PRE OPERATIVE MEASUREMENTS

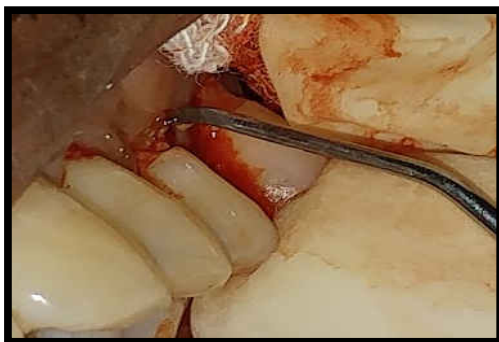


PPD –8mm in midbuccal aspect of 25

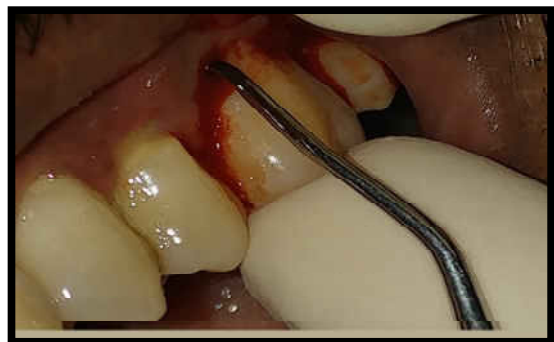

PPD –5mm distobuccal aspect 26

OPERATIVE PHOTO-5.12.17

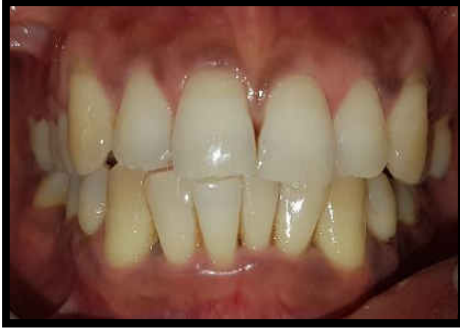

Gingival curettage in 25

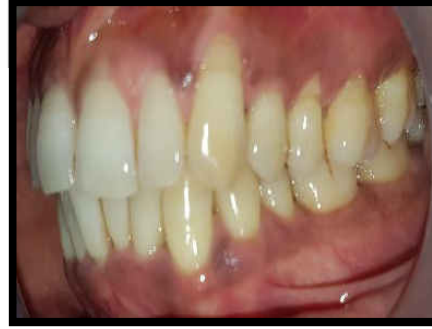

Gingival curettage in 26

POST OPERATIVE PHOTO – 1 MONTH

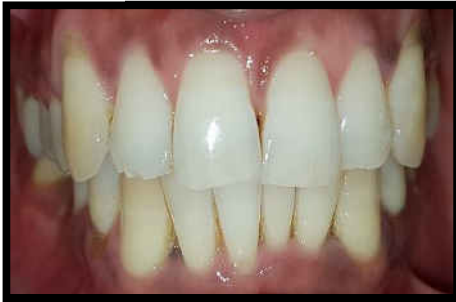

Frontal view

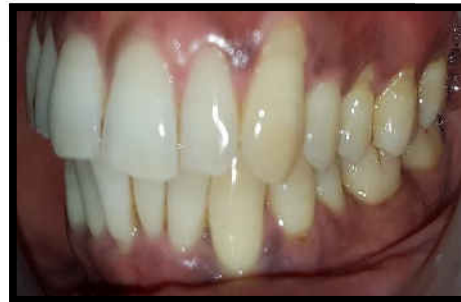

Left lateral view

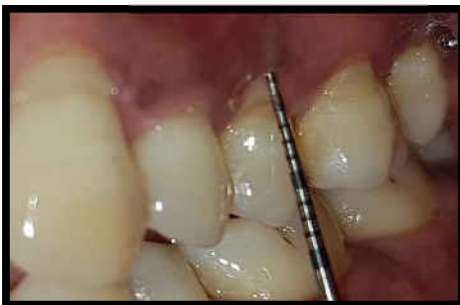**POST OPERATIVE PHOTO – 3rd MONTH
22/3/18**



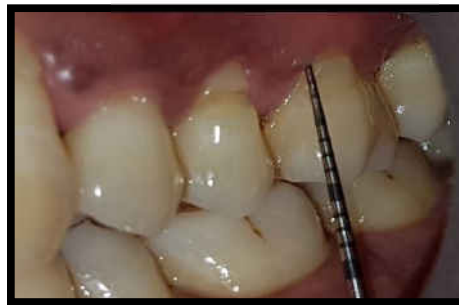Frontal view



Left lateral view



Midbuccal aspect-25



Mesiobuccal aspect-26

Case-24

DEMOGRAPHIC DATA

PATIENT NAME : Mr. Parthiban

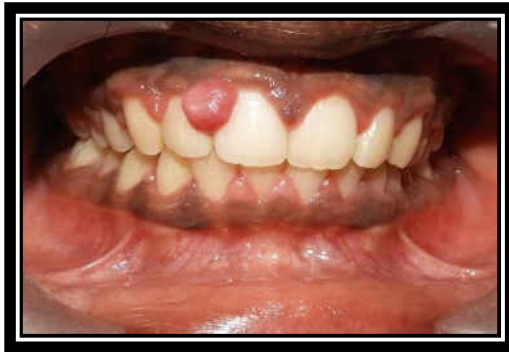DATE: 16.11.17

OP NO: 201711110077

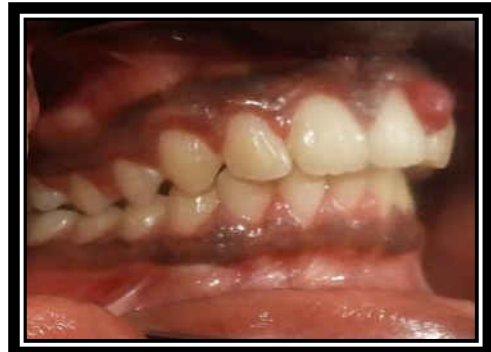AGE/SEX: 21/M

PROCEDURE: Gingival curettage done in relation to 11-17,23-27,37,44-47

PRE OPERATIVE PHOTO – 16.11.17

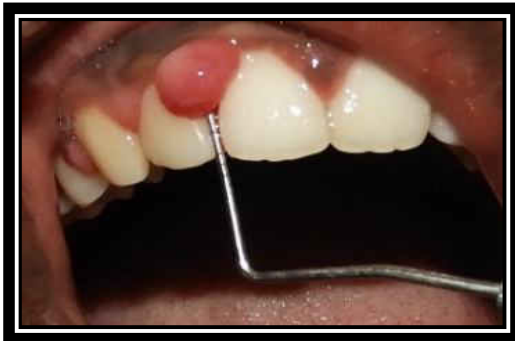

Frontal view

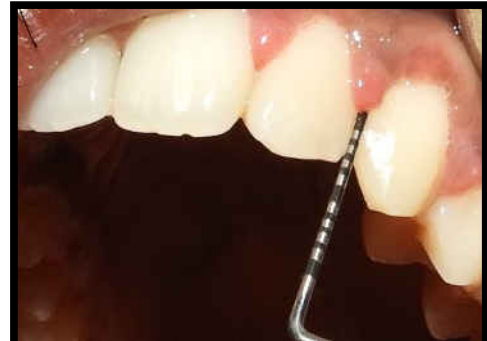

Left lateral view

PRE OPERATIVE MEASUREMENTS

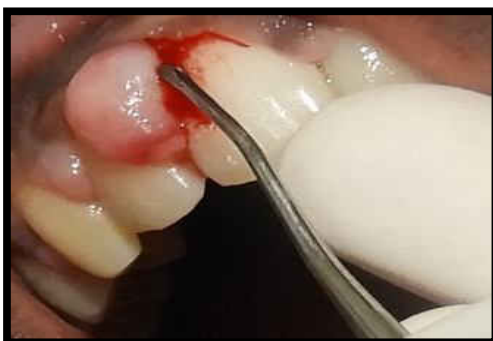

PPD –7mm in distobuccal aspect of 11

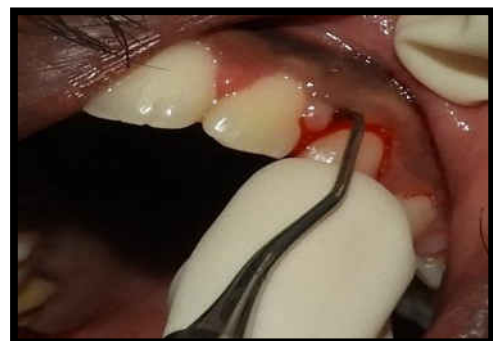

PPD–5mm in mesiobuccal aspect of 23

OPERATIVE PHOTO-29.11.17

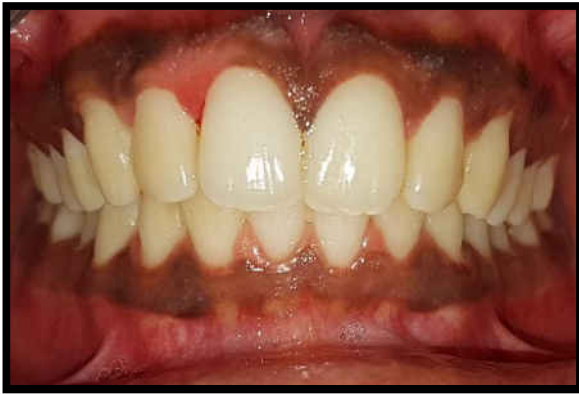

Gingival curettage in 11-distobuccal aspect

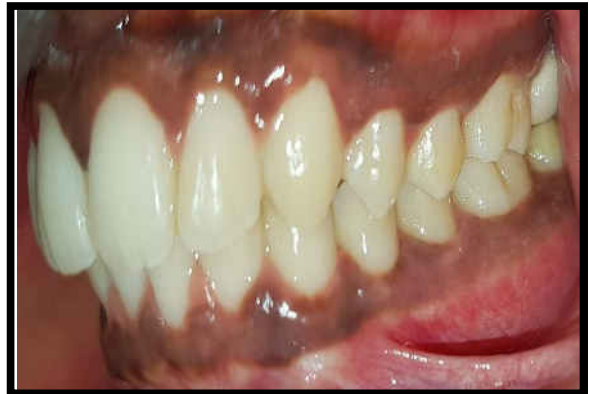

Gingival curettage in 23 mesiobuccal aspect

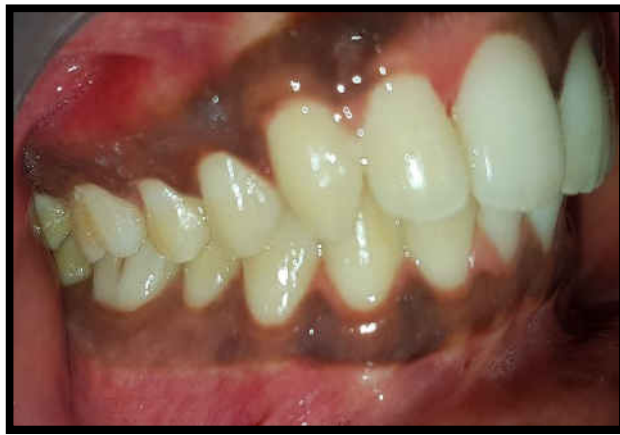POST OPERATIVE PHOTOS-1 MONTH (24.1.18)



Frontal view

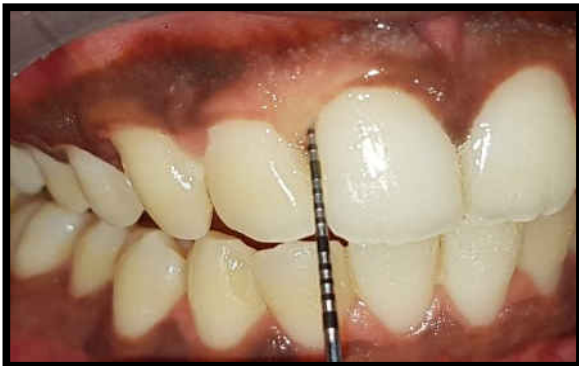

Left lateral view

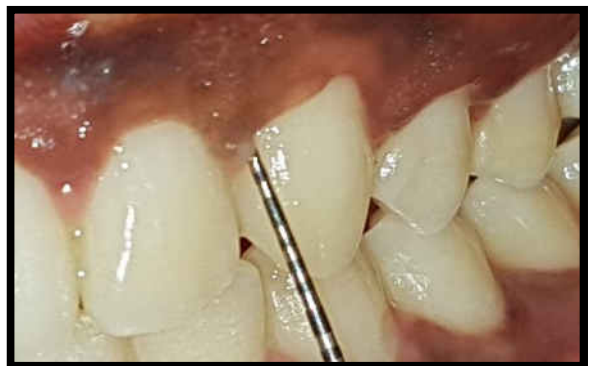

Right lateral view

POST OPERATIVE PHOTOS-3 MONTHS (4.4.18)



11-distobuccal aspect



23- mesiobuccal aspect

Case-25

DEMOGRAPHIC DATA

PATIENT NAME : Mr. Srinivasulu

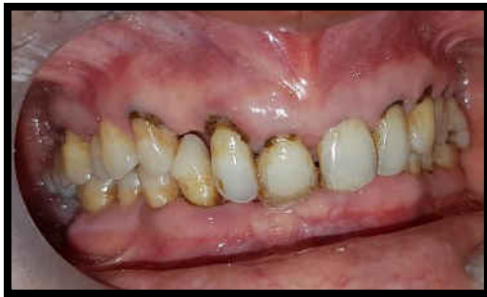DATE: 31.1.18

OP NO: 201801250118

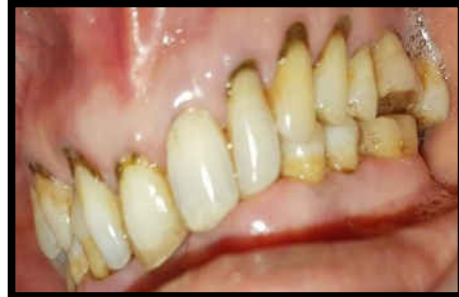AGE/SEX: 59/M

PROCEDURE: Gingival curettage done in relation to 1st, 2nd,
3rd, 4th Quadrant

PRE OPERATIVE PHOTO –31.1.18

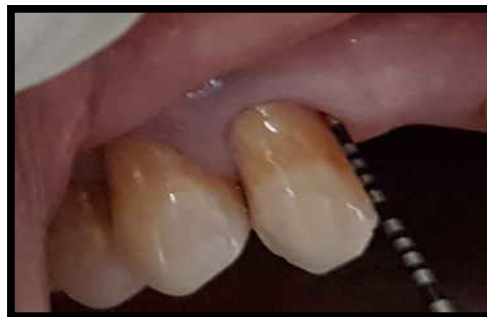

Frontal view



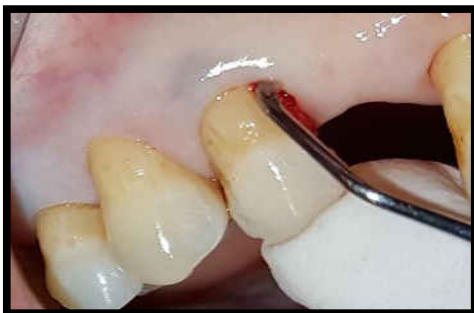Left lateral view

PRE OPERATIVE MEASUREMENTS

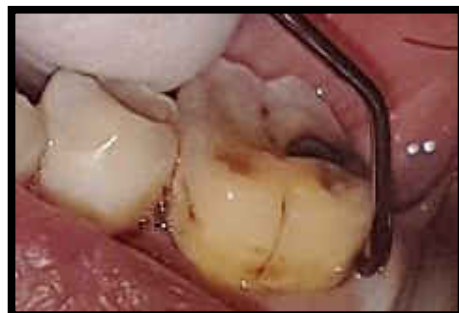

PPD –5mm in mesiobuccal I aspect 13

OPERATIVE PHOTO 8.2.18 and 20.3.18

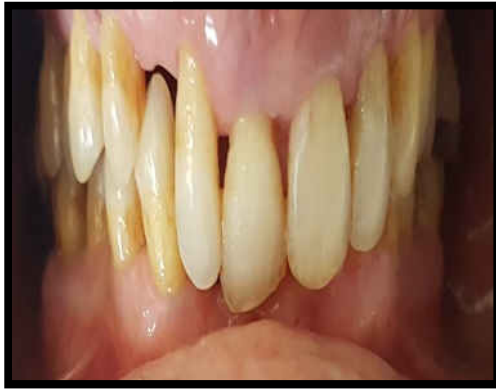

13 mesiobuccal aspect

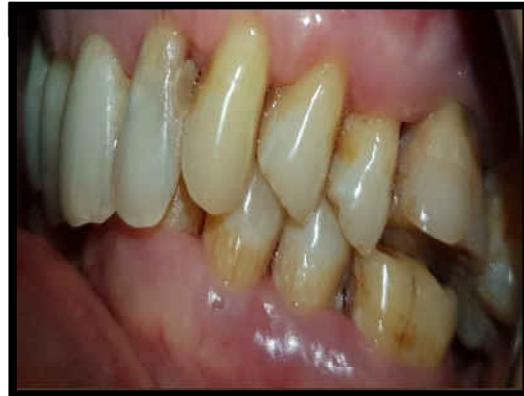

36- Distobuccal aspect

POST OPERATIVE PHOTO- 1 MONTH

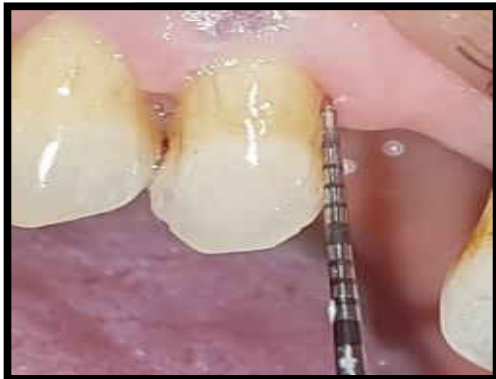

Frontal aspect

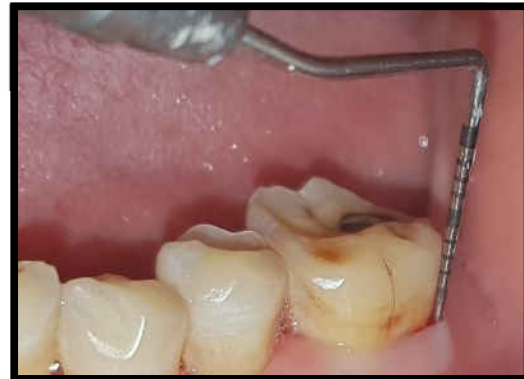

Right Lateral aspect

POST OPERATIVE PHOTOS – 3rd MONTH-5.7.18



Mesio Buccal aspect 13



Distobuccal aspect 36

Case-24

DEMOGRAPHIC DATA

PATIENT NAME :Mr. Suresh Babu

DATE: 21.4.18

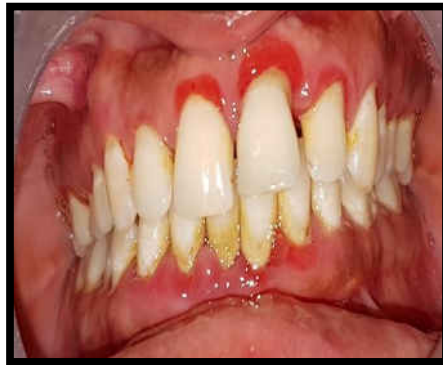OP NO: 201804190124

AGE/SEX: 30/M

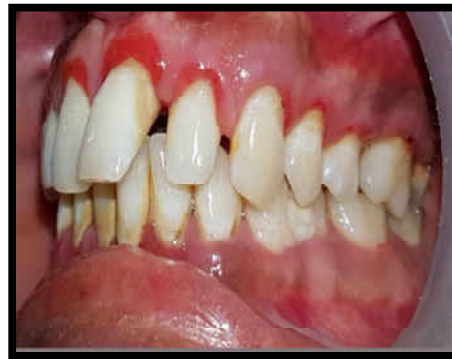PROCEDURE: Gingival curettage done in relation to

1st,2nd,3rd,4th Quadrant

PRE OPERATIVE PHOTO – 21.4.18

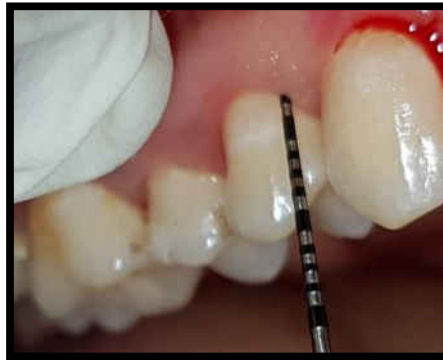

Frontal view

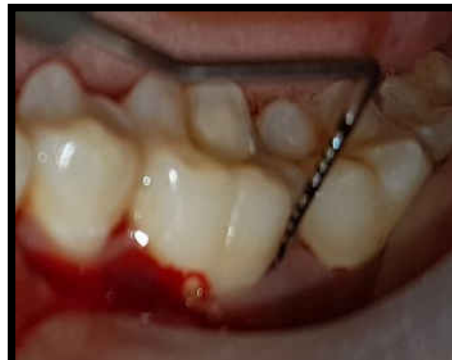

Left lateral view

PRE OPERATIVE MEASUREMENTS

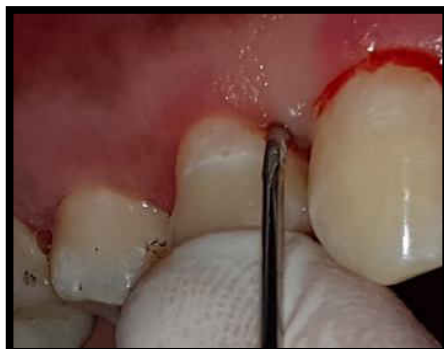

PPD –7mm in mesiobuccal aspect of 14

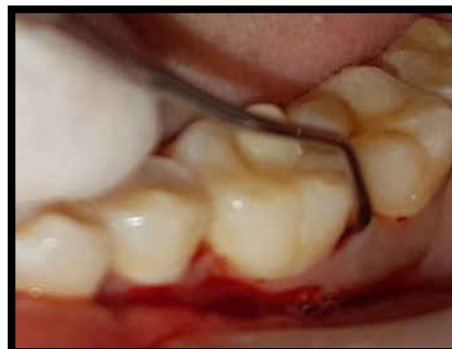

PPD –5mm in distobuccal aspect of 36

OPERATIVE PHOTO-5.5.18 and 12.5.18

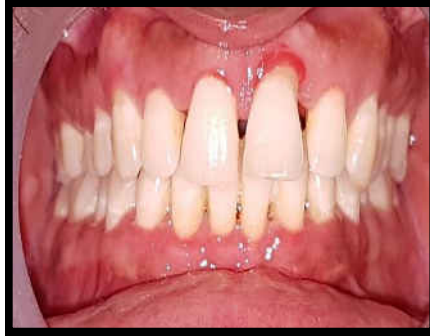

14 mesiobuccal aspect

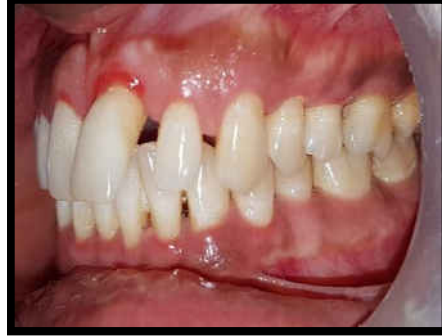

36 distobuccal aspect

POST OPERATIVE PHOTOS – 1 MONTH

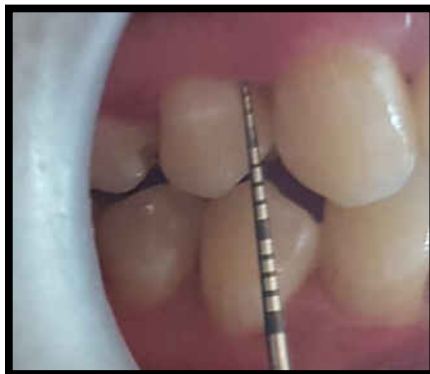

Frontal view

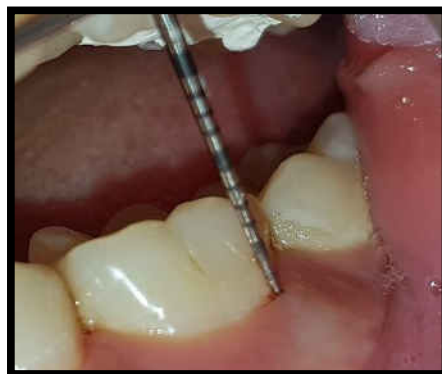

Left lateral view

**POST OPERATIVE PHOTOS – 3rd MONTH
9.7.18**



Mesio buccal aspect 14



Distobuccal aspect 36

Case-25

DEMOGRAPHIC DATA

PATIENT NAME :Mr. Vignesh

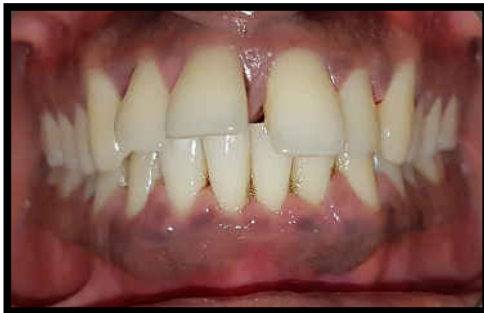DATE:7.3.18

OP NO:201802170165

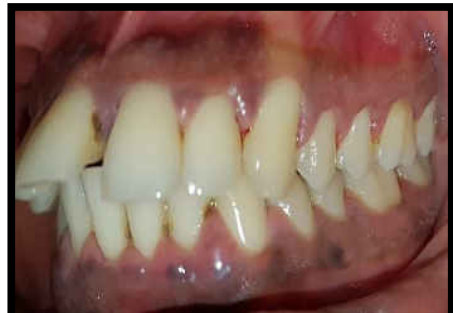AGE/SEX: 26/M

PROCEDURE: Gingival curettage done in relation to 11,12,15-18,
21-24, 26-28,31-34, 36-38, 41-48

PRE OPERATIVE PHOTO – 7.3.18

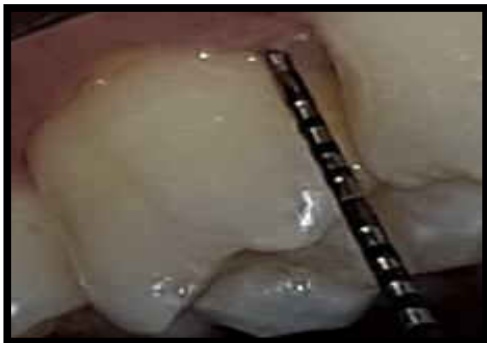

Frontal view

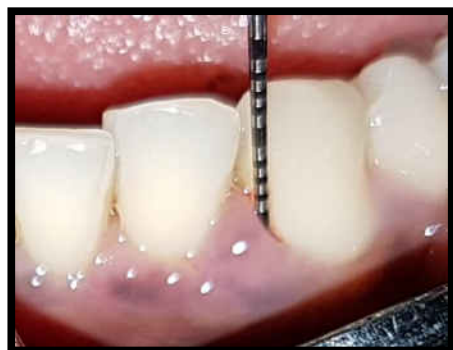

Left lateral view

PRE OPERATIVE MEASUREMENTS

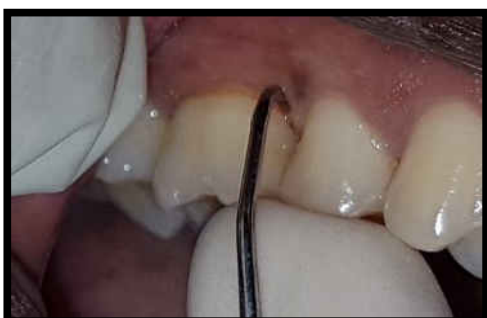

PPD -5 mm mesiobuccal aspect 16

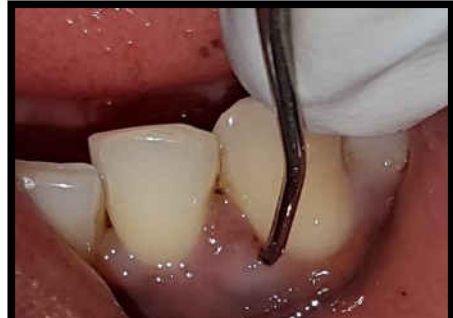

PPD-5 mm Mesiobuccal spect 33

OPERATIVE PHOTO- 13.3.18, 14.3.18

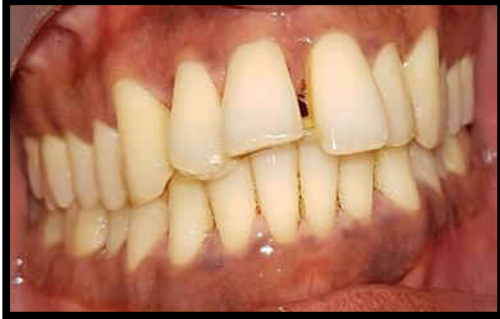

SRP mesiobuccal aspect 16

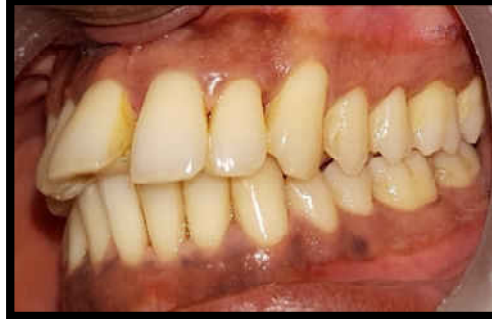

SRP mesiobuccal aspect 33

POST OPERATIVE PHOTOS – 3 MONTH



Frontal view



Left lateral view

CASE-26

DEMOGRAPHIC DATA

PATIENT NAME : Mrs. Vijaya

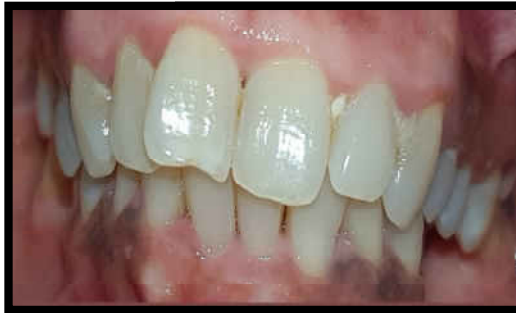DATE: 26.5.18

OP NO: 201805120103

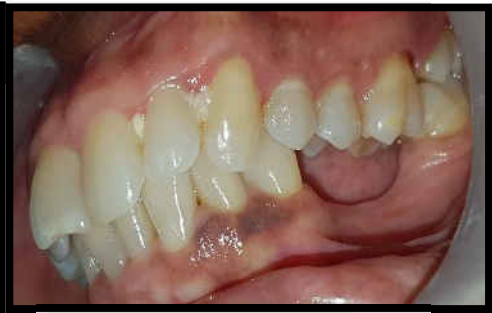AGE/SEX: 51/F

PROCEDURE: SRP done in relation to 26,27

PRE OPERATIVE PHOTO – 26.5.18

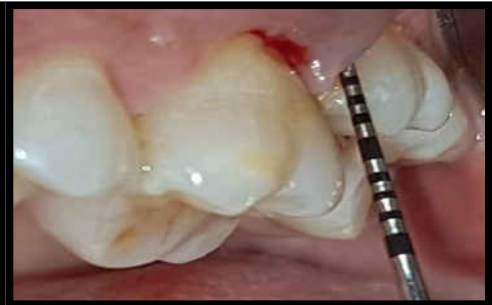
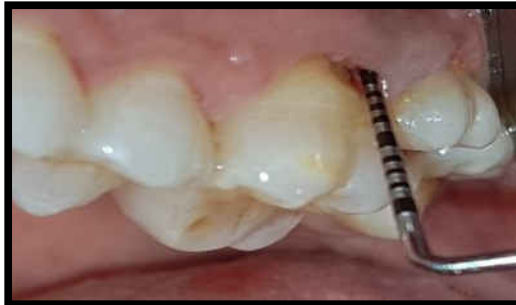
Frontal view



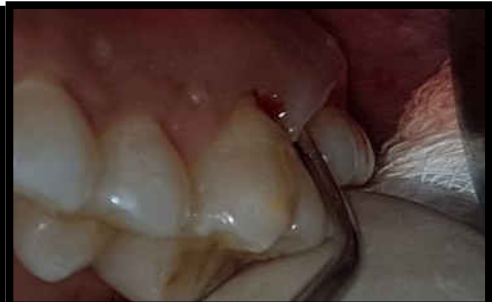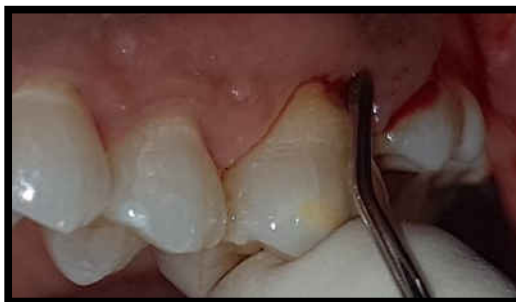Right Laterall view

PRE OPERATIVE MEASUREMENTS



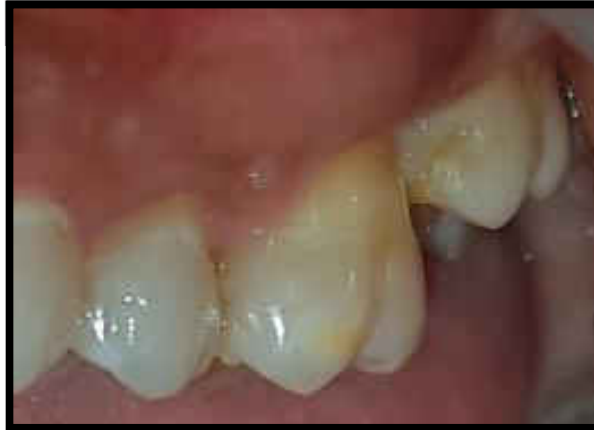Periodontal Probing Pocket Depth
5 mm in 26, 27

OPERATIVE PHOTO-26.5.18



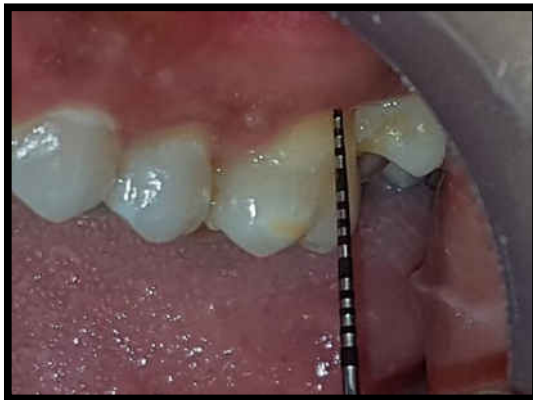SRP 26,27

POST OPERATIVE PHOTO- 1 MONTH

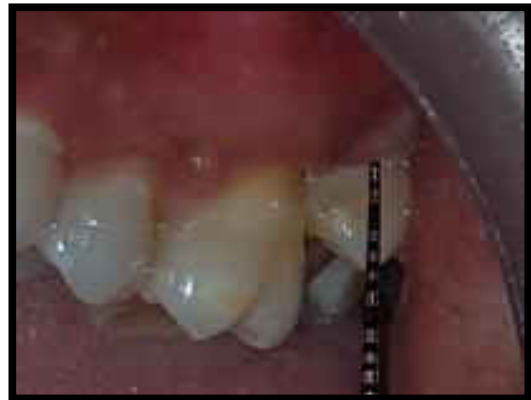

Right lateral view

POST OPERATIVE PHOTO- 3rd MONTH



Midbuccal aspect 26



Mesiobuccal aspect 27

Case-27

DEMOGRAPHIC DATA

PATIENT NAME : Mrs. Vijaya

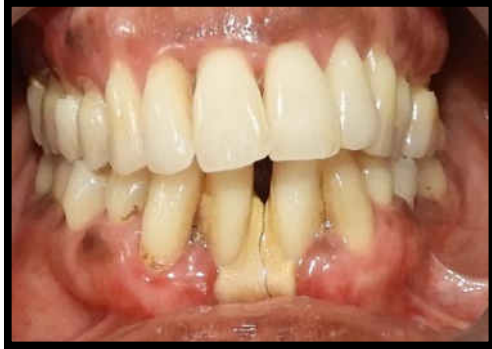DATE: 20/11/17

OP NO: 201712110007

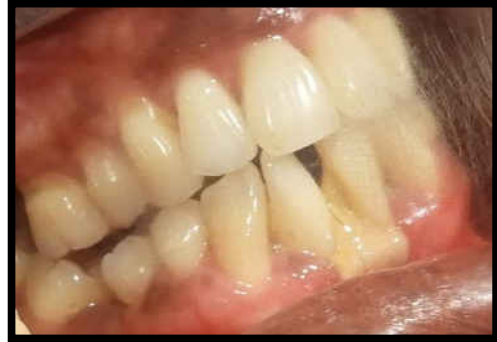AGE/SEX: 45/F

PROCEDURE: Gingival curettage done in relation to 16,34

PRE OPERATIVE PHOTO – 20.11.17

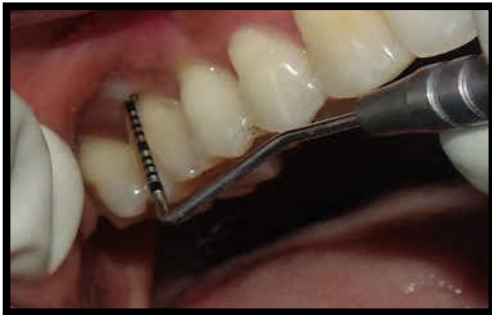

Frontal view

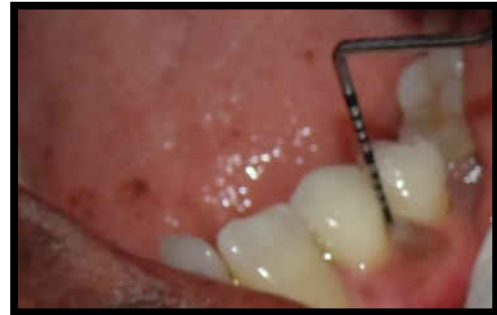

Left lateral view

PRE OPERATIVE MEASUREMENTS

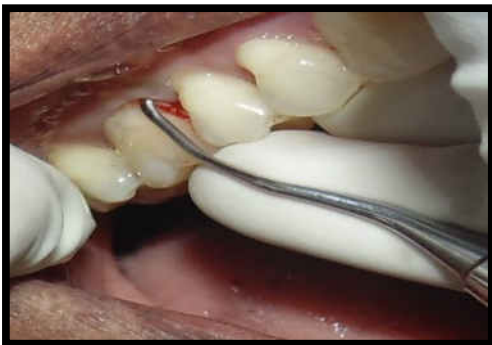

PPD –5mm in midbuccal aspect of 16

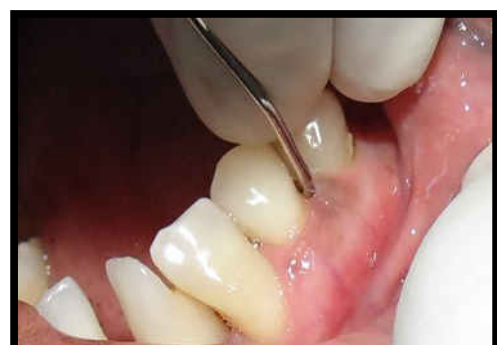

PPD –5mm in distobuccal aspect of 34

OPERATIVE PHOTO-4.12.17

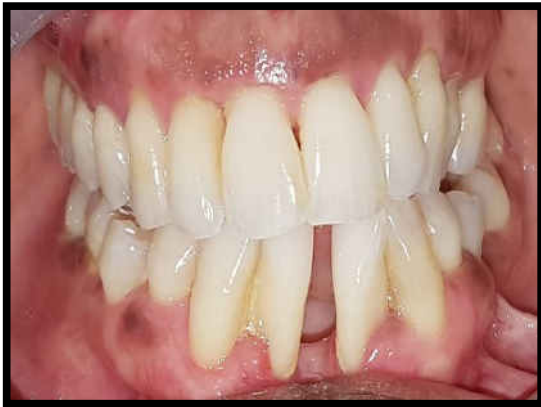

Gingival curettage in 16 mesiobuccall aspect

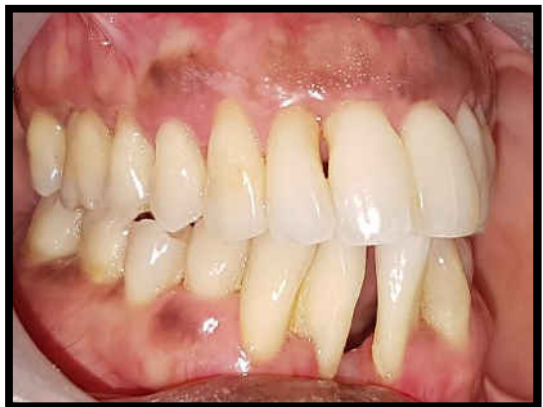

Gingival curettage in 34 distobuccal aspect

POST OPERATIVE PHOTO-1st MONTH

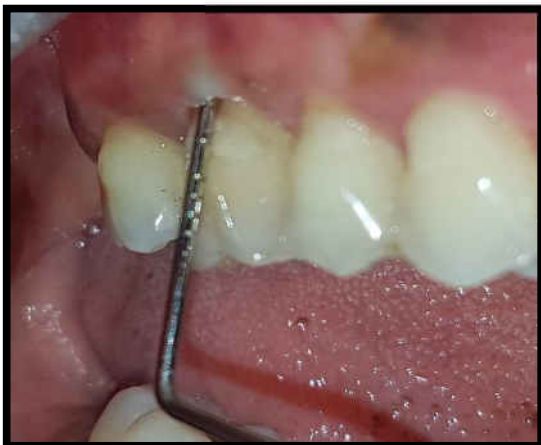

Frontal view

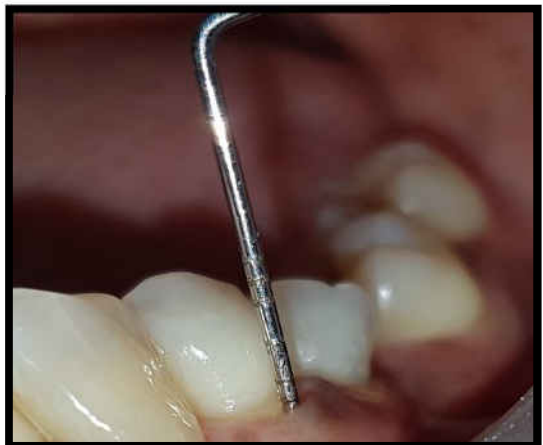

Left lateral view

POST OPERATIVE PHOTO-3rd MONTH



Midbuccal 16



Distobuccal 34

LDD

CASE-1

DEMOGRAPHIC DATA

PATIENT NAME :Mr. Venkata Subramaniam

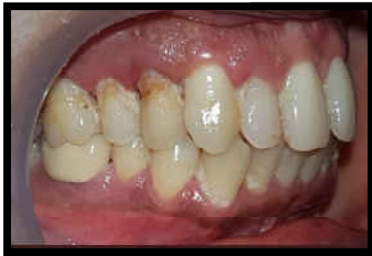DATE:12.2.19

OP NO: CSSH 255290

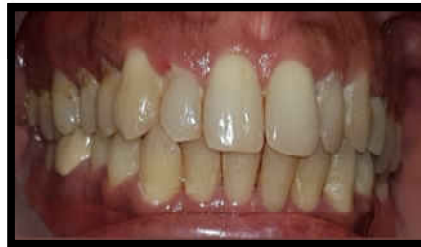AGE/SEX: 65/M

PROCEDURE: Local drug delivery

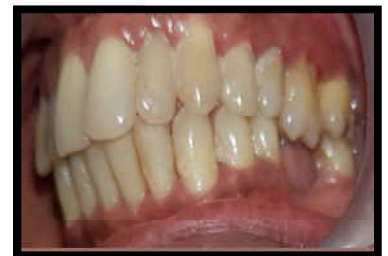PRE OPERATIVE PHOTO -14.2.19



Right lateral view

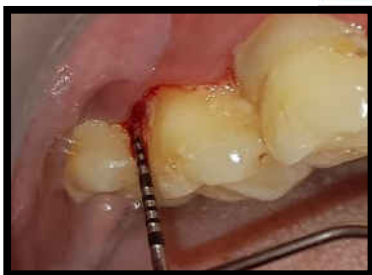

Frontal view

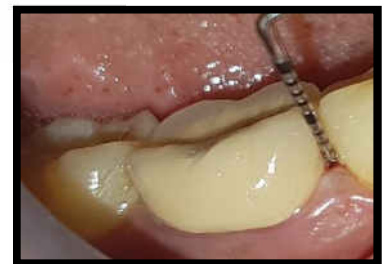

Left lateral view

PRE OPERATIVE MEASUREMENTS

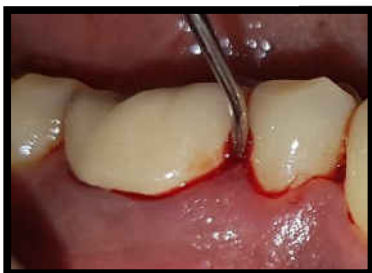

Periodontal probing pocket depth
5mm distobuccal aspect 17

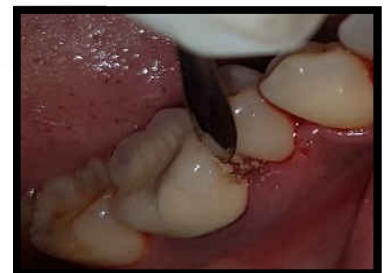

Periodontal probing pocket depth 5
mm mesiobuccal aspect 46

OPERATIVE PHOTO-14.2.2019



Scaling and root planning
mesiobuccal aspect 46



Local drug delivery at
mesiobuccal aspect 46

CASE-2

DEMOGRAPHIC DATA

PATIENT NAME: Mrs. Anbalagi

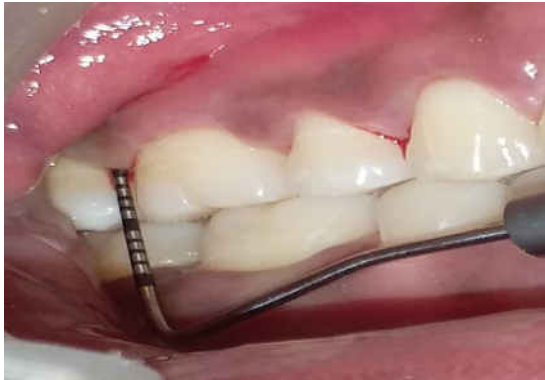DATE: 15.2.2019

OP NO: 201902140110

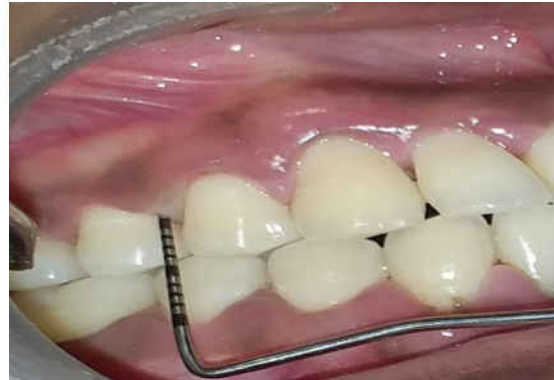AGE/SEX: 28/F

PROCEDURE: Scaling & root planning in relation to 16,17 with tetracycline fiber inserted into 16,17

PRE OPERATIVE PHOTO

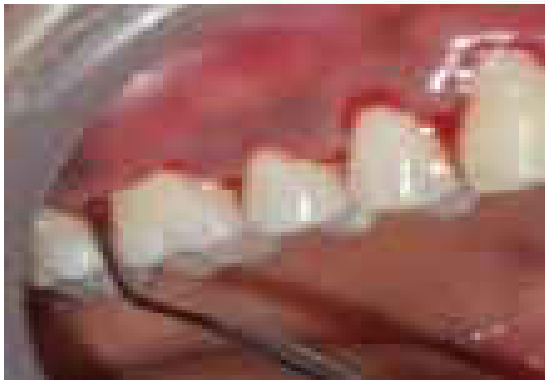

PPD (UNC-15 probe)-5mm in distobuccal aspect of 16

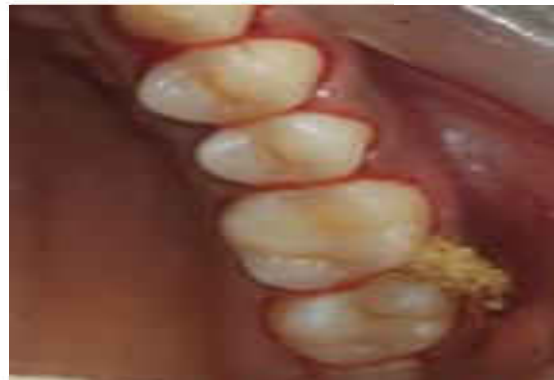

PPD (UNC-15 probe)-4mm in mesiobuccal aspect of 15

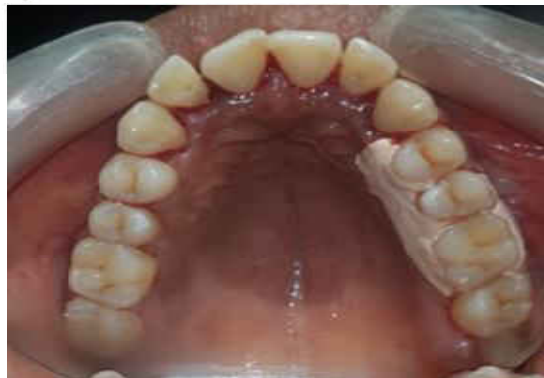OPERATIVE PHOTO



Scaling & root planning in 16 distobuccal aspect



Tetracycline fibers inserted into 16,17



COE pack given in 15,16,17

CASE-3

DEMOGRAPHIC DATA

PATIENT NAME: Mr. Kasi

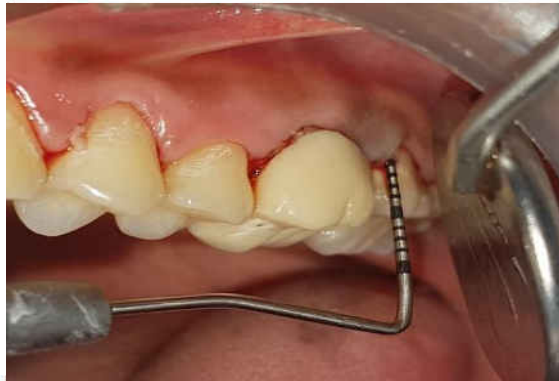DATE: 15.2.2019

OP NO: 201902140127

AGE/SEX: 34/M

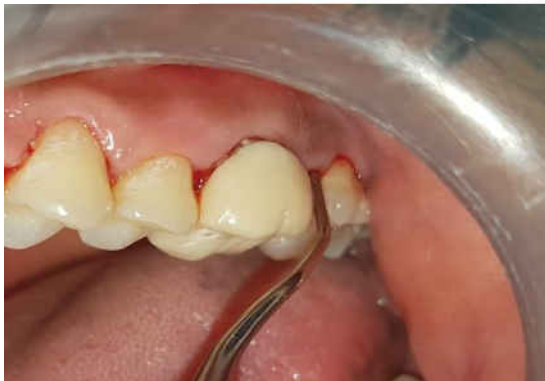PROCEDURE: Scaling & root planning in relation to 26,27 with tetracycline fiber inserted into 26,27

PRE OPERATIVE PHOTO

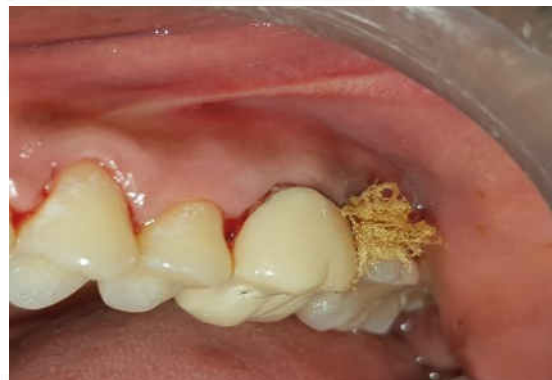

PPD (UNC-15 probe)-5mm in mesiobuccal aspect of 26

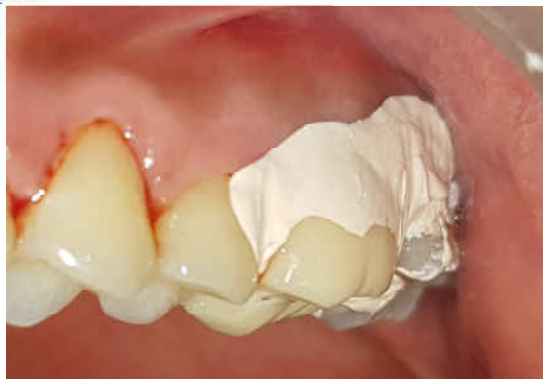OPERATIVE PHOTO



Scaling & root planning in 26 distobuccal aspect



Tetracycline fibers inserted into 26,27



COE pack given in 26,27

CASE-4

DEMOGRAPHIC DATA

PATIENT NAME: Mr. Sharmaa

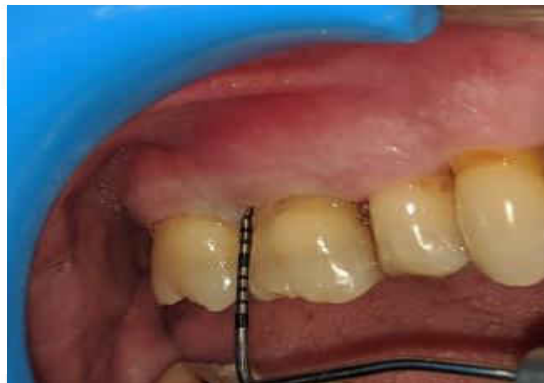DATE: 1.3.2019

OP NO: 20181150035

AGE/SEX: 66/M

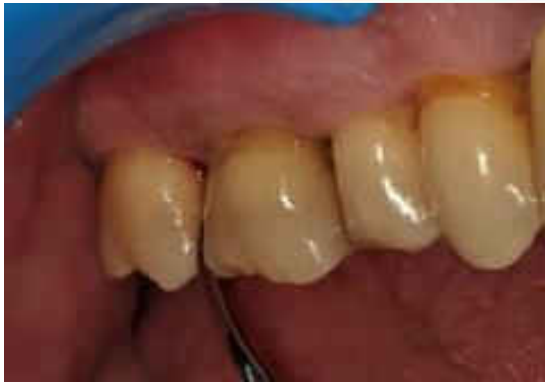PROCEDURE: Scaling & root planning in relation to 16,17 with tetracycline fiber inserted into 16,17

PRE OPERATIVE PHOTO

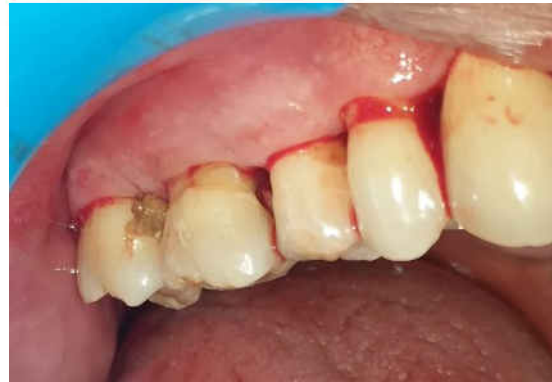

PPD (UNC-15 probe)-5mm in distobuccal aspect of 16

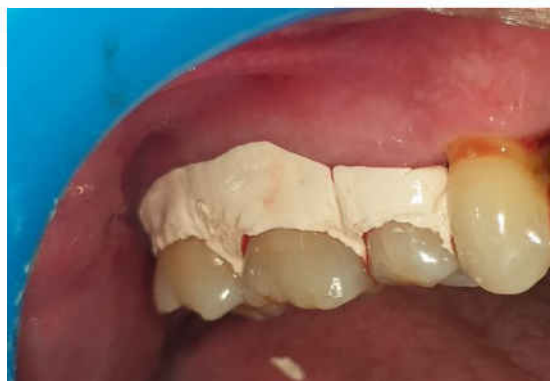OPERATIVE PHOTO



Scaling & root planning in 16 distobuccal aspect



Tetracycline fibers inserted into 16,17



COE pack given in 15,16,17

CASE-5

DEMOGRAPHIC DATA

PATIENT NAME: Mr. Nambirajan

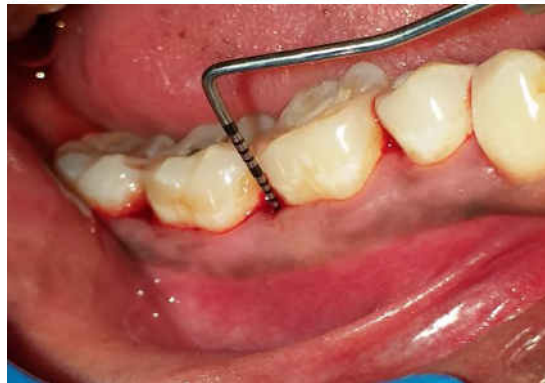DATE: 22.3.2019

OP NO: 201902140116

AGE/SEX: 30/M

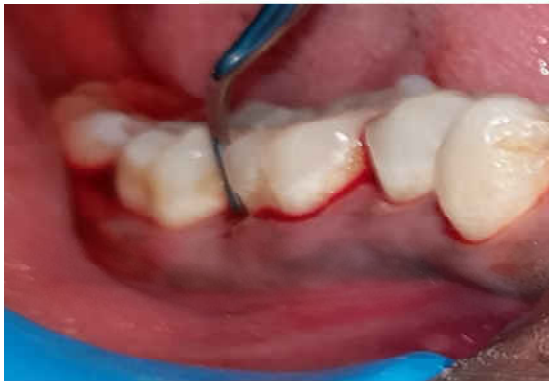PROCEDURE: Scaling & root planning in relation to 46,47 with tetracycline fiber inserted into 46,47

PRE OPERATIVE PHOTO

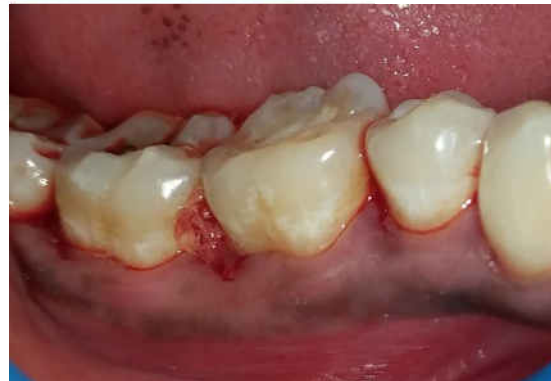

PPD (UNC-15 probe)-5mm in distobuccal aspect of 46

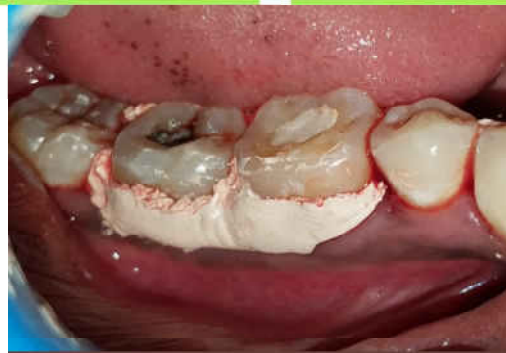OPERATIVE PHOTO



Scaling & root planning in 46 distobuccal aspect



Tetracycline fibers inserted into 46,47



COE pack given in 46,47

CASE-6

DEMOGRAPHIC DATA

PATIENT NAME: Mrs.Rajeshwari

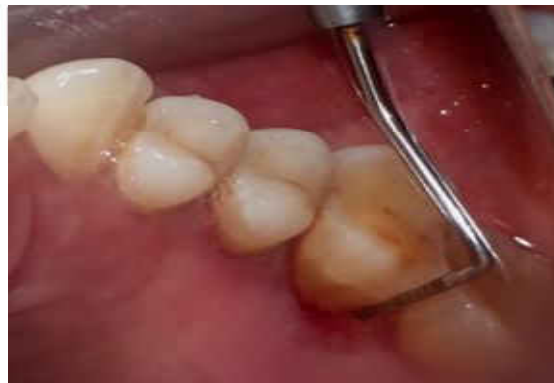DATE: 24.12.2018

OP NO: 201806120090

AGE/SEX: 64/F

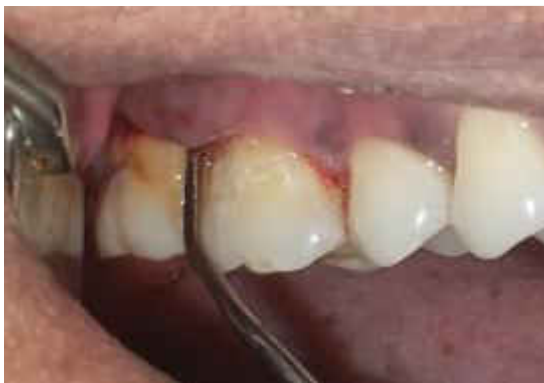PROCEDURE: Scaling & root planning in relation to 16,17 with tetracycline fiber inserted in relation to 16,17

PRE OPERATIVE PHOTO

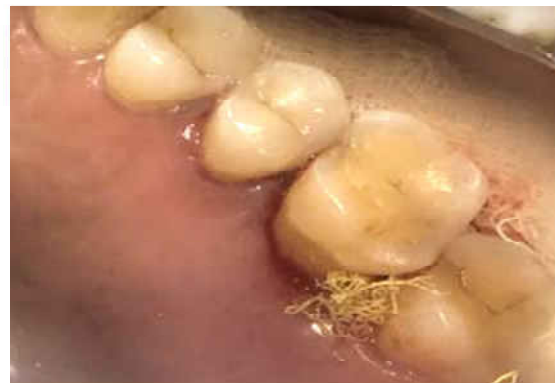

PPD(UNC-15 probe) -5mm in distopalatal aspect of 16

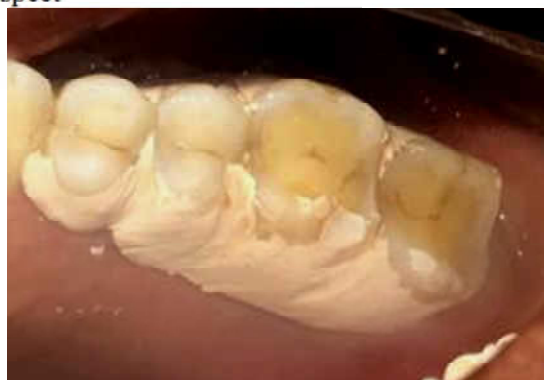OPERATIVE PHOTO



Scaling & root planning in 16 distobuccal aspect



Tetracycline fibers inserted into 16,17



COE pack given in 15,16,17

SPLINTTING

Case-1

DEMOGRAPHIC DATA

PATIENT NAME: Mr. Dhandapani

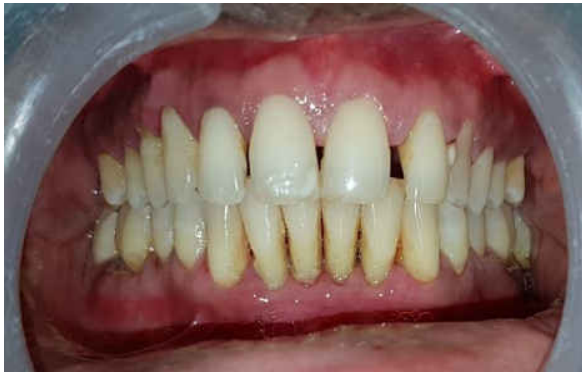DATE: 10.5.2018

OP NO: 201803280163

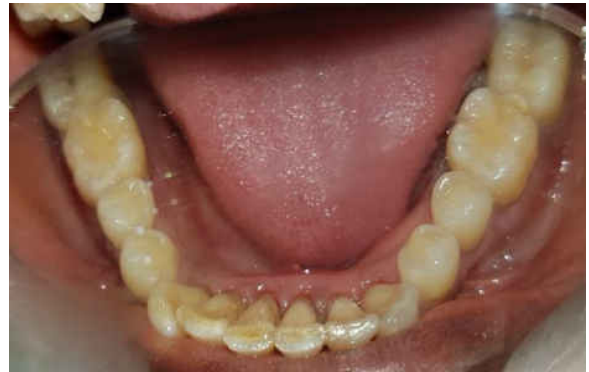AGE/SEX: 44/M

PROCEDURE: Mandibular arch splinting done in relation to 31,32,33,41,42,43 with fixed intracoronal composite wire

PRE OPERATIVE PHOTO

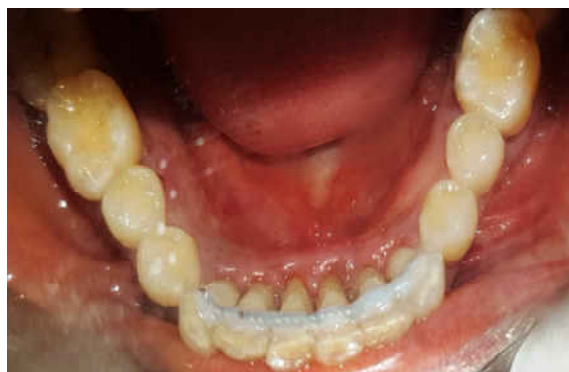

Frontal view



Lower occlusal view

OPERATIVE PHOTO



Splinting done in relation to 31,32,33,41,42,43

Case-2

DEMOGRAPHIC DATA

PATIENT NAME: Mrs. Indira

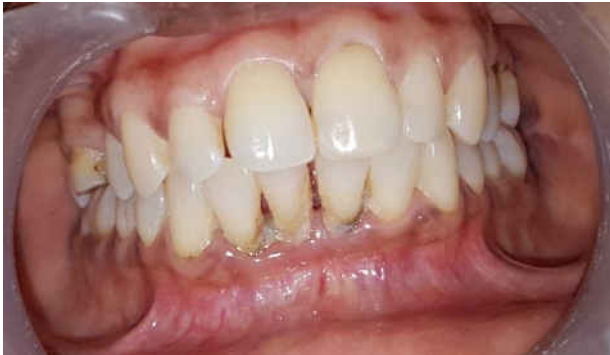DATE: 27.04.2018

OP NO: 201804250163

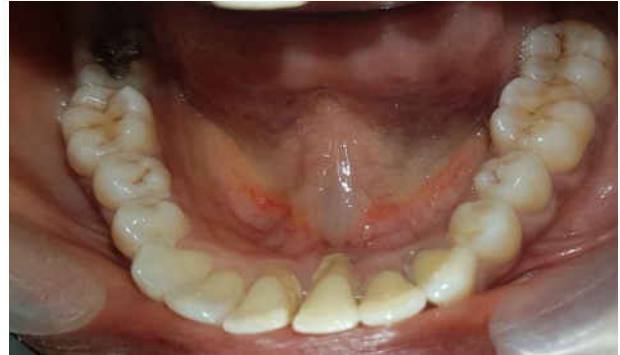AGE/SEX: 60/F

PROCEDURE: Mandibular arch splinting done in relation to 31,32,33,41,42,43 with fixed intracoronal composite wire

PRE OPERATIVE PHOTO

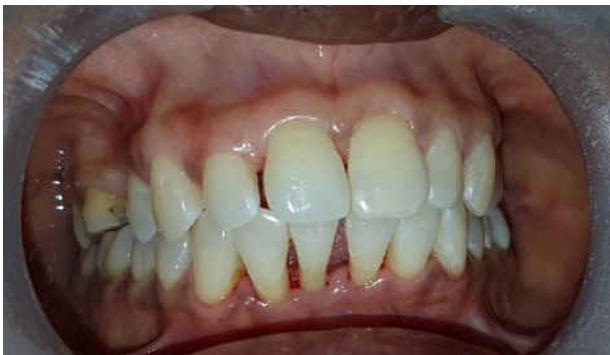

Frontal view

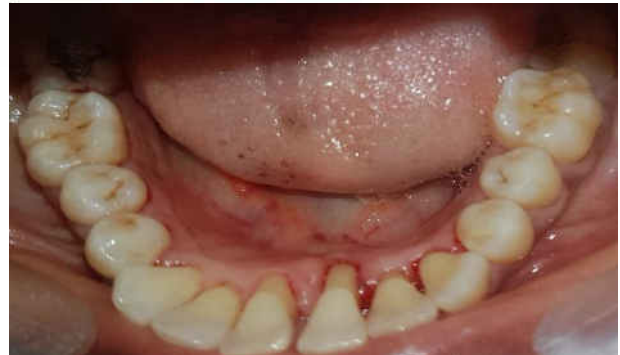

Lower occlusal view

POST- SCALING PHOTO

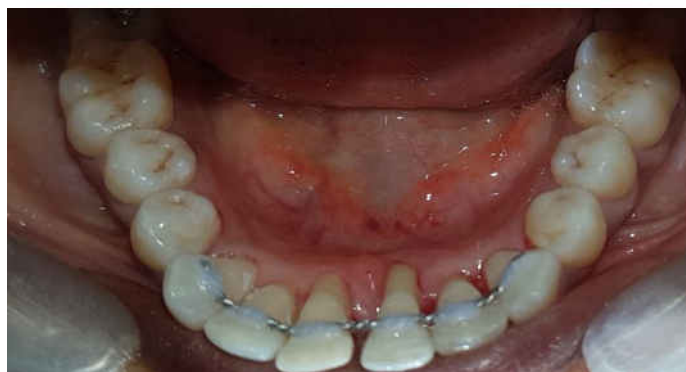

Frontal view



Lower occlusal view

OPERATIVE PHOTO



Splinting done in relation to 31,32,33,41,42,43

Case-3

DEMOGRAPHIC DATA

PATIENT NAME: Mr. Srinivasan

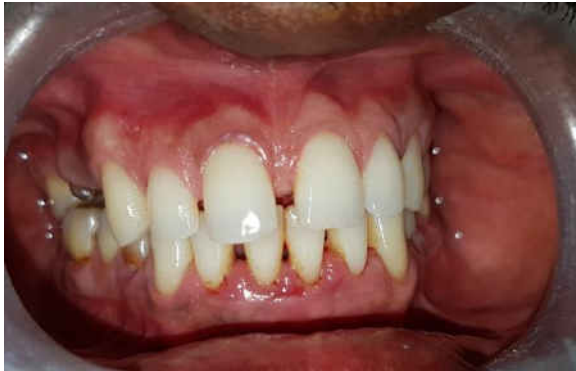DATE: 12.05.2018

OP NO: 201805716104

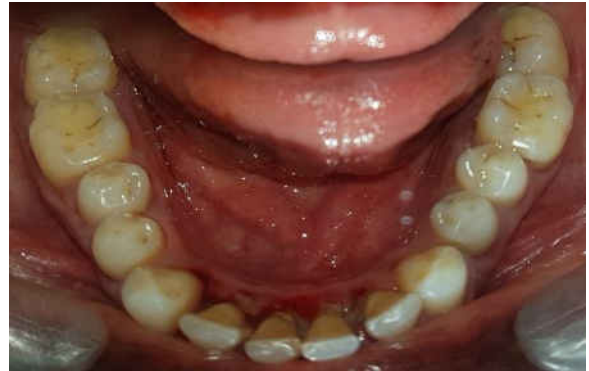AGE/SEX: 47/M

PROCEDURE: Mandibular arch splinting done in relation to 31,32,33,41,42,43 with fixed intracoronal composite wire

PRE OPERATIVE PHOTO

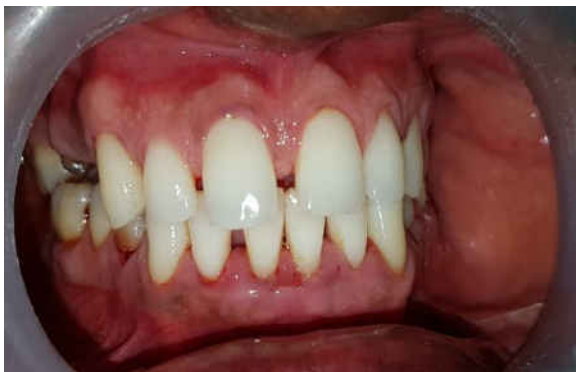

Frontal view

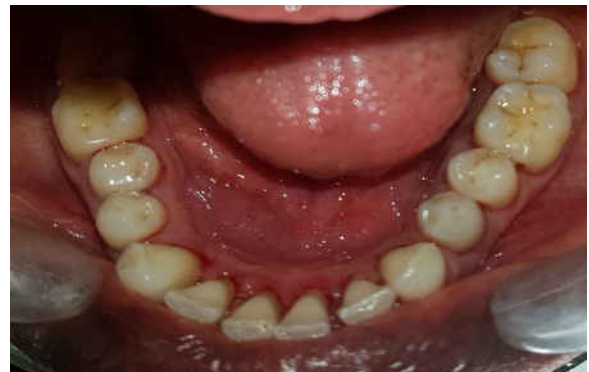

Lower occlusal view

POST- SCALING PHOTO

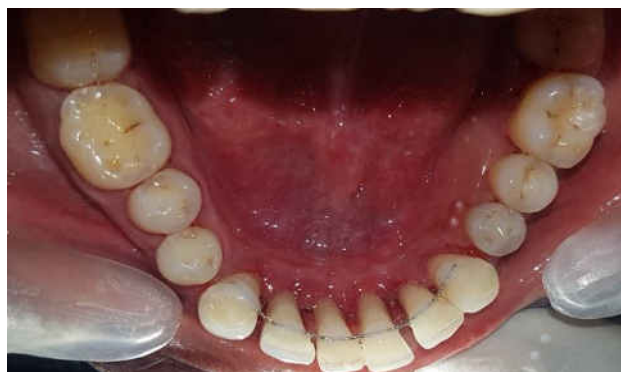

Frontal view



Lower occlusal view

OPERATIVE PHOTO



Splinting done in relation to 31,32,33,41,42,43

Case-4

DEMOGRAPHIC DATA

PATIENT NAME :Mr. Khallelullah

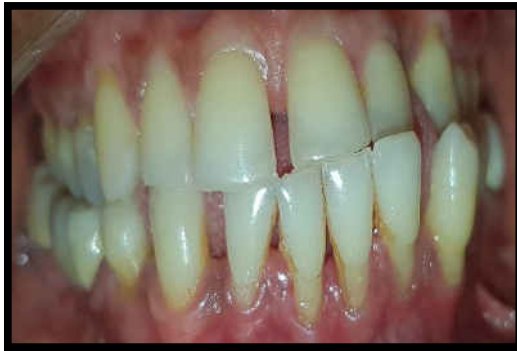DATE: 27.5.2018

OP NO: 201807070067

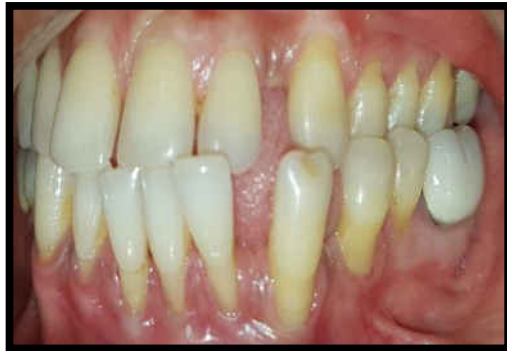AGE/SEX: 47/M

PROCEDURE: Splinting done in relation to 31,32,43,41,42,43- composite wire splint

PRE OPERATIVE PHOTO – 27.5.18

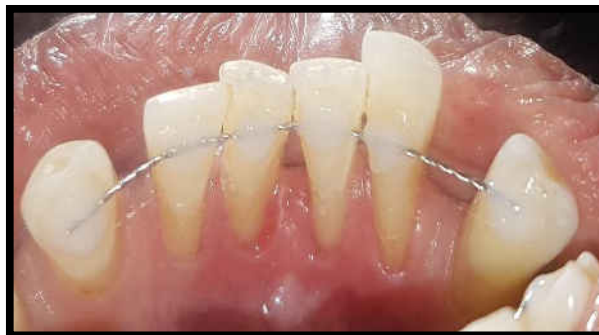

Frontal view



Left lateral view

SPLINTING



Splinting 31,32,33,41,42,43

Case-5

DEMOGRAPHIC DATA

PATIENT NAME : Mrs. Ponnu Siva

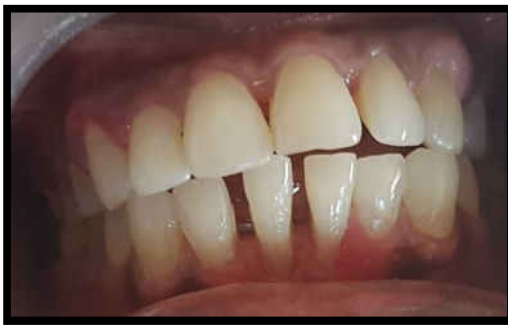DATE: 11.5.2018

OP NO: 201805080138

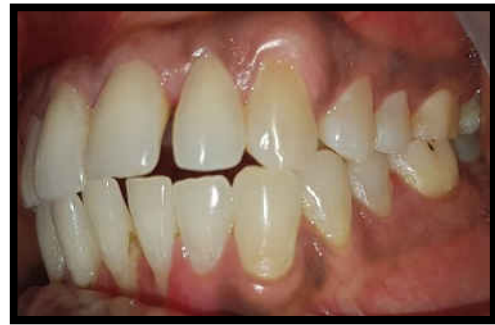AGE/SEX: 35/F

PROCEDURE: Coronoplasty 41 & Splinting done in relation to
31,32,43,41,42,43- composite wire splint

PRE OPERATIVE PHOTO – 11.5.18

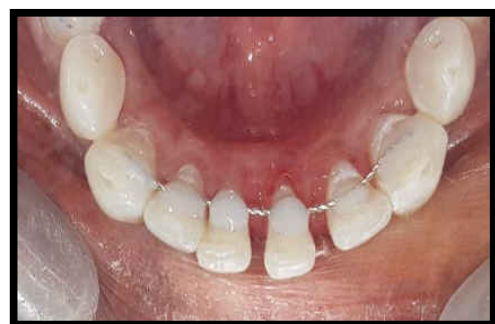
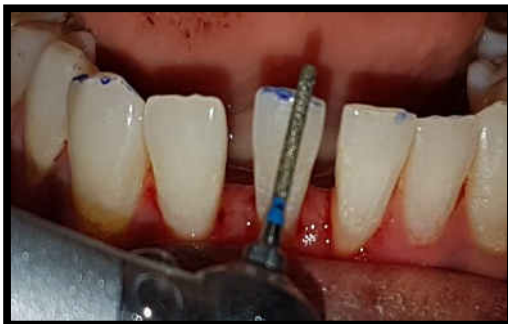
Frontal view



Left lateral view

SPLINTING



Coronoplasty 41 & Splinting 11,12,13,21,22,23

CASE-6

DEMOGRAPHIC DATA

PATIENT NAME: Mr. Duraiswamy

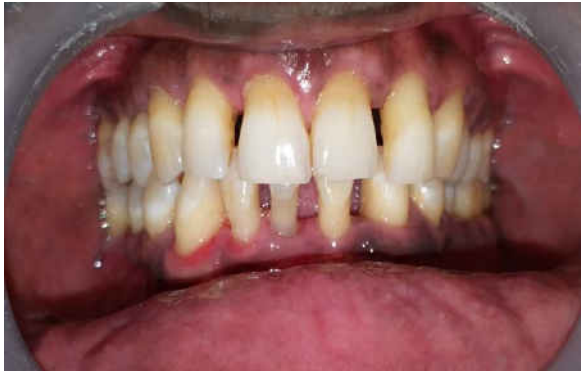DATE: 12.05.2018

OP NO: 201805716104

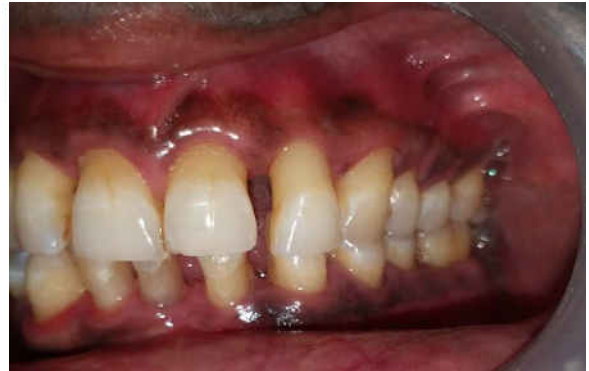AGE/SEX: 47/M

PROCEDURE: Mandibular arch splinting done in relation to 31,32,33,42,43 with fixed intracoronal composite wire

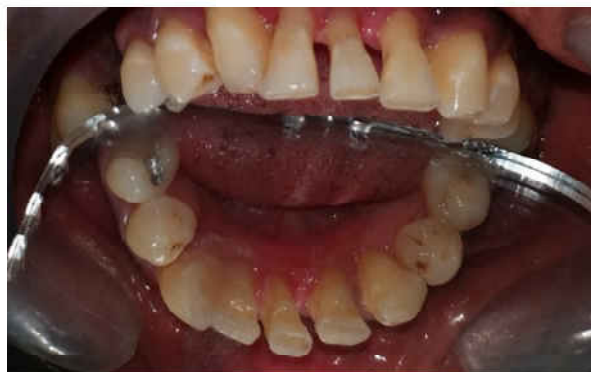PRE OPERATIVE PHOTO



Frontal view

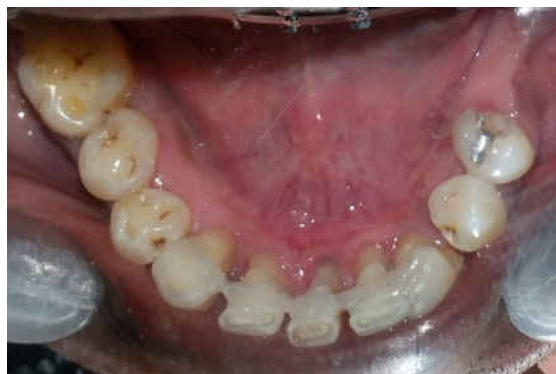

Left lateral view



Lower occlusal view

OPERATIVE PHOTO



Splinting done in relation to 31,32,33,42,43

CASE-6

DEMOGRAPHIC DATA

PATIENT NAME: Mrs. Munniyammal

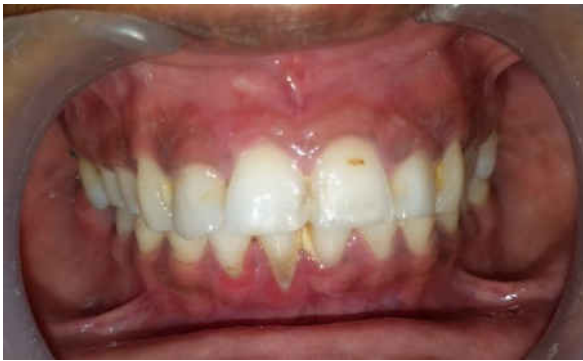DATE: 24.08. 2018

OP NO: 201808040138

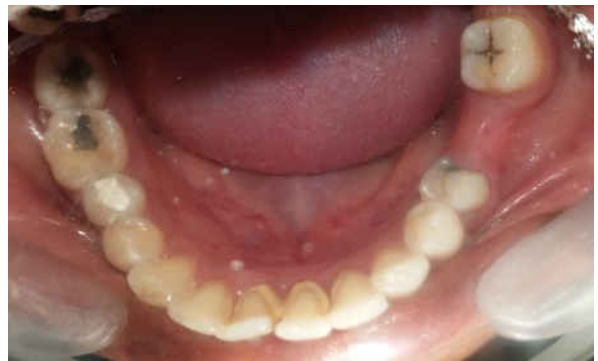AGE/SEX: 42/F

PROCEDURE: Mandibular arch splinting done in relation to 31,32,33,41,42,43
with fixed intracoronal composite wire

PRE OPERATIVE PHOTO

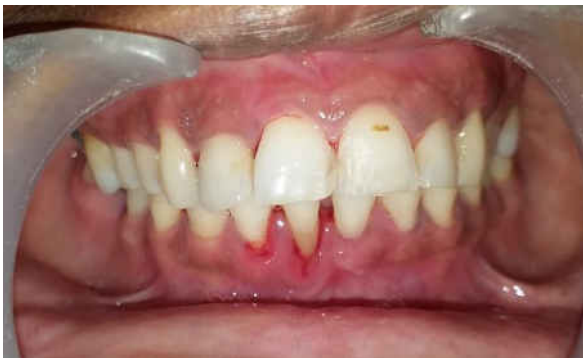

Frontal view

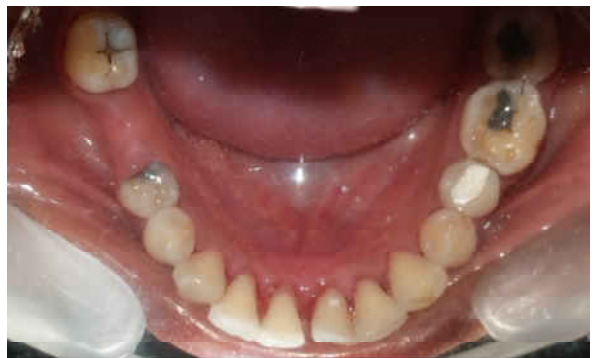

Lower occlusal view

POST- SCALING PHOTO

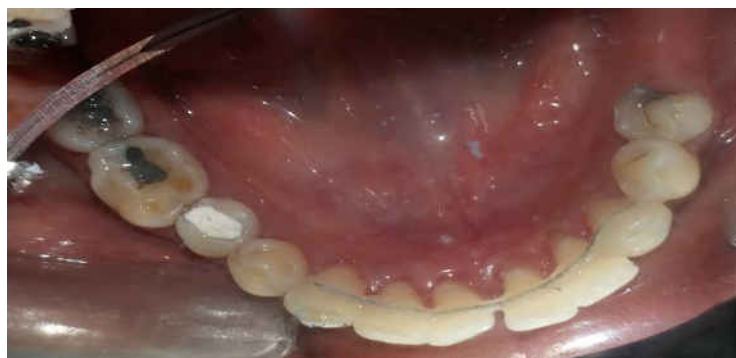

Frontal view



Lower occlusal view

OPERATIVE PHOTO



Splinting done in relation to 31,32,33,41,42,43

SPLINTTING

DEMOGRAPHIC DATA

PATIENT NAME: Mrs. Srivalli

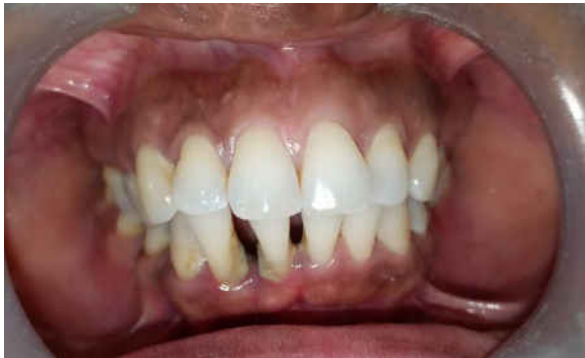DATE: 31.08. 2018

OP NO: 201808240060

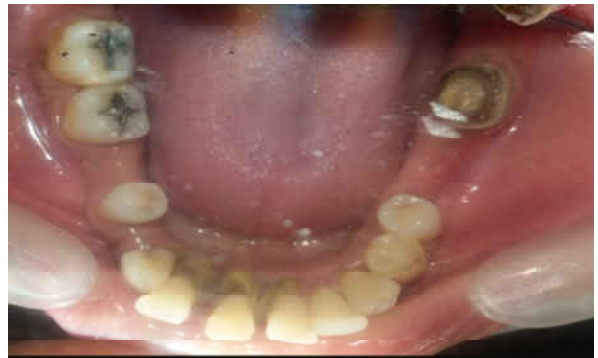AGE/SEX: 43/F

PROCEDURE: Mandibular arch splinting done in relation to 31,32,33,41,42,43 with fixed intracoronal composite wire

PRE OPERATIVE PHOTO

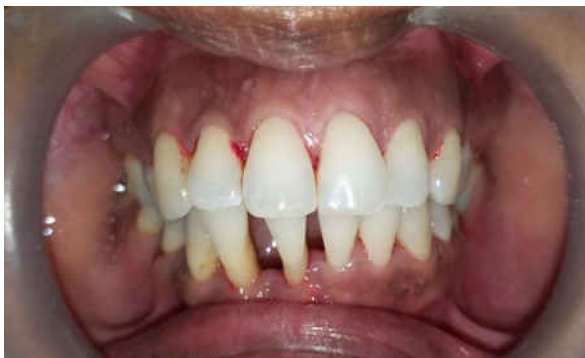

Frontal view

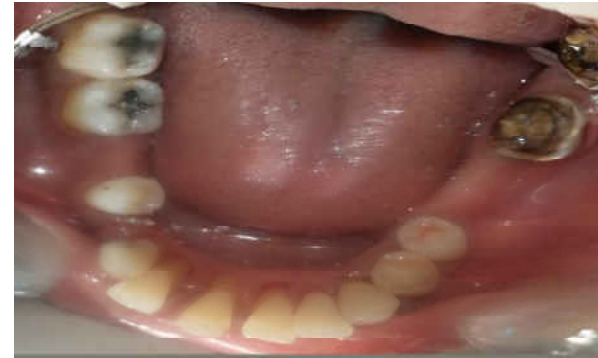

Lower occlusal view

POST- SCALING PHOTO

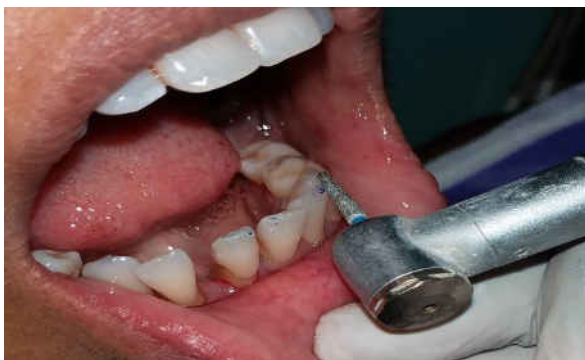

Frontal view

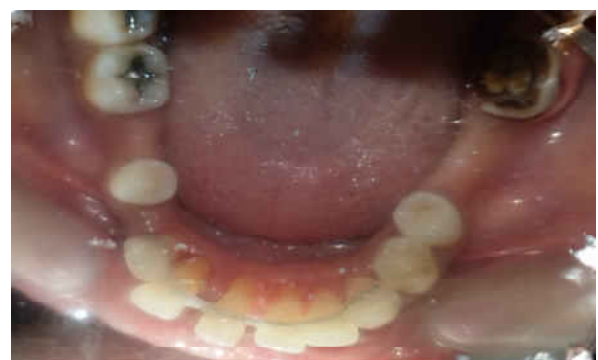

Lower occlusal view

OPERATIVE PHOTO



Coronoplasty done in relation to 32



Splinting done in relation to 31,32,33,41,42,43

SPLINTTING

DEMOGRAPHIC DATA

PATIENT NAME: Mr. Sutheharan

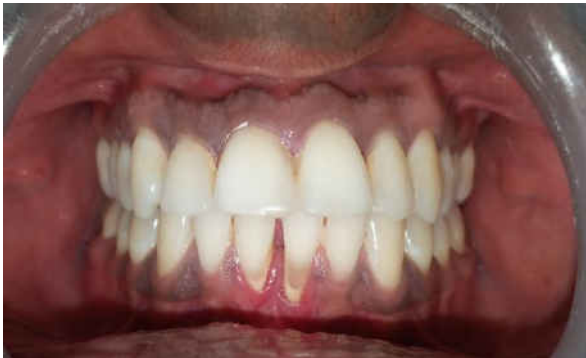DATE: 7.09. 2018

OP NO: 201712200031

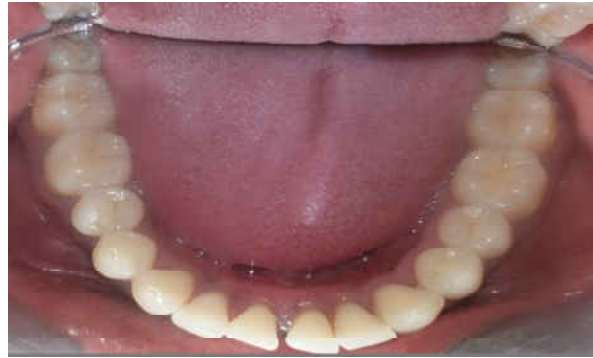AGE/SEX: 37/M

PROCEDURE: Mandibular arch splinting done in relation to 31,32,33,41,42,43
with fixed intracoronal composite wire

PRE OPERATIVE PHOTO

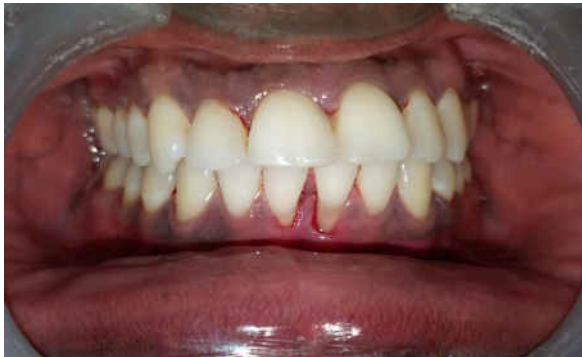

Frontal view

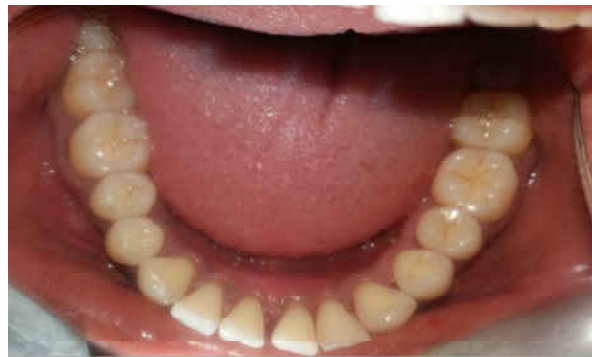

Lower occlusal view

POST- SCALING PHOTO

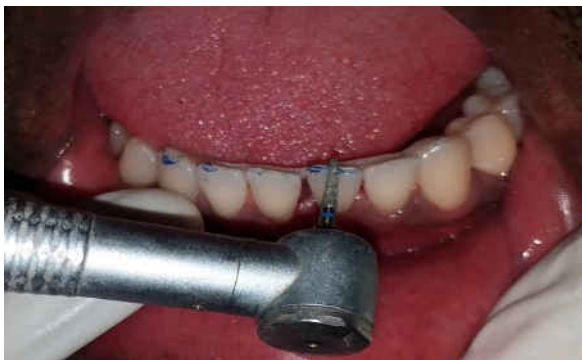

Frontal view

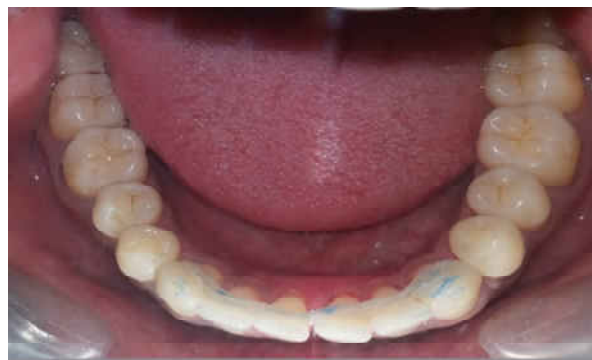

Lower occlusal view

OPERATIVE PHOTO



Coronoplasty done in relation to 31



Splinting done in relation to 31,32,33,41,42,43

SPLINTTING

DEMOGRAPHIC DATA

PATIENT NAME: Mrs. Manjula Rani

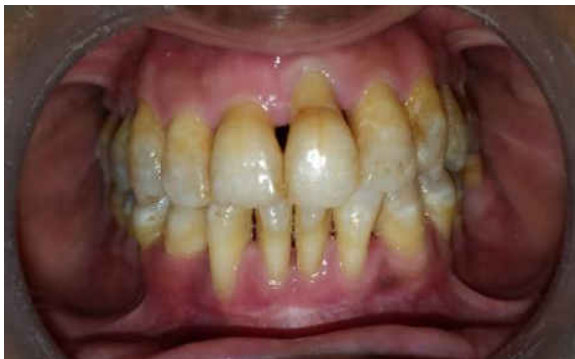DATE: 20.09. 2018

OP NO: 201809180078

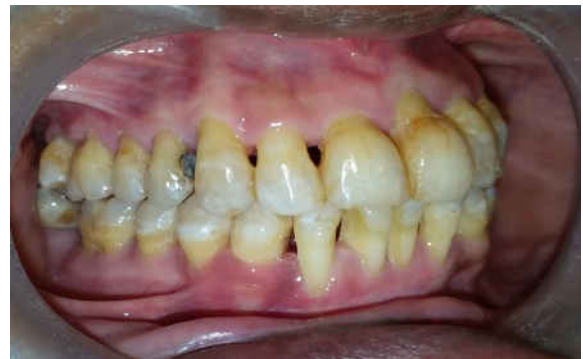AGE/SEX: 49/F

PROCEDURE: Mandibular arch splinting done in relation to 31,32,33,41,42,43 with fixed intracoronal wire and composite

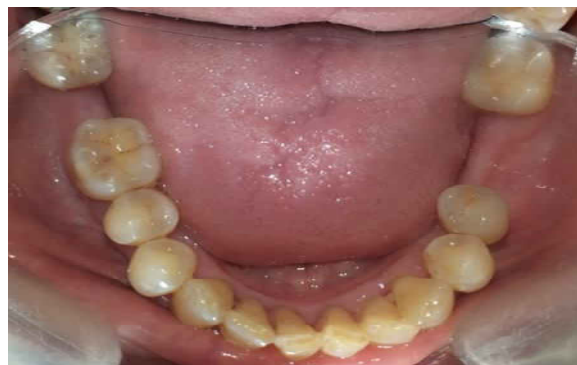PRE OPERATIVE PHOTO



Frontal view

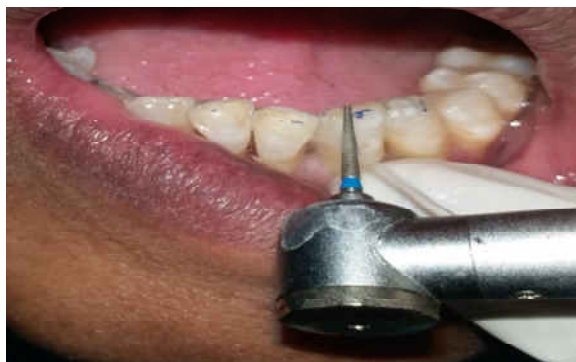

Right lateral view

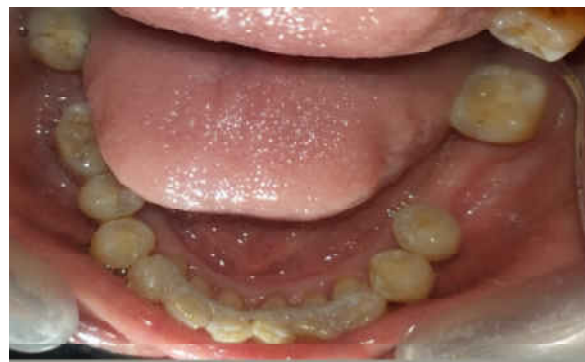

Lower occlusal view

OPERATIVE PHOTO



Coronoplasty done in relation to 32



Splinting done in relation to 31,32,33,41,42,43

SPLINTTING

DEMOGRAPHIC DATA

PATIENT NAME: Mrs. Revathy Sampath

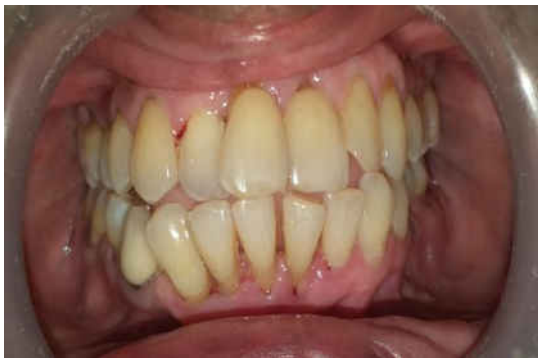DATE: 4.03. 2019

OP NO: 20190206012

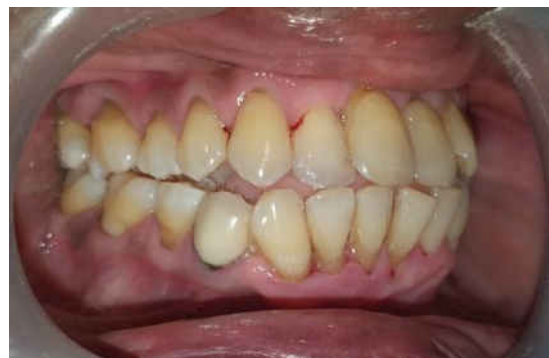AGE/SEX: 49/F

PROCEDURE: Mandibular arch splinting done in relation to 31,32,33,41,42,43 with fixed intracoronal wire and composite

PRE OPERATIVE PHOTO

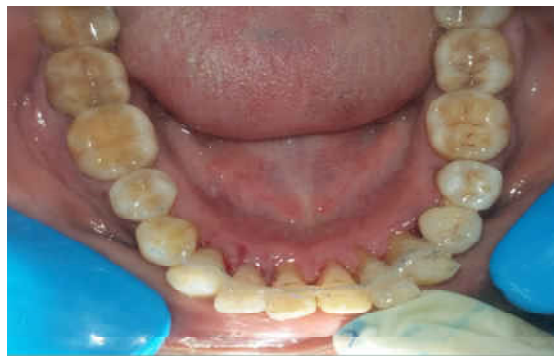

Frontal view



Right lateral view

OPERATIVE PHOTO



Splinting done in relation to 31,32,33,41,42,43

SPLINTTING

DEMOGRAPHIC DATA

PATIENT NAME: Mr. Sanadha Kumar

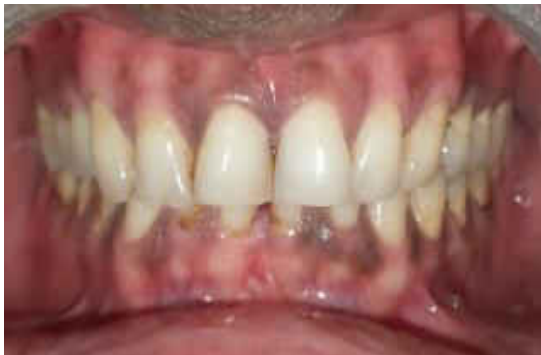DATE: 13.03. 2019

OP NO: 201809180078

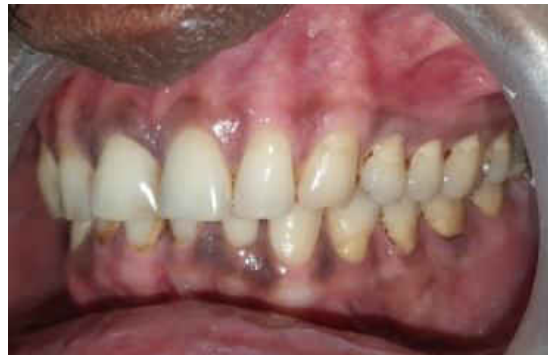AGE/SEX: 40/M

PROCEDURE: Cap splinting done in Mandibular arch

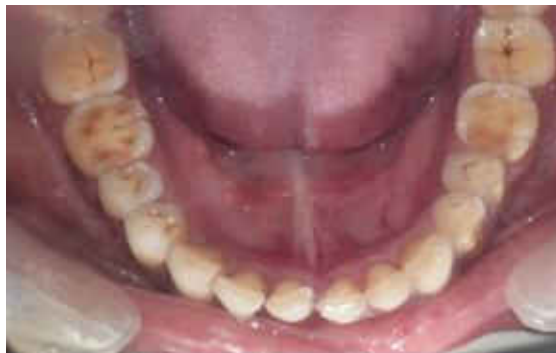PRE OPERATIVE PHOTO



Frontal view

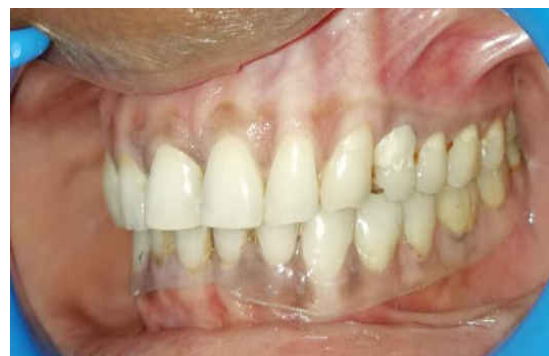
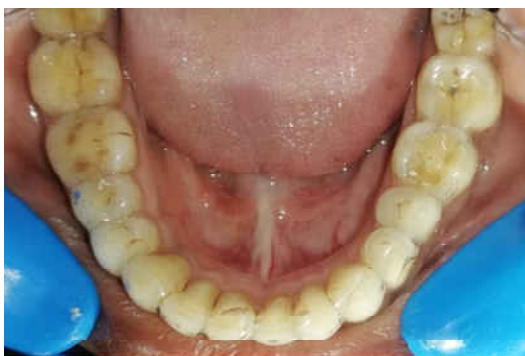
Right lateral view



Lower occlusal view

OPERATIVE PHOTO



Cap splinting done in relation to lower arch

SPLINTING

DEMOGRAPHIC DATA

PATIENT NAME :Mr.Sivagnanam

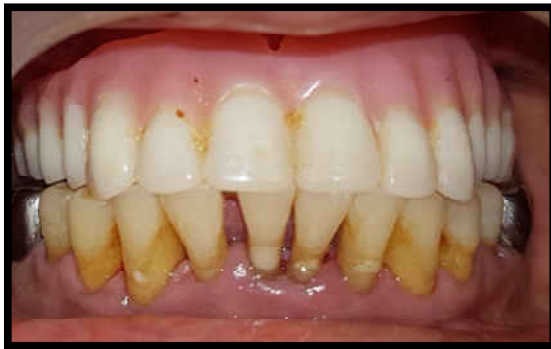DATE: 11.1.2019

OP NO: 201812180149

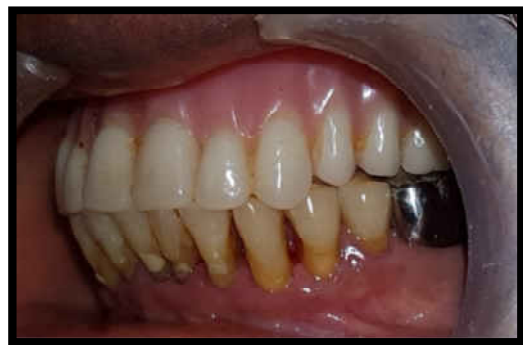AGE/SEX: 62/M

PROCEDURE: Coronoplasty 41 & Splinting done in relation to
31,32,33,41,42,43- composite splint

PRE OPERATIVE PHOTO – 11.1.19

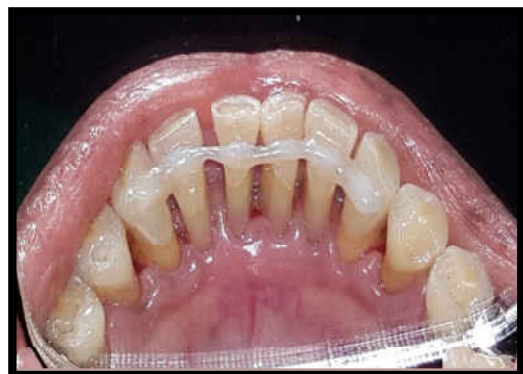
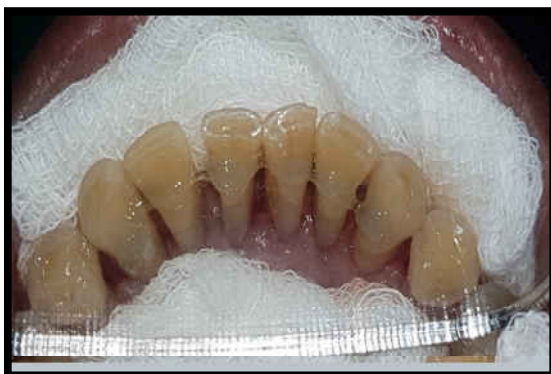
Frontal view



Left lateral view

SPLINTING



Splinting 11,12,13,21,22,23

SPLINTING

DEMOGRAPHIC DATA

PATIENT NAME :Mr.Ravi Kumar

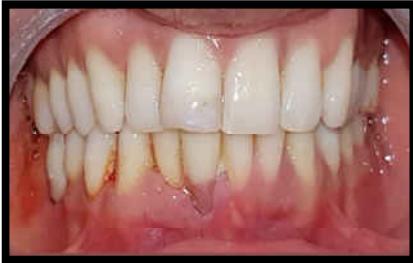DATE: 1.1.2019

OP NO: 201712270018

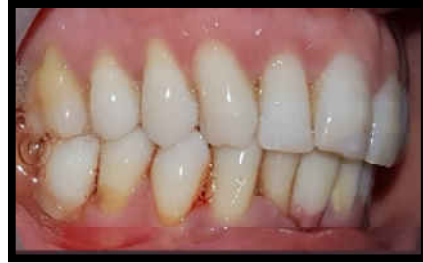AGE/SEX: 43/M

PROCEDURE: Coronoplasty 42 & Splinting done in relation to
42,43- composite wire splint

PRE OPERATIVE PHOTO – 11.1.19

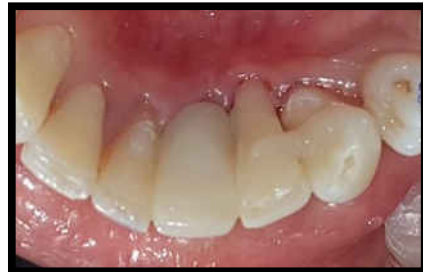
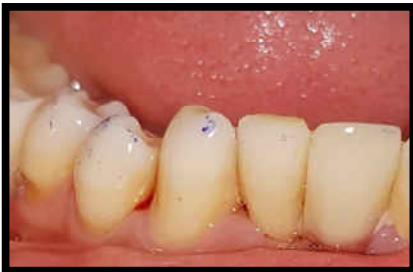
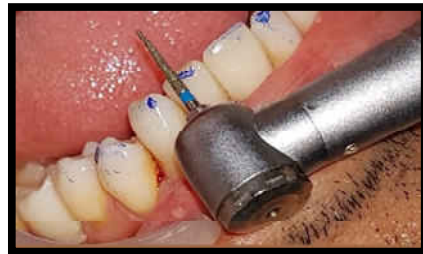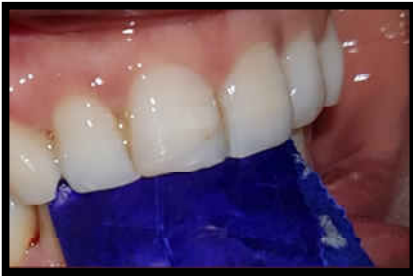Frontal view



Right lateral view

SPLINTING



Coronoplasty 42 & Splinting 42,43

SPLINTING

DEMOGRAPHIC DATA

PATIENT NAME :Mr. Sanjay Kumar

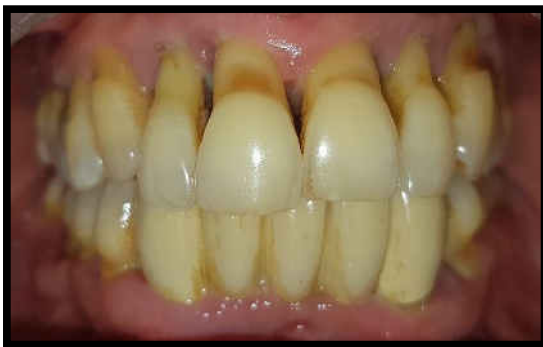DATE: 2.10.18

OP NO: 201808200166

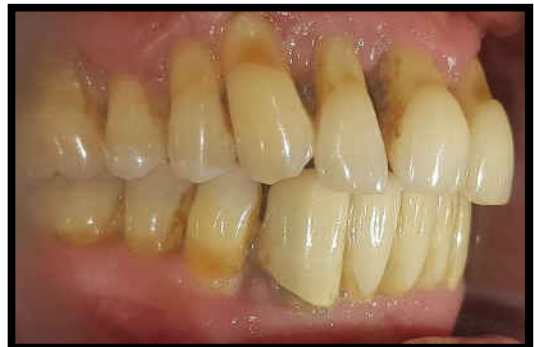AGE/SEX: 40/M

PROCEDURE: Splinting done in relation to 45,46,47 composite
wire splint

PRE OPERATIVE PHOTO – 23.8.18

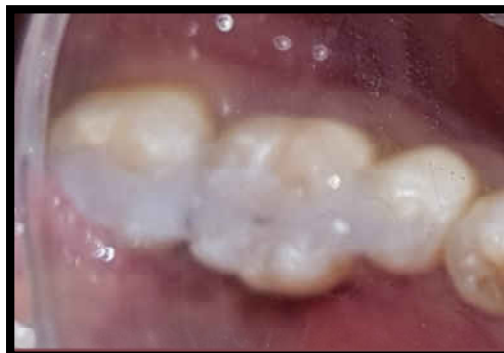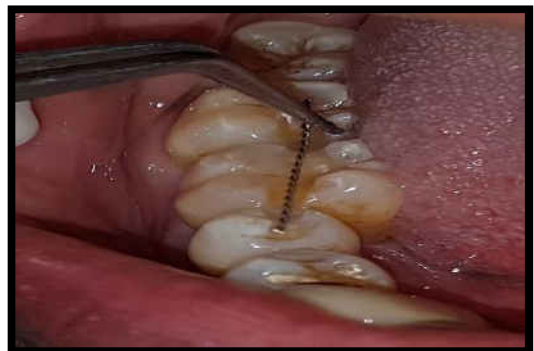

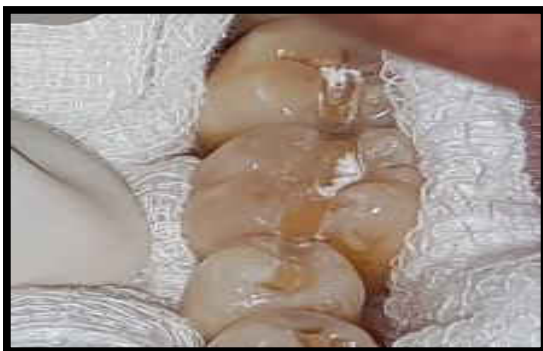
Frontal view



Left lateral view

Periodontal occlusal splint



Splinting 45,46,47

SPLINTING

DEMOGRAPHIC DATA

PATIENT NAME :Mr. Sanjay Kumar

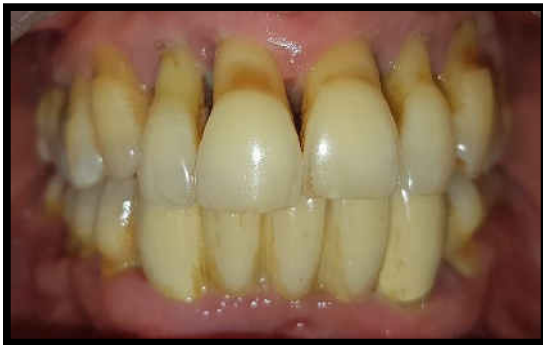DATE: 18.9.18

OP NO: 201808200166

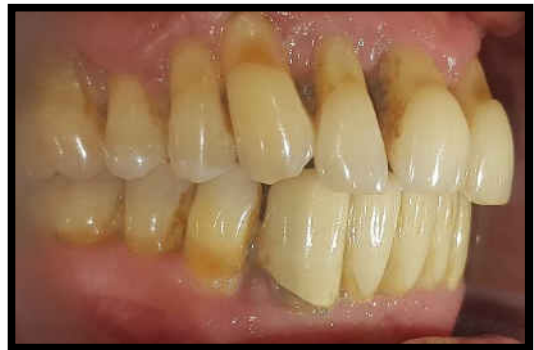AGE/SEX: 40/M

PROCEDURE: Splinting done in relation to 13,12,11,21,22,23- composite wire splint

PRE OPERATIVE PHOTO – 23.8.18

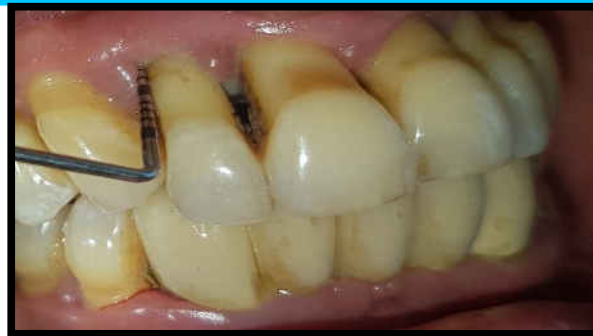

Frontal view

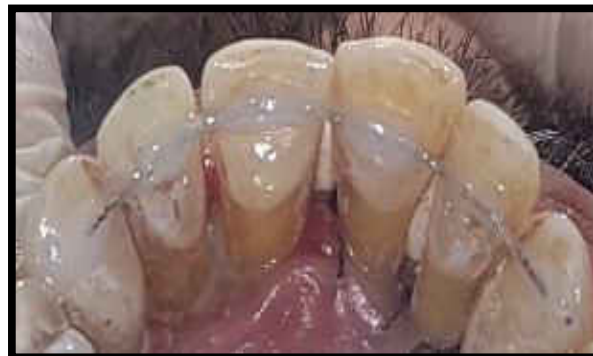

Left lateral view

POST SCALING



SPLINTING 18.8.18



Splinting 13,12,11,21,22,23

SPLINTING

DEMOGRAPHIC DATA

PATIENT NAME :Mr. Siva

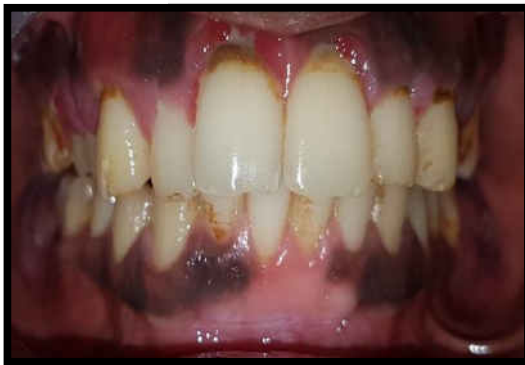DATE: 28.2.18

OP NO: 201802260096

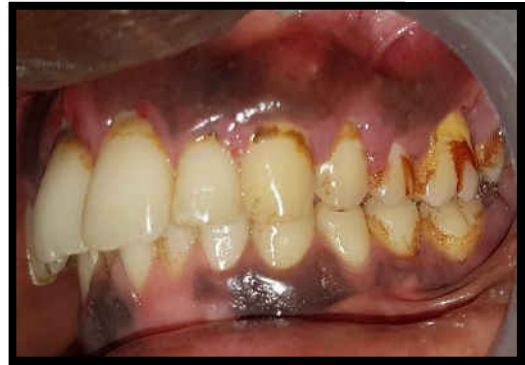AGE/SEX: 36/M

PROCEDURE: Splinting done in relation to 11,12,13,21,22,23- composite wire splint

PRE OPERATIVE PHOTO – 28.2.18

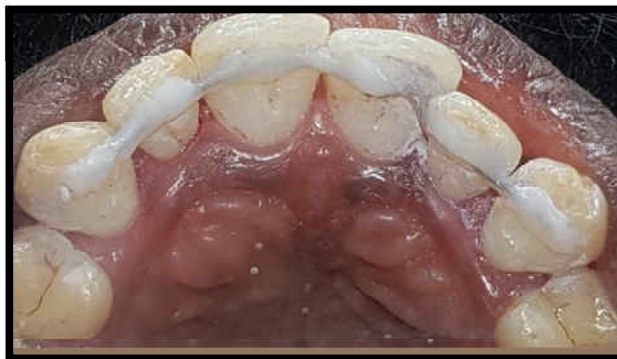

Frontal view



Left lateral view

SPLINTING



Splinting 11,12,13,21,22,23

SPLINTING

DEMOGRAPHIC DATA

PATIENT NAME :Mr.Sivagnanam

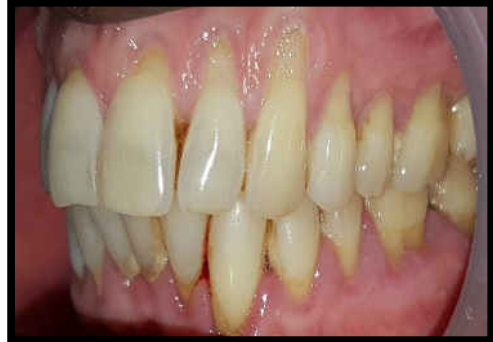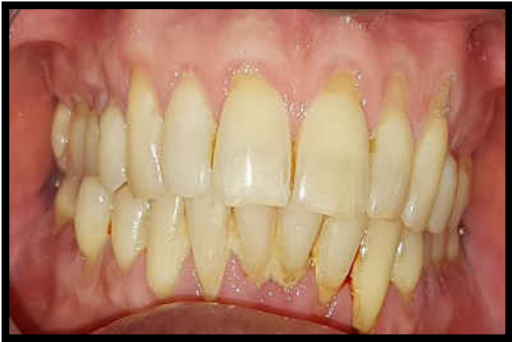DATE: 11.1.2019

OP NO: 201812180149

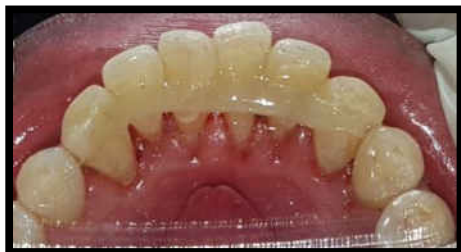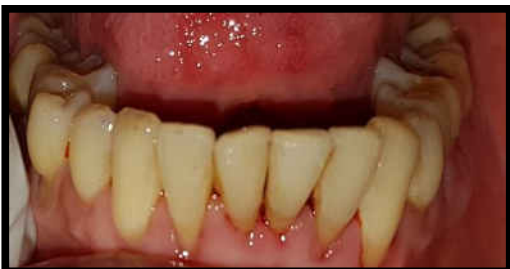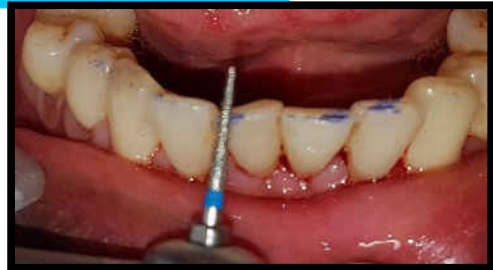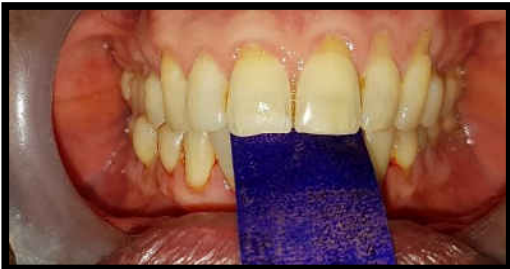AGE/SEX: 62/M

PROCEDURE: Coronoplasty 41 & Splinting done in relation to
31,32,33,41,42,43- composite fibre splint

PRE OPERATIVE PHOTO – 11.1.19



SPLINTING



Coronoplasty 41 & Splinting 11,12,13,21,22,23

SPLINTING

DEMOGRAPHIC DATA

PATIENT NAME :Mr. Suresh Babu

DATE: 21.4.18

OP NO: 201804190124

AGE/SEX: 30/M

PROCEDURE: Splinting done in relation to 31,32,33,41,42,43- composite wire splint

PRE OPERATIVE PHOTO – 21.4.18

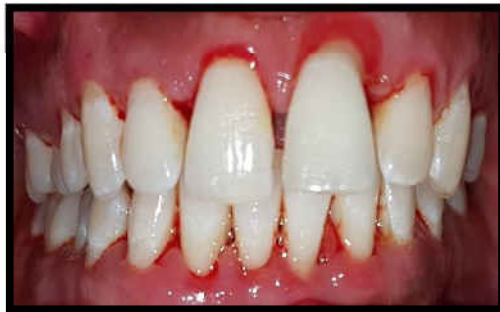

Frontal view

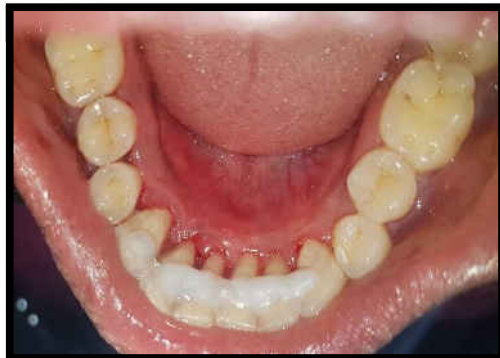

Left lateral view

POST SCALING



SPLINTING



Splinting 31,32,33,41,42,43

SPLINTING

DEMOGRAPHIC DATA

PATIENT NAME :Mr. Vignesh

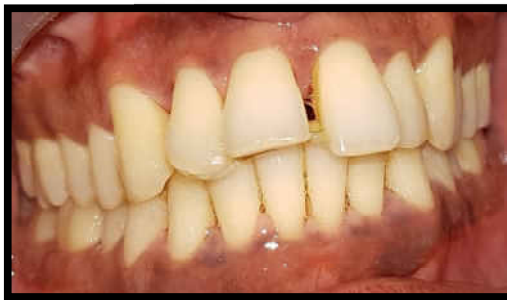DATE: 7.3.18

OP NO: 201802170165

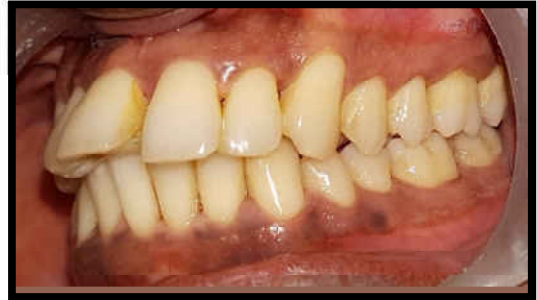AGE/SEX: 26/M

PROCEDURE: Splinting done in relation to 11,12,21,22, 31,32,33,41,42,43-
composite wire splint

PRE OPERATIVE PHOTO – 7.3.18

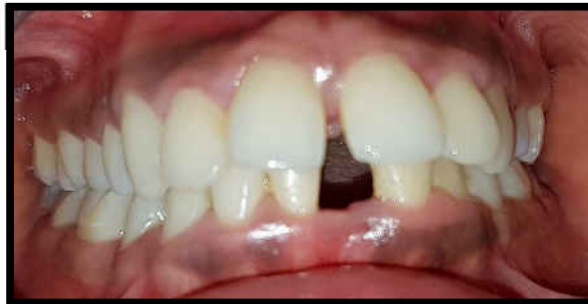

Frontal view

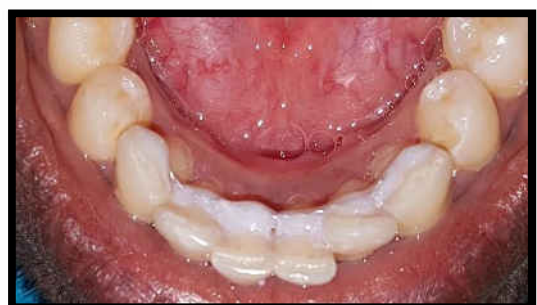
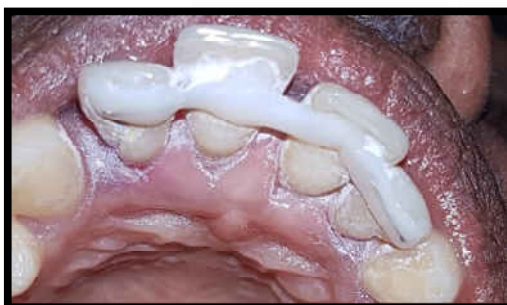
Left lateral view

POST SCALING



SPLINTING



Splinting 11,12,21,22,31,32,33,41,42,43

SPLINTING

DEMOGRAPHIC DATA

PATIENT NAME: MR. PADMINI

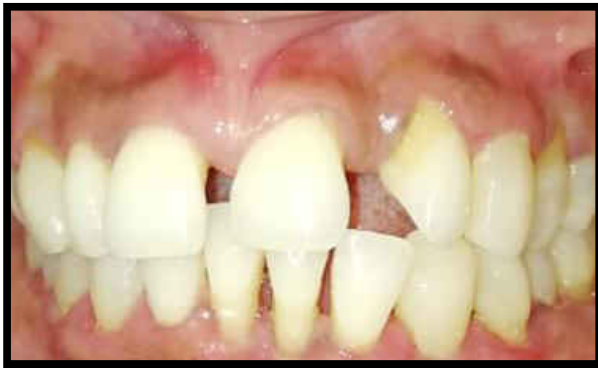DATE: 13.09. 2018

OP NO: 302241

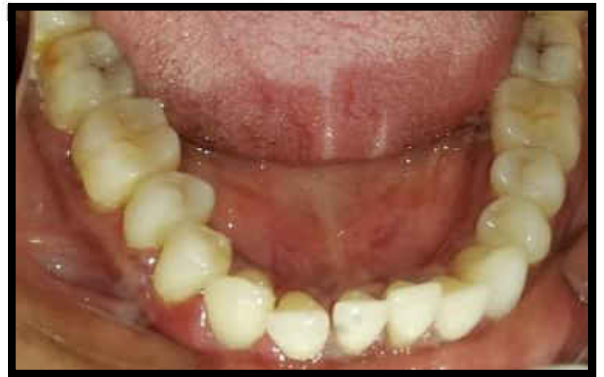AGE/SEX: 62/F

PROCEDURE: Splinting in relation to 31,32,33,41,42,43

PRE OPERATIVE PHOTOGRAPHS

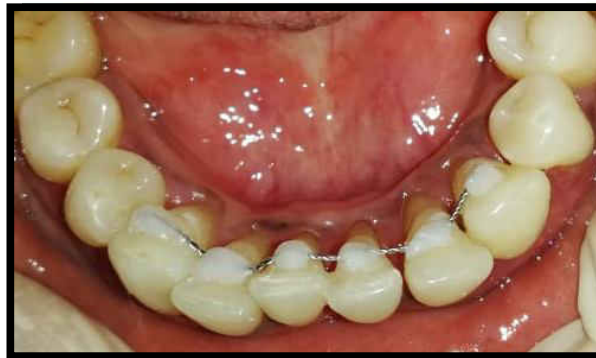

Frontal view



Occlusal view

OPERATIVE PHOTOGRAPHS



Splinting done in relation to 31, 32,33,41,42,43

CORONOPLASTY

Case-1

DEMOGRAPHIC DATA

PATIENT NAME : Mrs. Ponnu Siva

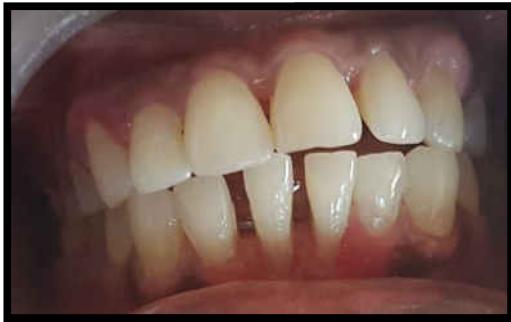DATE: 11.5.2018

OP NO: 201805080138

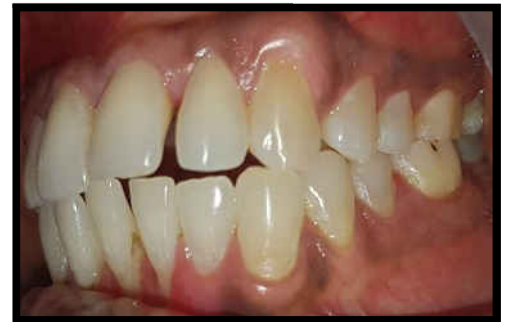AGE/SEX: 35/F

PROCEDURE: Coronoplasty 41

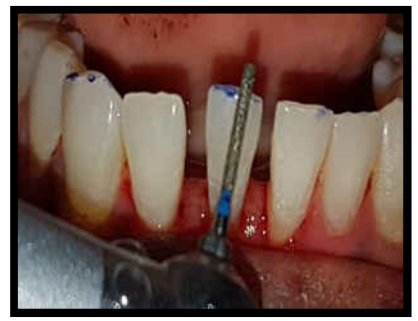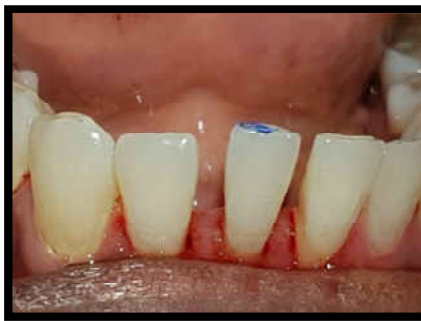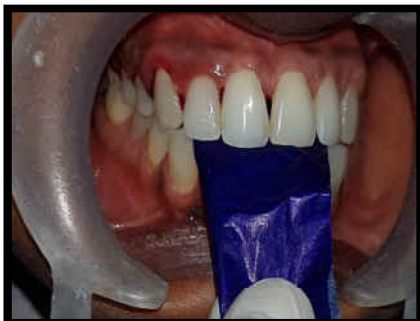PRE OPERATIVE PHOTO – 11.5.18



Frontal view



Left lateral view



Coronoplasty 41

Case-2

DEMOGRAPHIC DATA

PATIENT NAME :Mr.Ravi Kumar

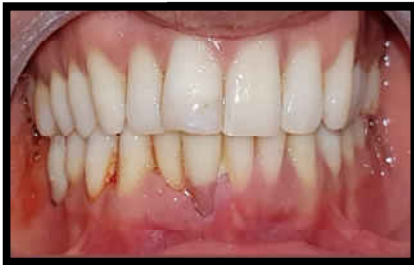DATE: 1.1.2019

OP NO: 201712270018

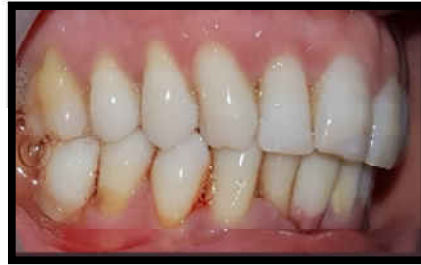AGE/SEX: 43/M

PROCEDURE: Coronoplasty 42

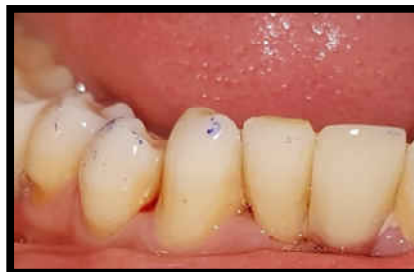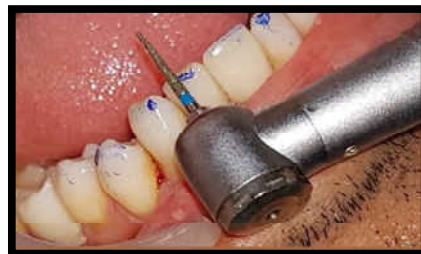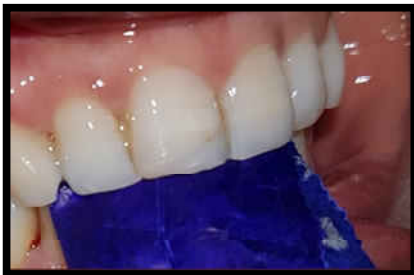PRE OPERATIVE PHOTO – 11.1.19



Frontal view



Right lateral view



Coronoplasty42

Case-3

DEMOGRAPHIC DATA

PATIENT NAME :Mr.Sivagnanam

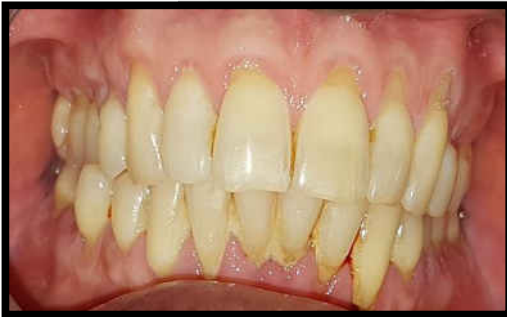DATE: 11.1.2019

OP NO: 201812180149

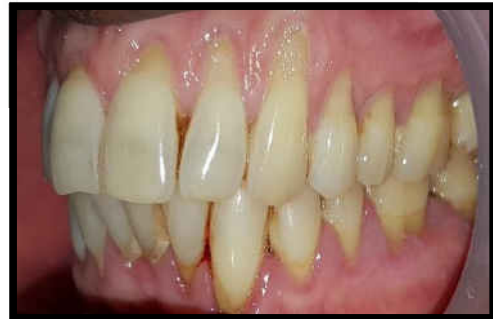AGE/SEX: 62/M

PROCEDURE: Coronoplasty 41

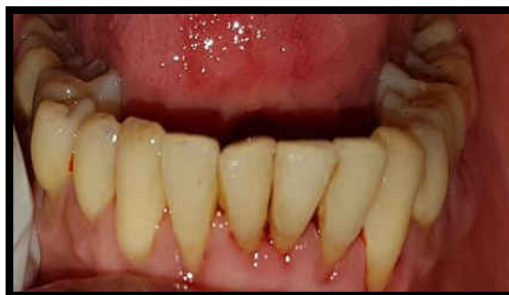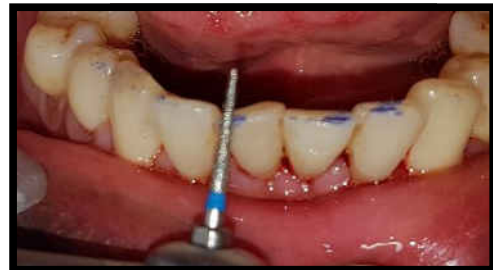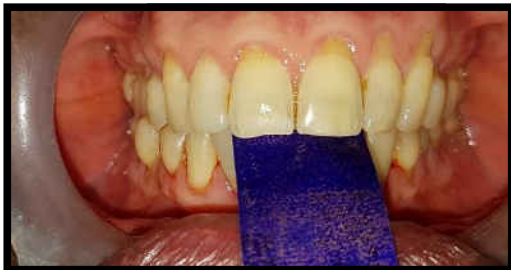PRE OPERATIVE PHOTO – 11.1.19



Frontal view



Left lateral view



Coronoplasty 41

Case-4

DEMOGRAPHIC DATA

PATIENT NAME: Mr. Elumalai

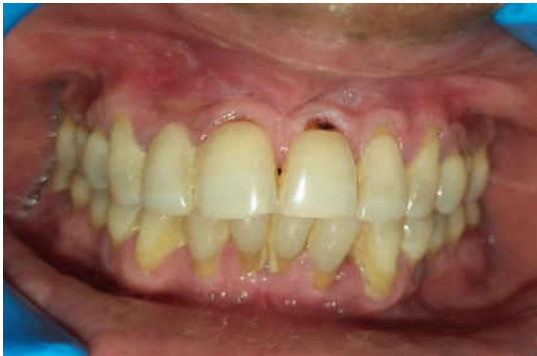DATE: 13.3.2019

OP NO: 201901300055

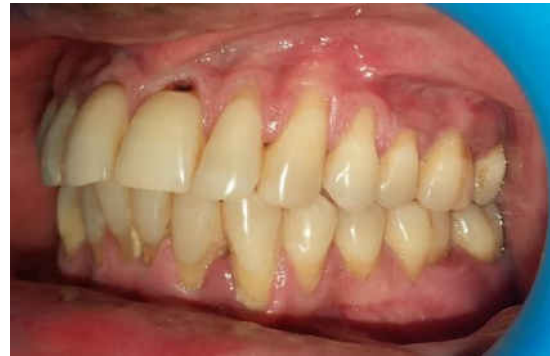AGE/SEX: 54/M

PROCEDURE: Coronoplasty done in relation to 31,32,41,42

PRE OPERATIVE PHOTO

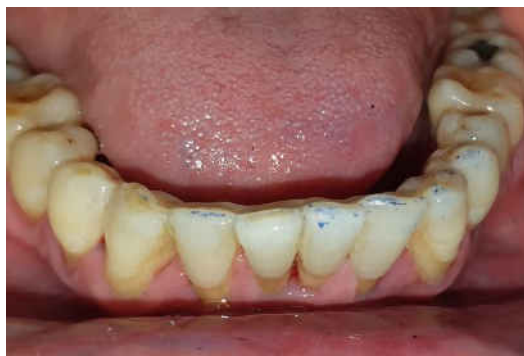
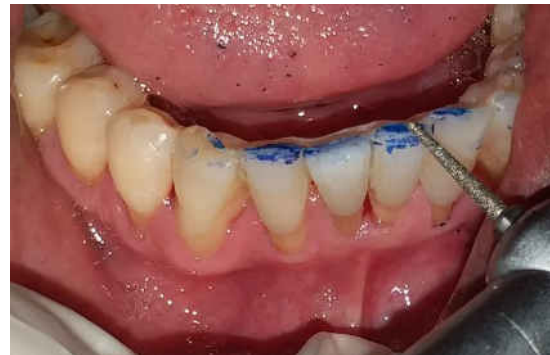
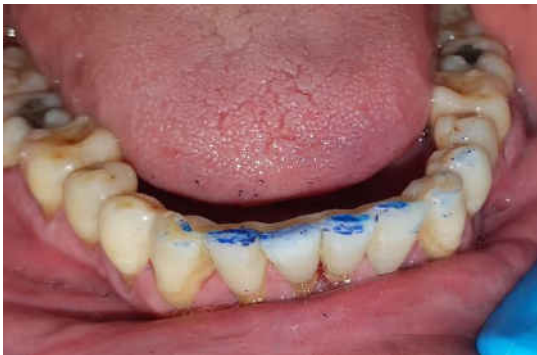Frontal view



Left lateral view

OPERATIVE PHOTO



Coronoplasty done in relation to 31,32,41,42

Case-5

DEMOGRAPHIC DATA

PATIENT NAME: Mrs. Manjula Rani

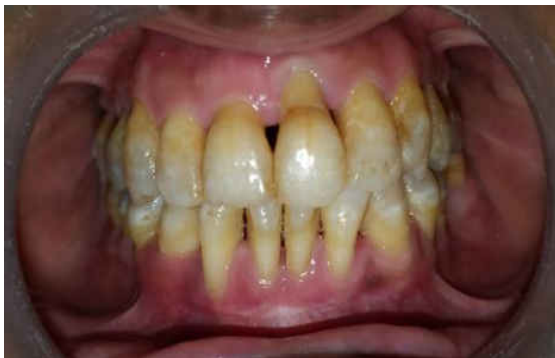DATE: 20.9.2018

OP NO: 201809180078

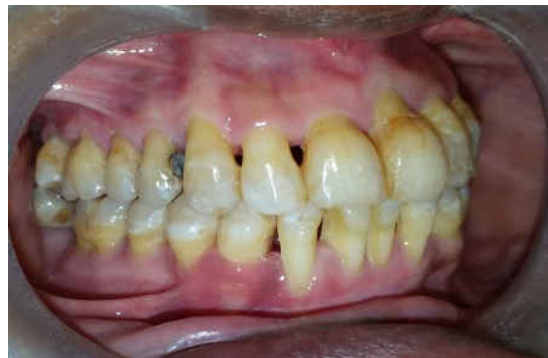AGE/SEX: 49/F

PROCEDURE: Coronoplasty done in relation to 31,32,41,42

PRE OPERATIVE PHOTO

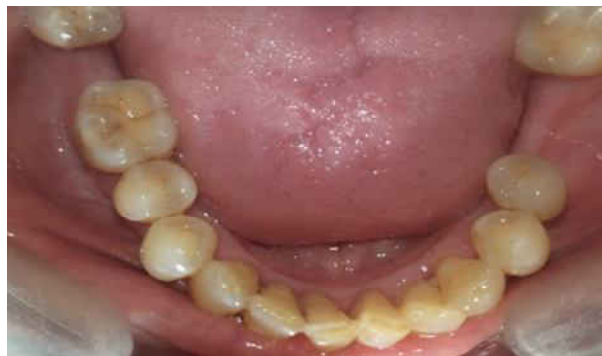
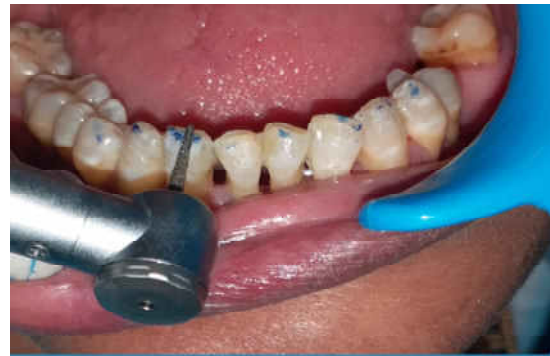
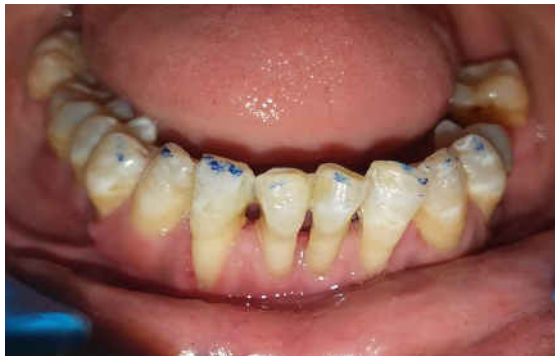Frontal view



Left lateral view

OPERATIVE PHOTO



Coronoplasty done in relation to 31,32,41,42

Case-6

DEMOGRAPHIC DATA

PATIENT NAME: Mr. Sanadha Kumar

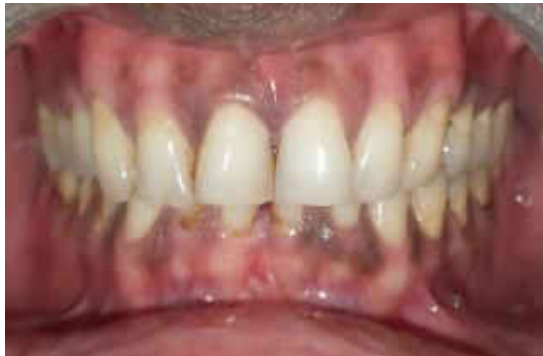DATE: 13.3.2019

OP NO: 20191070032

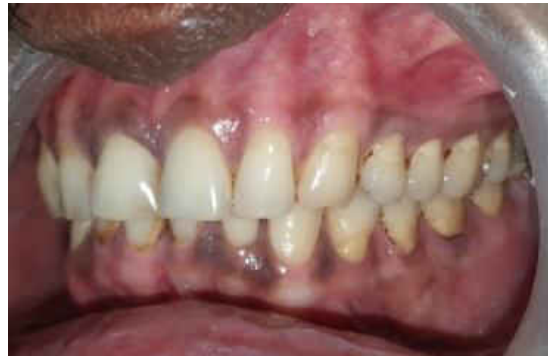AGE/SEX: 40/M

PROCEDURE: Coronoplasty done in relation to III and IV quadrant

PRE OPERATIVE PHOTO

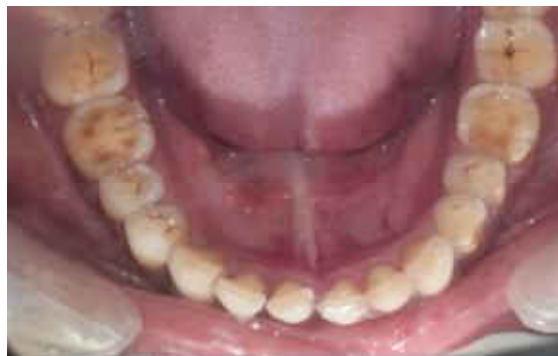
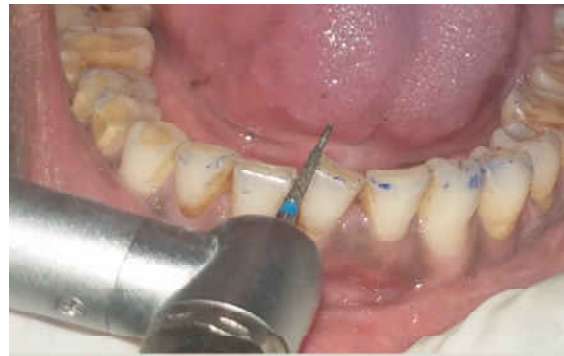
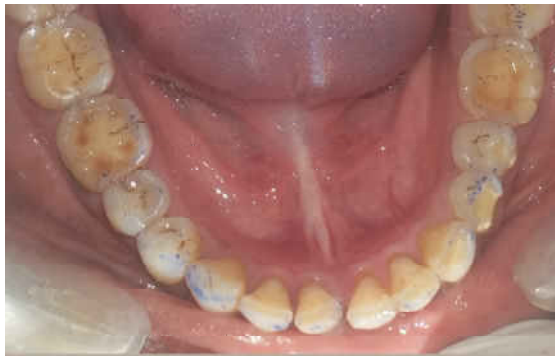Frontal view



Left lateral view

OPERATIVE PHOTO



Coronoplasty done in relation to lower arch

OPERCULECTOMY

Case-1

DEMOGRAPHIC DATA

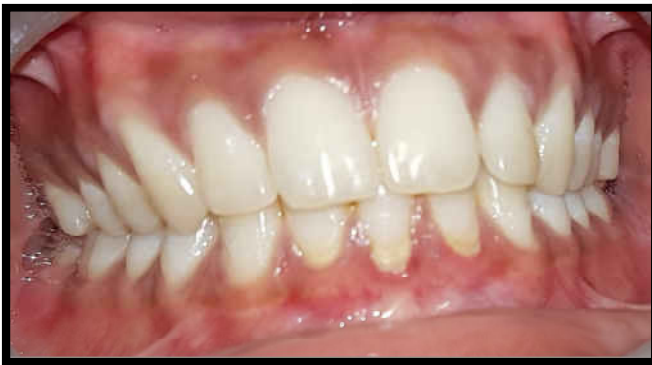PATIENT NAME : Mr .Santha Kumar **DATE:** 6/2/18

OP NO: 201710070012

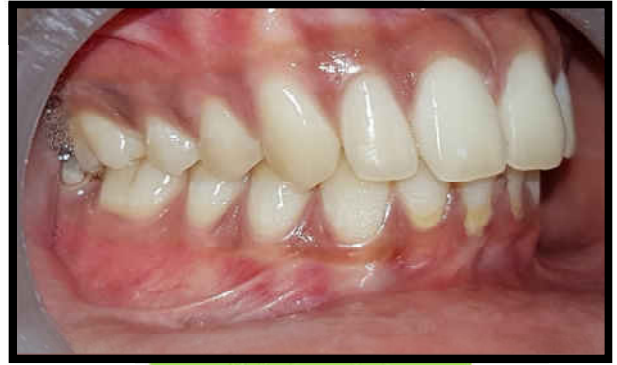AGE/SEX: 23M

PROCEDURE: Operculectomy in 48

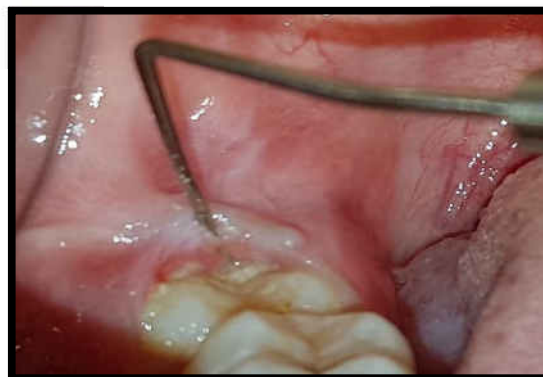
PRE OPERATIVE PHOTO – 6.2.18



Frontal view

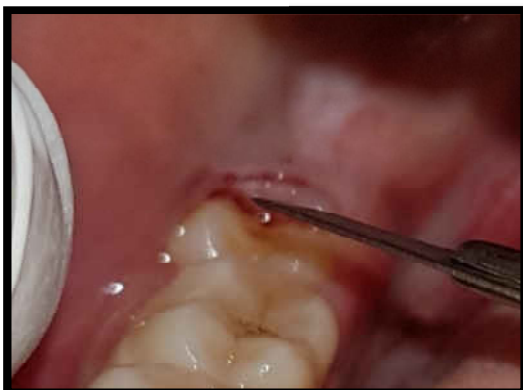

Right lateral view

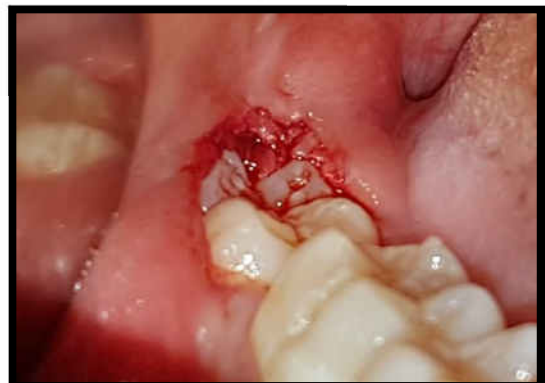


Pericoronal flap in 48

OPERATIVE PHOTO – 6.2.18

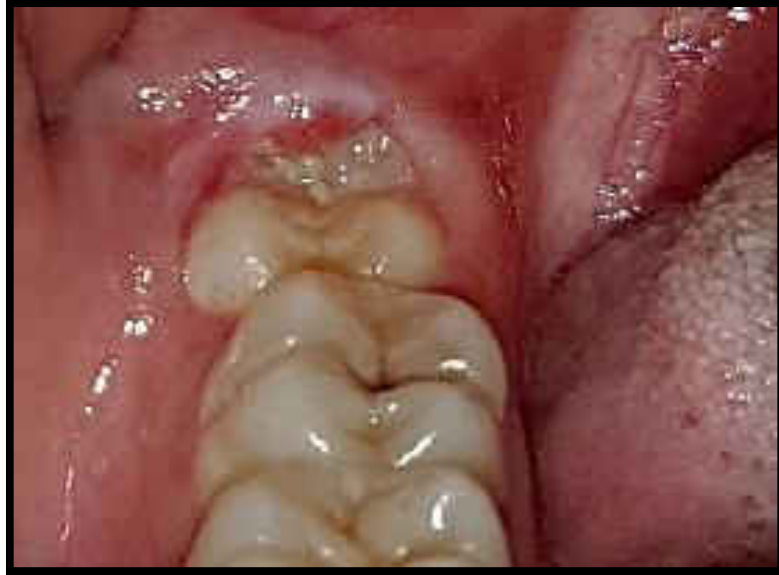

External bevel incision in 48



Post operative photo-48

1 MONTH POST OPERATIVE PHOTO



OCCLUSAL VIEW 48

Case-2

DEMOGRAPHIC DATA

PATIENT NAME : Ms Preethi Kumari

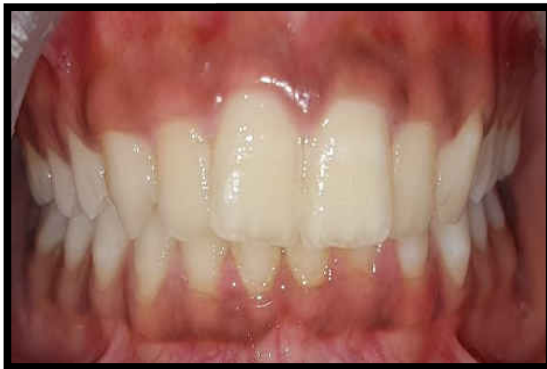DATE:6.6.18

OP NO: 201806060039

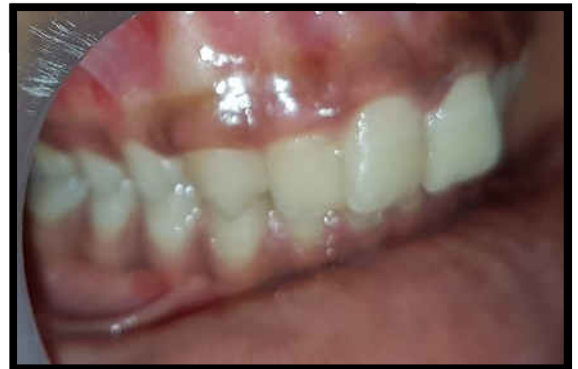AGE/SEX: 15/F

PROCEDURE: Operculectomy 18

PRE OPERATIVE PHOTO -6.6.18

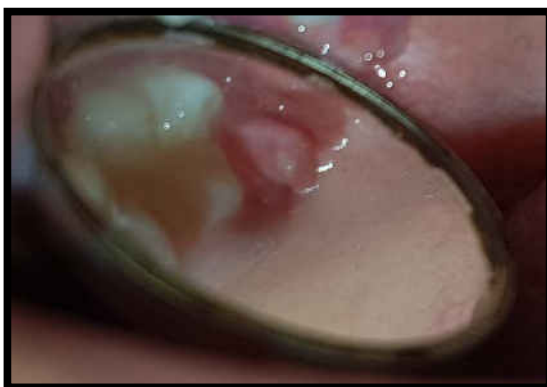

Frontal view

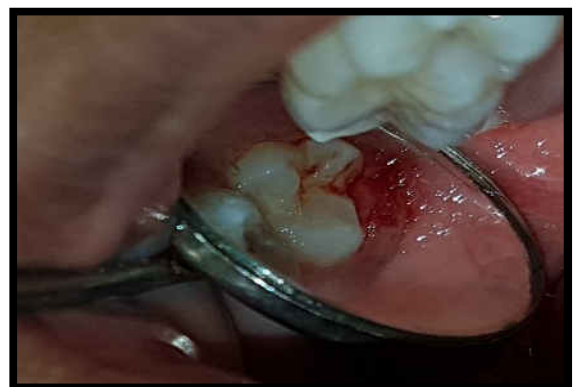

Right lateral view

OPERATIVE PHOTO-6.6.18

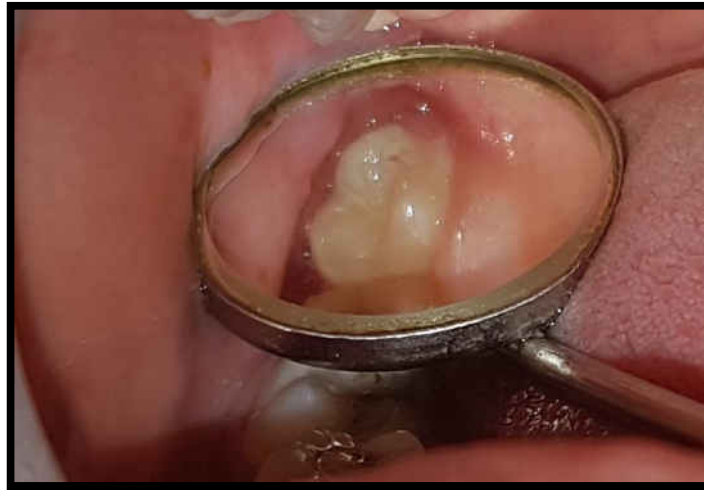

Pericoronal flap 18



Post Operculectomy- 18

1 MONTH POST –OP



18

Case-3

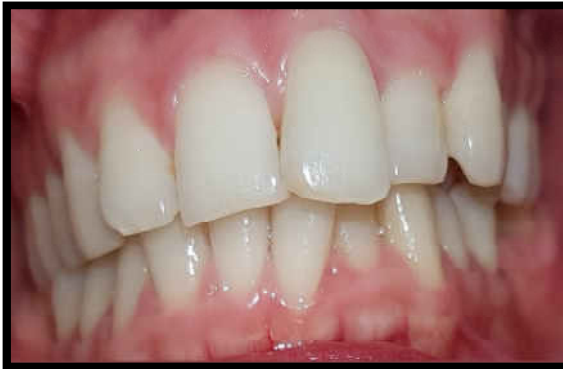DEMOGRAPHIC DATA

PATIENT NAME : Mr .Tamizharasan **DATE:** 20/4/18

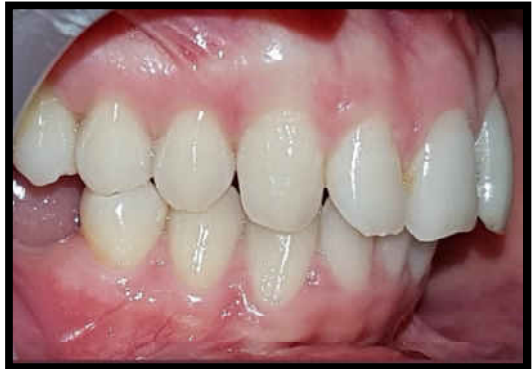OP NO: 2018041170180 **AGE/SEX:** 26/M

PROCEDURE: Operculectomy in 48

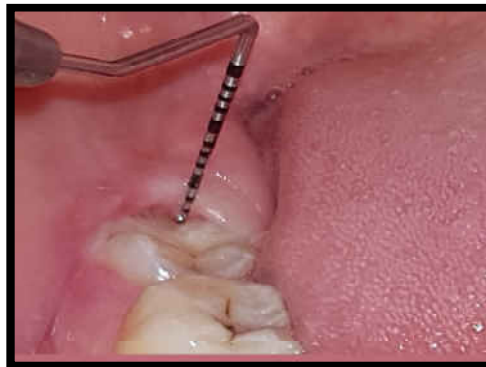PRE OPERATIVE PHOTO – 20.4.18



Frontal view

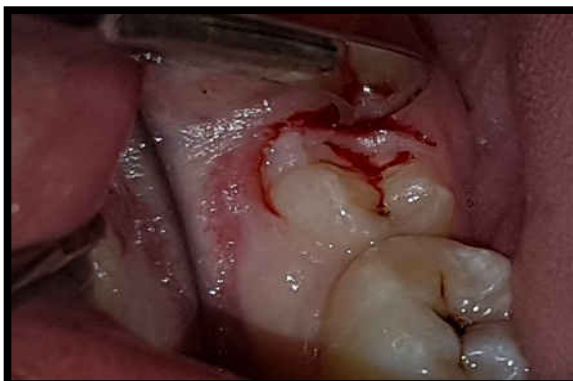


Right lateral view

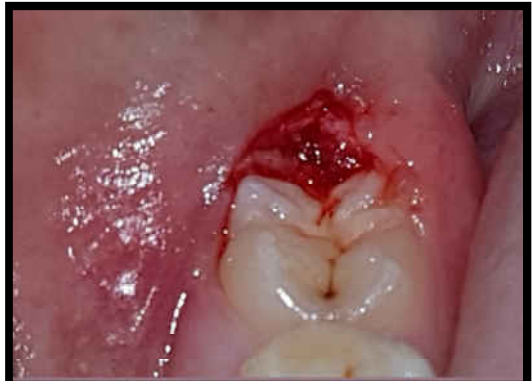


Pericoronal flap in 48

OPERATIVE PHOTO –23.4.18

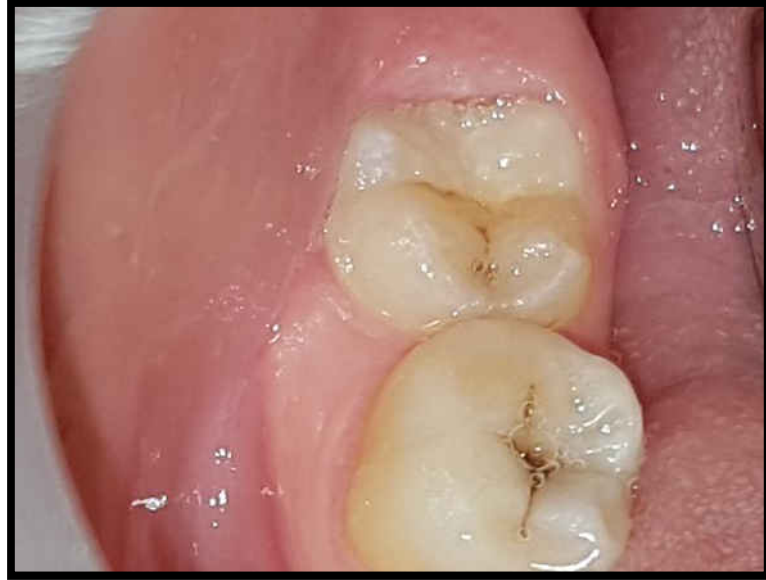

External bevel incision in 48



Post operative photo-48

**1 MONTH POST OPERATIVE PHOTO-
26.5.18**



OCCLUSAL VIEW 48

Case-4

DEMOGRAPHIC DATA

PATIENT NAME: Mr. Rakesh

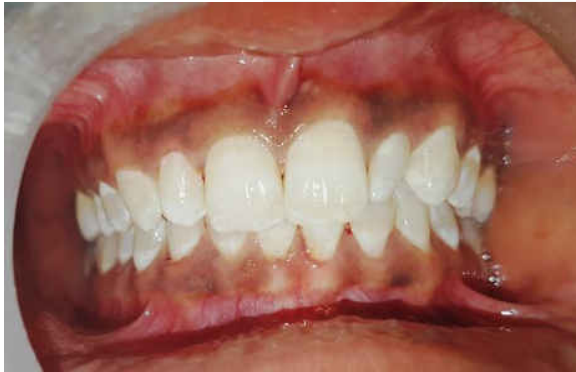DATE: 20.6.2018

OP NO: 201806180160

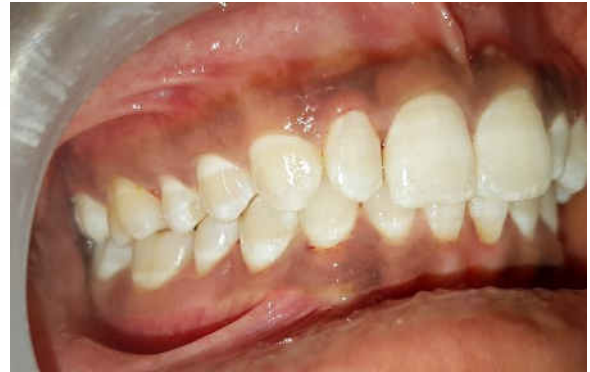AGE/SEX: 18/M

PROCEDURE: Operculectomy done in relation to 48

PRE OPERATIVE PHOTO

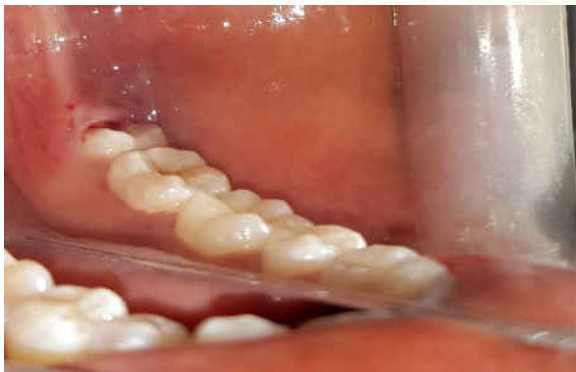

Frontal view

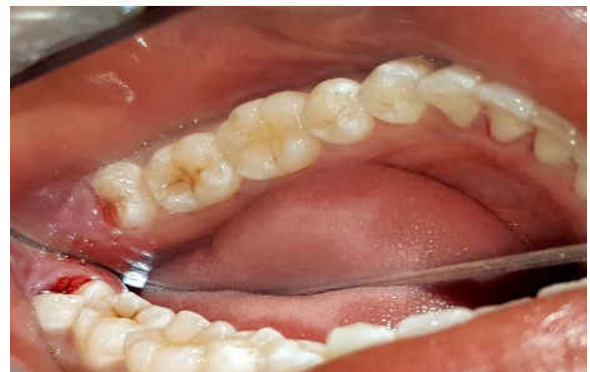

Right lateral view

PRE OPERATIVE PHOTO

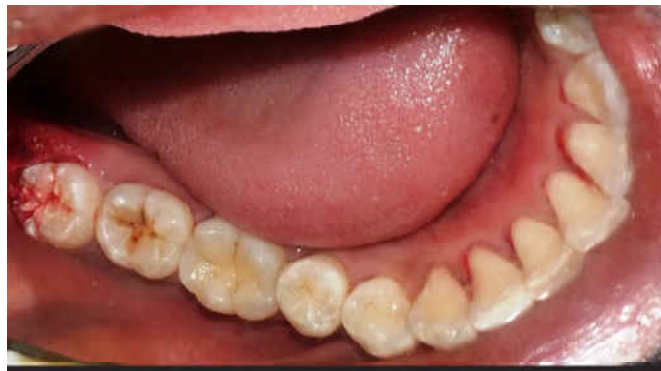

Lingual view



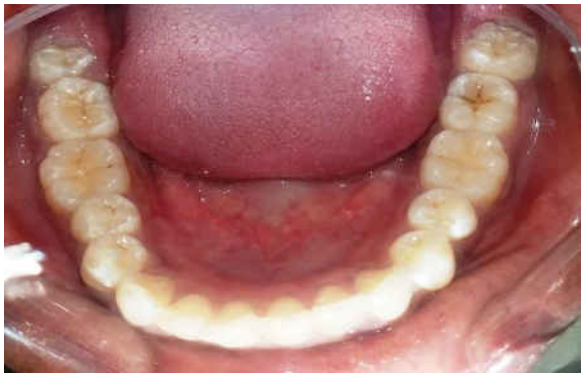Occlusal view

OPERATIVE PHOTO

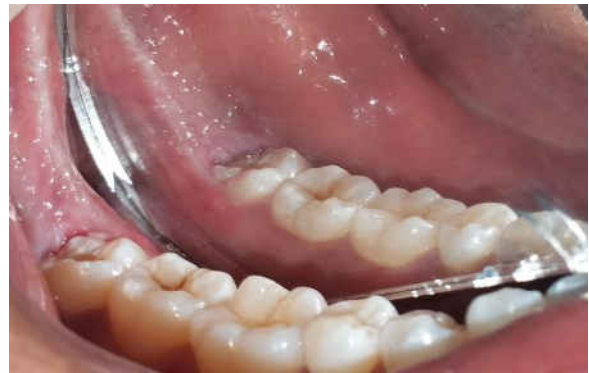

Operculectomy done in relation to 48

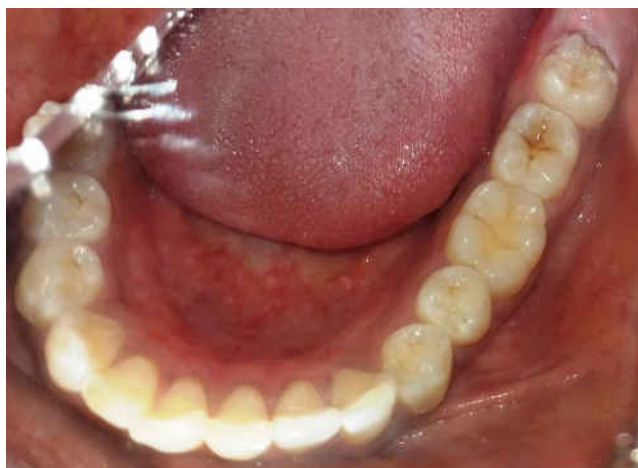POST OPERATIVE PHOTO



Occlusal view



Lingual view



Occlusal view

Case-5

DEMOGRAPHIC DATA

PATIENT NAME: Mr. Naresh

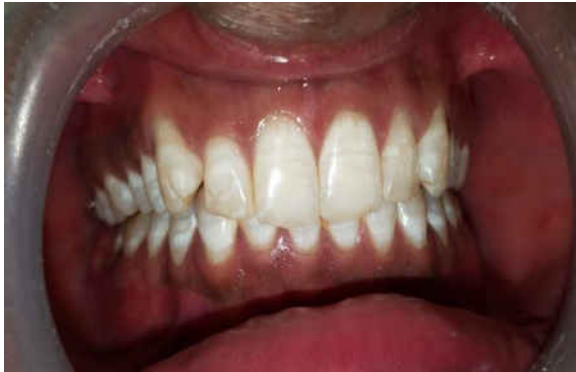DATE: 21.7.2018

OP NO: 2018072210022

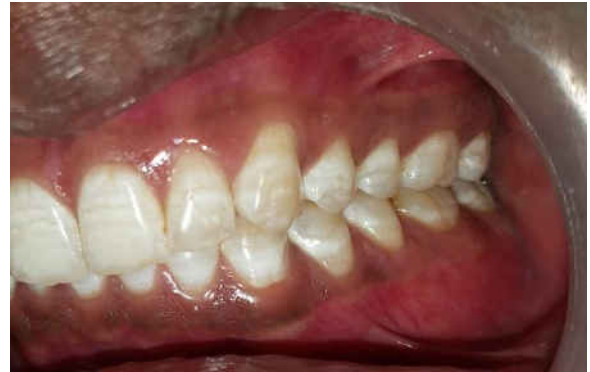AGE/SEX: 27/M

PROCEDURE: Operculectomy done in relation to 38

PRE OPERATIVE PHOTO

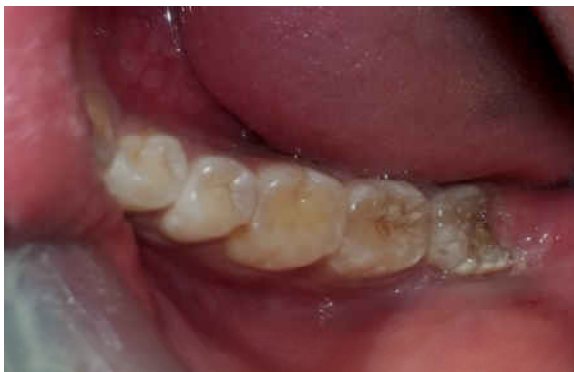

Frontal view

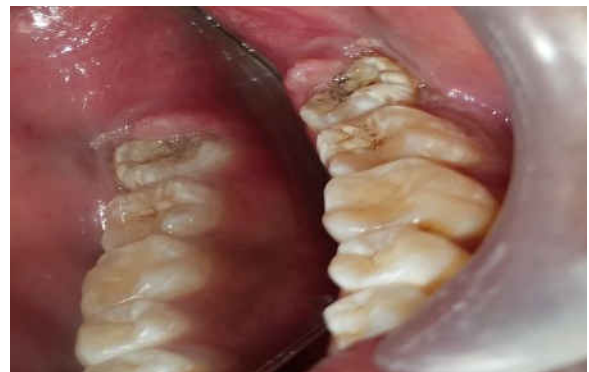

Left lateral view

PRE OPERATIVE PHOTO

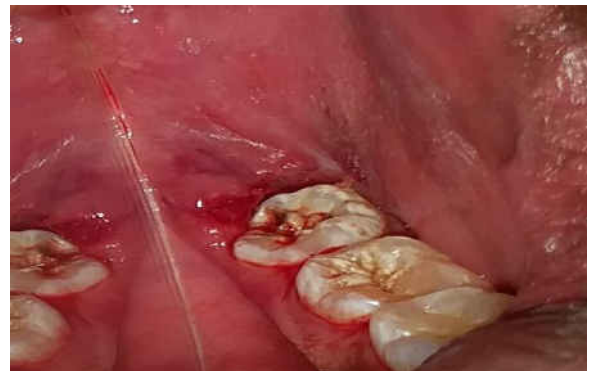
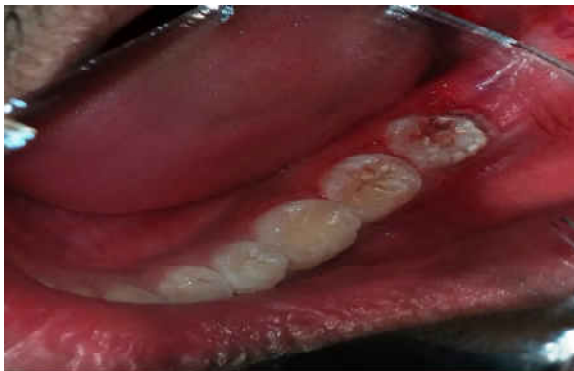
Occlusal view



Lingual view

OPERATIVE PHOTO



Operculectomy done in relation to 38

FRENECTOMY

Case-1

DEMOGRAPHIC DATA

PATIENT NAME: Miss. Poojitha

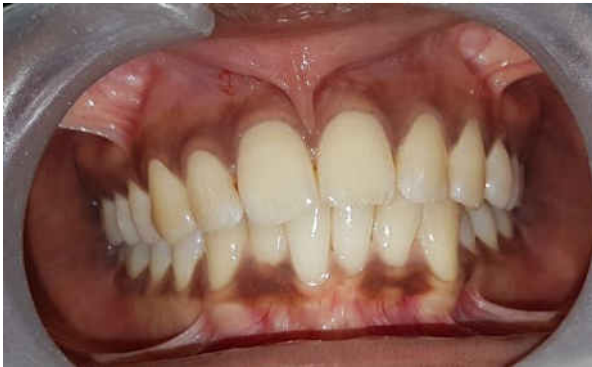DATE: 5.5.2018

OP NO: 201805040159

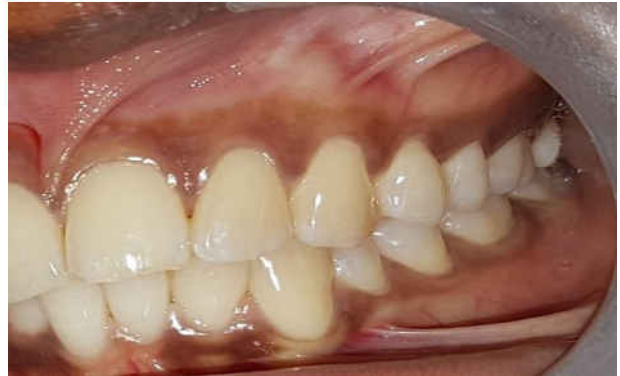AGE/SEX: 22/F

PROCEDURE: Maxillary labial frenectomy done

PRE OPERATIVE PHOTO

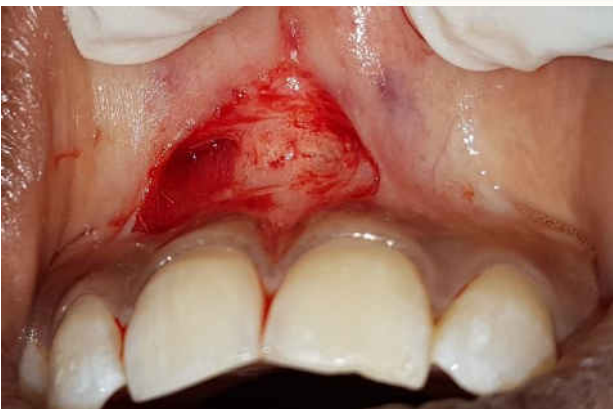

Frontal view

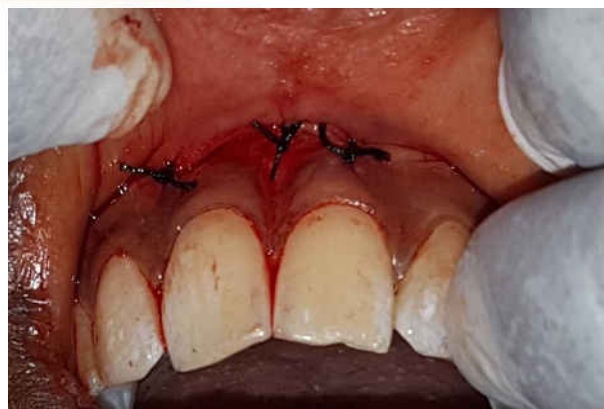

Left lateral view

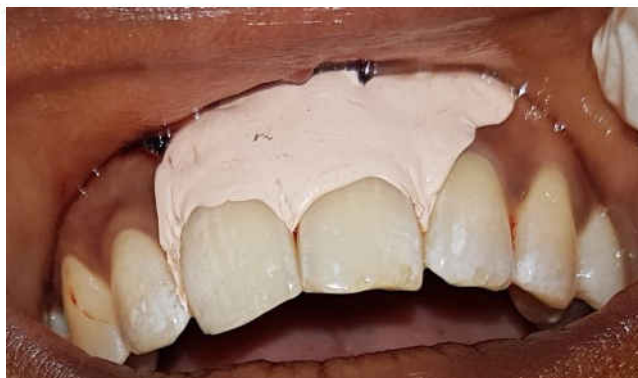OPERATIVE PHOTO



Upper labial frenectomy done



Simple interrupted sutures given



Non eugenol Periodontal dressing given in relation to 11,2122

Case-2

DEMOGRAPHIC DATA

PATIENT NAME: Mrs. Maheshwari

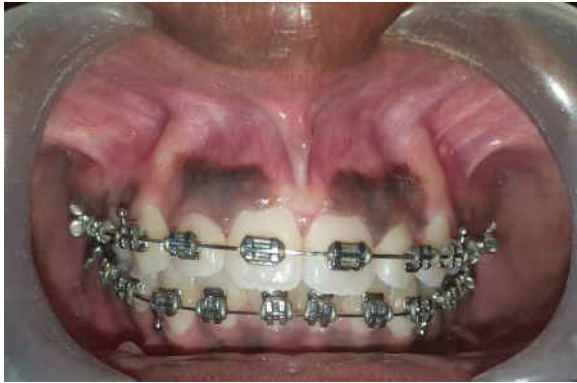DATE: 30.1.2019

OP NO: 201705110045

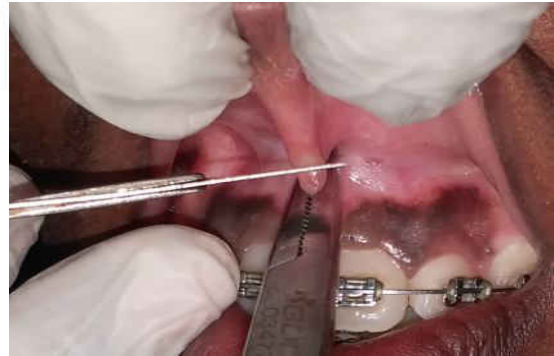AGE/SEX: 19/F

PROCEDURE: Frenectomy done in relation to maxillary labial frenum

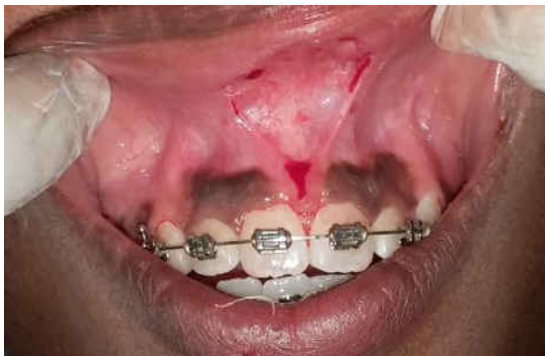OPERATIVE PHOTO



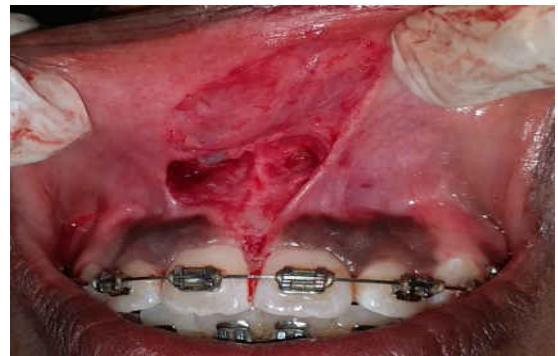Frontal view



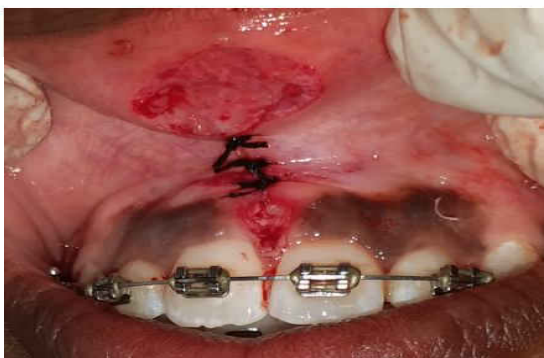Horizontal Incision placed



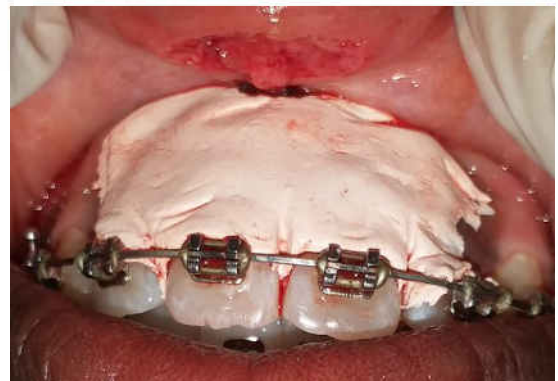Wedge of Frenal tissue removed



V-Y incision given



Simple interrupted sutures



COE pack given

Case-2

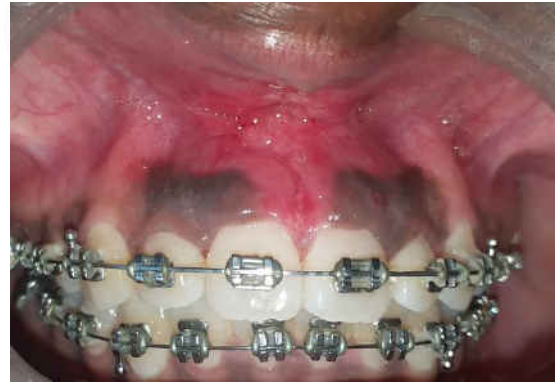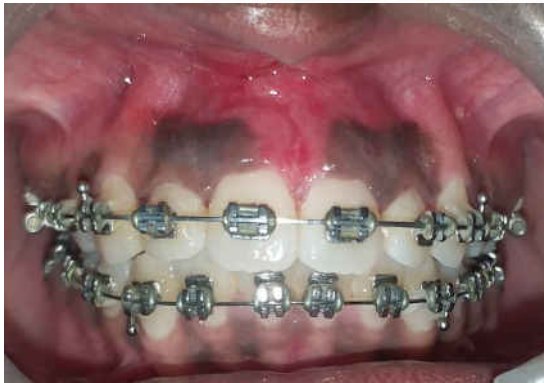DEMOGRAPHIC DATA

PATIENT NAME: Mrs. Maheshwari

OP NO: 201705110045

AGE/SEX: 19/F

POST OPERATIVE PHOTO- 1 WEEK



Frontal view

CASE-3

DEMOGRAPHIC DATA

PATIENT NAME : Ms. Swetha

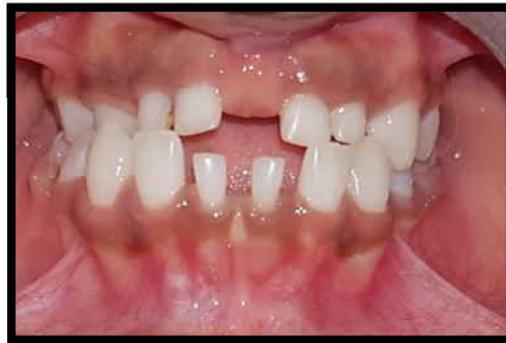DATE: 29.12.18

OP NO: 201810120048

AGE/SEX:12/F

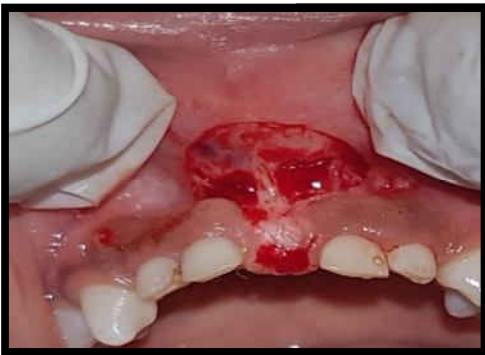
PROCEDURE: Frenectomy –Maxillary Labial Frenum

PRE OPERATIVE PHOTO – 29.12.18

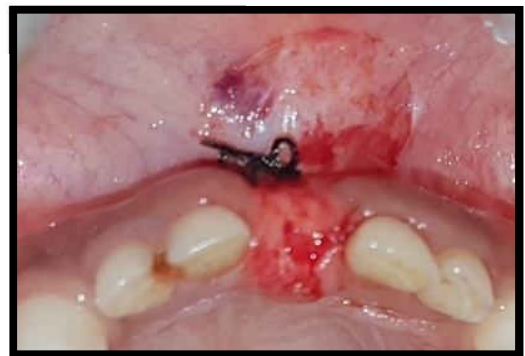


Frontal view

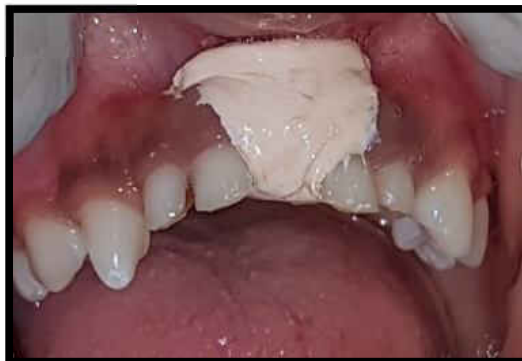OPERATIVE PHOTO-29.12.18



Frenectomy done



Sutures placed



Periodontal dressing given

CASE-4

DEMOGRAPHIC DATA

PATIENT NAME : Master Jeevanandhan

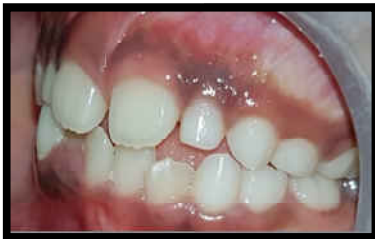DATE: 06.12.18

OP NO: 201812050063

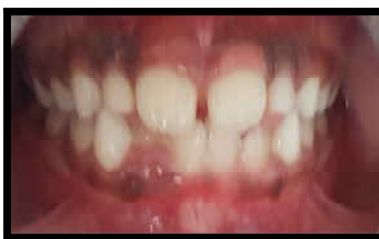AGE/SEX: 7 ½ M

PROCEDURE: Frenectomy –Mandibular lingual Frenum

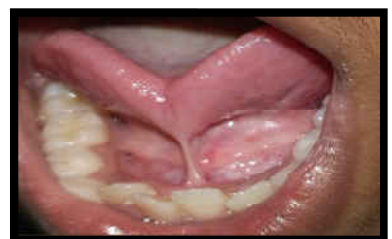PRE OPERATIVE PHOTO – 06.12.18



Left lateral view

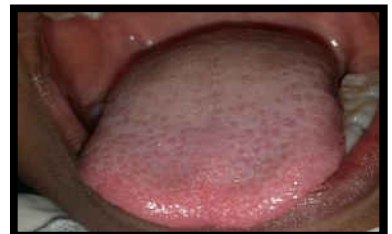
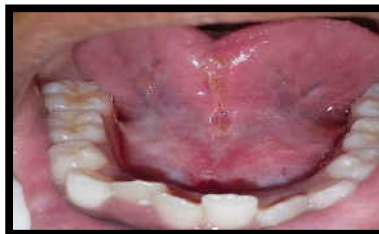
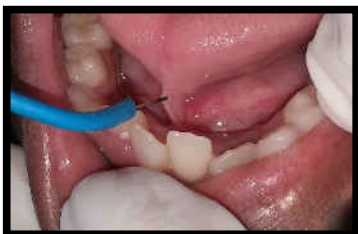Frontal view



Tongue tie

OPERATIVE PHOTO-06.12.18



Frenectomy done using Electrocautery

CASE-5

DEMOGRAPHIC DATA

PATIENT NAME : Master Jeevanandhan

DATE: 06.12.18

OP NO: 201812050063

AGE/SEX: 7 ½ M

PROCEDURE: Frenectomy –Mandibular lingual Frenum

PRE OPERATIVE PHOTO – 06.12.18



Left lateral view



Frontal view



Tongue tie

OPERATIVE PHOTO-06.12.18



Frenectomy done using Electrocautery

CASE-5

DEMOGRAPHIC DATA

PATIENT NAME : Master Jeevanandhan

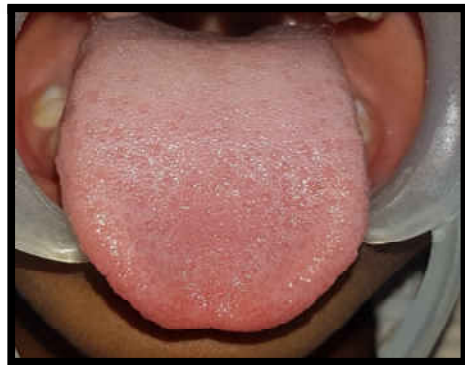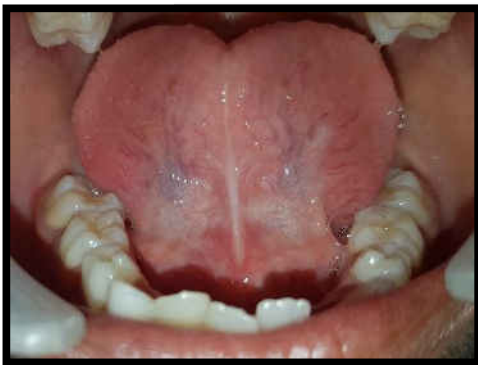DATE: 06.12.18

OP NO: 201812050063

AGE/SEX: 7 ½ M

PROCEDURE: Frenectomy –Mandibular lingual Frenum

POST OPERATIVE PHOTO-18.2.18



CROWN LENGTHENING

Case-1

DEMOGRAPHIC DATA

PATIENT NAME : Mrs.Raziya

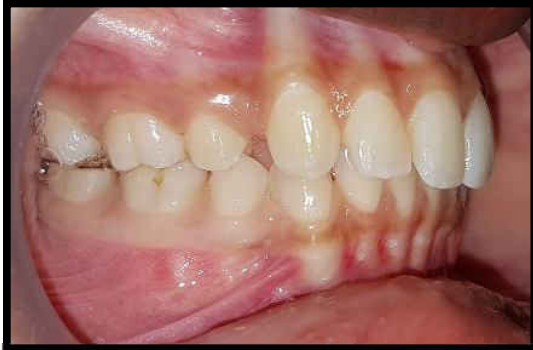DATE:26.2.18

OP NO: 201712160012

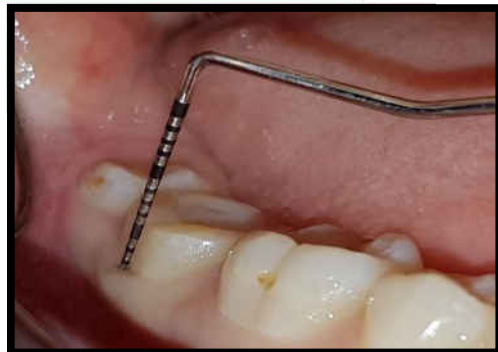AGE/SEX:27/F

PROCEDURE: Gingivectomy done in relation to 46

PRE OPERATIVE PHOTO -26.2.18

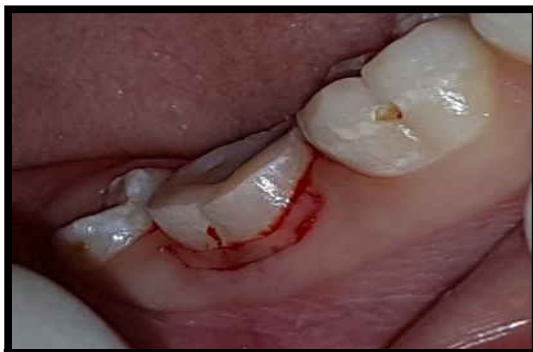

RIGHT LATERAL

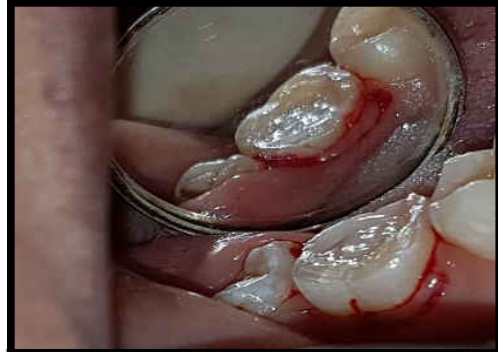

INSUFFICIENT CROWN
HEIGHT-47

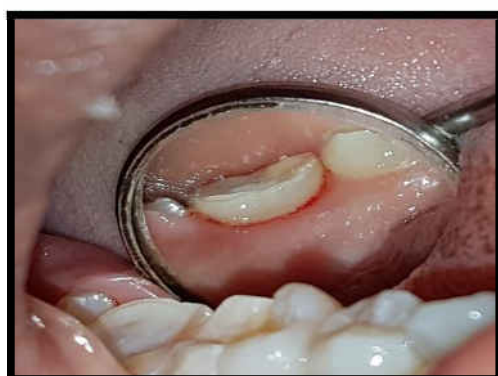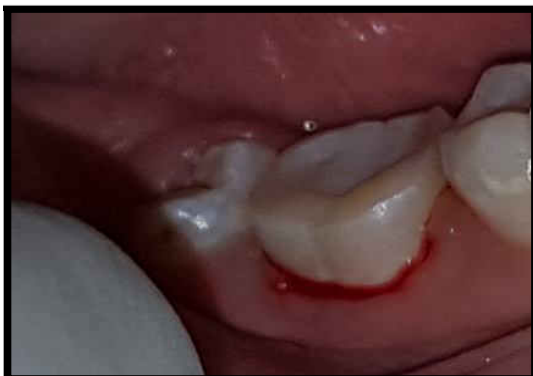OPERATIVE PHOTOS-26.2.18



47-EXTERNAL BEVEL
INCISION- BUCCAL ASPECT

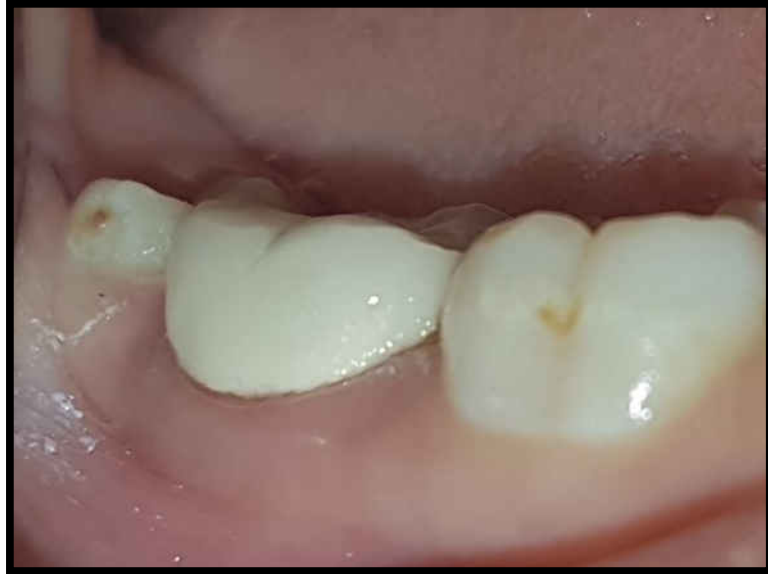

47-EXTERNAL BEVEL
INCISION- LINGUAL
ASPECT

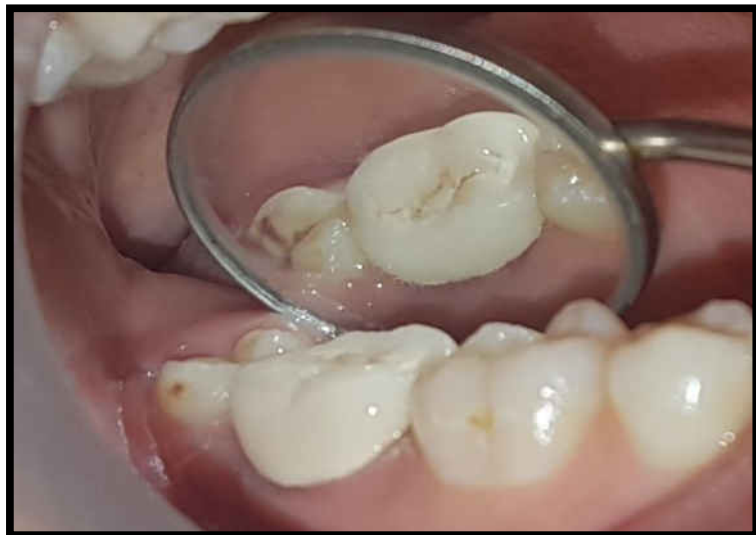

IMMEDIATE POST-OPERATIVE

1 MONTH POST-OPERATIVE
PHOTOS



BUCCAL ASPECT 47



LINGUAL ASPECT 47

Case-2

DEMOGRAPHIC DATA

PATIENT NAME : Mrs.Shakila

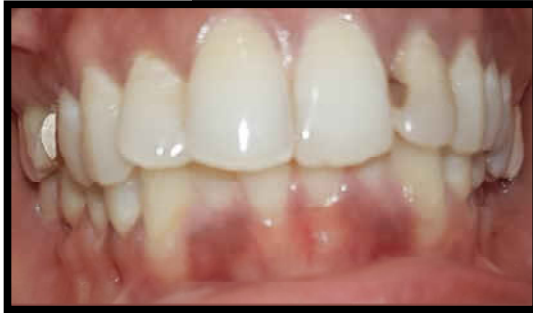DATE:7.7.18

OP NO: 201806230055

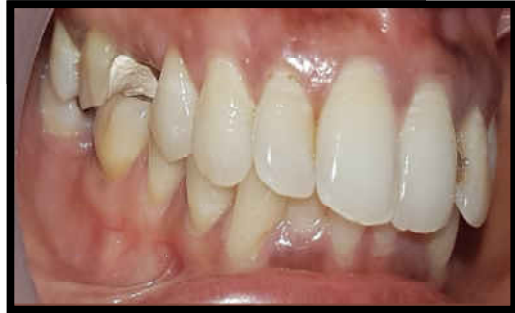AGE/SEX:38/F

PROCEDURE: Crown lengthening done in relation to 16

PRE OPERATIVE PHOTO -7.7.18

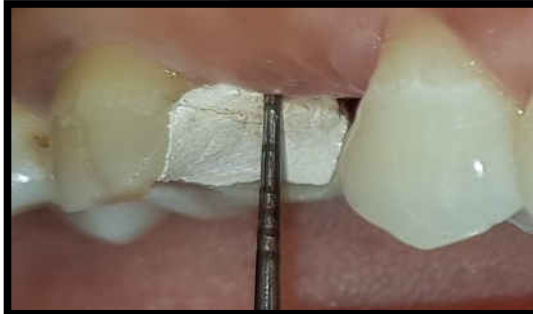

Frontal View

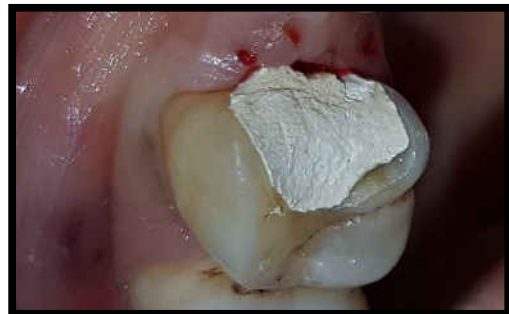

Right Lateral

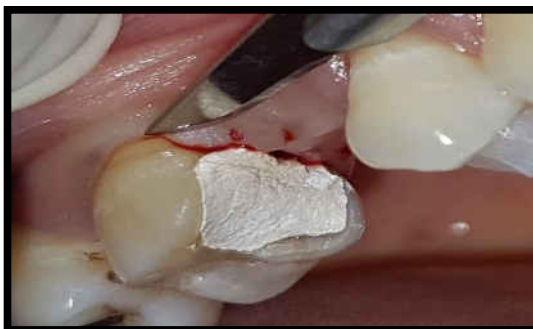OPERATIVE PHOTOS-7.7.18



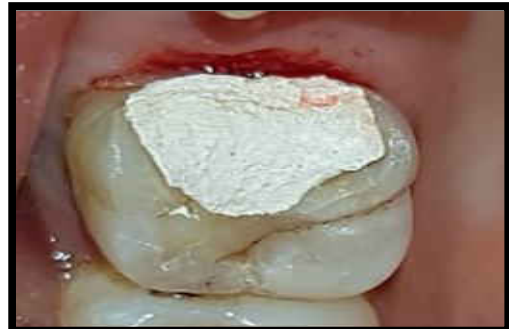16-Insufficient clinical crown height



16-Pocket Markings

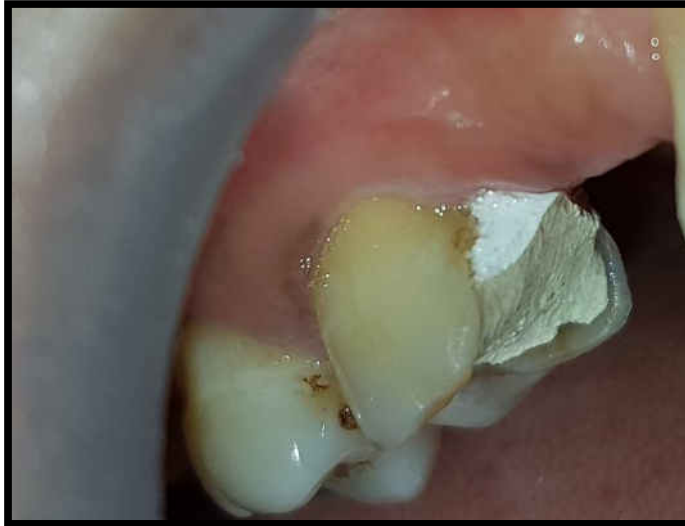

16 External Bevel Incision- Labial Aspect

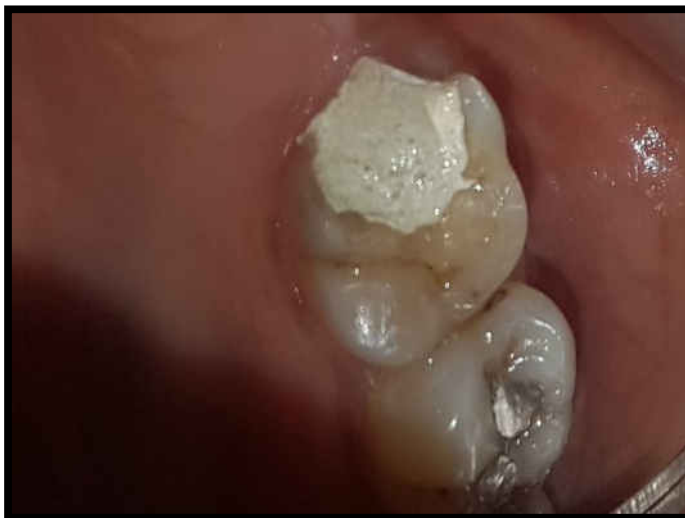

Immediate Post-operative

POST-OPERATIVE PHOTOS



MESIAL ASPECT 16



OCCLUSAL ASPECT 16

Case-3

DEMOGRAPHIC DATA

PATIENT NAME : Mr.Solomon

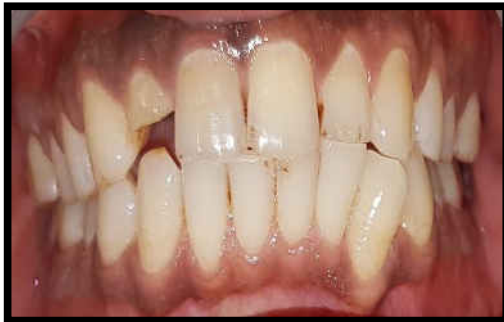DATE:29.5.18

OP NO: 201805210054

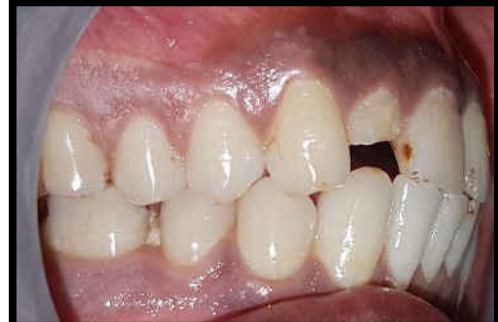AGE/SEX:31/M

PROCEDURE: Crown lengthening done in relation to 12

PRE OPERATIVE PHOTO -29.5.18

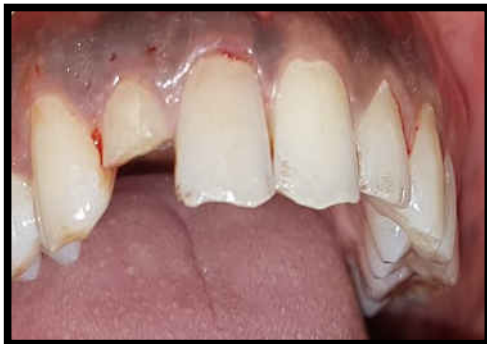

Frontal View

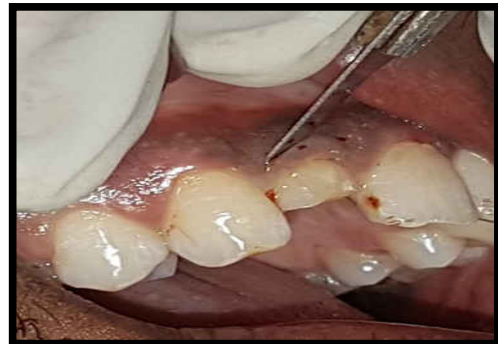

Right Lateral

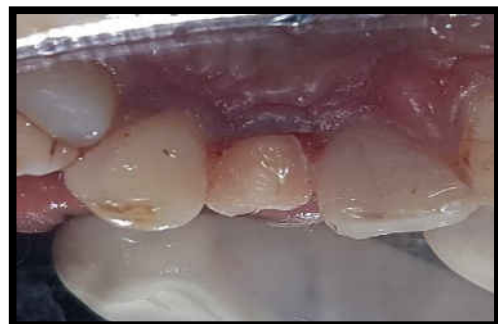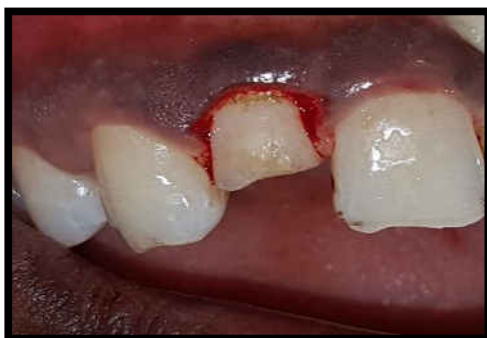OPERATIVE PHOTOS-29.5.18



12-Pocket Markings

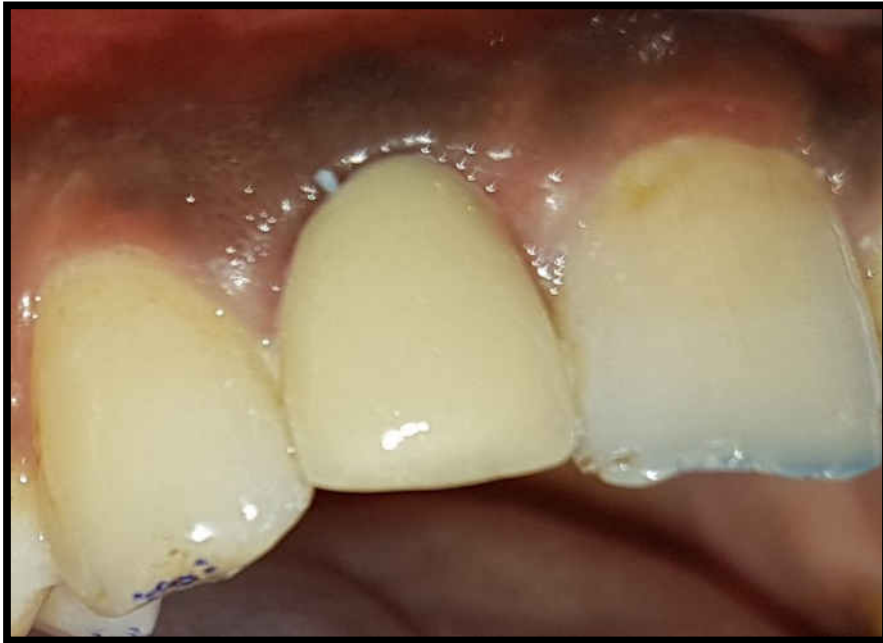

12 External Bevel Incision- Labial Aspect

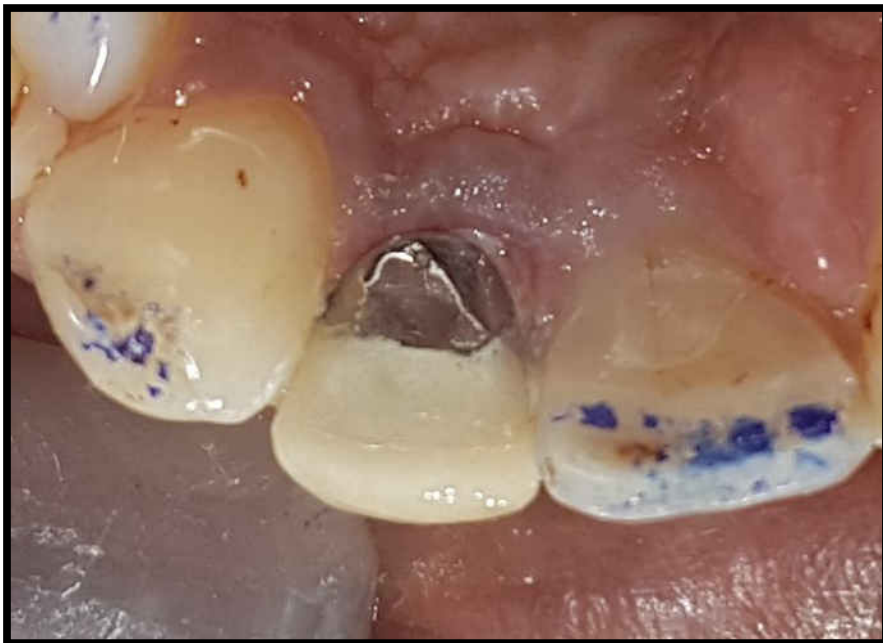

Immediate Post-operative

POST-OPERATIVE PHOTOS



LABIAL ASPECT 12



PALATAL ASPECT 12

Case-4

DEMOGRAPHIC DATA

PATIENT NAME : Mr.Subramani

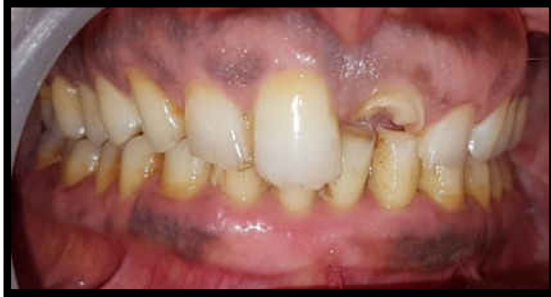DATE:21.5.18

OP NO: 201711200030

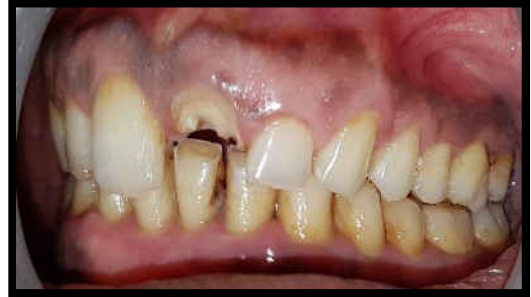AGE/SEX: 51/M

PROCEDURE: Crown lengthening in relation to 21

PRE OPERATIVE PHOTO -21.5.18

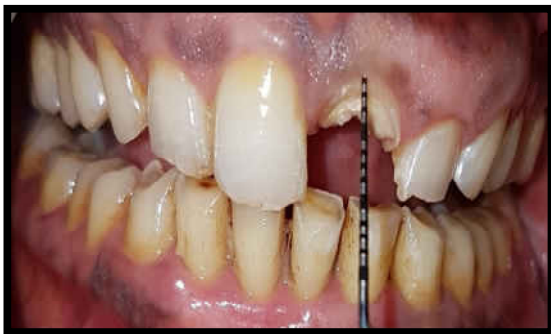

Frontal view

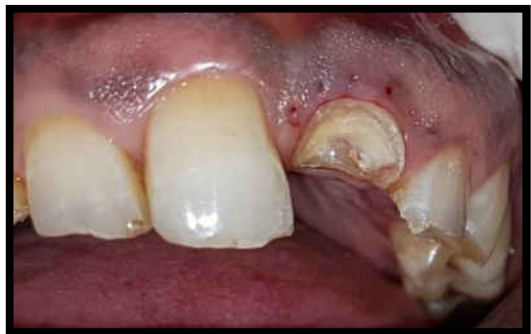

Left lateral view

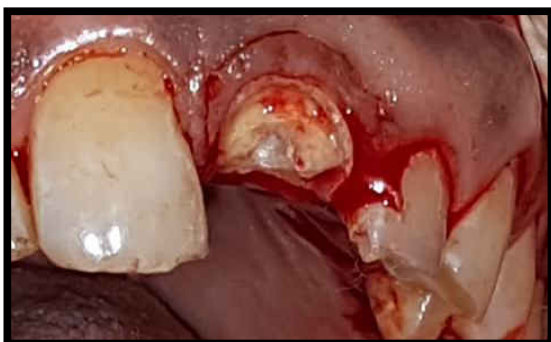
OPERATIVE PHOTO-21.5.18



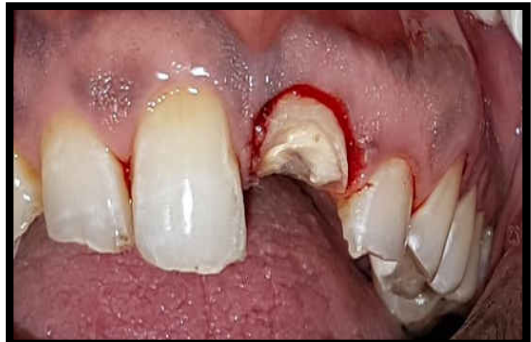Insufficient crown height -labial aspect-21



Pocket Markings-21

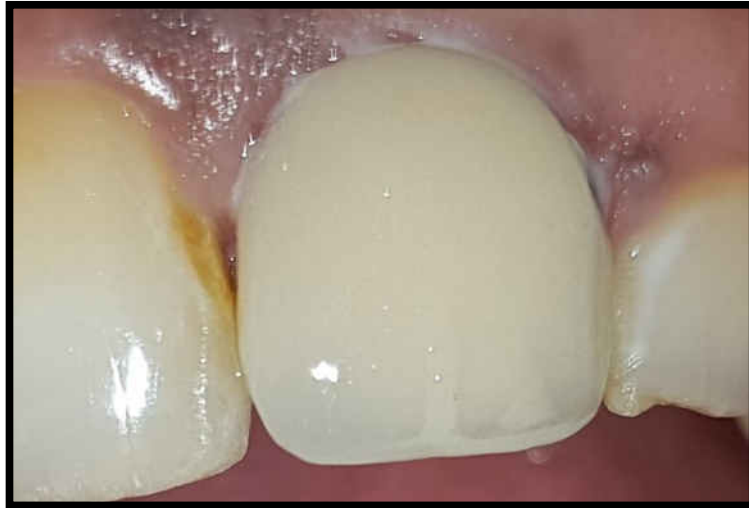

External bevel incision-21 labial aspect

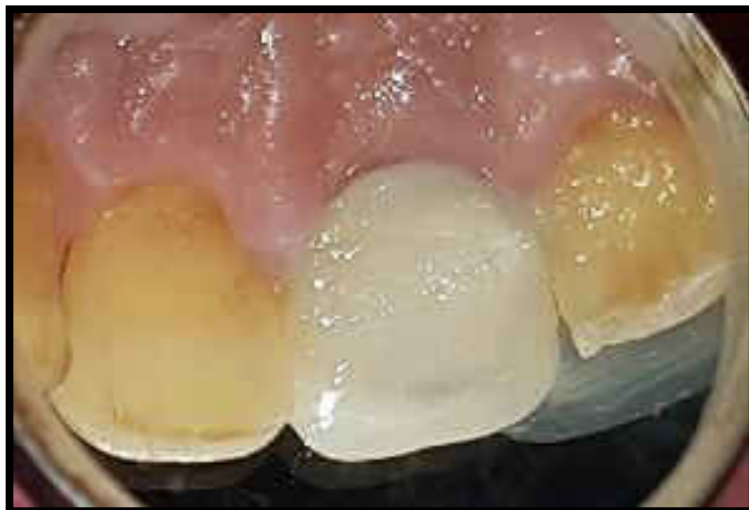

Post gingivectomy-21 labial aspect

1 MONTH POST –OPERATIVE



21-LABIAL ASPECT



21-PALATAL ASPECT

Case-5

DEMOGRAPHIC DATA

PATIENT NAME: Mr. Pankaj Darip

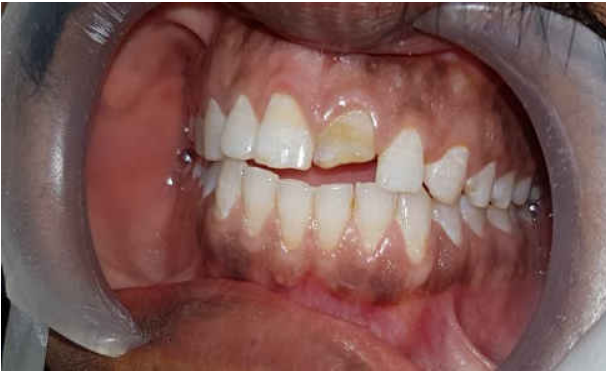DATE: 7.4.2018

OP NO: 201712230024

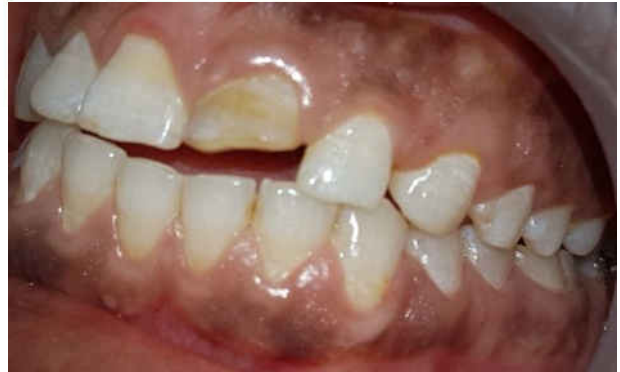AGE/SEX: 24/M

PROCEDURE: Crown lengthening done in relation to 36

PRE OPERATIVE PHOTO

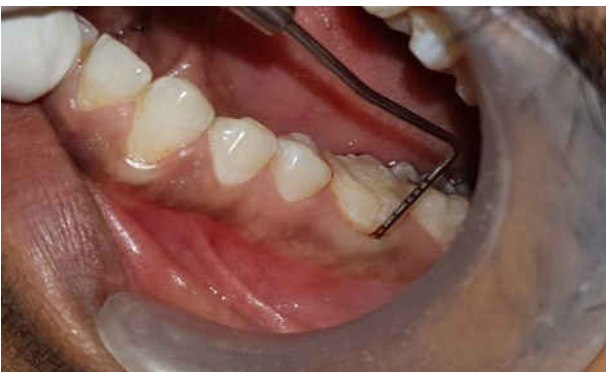

Frontal view

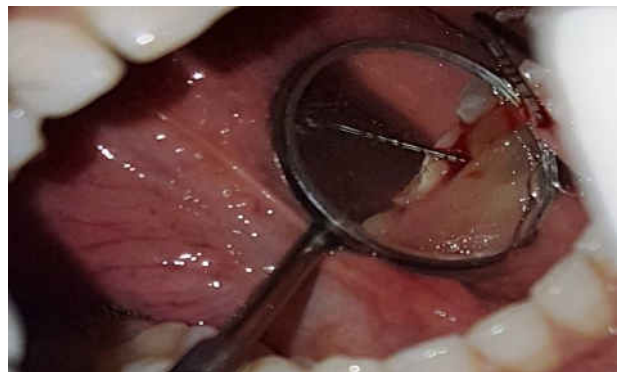


Left lateral view

PRE OPERATIVE MEASUREMENTS

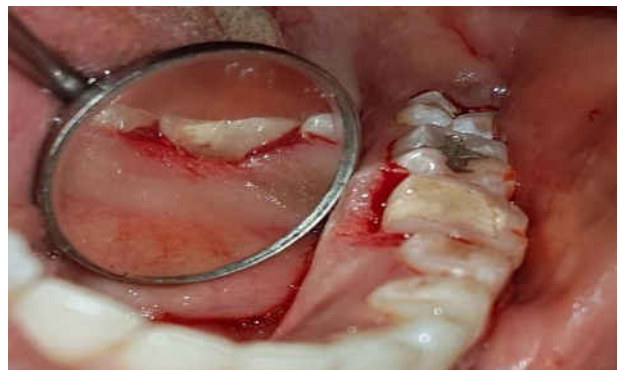
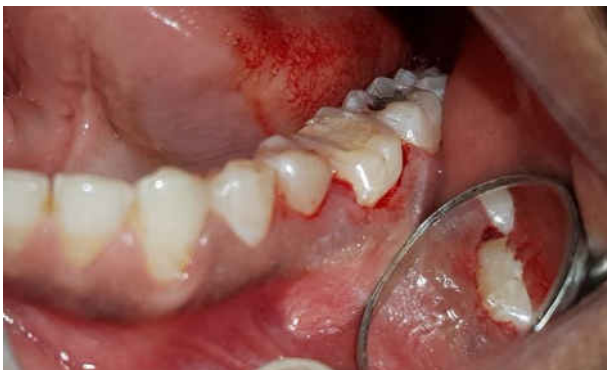

PPD- 2mm in midbuccal aspect of 36



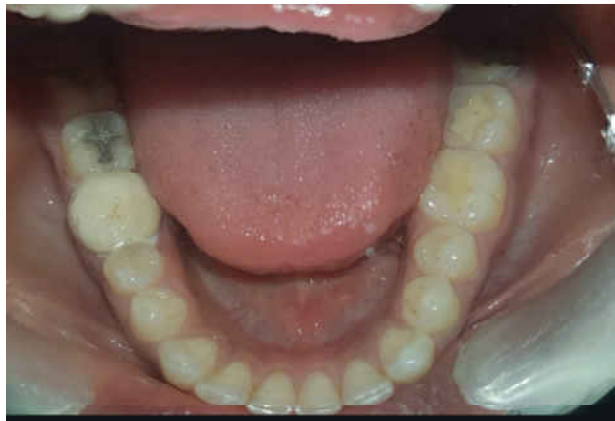PPD- 2mm in mesiolingual aspect of 36

OPERATIVE PHOTO

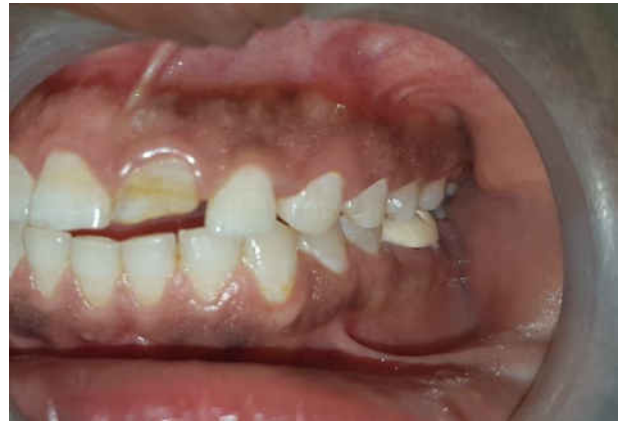

Gingivectomy done in relation to buccal and lingual aspect of 36

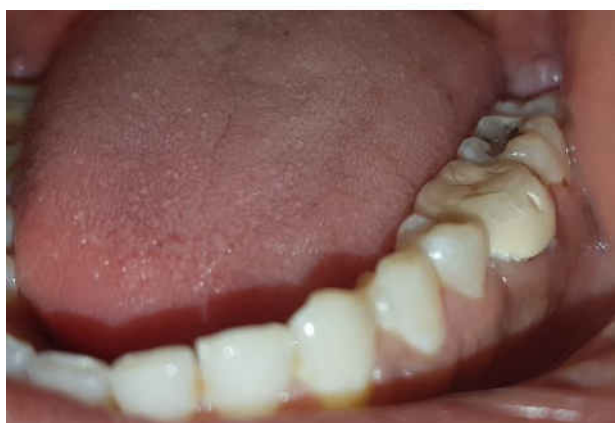POST OPERATIVE PHOTO



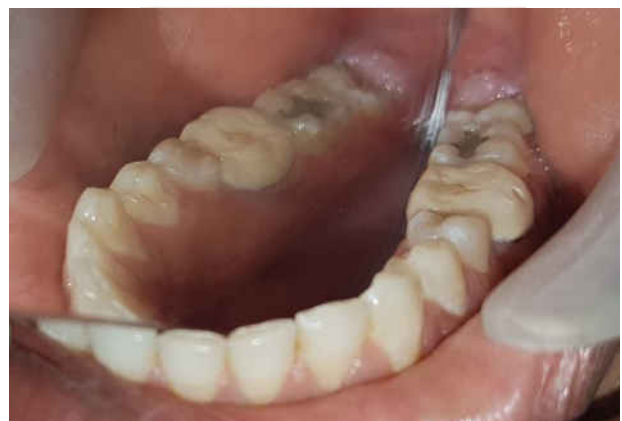Occlusal view



Right lateral view



Buccal view



Lingual view

Case-6

DEMOGRAPHIC DATA

PATIENT NAME: Mrs. Sridevi

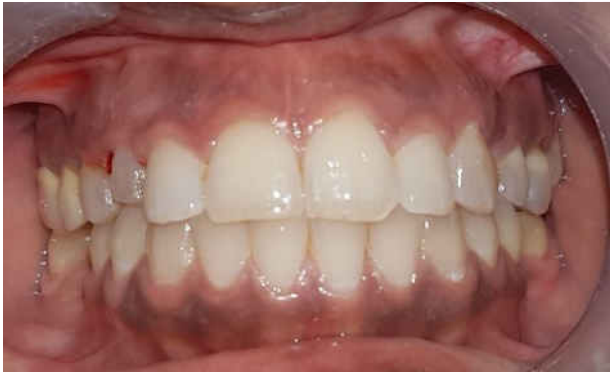DATE: 9.2.2018

OP NO: 201712270080

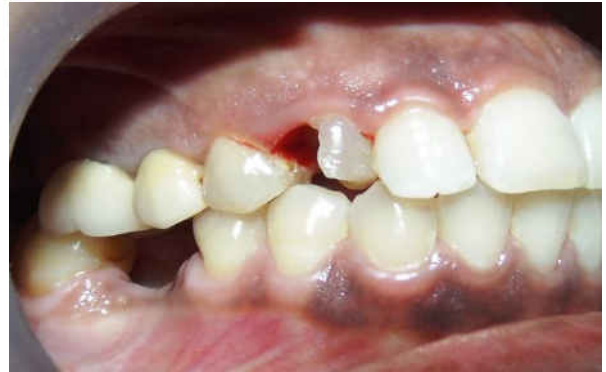AGE/SEX: 44/F

PROCEDURE: Gingivectomy done in relation to 13

PRE OPERATIVE PHOTO

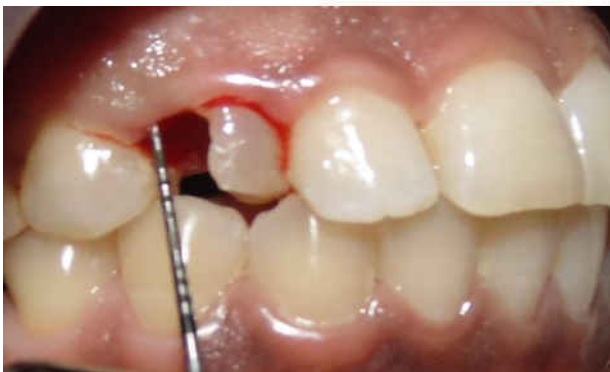

Frontal view

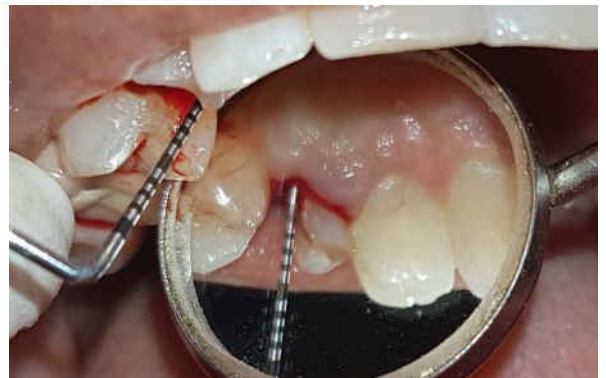

Right lateral view

PRE OPERATIVE MEASUREMENTS

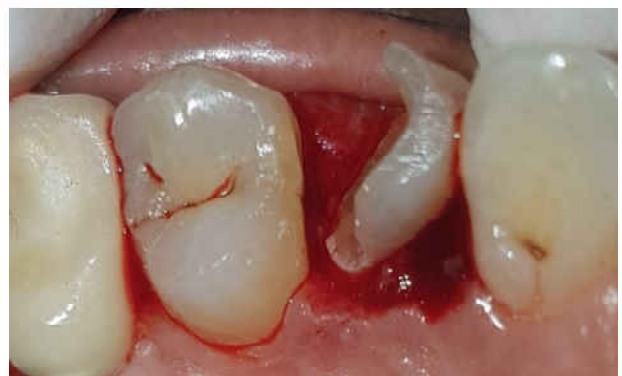
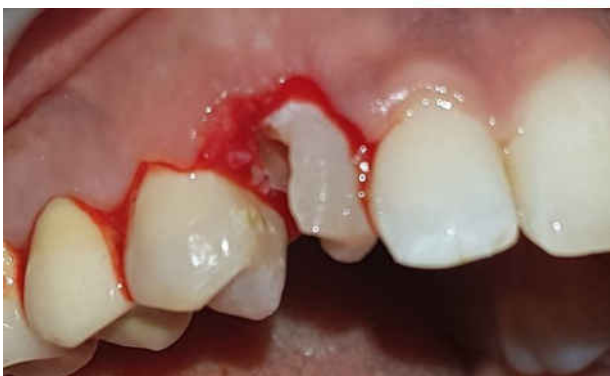
PPD- 3mm in distobuccal aspect of 13



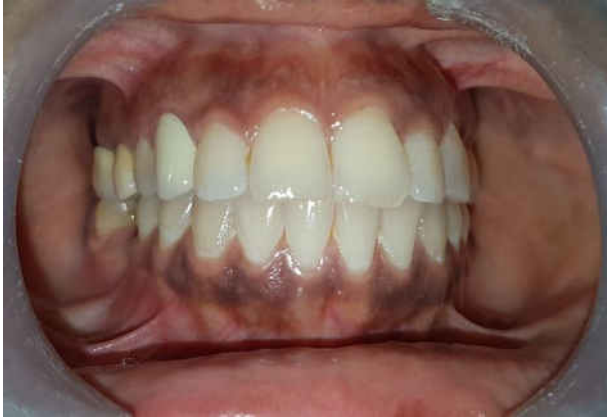PPD- 3mm in midlingual aspect of 13

OPERATIVE PHOTO

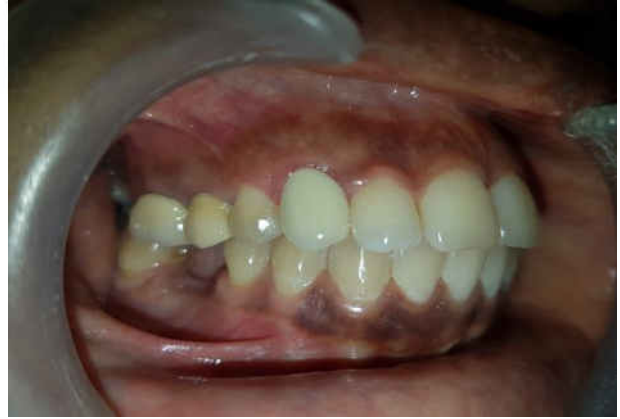

Gingivectomy done in relation to buccal and lingual aspect of 13

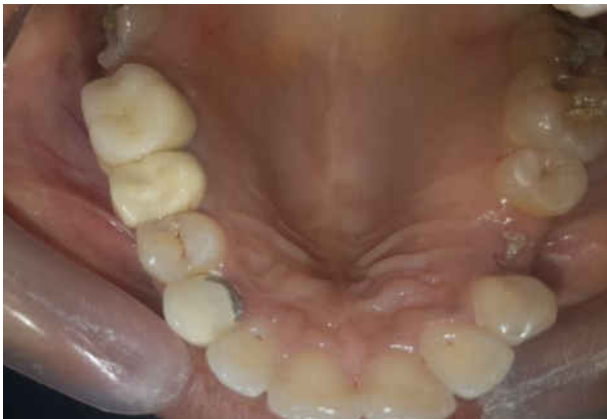POST OPERATIVE PHOTO



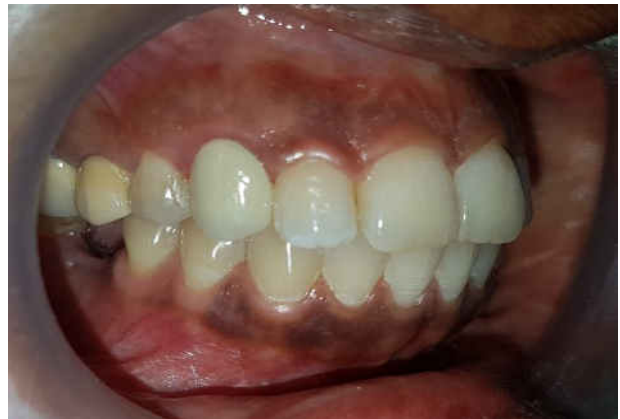Frontal view



Right lateral view



Occlusal view



Right lateral view

Case-5

DEMOGRAPHIC DATA

PATIENT NAME : Mr. Vijay

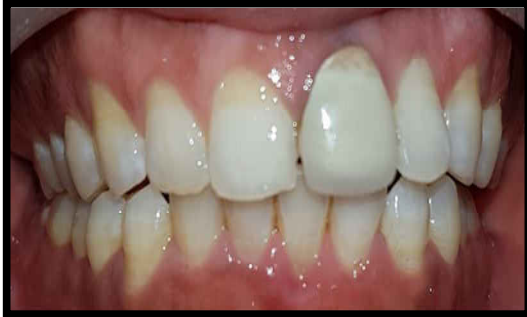DATE:18.4.18

OP NO: 201803300039

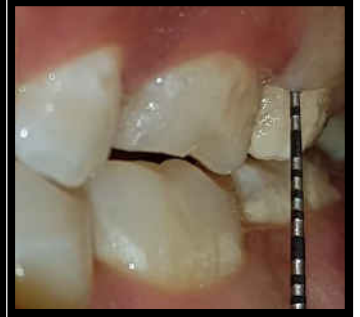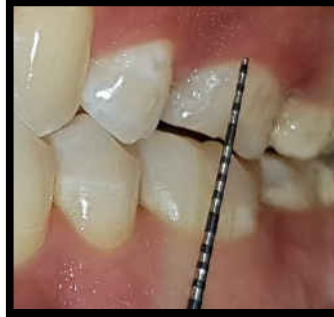AGE/SEX:32/M

PROCEDURE: Gingivectomy done in relation to 26,27

PRE OPERATIVE PHOTO -18.4.18

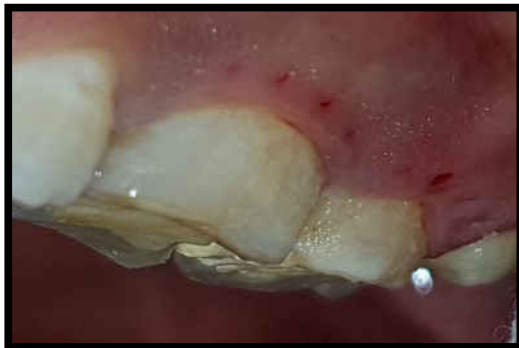

FRONTAL VIEW

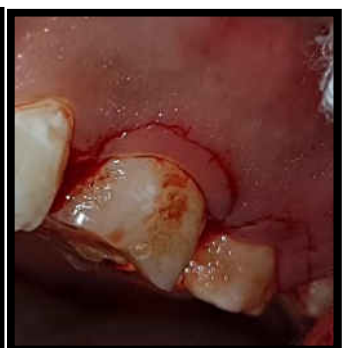
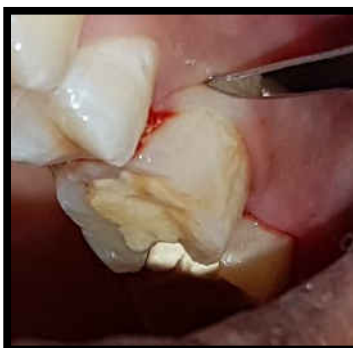
INSUFFICIENT CROWN HEIGHT-26,27

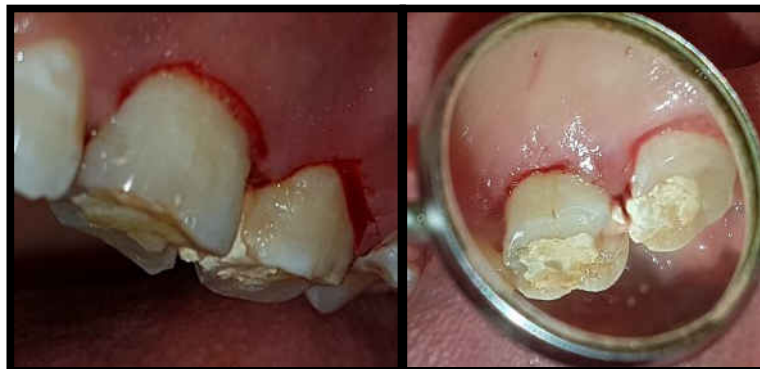OPERATIVE PHOTOS-18.4.18



26,27-POCKET MARKINGS



26,27-EXTERNAL BEVEL INCISION-
BUCCAL ASPECT



IMMEDIATE POST-OPERATIVE

Case-7

DEMOGRAPHIC DATA

PATIENT NAME : Mr.Umapathi

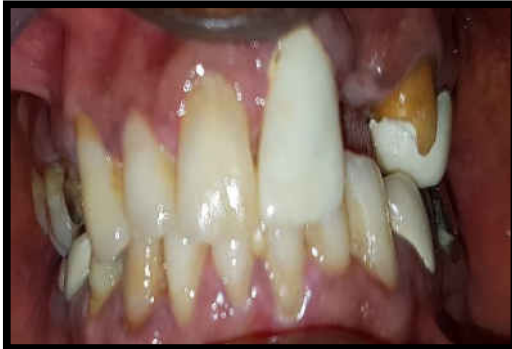DATE:4.6.18

OP NO: 201803140005

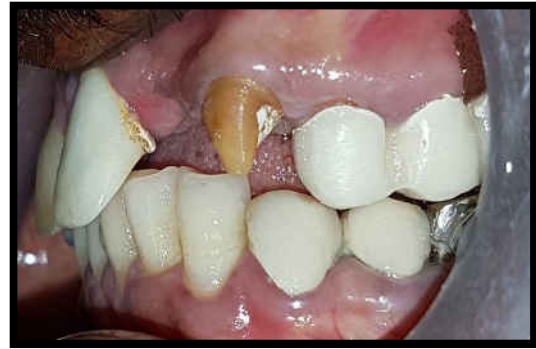AGE/SEX:62/M

PROCEDURE: Crown lengthening done in relation to 23

PRE OPERATIVE PHOTO -4.4.18

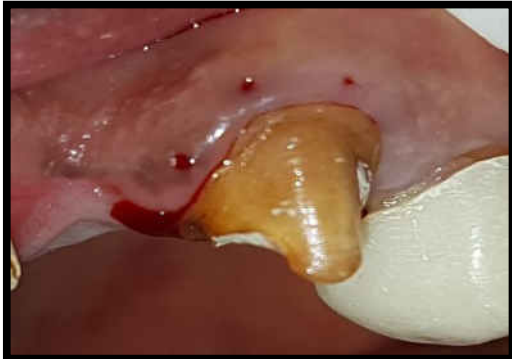


Frontal View

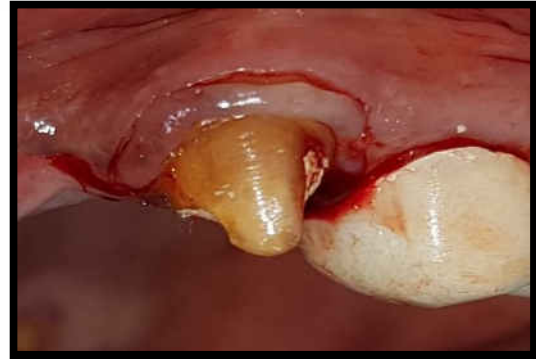


Left Lateral

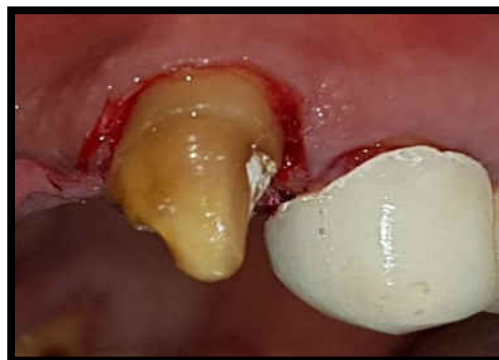
OPERATIVE PHOTOS-6.6.18



23-Pocket Markings

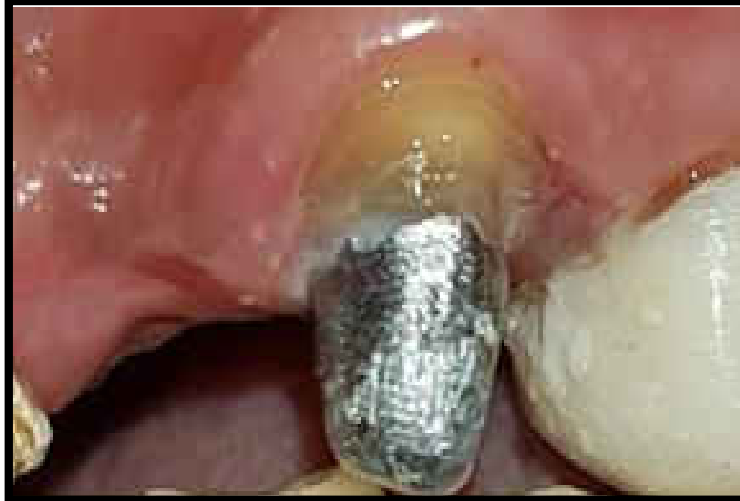

23 External Bevel Incision- Labial Aspect

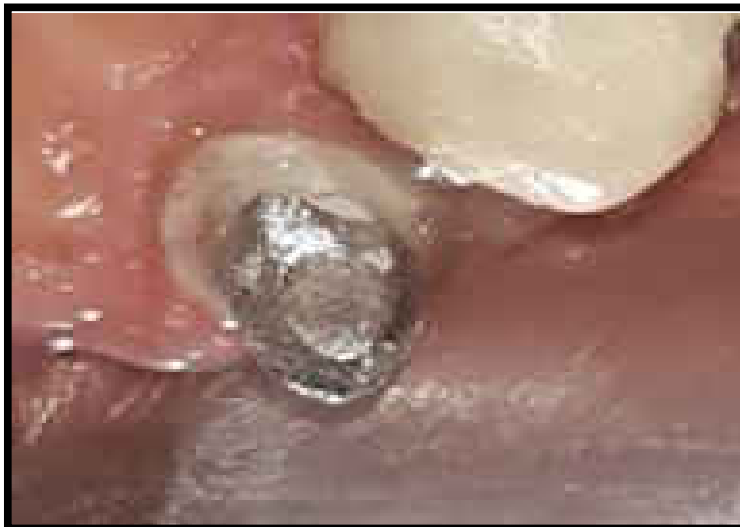

Immediate Post-operative

POST-OPERATIVE PHOTOS

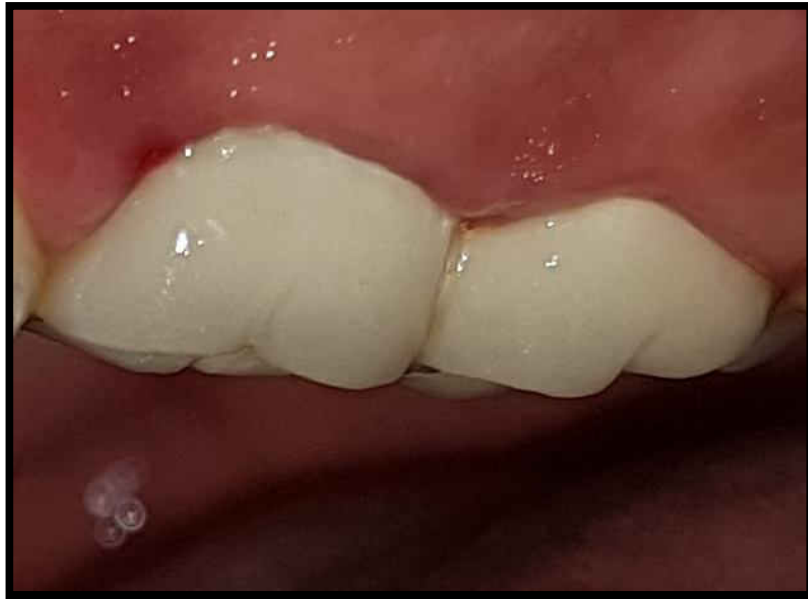

LABIAL ASPECT 23

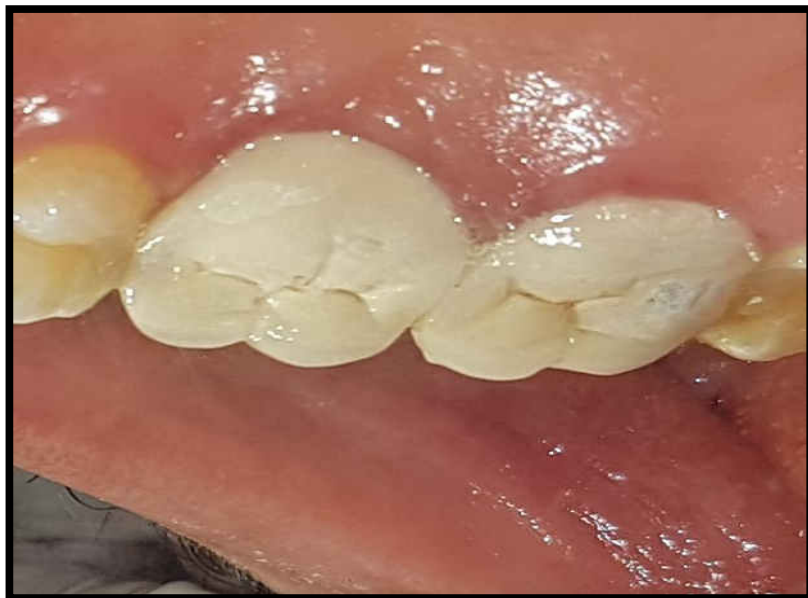

PALATAL ASPECT 23

1 MONTH POST-OPERATIVE
PHOTOS



BUCCAL ASPECT 26,27



LINGUAL ASPECT 26,27

case-8

DEMOGRAPHIC DATA

PATIENT NAME : Mrs.Visalakshi

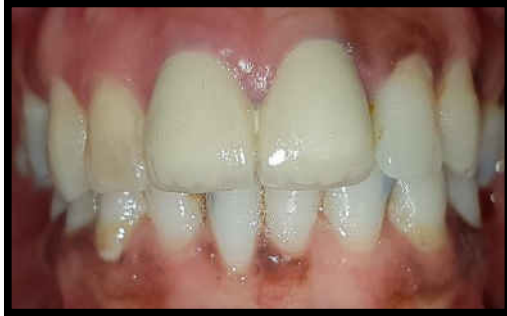DATE:8.6..18

OP NO: 201707250096

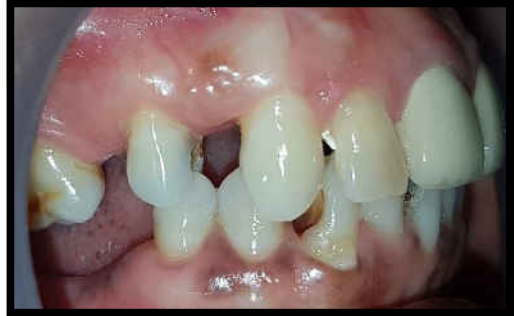AGE/SEX:31/F

PROCEDURE: Crown lengthening done in relation to 12

PRE OPERATIVE PHOTO -8.6.18

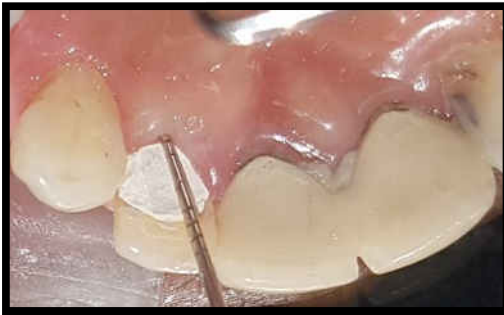

Frontal View

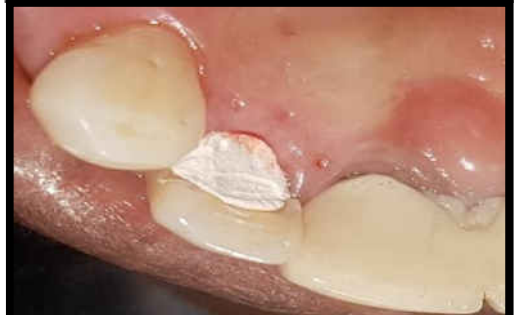

Right Lateral

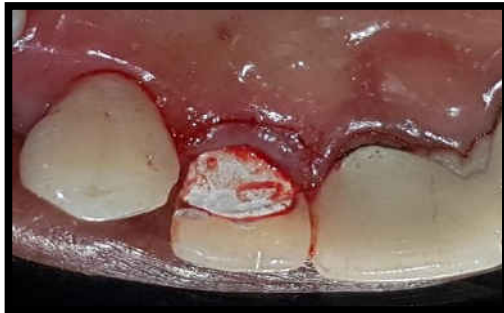
OPERATIVE PHOTOS-8.6.18



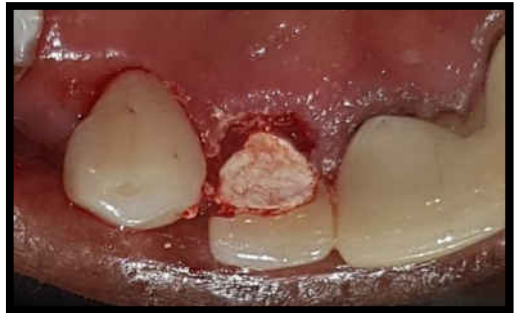12- Insufficient clinical crown height- lingual aspect



12-pocket Markings

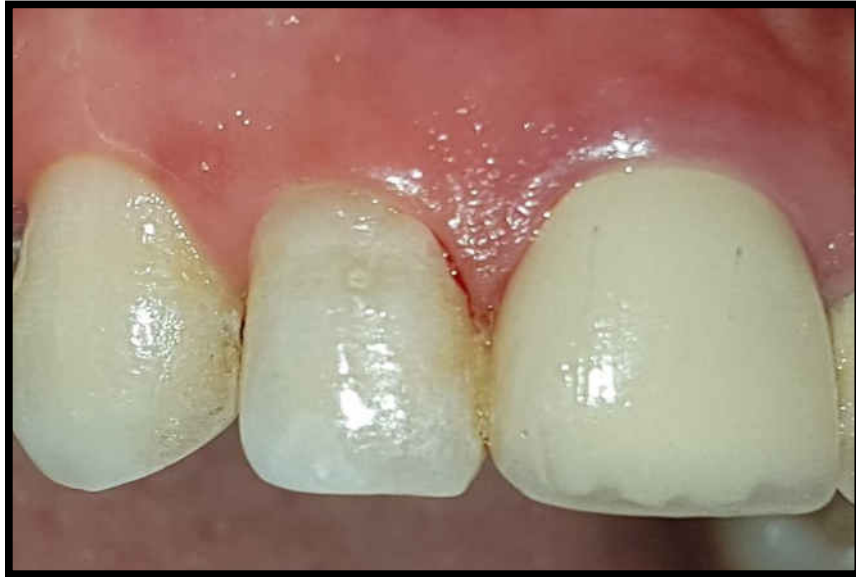

12 External Bevel Incision- Lingual Aspect

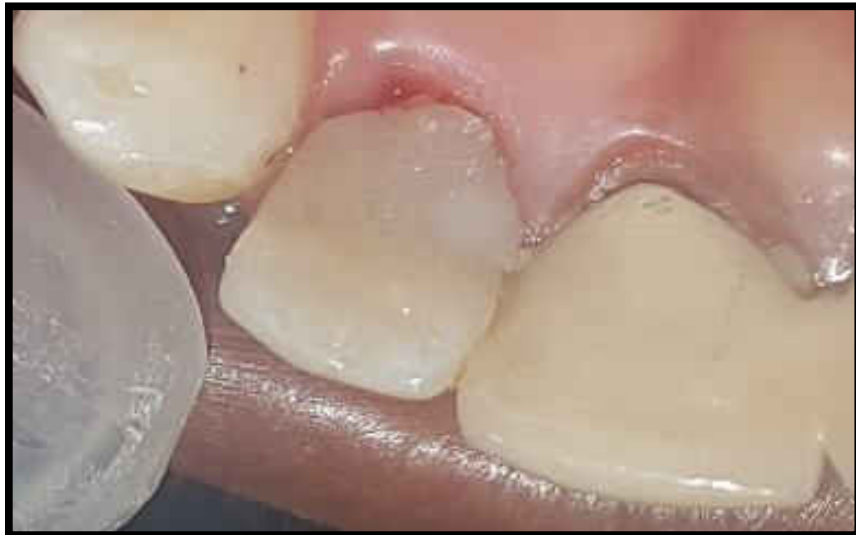

Immediate Post-operative

POST-OPERATIVE PHOTOS



LABIAL ASPECT 12



PALATAL ASPECT 12

Case- 9

DEMOGRAPHIC DATA

PATIENT NAME : Mr.Vishnu Shankar

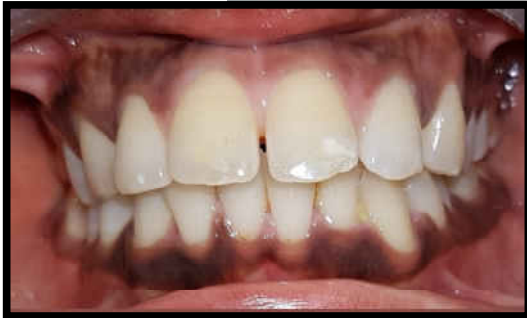DATE:12.4.18

OP NO: 201804060083

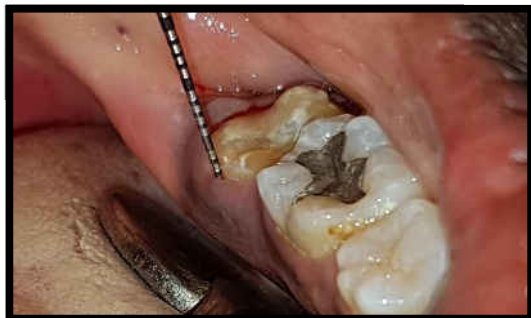AGE/SEX:31/M

PROCEDURE: Gingivectomy done in relation to 37

PRE OPERATIVE PHOTO -12.4.18

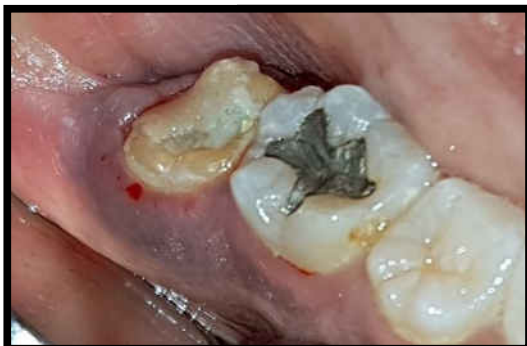

FRONTAL VIEW

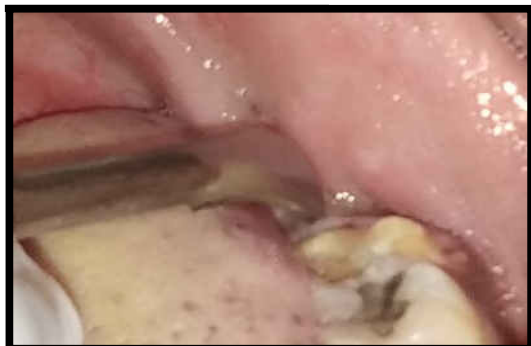

INSUFFICIENT CROWN
HEIGHT-37

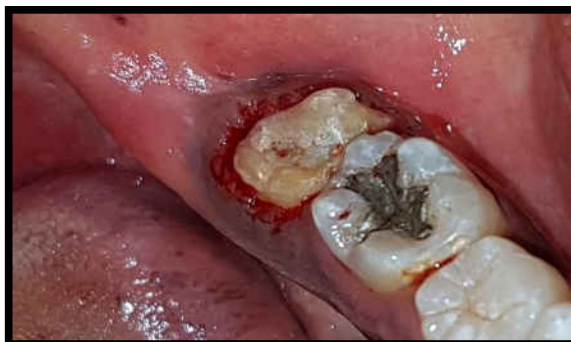OPERATIVE PHOTOS-12.4.18



37-POCKET MARKINGS

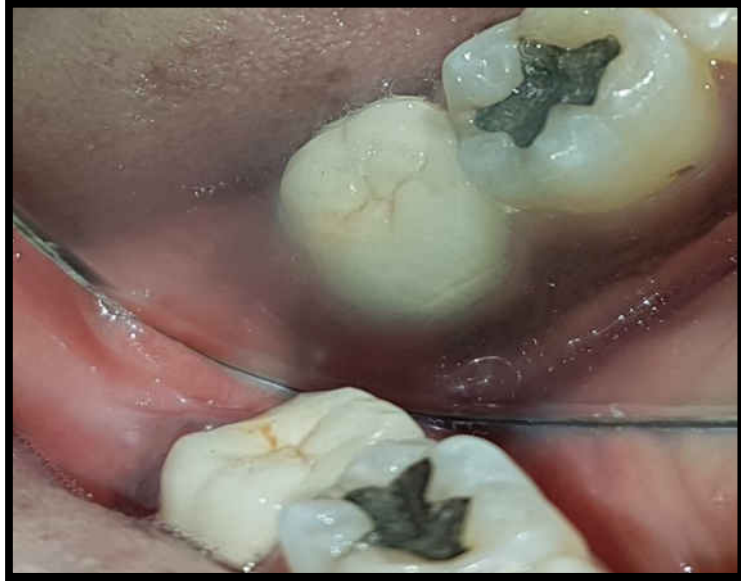

37-EXTERNAL BEVEL
INCISION- BUCCAL ASPECT

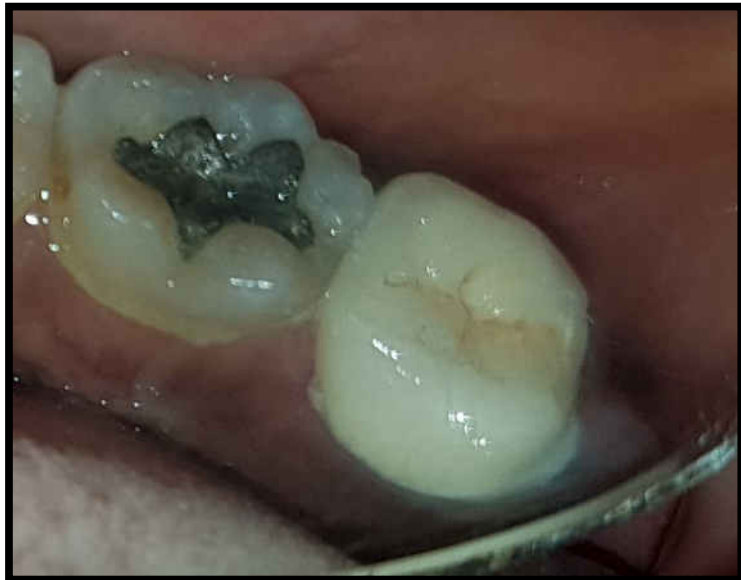

IMMEDIATE POST-OPERATIVE

1 MONTH POST-OPERATIVE
PHOTOS



BUCCAL ASPECT 37



LINGUAL ASPECT 37

POST OPERATIVE PHOTO



Occlusal view



Right lateral view



Buccal view



Lingual view

Case-10

DEMOGRAPHIC DATA

PATIENT NAME : Ms.Nithya

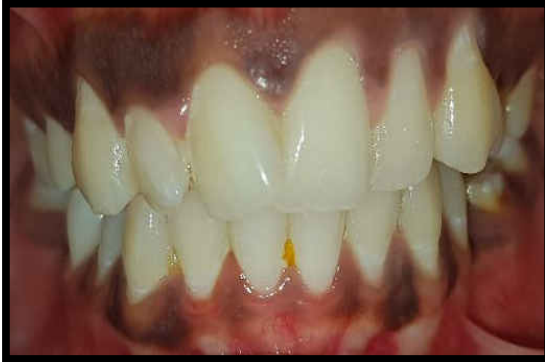DATE: 27/1/18

OP NO: 201712090023

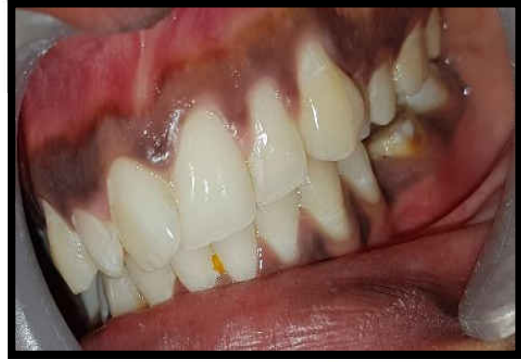AGE/SEX: 20/F

PROCEDURE: Gingivectomy done in relation to 36.

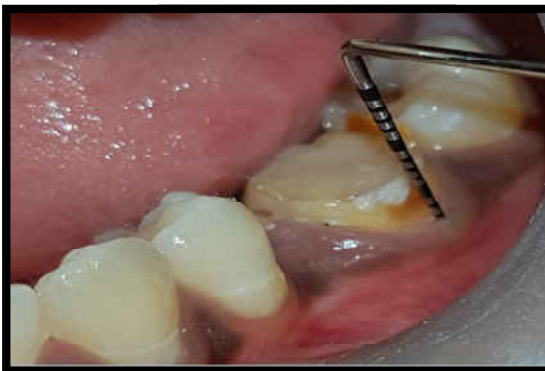
PRE OPERATIVE PHOTO – 27.1.18



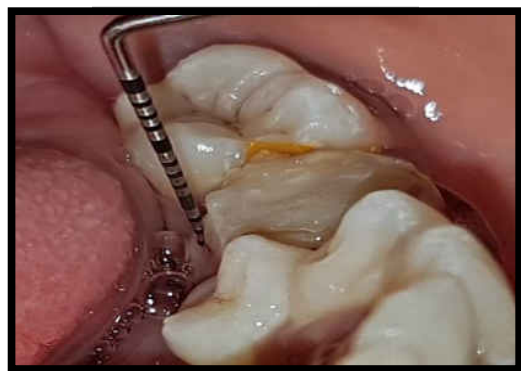
Frontal view



Left lateral view

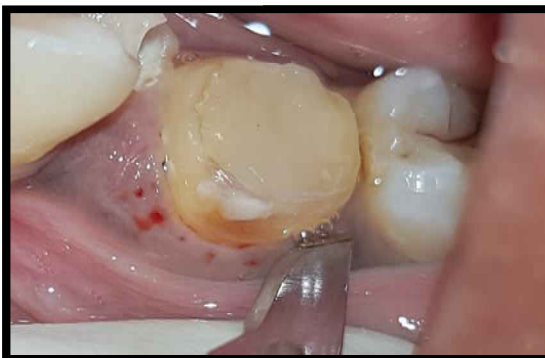

Insufficient crown height –buccal aspect-36

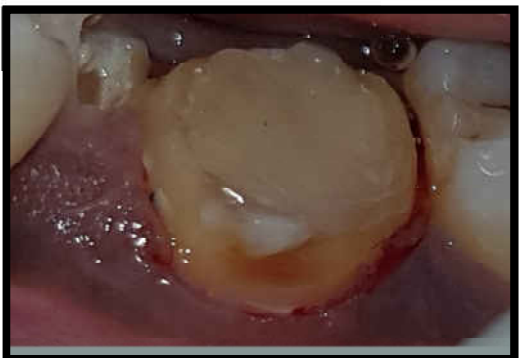


Insufficient crown height- lingual aspect 36

OPERATIVE PHOTO-31.1.18

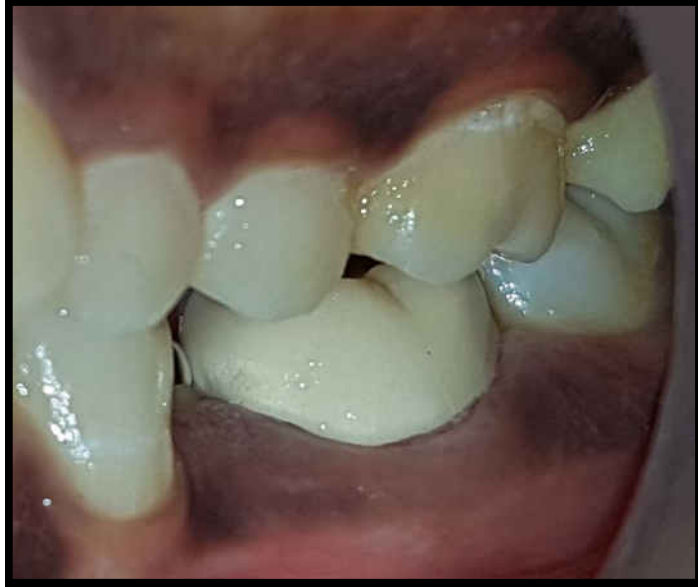

External bevel incision- 36

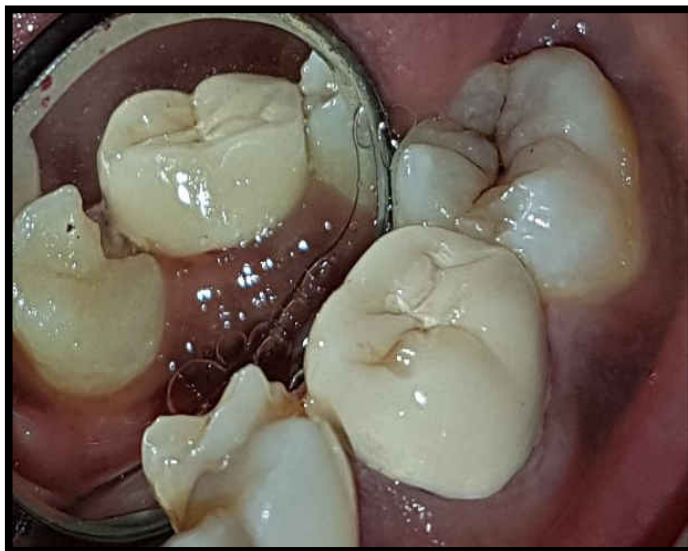


Post gingivectomy-36 buccal aspect

1 MONTH POST-OPERATIVE
PHOTOS



BUCCAL ASPECT 38



LINGUAL ASPECT 38

Case-11

DEMOGRAPHIC DATA

PATIENT NAME: Mr. Annamalai

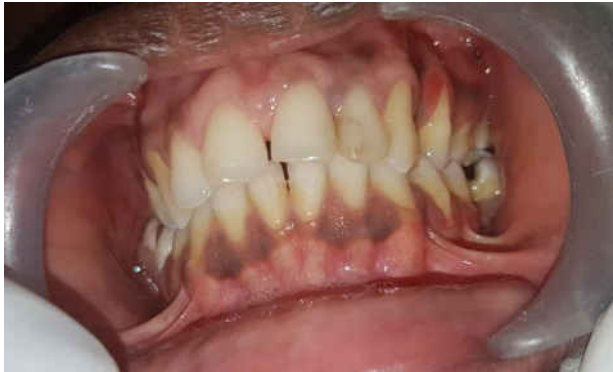DATE: 23.3.2018

OP NO: 201802160052

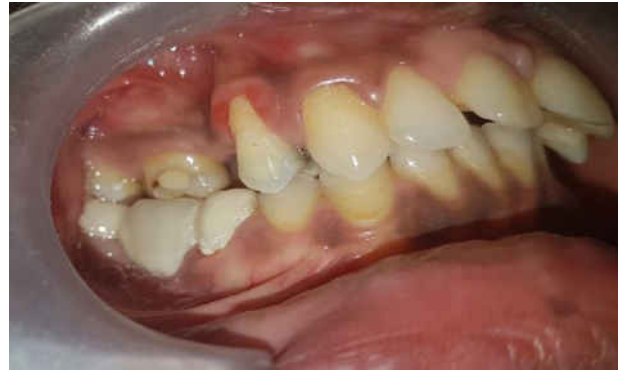AGE/SEX: 25/M

PROCEDURE: Crown lengthening done in relation to 47

PRE OPERATIVE PHOTO

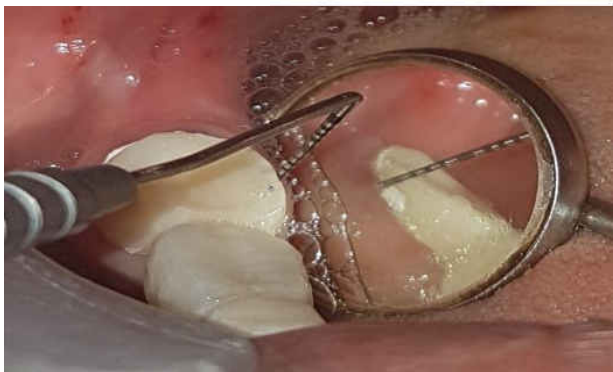

Frontal view

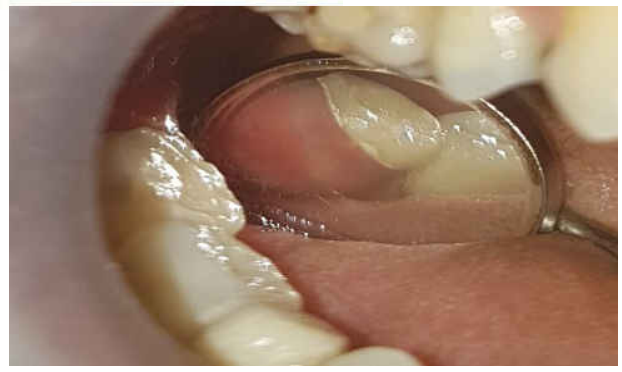


Right lateral view

PRE OPERATIVE MEASUREMENTS

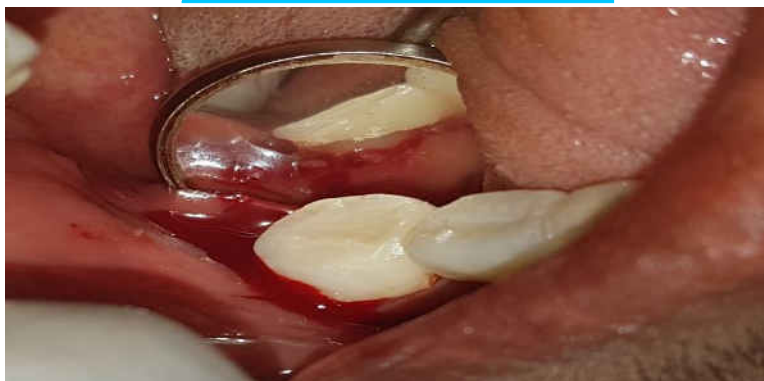


PPD- 5 mm in distolingual aspect of 47



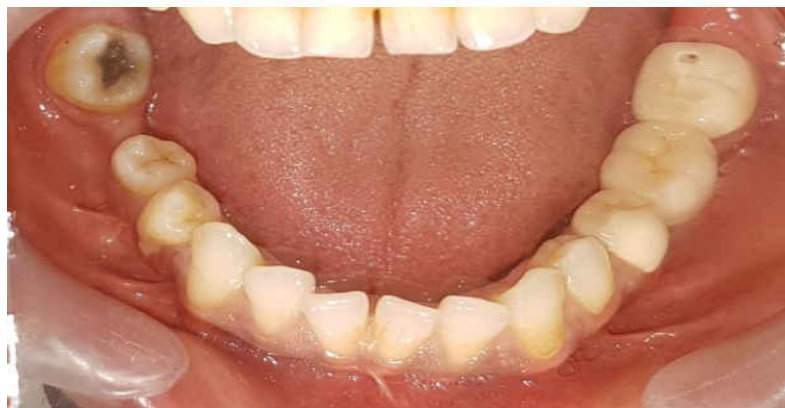Insufficient distal and lingual crown height

OPERATIVE PHOTO

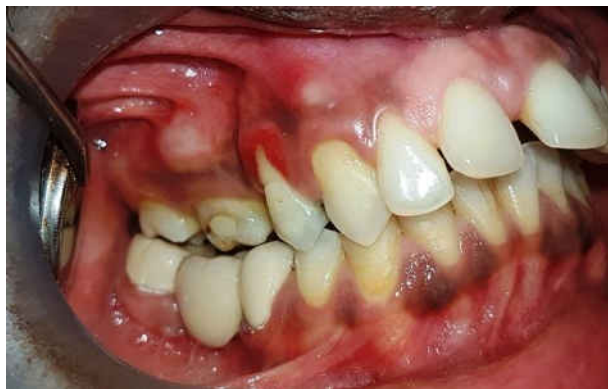

Gingivectomy done in relation to lingual aspect of 47

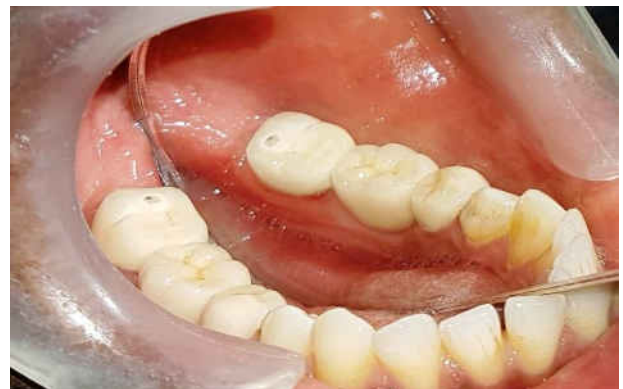POST OPERATIVE PHOTO



Occlusal view



Right lateral view



Lingual view

Case-12

DEMOGRAPHIC DATA

PATIENT NAME: Mr. Magesh

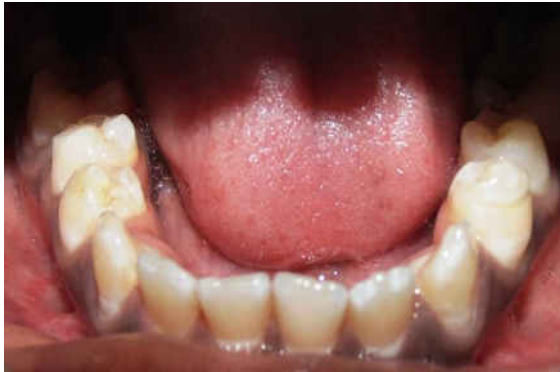DATE: 15.12.2017

OP NO: 201711170002

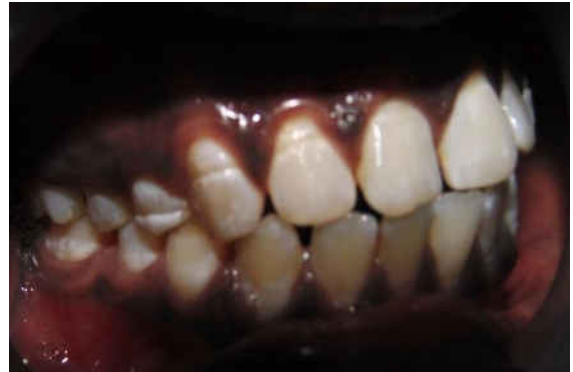AGE/SEX: 23/M

PROCEDURE: Crown lengthening done in relation to 47

PRE OPERATIVE PHOTO

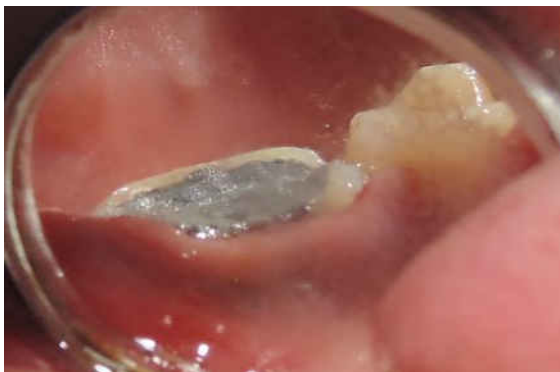

Lower occlusal view

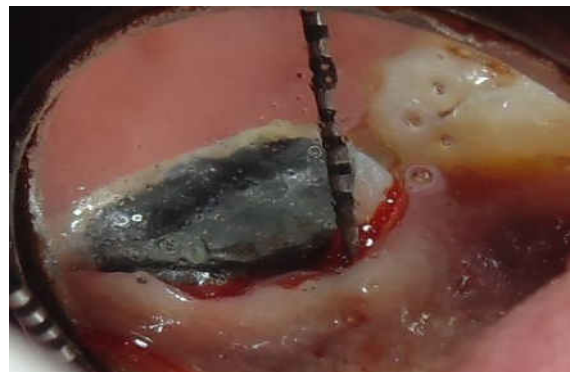

Right lateral view

PRE OPERATIVE MEASUREMENTS

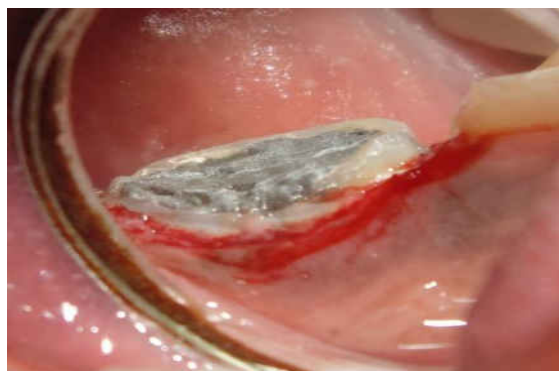

Insufficient lingual crown height



PPD- 3mm in midbuccal aspect of 47

OPERATIVE PHOTO



Gingivectomy done in relation to lingual and distal aspect of 47

Case-13

DEMOGRAPHIC DATA

PATIENT NAME: Mr. Jeeva

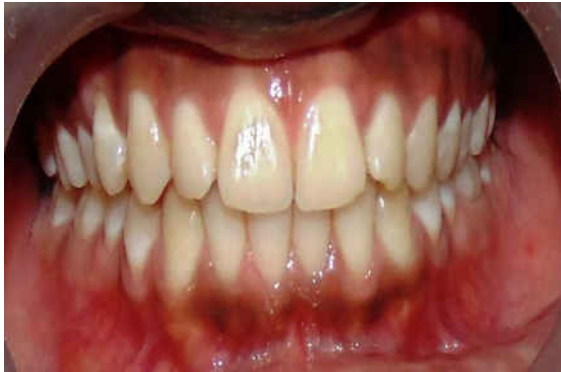DATE: 6.1.2018

OP NO: 20160820154

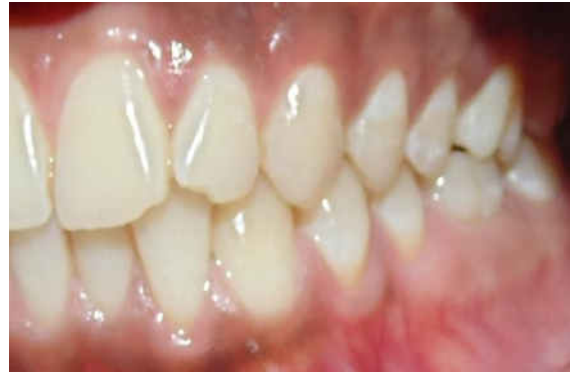AGE/SEX: 26/M

PROCEDURE: Crown lengthening done in relation to 36

PRE OPERATIVE PHOTO

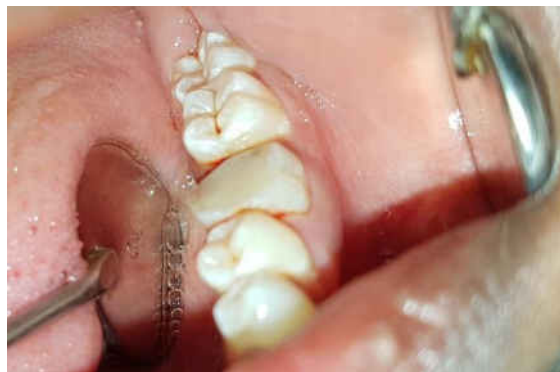

Frontal view



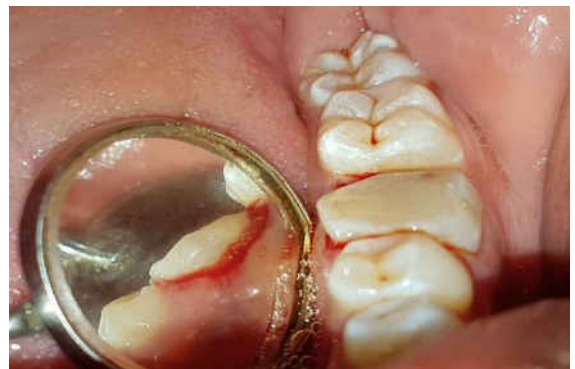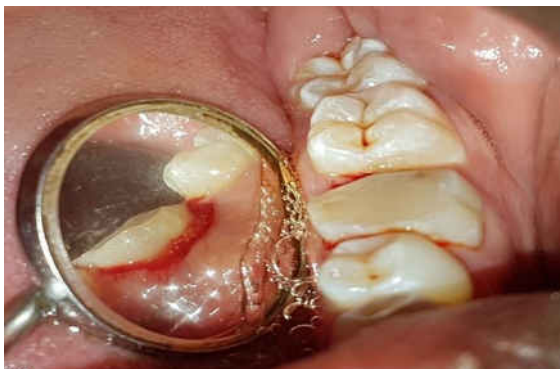Left lateral view

PRE OPERATIVE MEASUREMENTS



Insufficient lingual crown height

OPERATIVE PHOTO



Gingivectomy done in relation to lingual aspect of 36

Case-14

DEMOGRAPHIC DATA

PATIENT NAME: Mr. Chinnaswamy

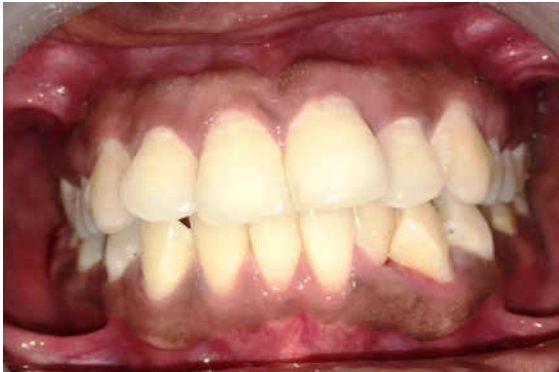DATE: 7.2.2018

OP NO: 201801220027

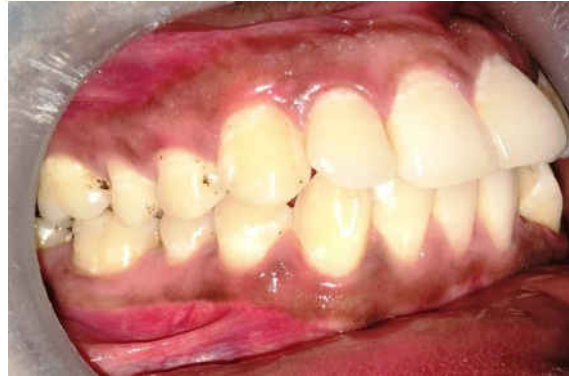AGE/SEX: 24/M

PROCEDURE: Gingivectomy done in relation to 47

PRE OPERATIVE PHOTO

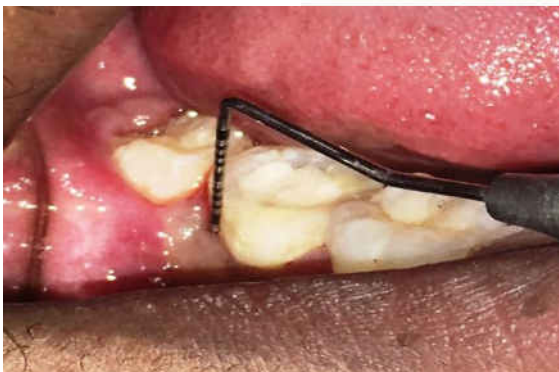

Frontal view

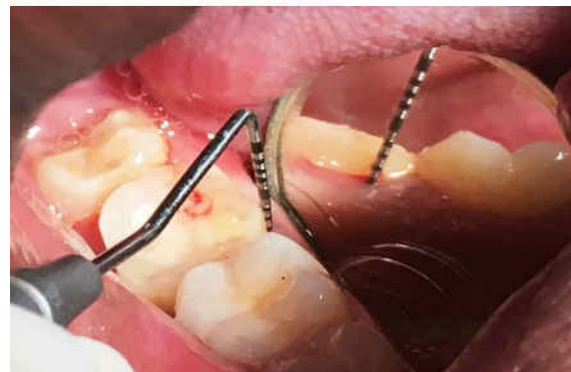

Right lateral view

PRE OPERATIVE MEASUREMENTS

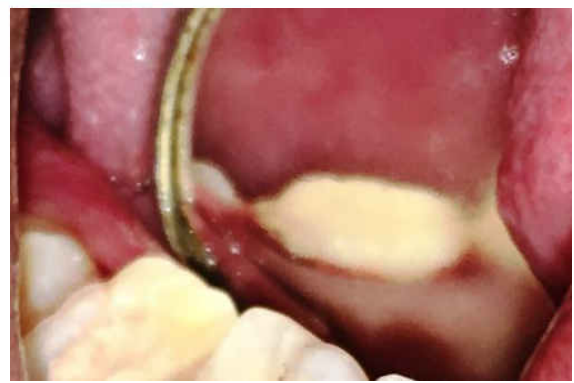
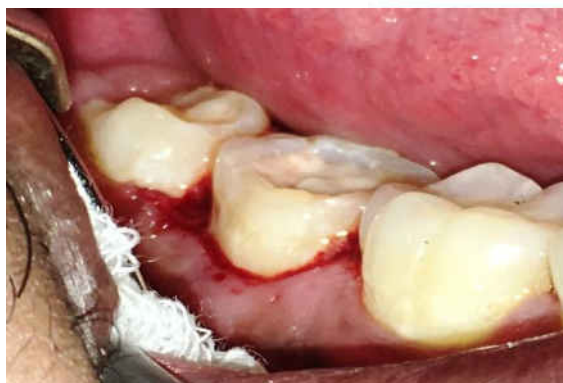
PPD- 3mm in distobuccal aspect of 47



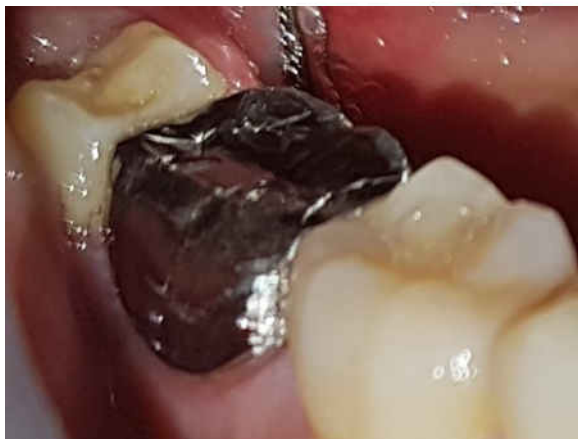
PPD- 3mm in mesiolingual aspect of 47

OPERATIVE PHOTO

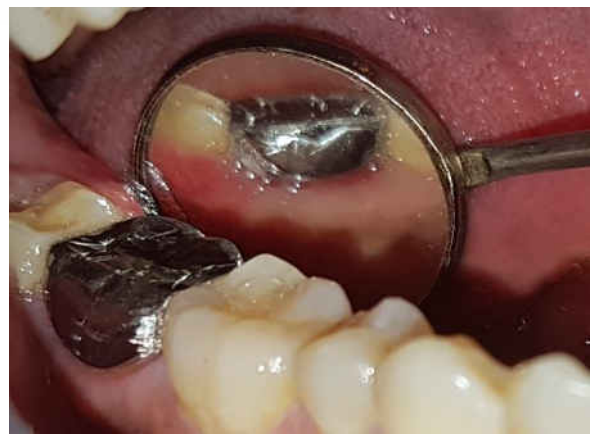

Gingivectomy done in relation to distal and lingual aspect of 47

POST OPERATIVE PHOTO



Buccal view of 47



Lingual view of 47

Case-15

DEMOGRAPHIC DATA

PATIENT NAME: Mr. Sathyanaryan Sao

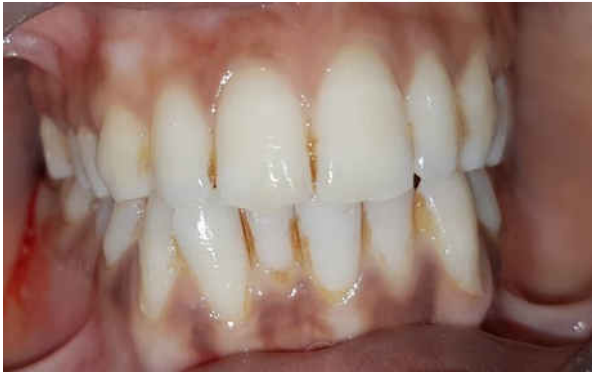DATE: 10.2.2018

OP NO: 201802100102

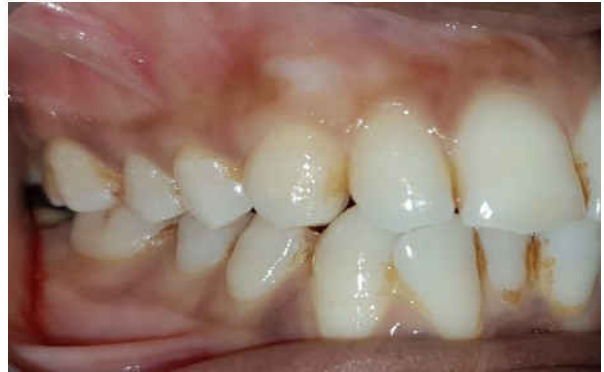AGE/SEX: 21/M

PROCEDURE: Gingivectomy done in relation to 47

PRE OPERATIVE PHOTO

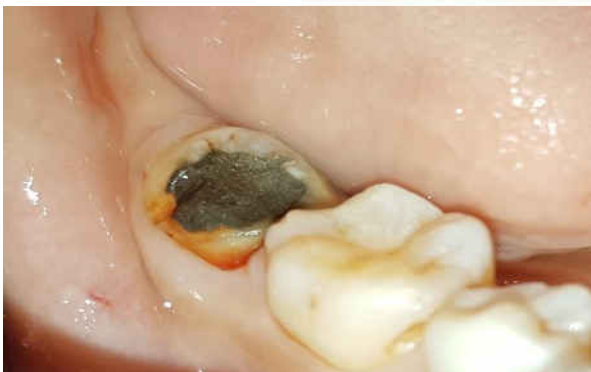

Frontal view

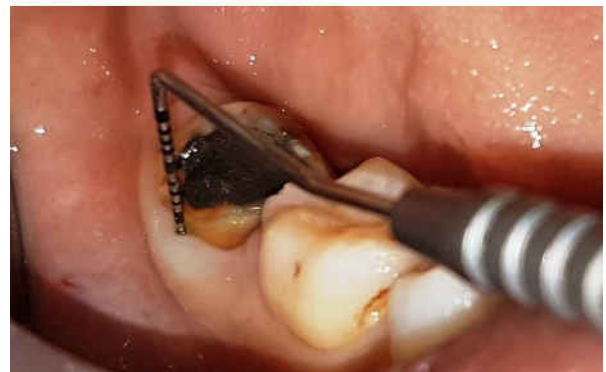

Right lateral view

PRE OPERATIVE MEASUREMENTS

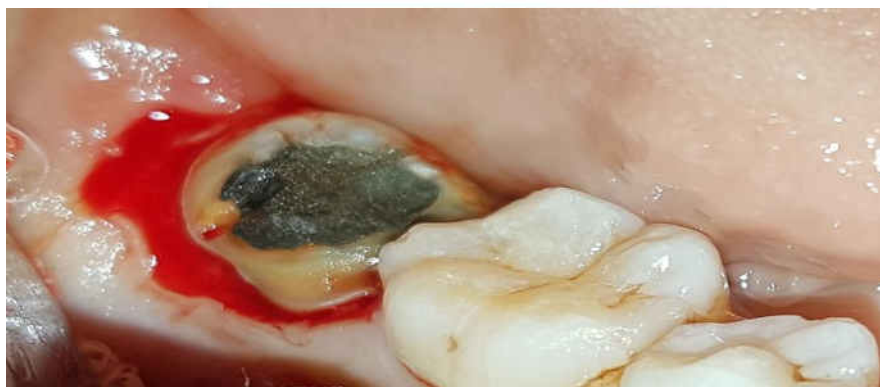

Insufficient buccal crown height



PPD- 3mm in midbuccal aspect of 47

OPERATIVE PHOTO



Gingivectomy done in relation to distal and lingual aspect of 47

Case-16

DEMOGRAPHIC DATA

PATIENT NAME: Mr. Sridhar Kumar

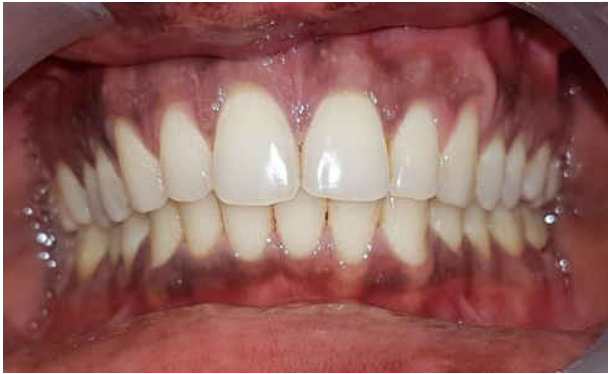DATE: 10.2.2018

OP NO: 201802030190

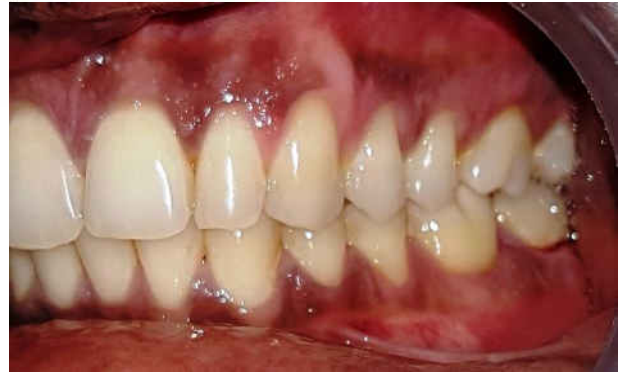AGE/SEX: 34/M

PROCEDURE: Gingivectomy done in relation to 37

PRE OPERATIVE PHOTO

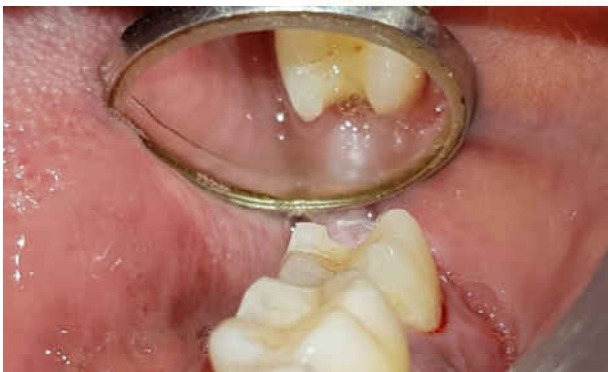

Frontal view

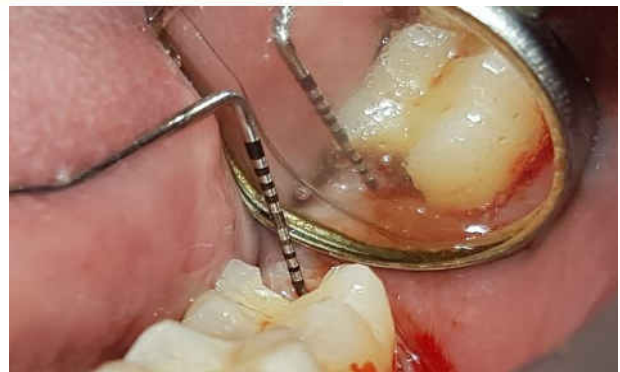

Right lateral view

PRE OPERATIVE MEASUREMENTS

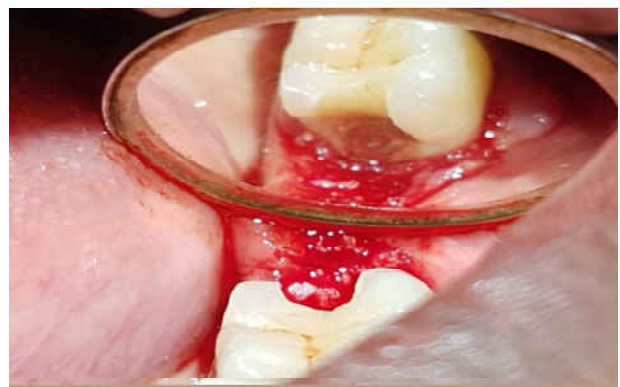
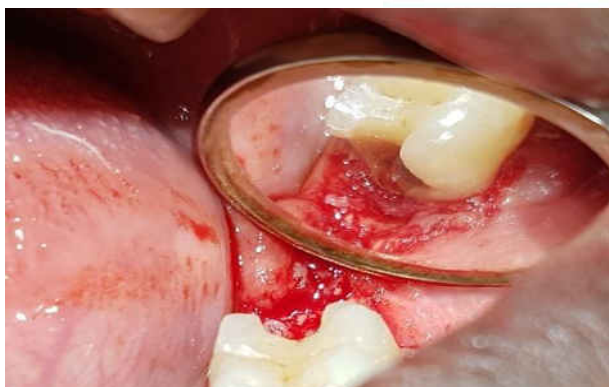

Subgingival cavity in distal aspect of 37



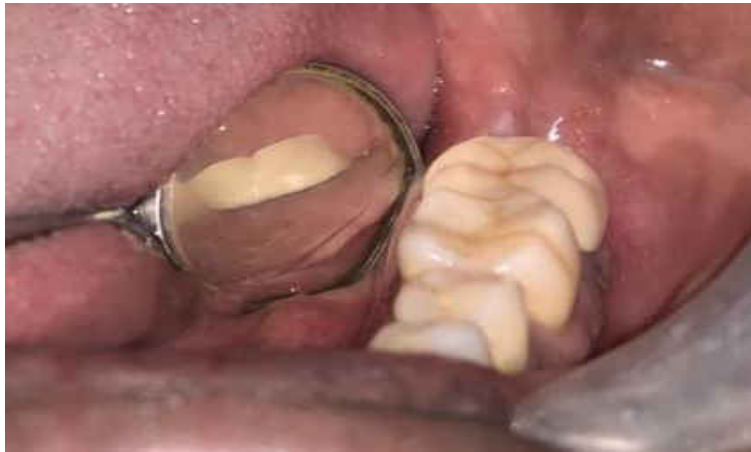Probing depth of 3mm in distal aspect of 37

OPERATIVE PHOTO

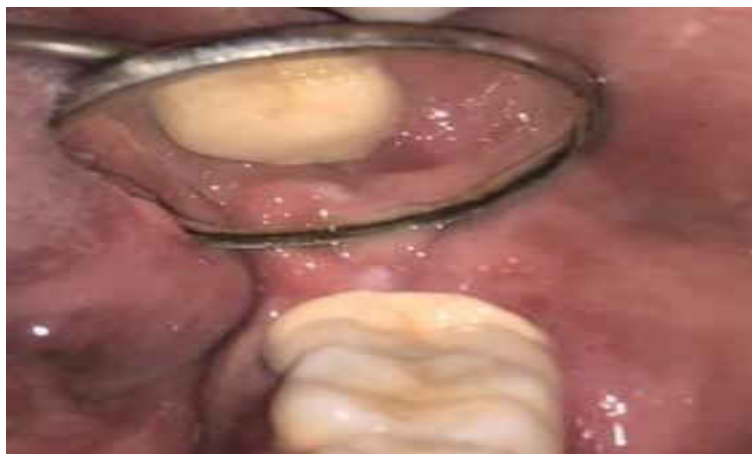

Gingivectomy done in relation to distal aspect of 37

POST OPERATIVE PHOTO



Lingual view of 47



Distal view of 47

Case-17

DEMOGRAPHIC DATA

PATIENT NAME: Mr. Annamalai

DATE: 23.3.2018

OP NO: 201802160052

AGE/SEX: 25/M

PROCEDURE: Crown lengthening done in relation to 47

PRE OPERATIVE PHOTO



Frontal view

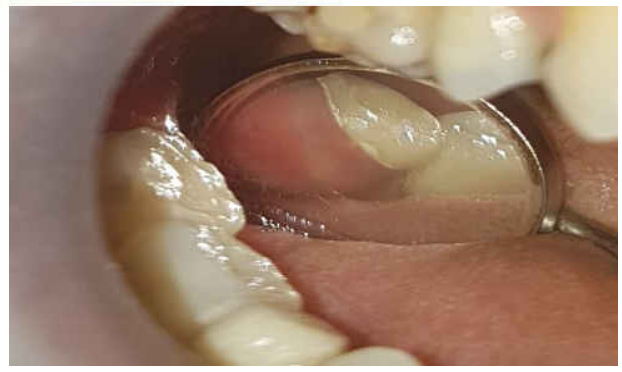


Right lateral view

PRE OPERATIVE MEASUREMENTS

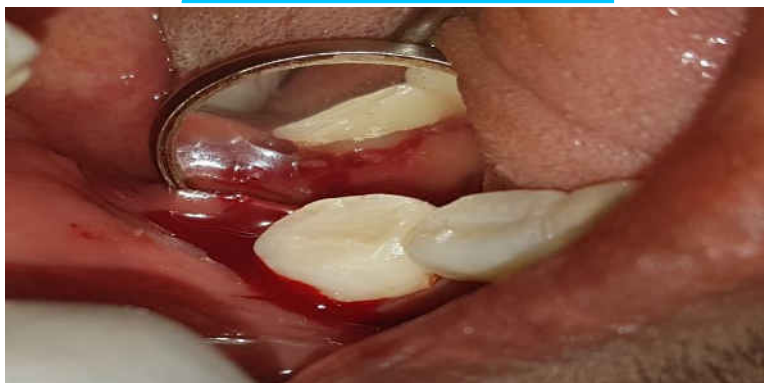


PPD- 5 mm in distolingual aspect of 47



Insufficient distal and lingual crown height

OPERATIVE PHOTO



Gingivectomy done in relation to lingual aspect of 47

POST OPERATIVE PHOTO



Occlusal view



Right lateral view



Lingual view

Case-18

DEMOGRAPHIC DATA

PATIENT NAME: Mr. Ankit Mishra

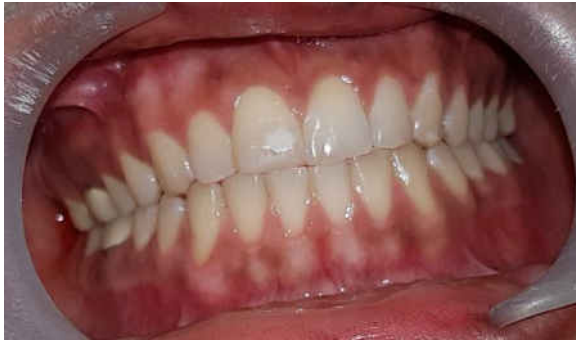AGE/SEX: 21/M

OP NO: 201804210071

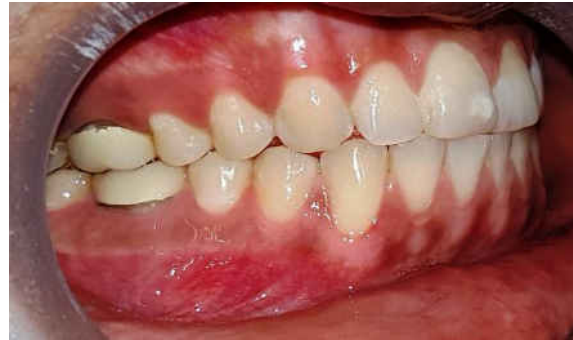DATE : 23.04.2018

PROCEDURE: Gingivectomy done in relation to 47

PRE OPERATIVE PHOTO

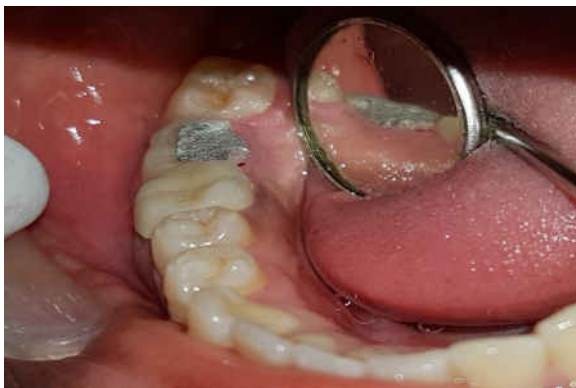

Frontal view

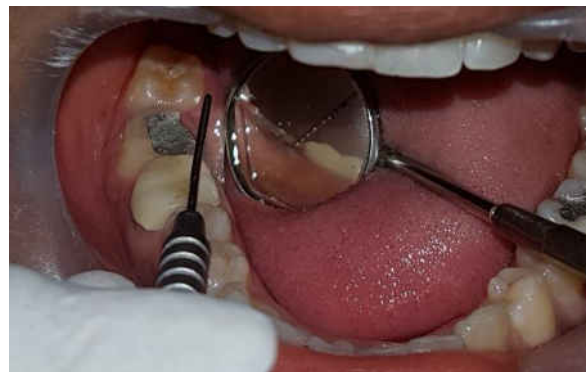

Right lateral view

PRE OPERATIVE MEASUREMENTS

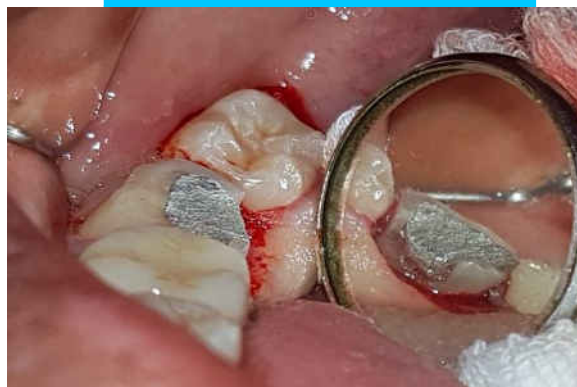

Lingual view



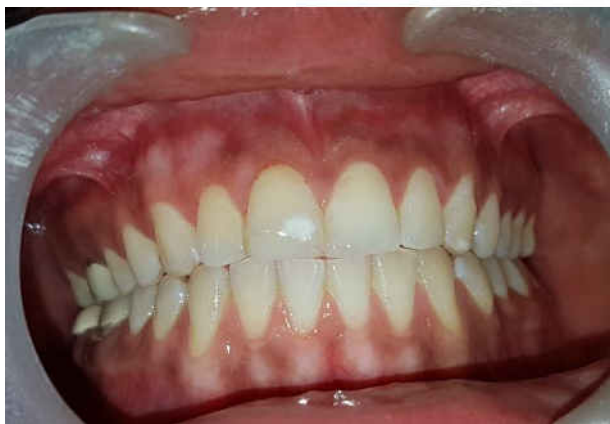PPD- 3mm in mesiolingual aspect of 47

OPERATIVE PHOTO

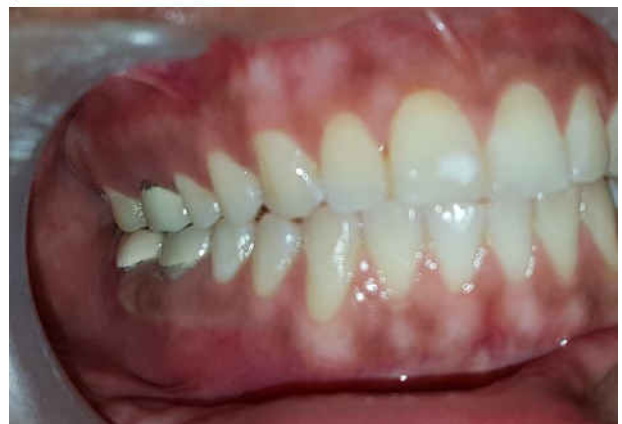

Gingivectomy done in relation to buccal and lingual aspect of 47

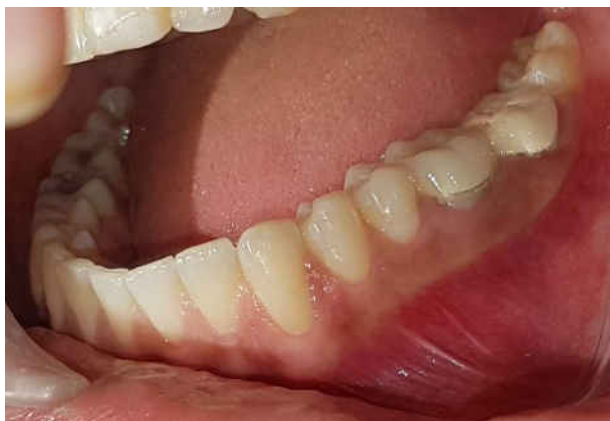POST OPERATIVE PHOTO



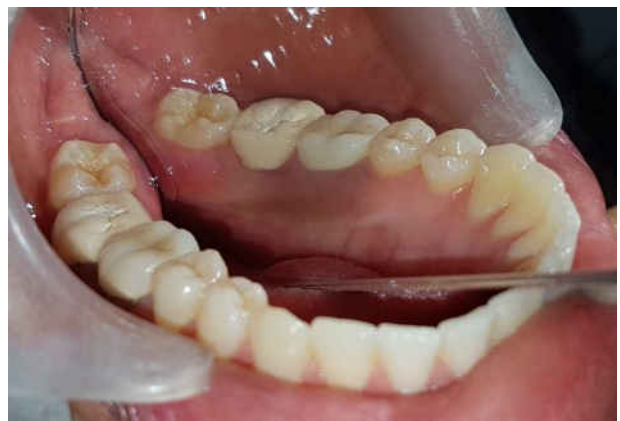Frontal view



Right lateral view



Buccal view



Lingual view

Case-19

DEMOGRAPHIC DATA

PATIENT NAME: Mrs. Umapathi

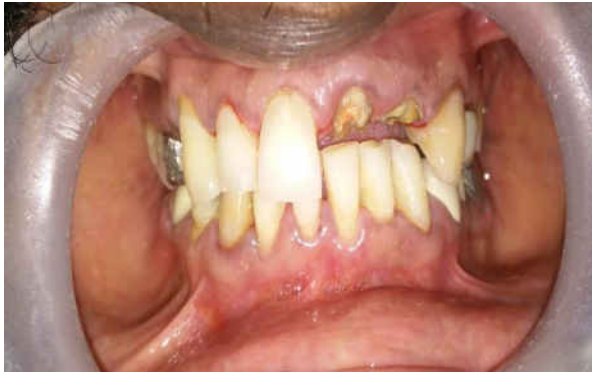DATE: 23.3.2018

OP NO: 201803140005

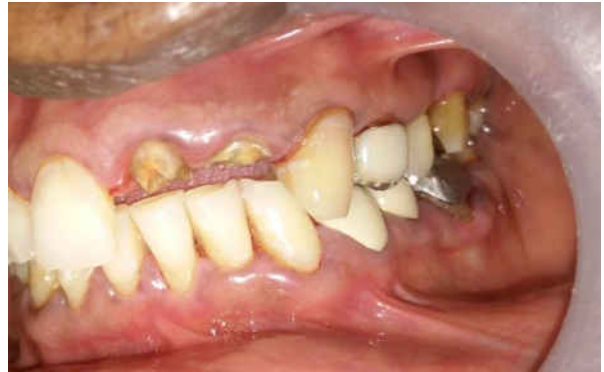AGE/SEX: 62/M

PROCEDURE: Gingivectomy done in relation to 21

PRE OPERATIVE PHOTO

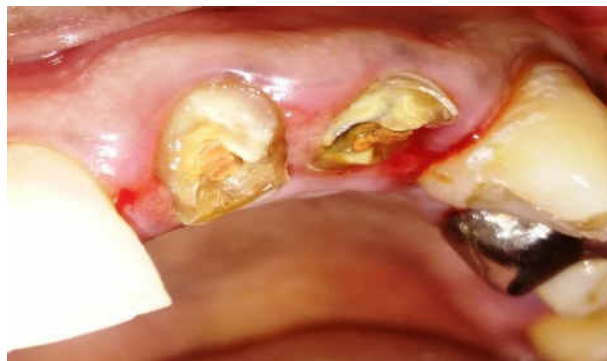

Frontal view



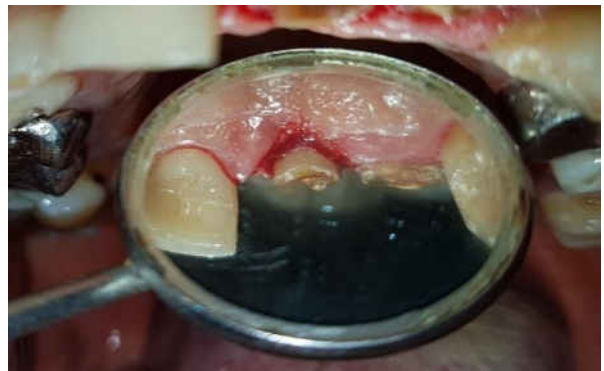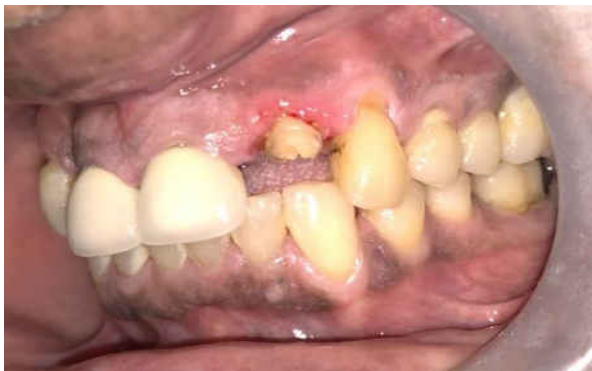Left lateral view

PRE OPERATIVE MEASUREMENTS



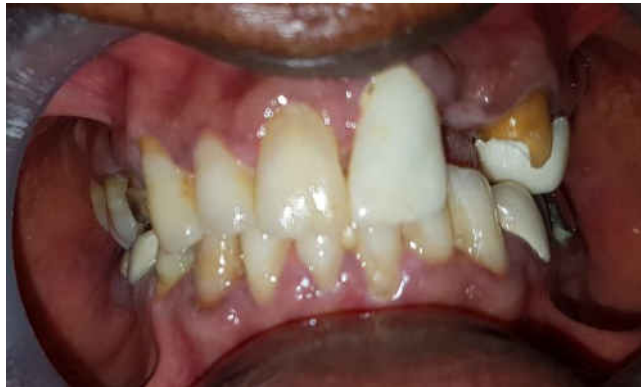Insufficient labial and lingual crown height

OPERATIVE PHOTO

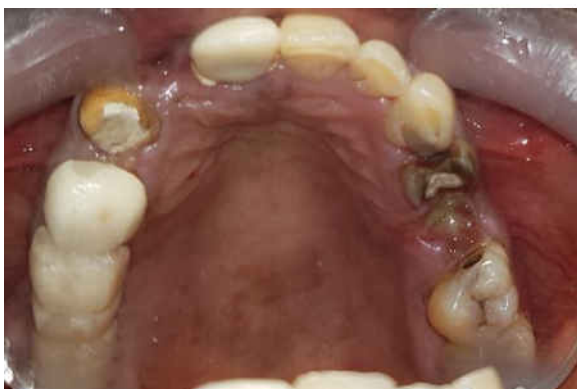

Gingivectomy done in relation to labial and lingual aspect of 21

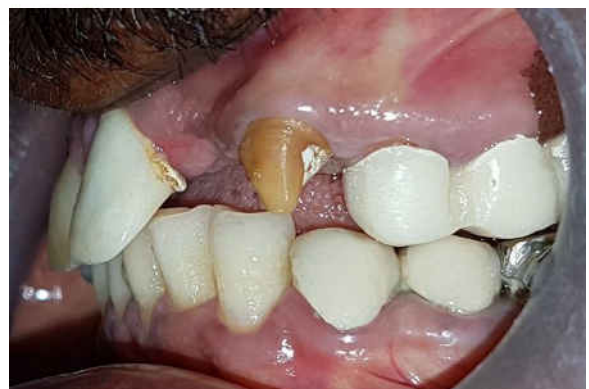POST OPERATIVE PHOTO



Frontal view



Occlusal view



Left lateral view

Case-20

DEMOGRAPHIC DATA

PATIENT NAME: Mrs. Vasugi

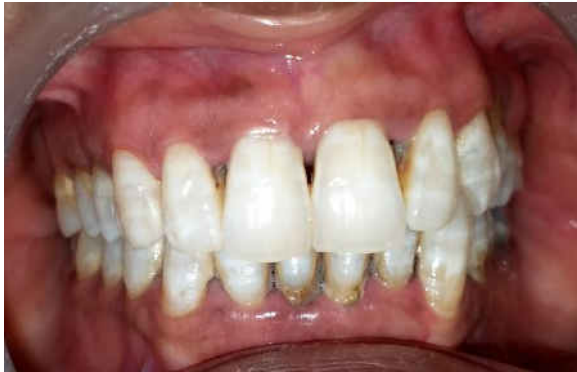DATE: 11.6.2018

OP NO: 2018060110051

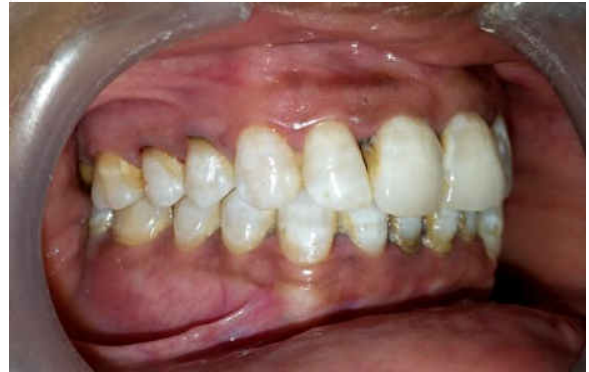AGE/SEX: 41/F

PROCEDURE: Excision of gingival poly done in relation to 17

PRE OPERATIVE PHOTO

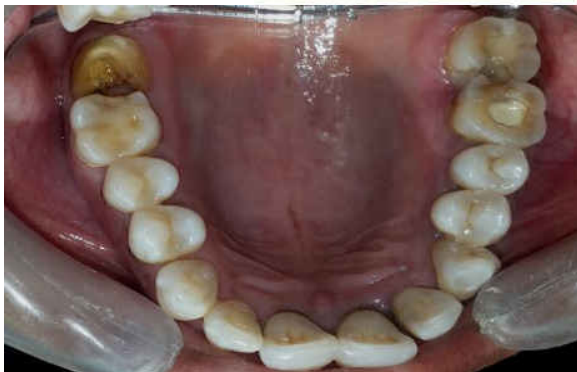

Frontal view

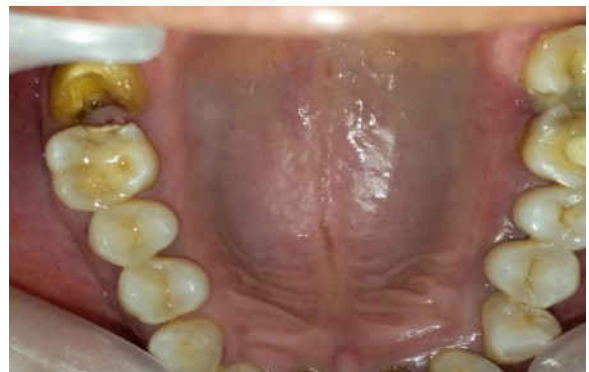

Right lateral view

PRE OPERATIVE PHOTO

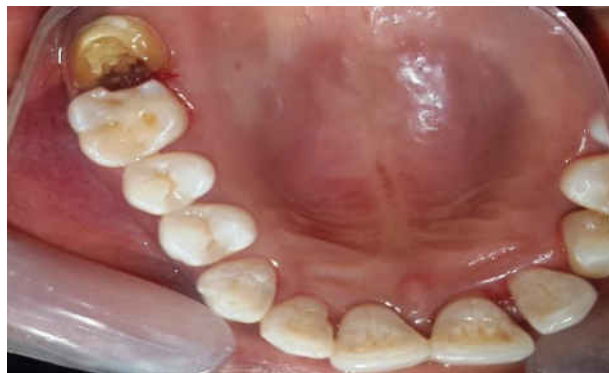

Maxillary Occlusal view



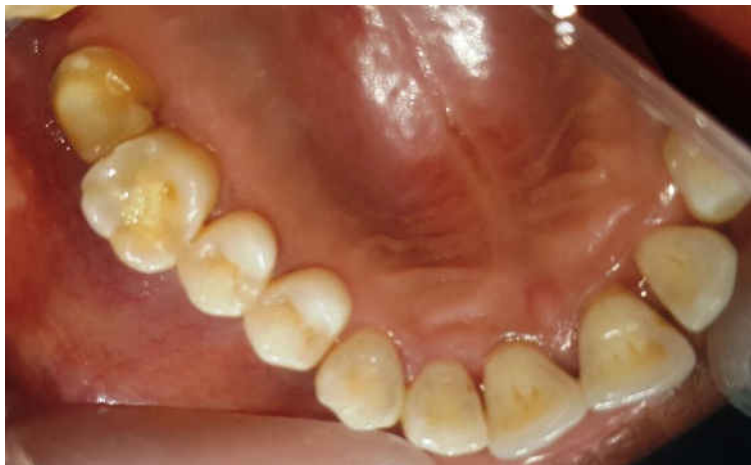Gingival polyp in 17

OPERATIVE PHOTO



Excision of gingival polyp done in relation to 17

POST OPERATIVE PHOTO- 1 WEEK



Occlusal view

Case-21

DEMOGRAPHIC DATA

PATIENT NAME: Mrs. Chandra

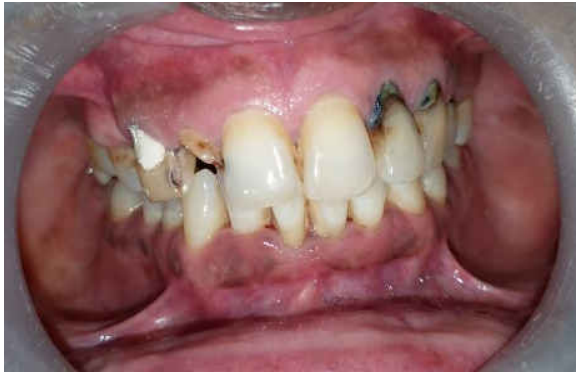DATE: 3.7.2018

OP NO: 201806040044

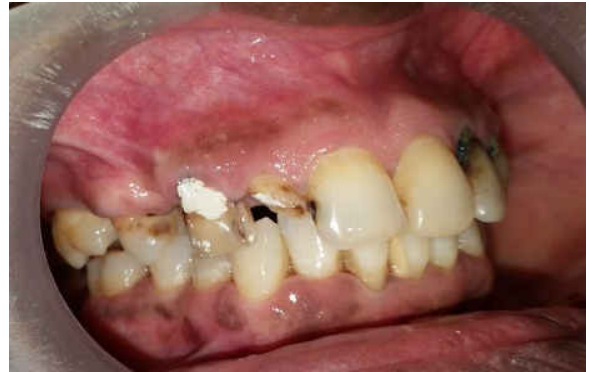AGE/SEX: 65/F

PROCEDURE: Gingivectomy done in relation to 12

PRE OPERATIVE PHOTO

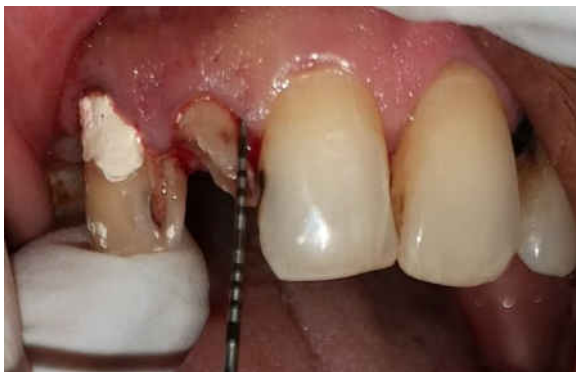

Frontal view

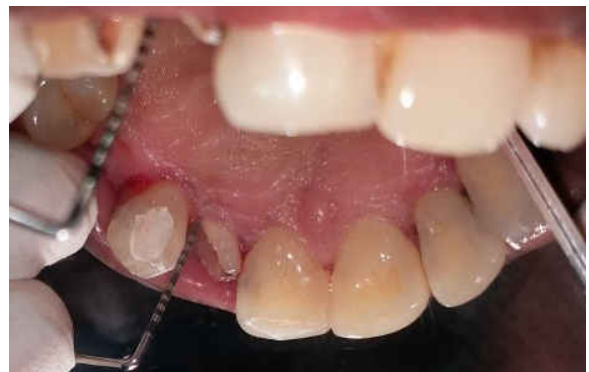

Right lateral view

PRE OPERATIVE MEASUREMENTS

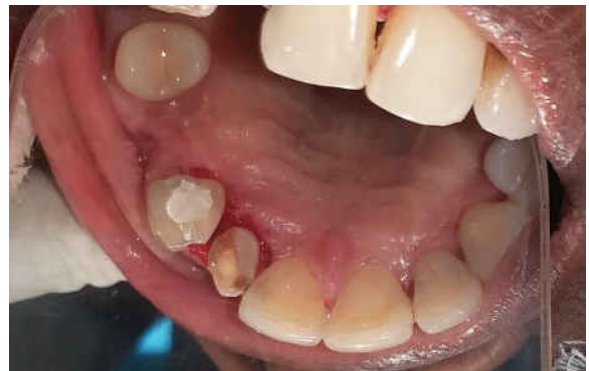
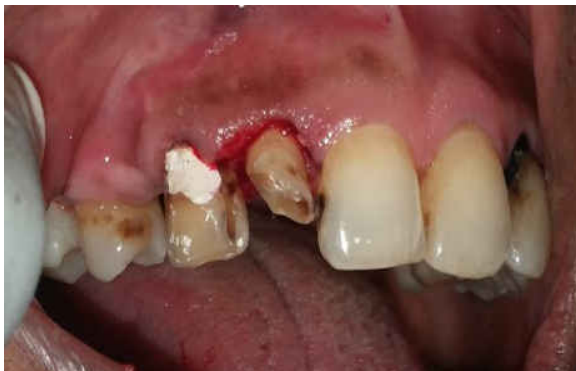
PPD 3 mm in mesiolabial aspect 12



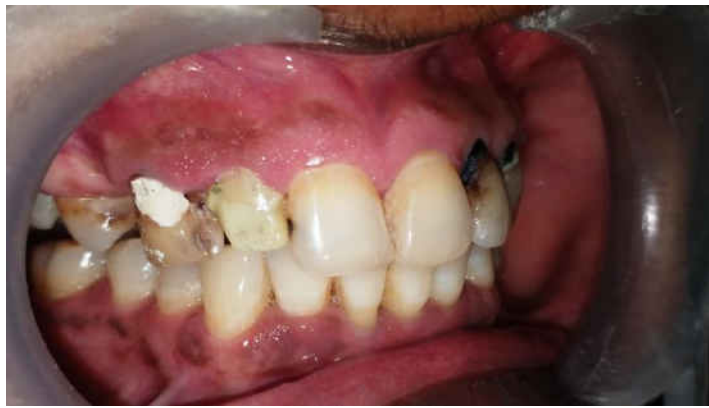PPD 4 mm in distopalatal aspect 12

OPERATIVE PHOTO

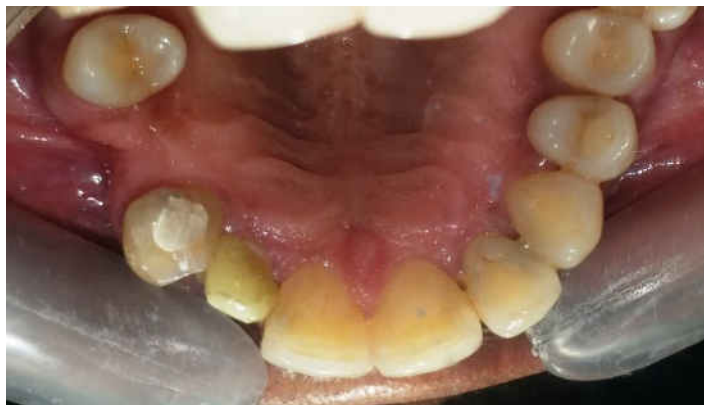

Gingivectomy done in relation to labial and palatal aspect of 12

POST OPERATIVE PHOTO



Frontal view



Occlusal view

Case-22

DEMOGRAPHIC DATA

PATIENT NAME: Mrs. Sarala Anil

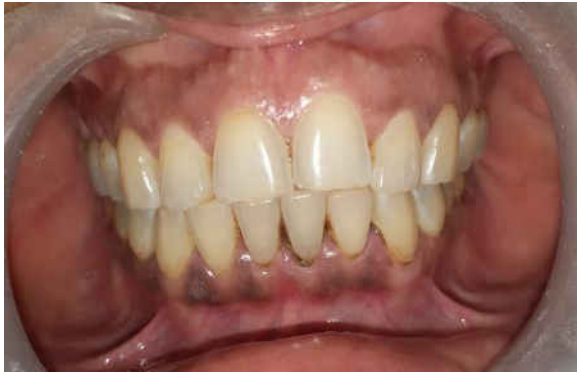DATE: 4.7.2018

OP NO: 201806200038

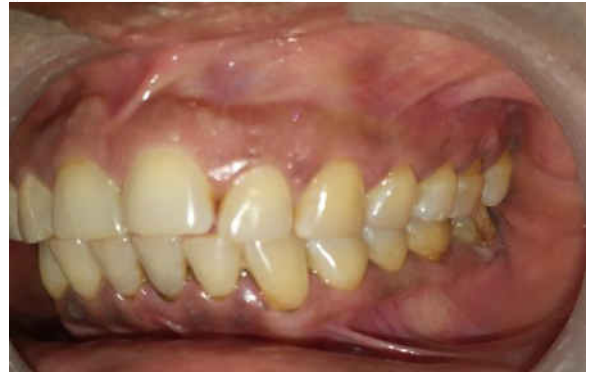AGE/SEX: 55/F

PROCEDURE: Gingivectomy done in relation to 37

PRE OPERATIVE PHOTO

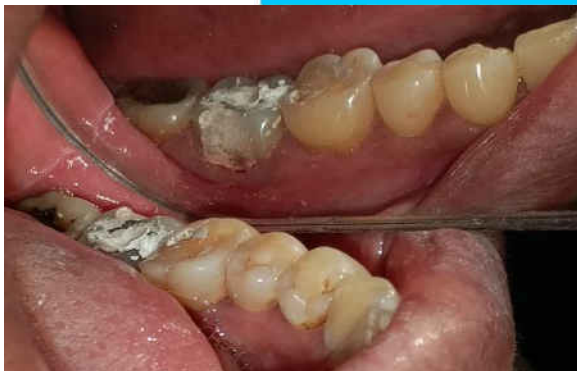

Frontal view

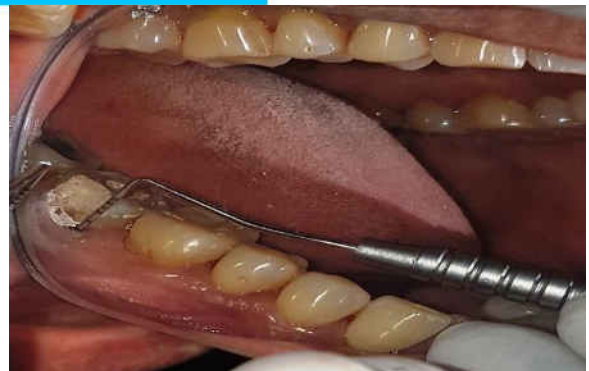

Left lateral view

PRE OPERATIVE PHOTO

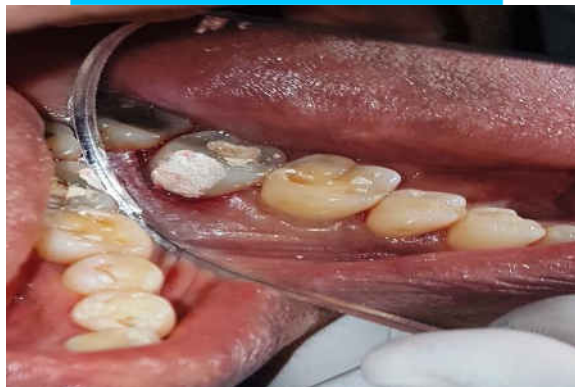

Buccal view



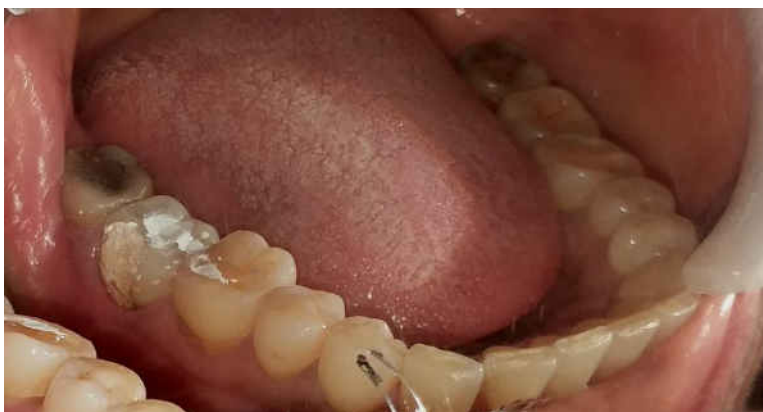PPD- 3mm in mesiobuccal aspect of 37

OPERATIVE PHOTO



Gingivectomy done in relation to buccal aspect of 37

POST OPERATIVE PHOTO- 1 WEEK



Buccal view

Case-13

DEMOGRAPHIC DATA

PATIENT NAME: Mr. Barath kumar

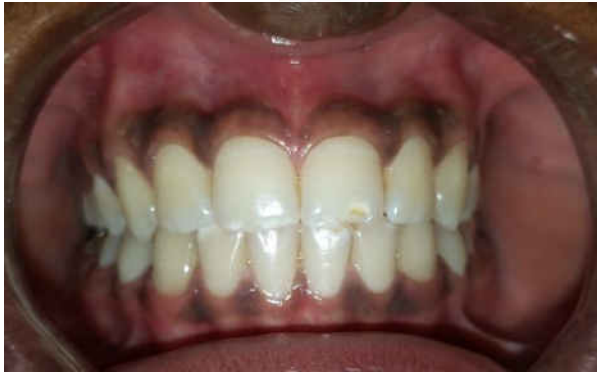DATE: 16.7.2018

OP NO: 201807140090

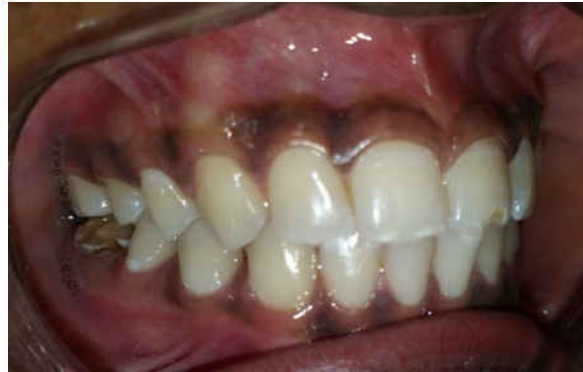AGE/SEX: 16/M

PROCEDURE: Gingivectomy done in relation to 46

PRE OPERATIVE PHOTO

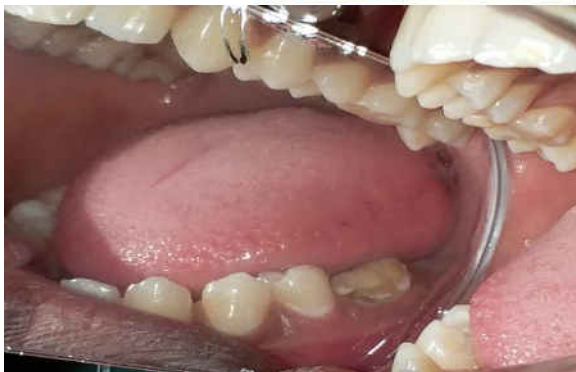

Frontal view

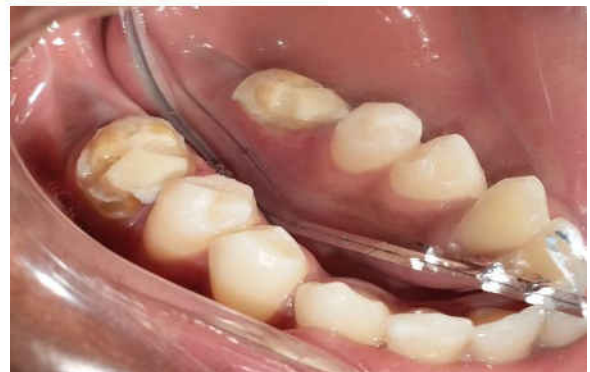

Right lateral view

PRE OPERATIVE PHOTO

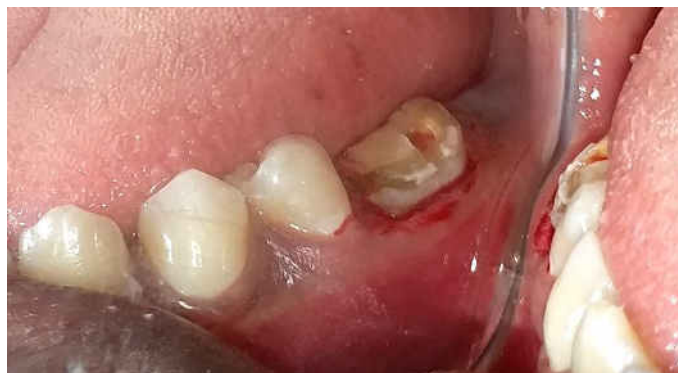

Buccal view



Lingual view

OPERATIVE PHOTO



Gingivectomy done in relation to buccal aspect of 46

Case-14

DEMOGRAPHIC DATA

PATIENT NAME: Mr. Srinivas

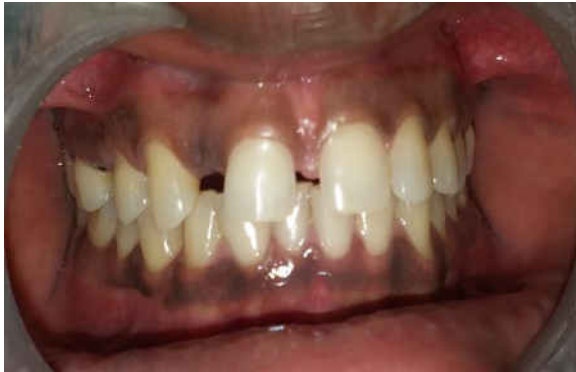DATE: 21.7.2018

OP NO: 201803260001

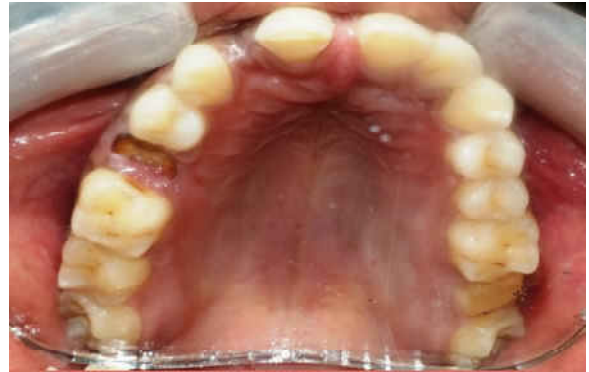AGE/SEX: 33/M

PROCEDURE: Gingivectomy done in relation to 27

PRE OPERATIVE PHOTO

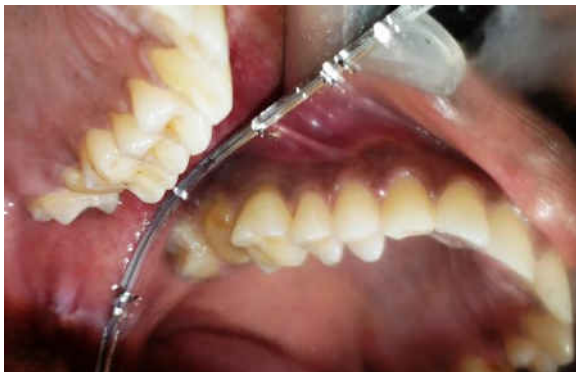

Frontal view

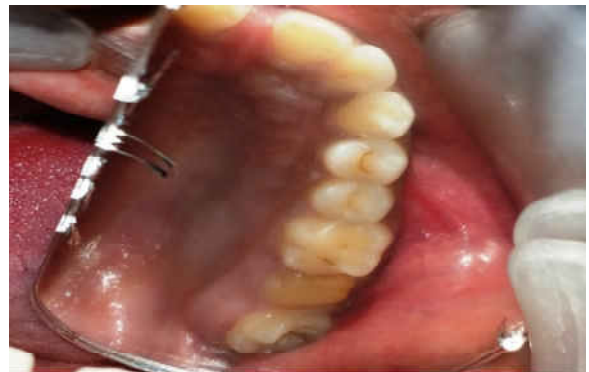


Left lateral view

PRE OPERATIVE PHOTO

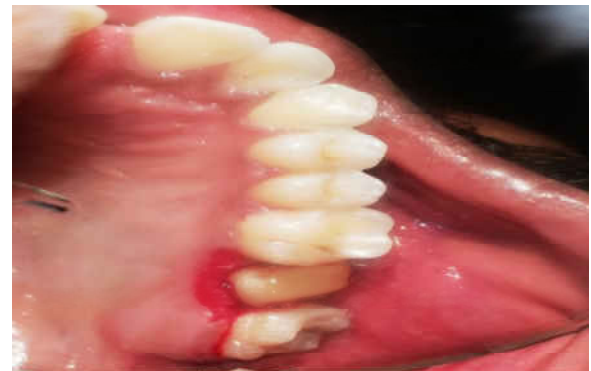
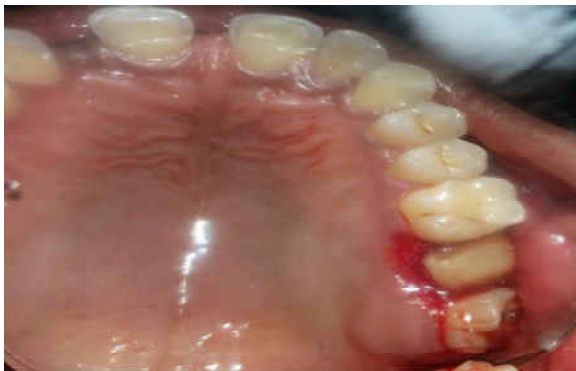
Buccal view



Palatal view

OPERATIVE PHOTO



Gingivectomy done in relation to buccal and palatal aspect of 27

CASE-15

DEMOGRAPHIC DATA

PATIENT NAME : Mr.Manohar

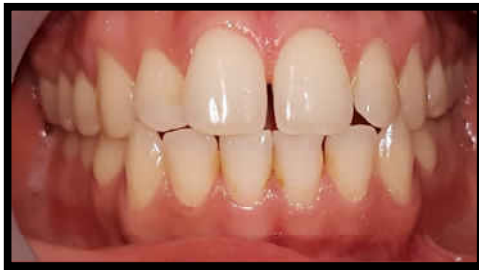DATE:11.6.18

OP NO: 201806050030

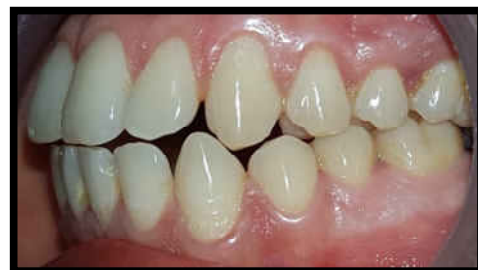AGE/SEX:33/M

PROCEDURE: Crown lengthening done in relation to 37

PRE OPERATIVE PHOTO -11.6.18

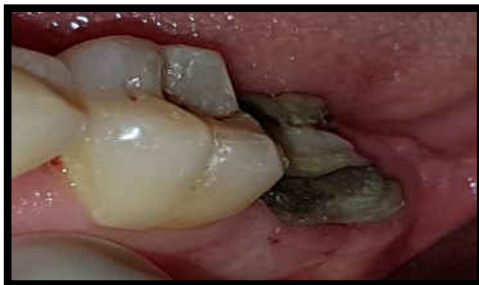

Frontal View

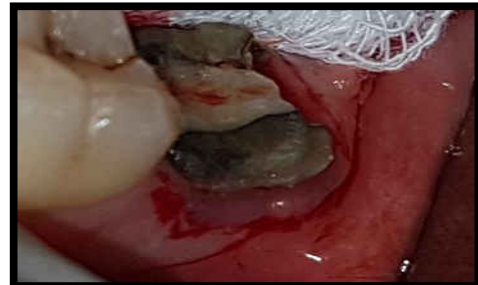

Left Lateral

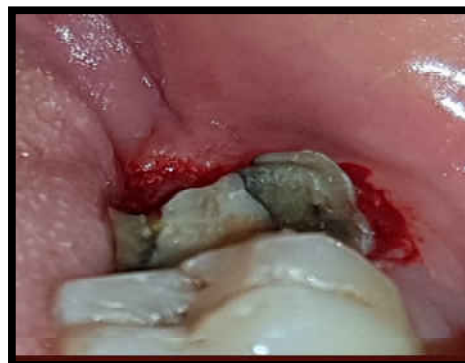OPERATIVE PHOTOS-11.6.18



37-pocket Markings

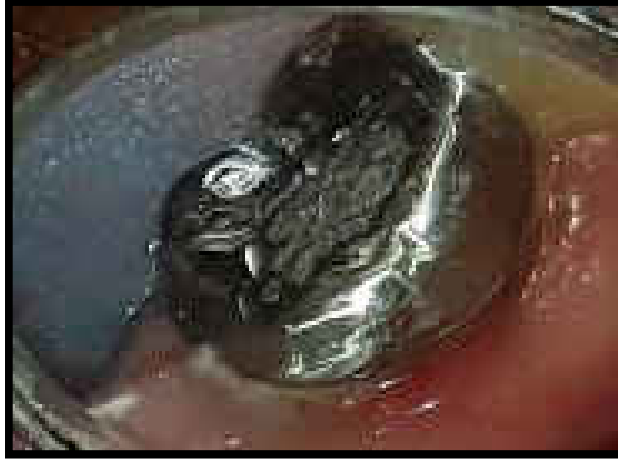

37 External Bevel Incision- Buccal Aspect

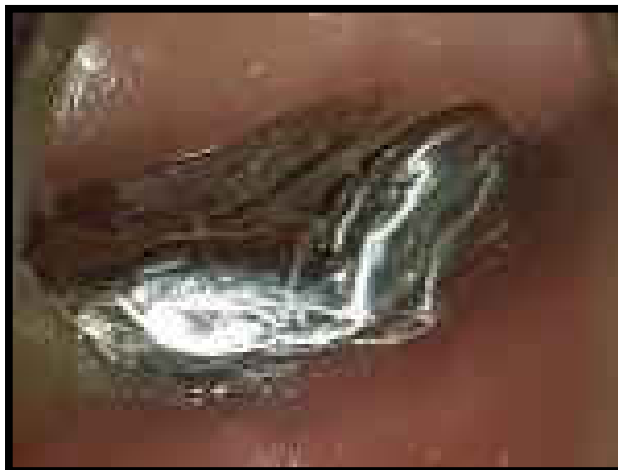

Immediate Post-operative

POST-OPERATIVE PHOTOS
19.7.18



BUCCAL ASPECT 37



LINGUAL ASPECT 37

CASE-16

DEMOGRAPHIC DATA

PATIENT NAME : Mrs.Shakila

DATE:7.7.18

OP NO: 201806230055

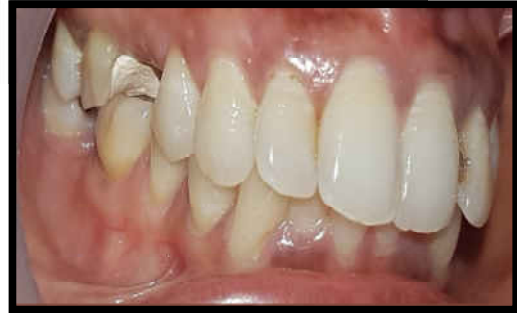AGE/SEX:38/F

PROCEDURE: Crown lengthening done in relation to 16

PRE OPERATIVE PHOTO -7.7.18



Frontal View

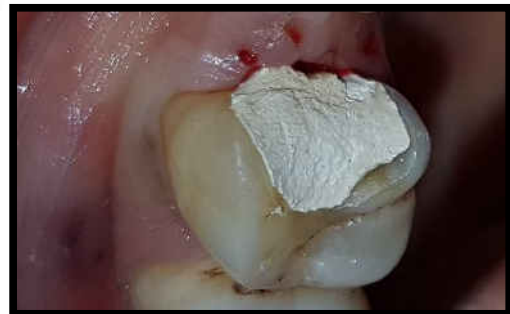

Right Lateral

OPERATIVE PHOTOS-7.7.18



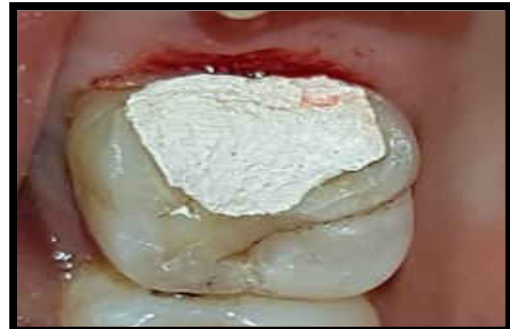16-Insufficient clinical crown height



16-Pocket Markings



16 External Bevel Incision- Labial Aspect



Immediate Post-operative

POST-OPERATIVE PHOTOS
18.6.18



MESIAL ASPECT 16



OCCLUSAL ASPECT 16

CASE-17

DEMOGRAPHIC DATA

PATIENT NAME : Mr. Vijay

DATE:18.4.18

OP NO: 201803300039

AGE/SEX:32/M

PROCEDURE: Gingivectomy done in relation to 26,27

PRE OPERATIVE PHOTO -18.4.18

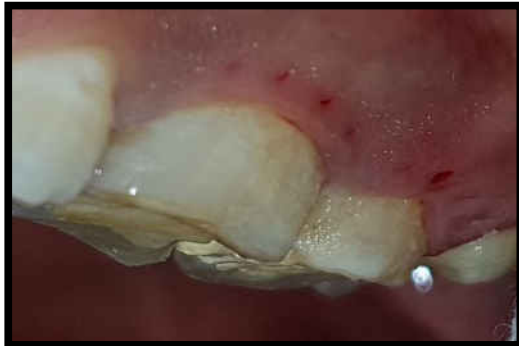

FRONTAL VIEW

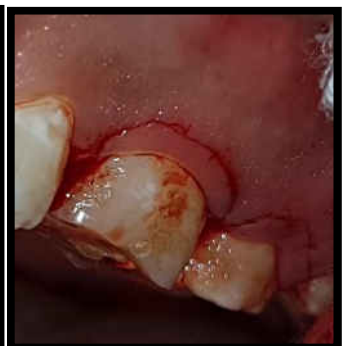
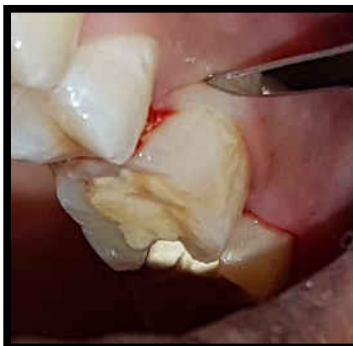

INSUFFICIENT CROWN HEIGHT-26,27

OPERATIVE PHOTOS-18.4.18



26,27-POCKET MARKINGS



26,27-EXTERNAL BEVEL INCISION-
BUCCAL ASPECT



IMMEDIATE POST-OPERATIVE

1 MONTH POST-OPERATIVE
PHOTOS



BUCCAL ASPECT 26,27



LINGUAL ASPECT 26,27

CASE-18

DEMOGRAPHIC DATA

PATIENT NAME: MS. NAGALAKSHMI

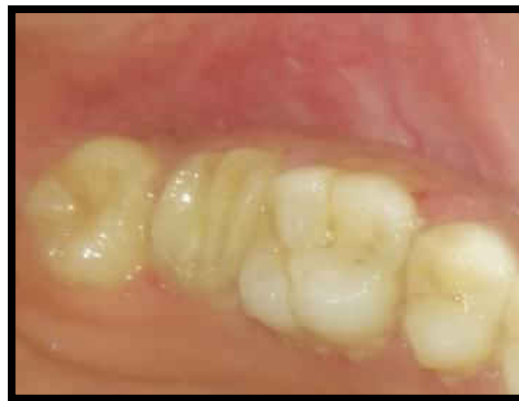DATE: 02.08. 2018

OP NO: 201802090010

AGE/SEX: 20/F

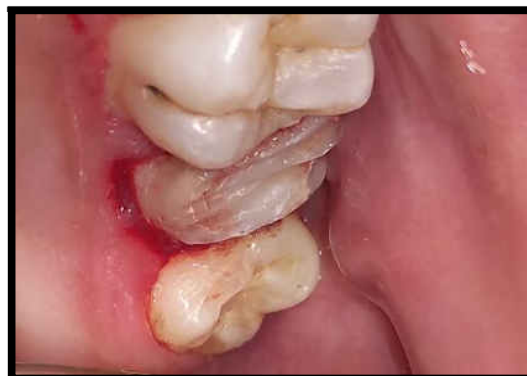PROCEDURE: Crown lengthening in relation to 27

PRE OPERATIVE PHOTOGRAPH



INADEQUATE CROWN HEIGHT IN RELATION TO LINGUAL ASPECT OF 27

OPERATIVE PHOTOGRAPH



EXTERNAL BEVEL CROWN LENGTHENING DONE IN LINGUAL ASPECT OF 27

DEMOGRAPHIC DATA

PATIENT NAME: MS. NAGALAKSHMI

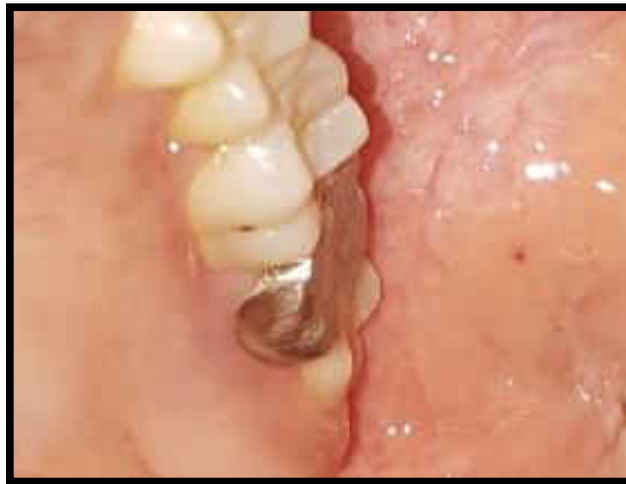DATE: 15.02. 2019

OP NO: 201802090010

AGE/SEX: 20/F

PROCEDURE: Crown lengthening in relation to 27

POST OPERATIVE PHOTOGRAPH- 1 MONTH



CASE-19

DEMOGRAPHIC DATA

PATIENT NAME: MRS. NANDHINI

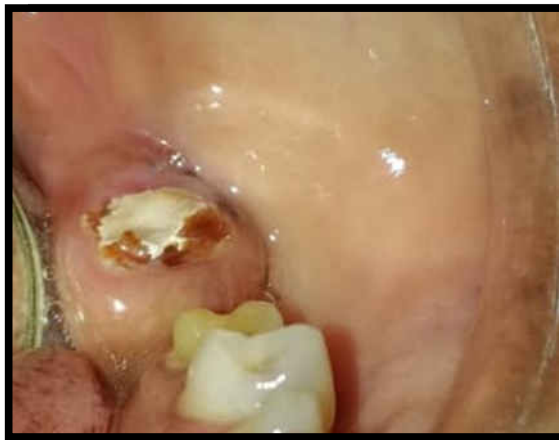DATE: 17.12. 2018

OP NO: 201807190143

AGE/SEX: 44/F

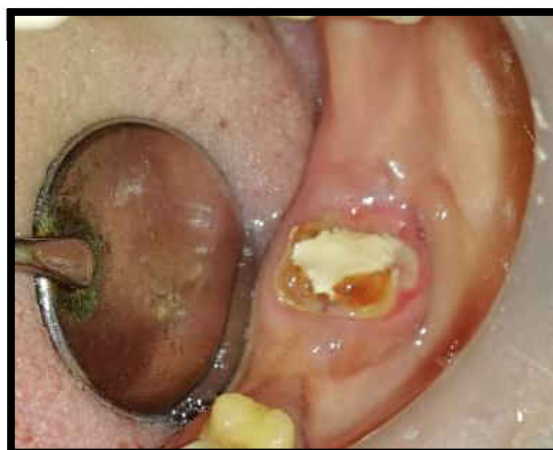
PROCEDURE: Crown lengthening in relation to 37

PRE OPERATIVE PHOTOGRAPH



INADEQUATE CROWN HEIGHT IN RELATION TO 37

POST OPERATIVE PHOTOGRAPH



CROWN LENGTHENING DONE IN RELATION TO 37

DEMOGRAPHIC DATA

PATIENT NAME: MRS. NANDHINI

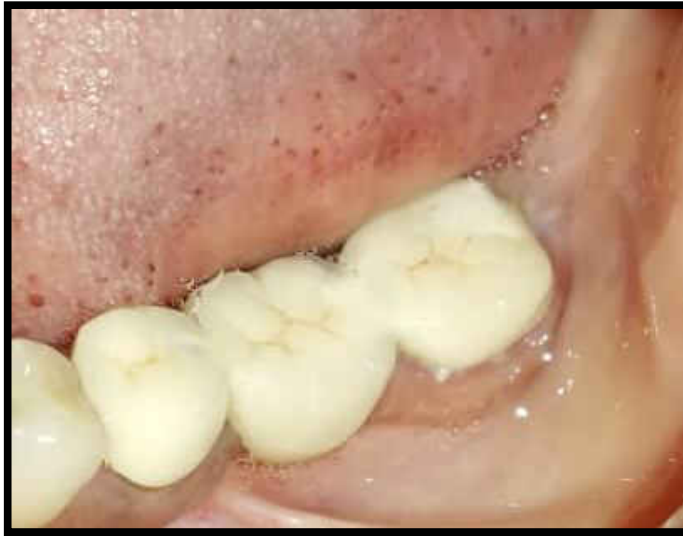DATE: 02.02. 2019

OP NO: 201807190143

AGE/SEX: 44/F

PROCEDURE: Crown lengthening in relation to 37

POST OPERATIVE PHOTOGRAPH- 1 MONTH



CASE-19

DEMOGRAPHIC DATA

PATIENT NAME: MR. PRABAKARAN.A

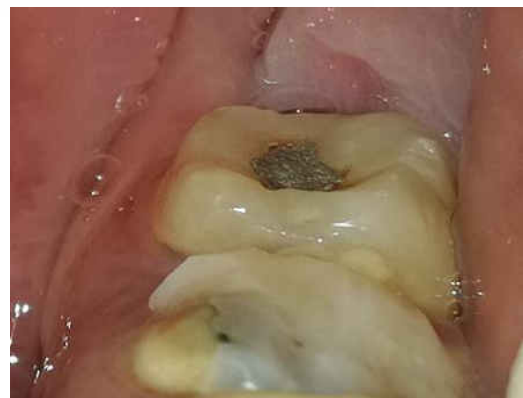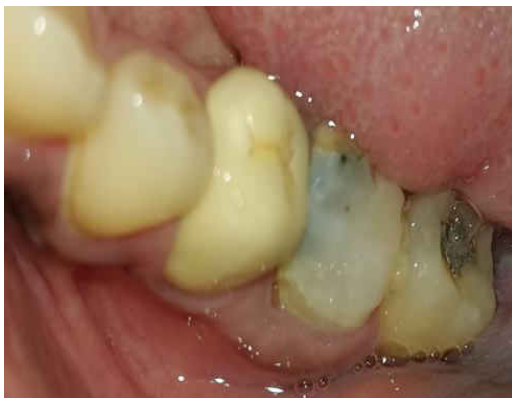DATE: 09.08. 2018

OP NO: 201807280099

AGE/SEX: 36/M

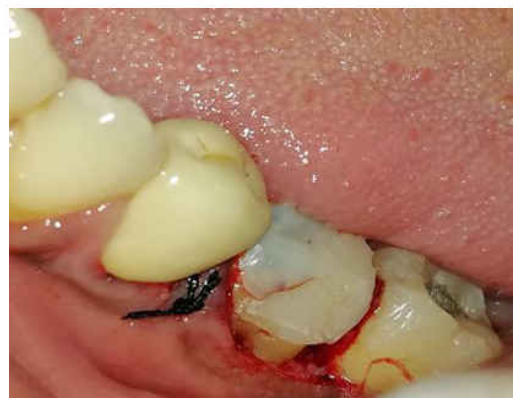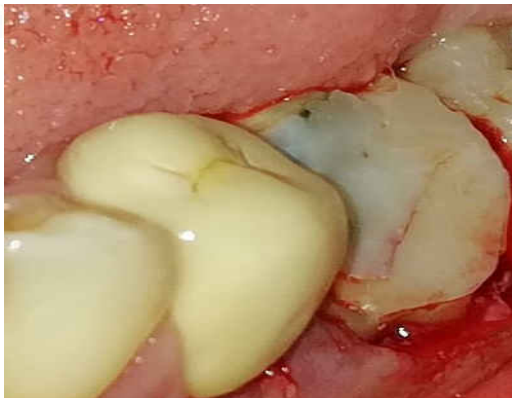PROCEDURE: Crown lengthening in relation to 36

PRE OPERATIVE PHOTOGRAPHS



INADEQUATE CROWN HEIGHT IN RELATION TO BUCCAL AND LINGUAL ASPECT OF 36

OPERATIVE PHOTOGRAPHS



INTERNAL BEVEL CROWN LENGTHENING DONE IN BUCCAL ASPECT OF 36 AND
SUTURES PLACED

DEMOGRAPHIC DATA

PATIENT NAME: MR. PRABAKARAN.A

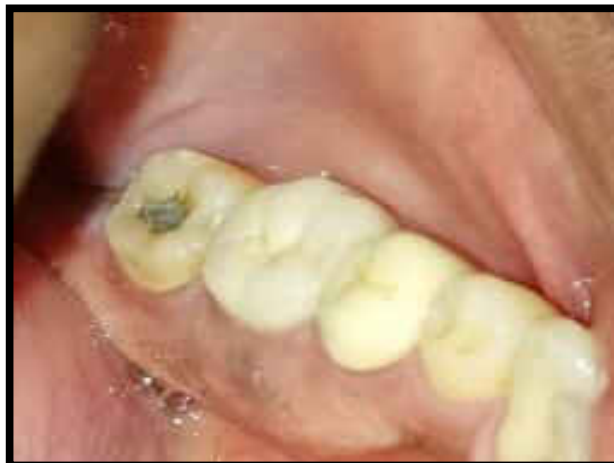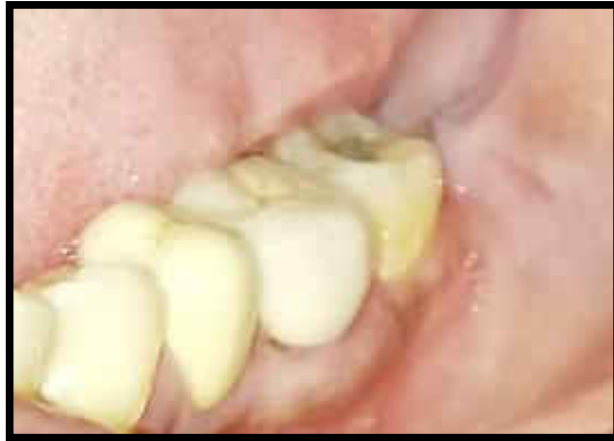DATE: 12.10. 2018

OP NO: 201807280099

AGE/SEX: 36/M

PROCEDURE: Crown lengthening in relation to 36

POST OPERATIVE PHOTOGRAPHS - 1 MONTH



CASE-20

DEMOGRAPHIC DATA

PATIENT NAME: MR. SRIKANT PATRO

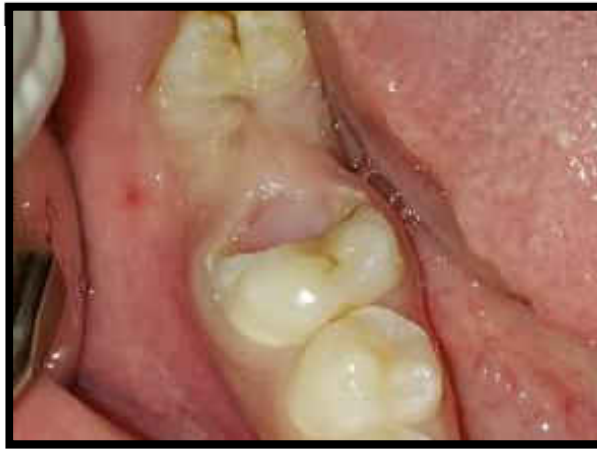DATE: 30.01. 2019

OP NO: 201809080141

AGE/SEX: 25/M

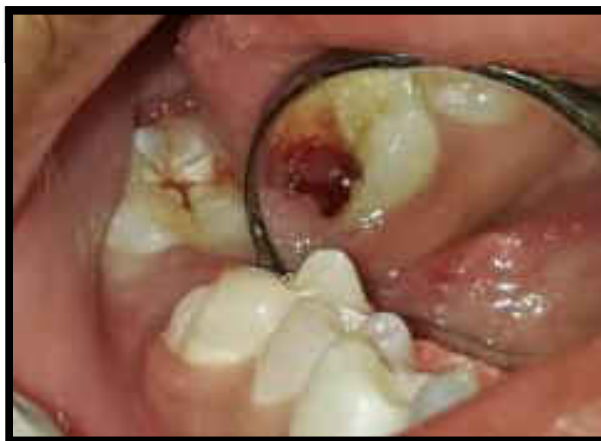PROCEDURE: Excision of pulp polyp in relation to 46

PRE OPERATIVE PHOTOGRAPH



PULP POLYP IN RELATION TO 46

POST OPERATIVE PHOTOGRAPH



EXCISION OF PULP POLYP DONE IN RELATION TO 46

DEMOGRAPHIC DATA

PATIENT NAME: MR. SRIKANT PATRO

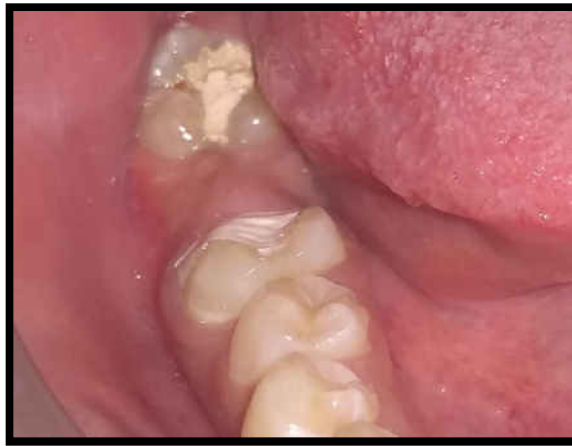DATE: 16.02. 2019

OP NO: 201809080141

AGE/SEX: 25/M

PROCEDURE: Excision of pulp polyp in relation to 46

POST OPERATIVE PHOTOGRAPH- 1 MONTH



CASE-21

DEMOGRAPHIC DATA

PATIENT NAME: MRS. SUDHA

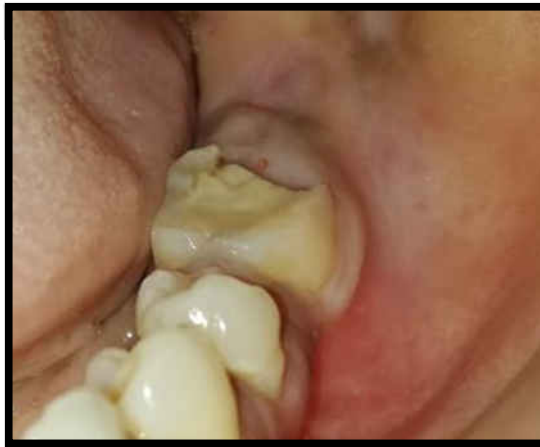DATE: 22.02. 2019

OP NO: 201805190037

AGE/SEX: 27/F

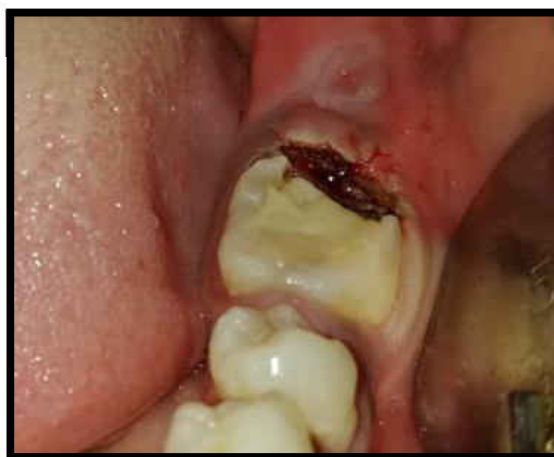PROCEDURE: Crown lengthening in relation to 37

PRE OPERATIVE PHOTOGRAPH



INADEQUATE CROWN HEIGHT IN RELATION TO 37

POST OPERATIVE PHOTOGRAPH



CROWN LENGTHENING DONE IN RELATION TO 37

DEMOGRAPHIC DATA

PATIENT NAME: MRS. SUDHA

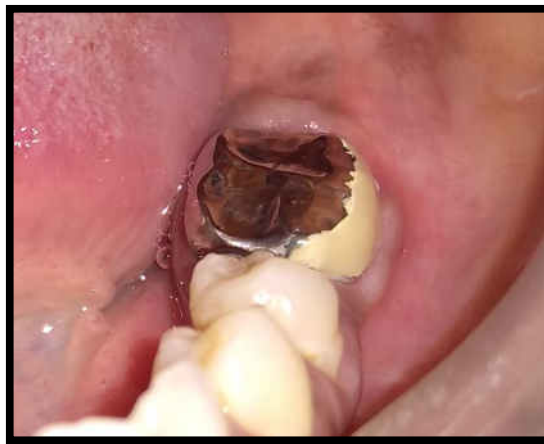DATE: 13.03. 2019

OP NO: 201805190037

AGE/SEX: 27/F

PROCEDURE: Crown lengthening in relation to 37

POST OPERATIVE PHOTOGRAPH



LASER

CROWN LENGTHENING

DEMOGRAPHIC DATA

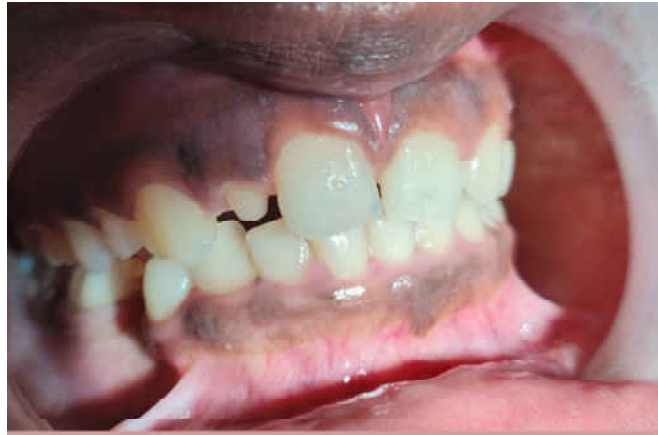PATIENT NAME: Mrs. Elakiya

OP NO: 201808070034

AGE/SEX: 31 year / Female

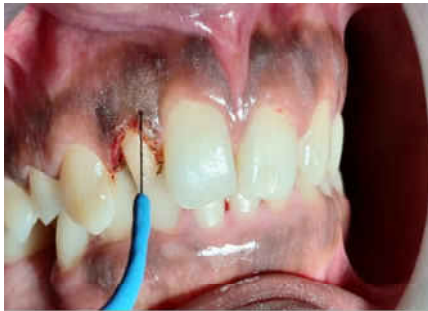PROCEDURE: Crown lengthening done using laser-12

PRE OPERATIVE PHOTO

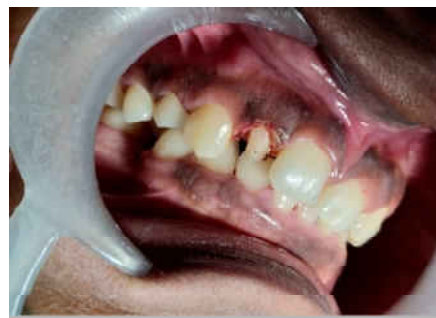

Right lateral view

OPERATIVE MEASUREMENTS



Crown lengthening done using laser



Crown lengthening

GINGIVECTOMY

Case-1

DEMOGRAPHIC DATA

PATIENT NAME: Mr. Kanagaraj

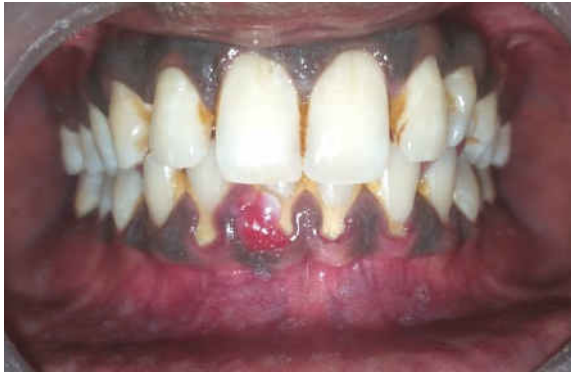DATE: 19.7.2018

OP NO: 201807190146

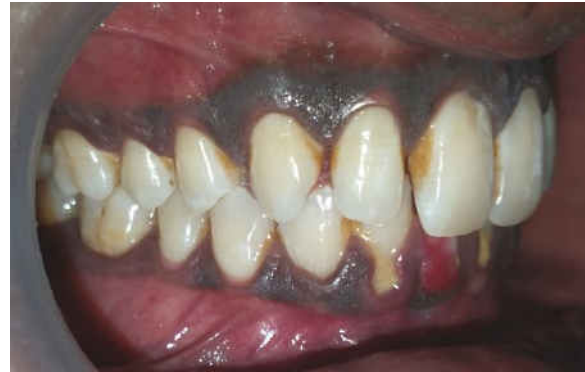AGE/SEX: 26/M

PROCEDURE: Gingivectomy done in relation to 41,42

PRE OPERATIVE PHOTO

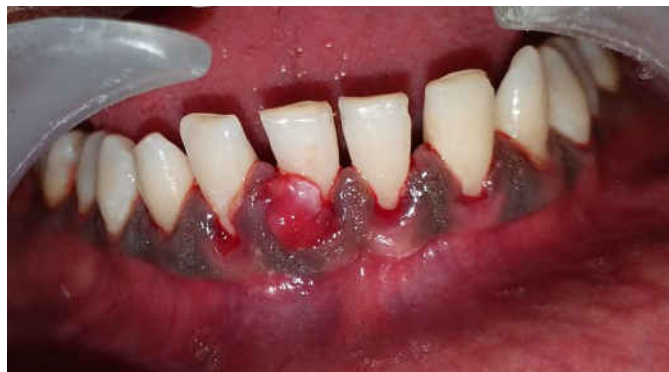

Frontal view



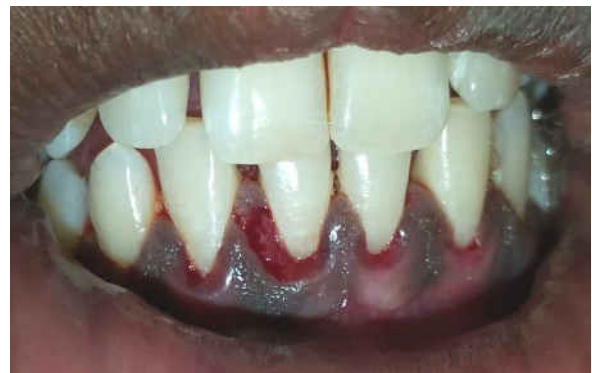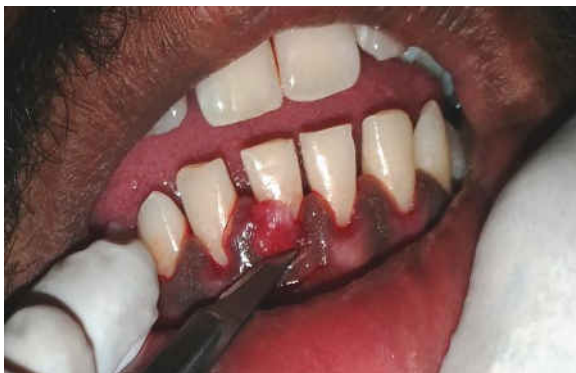Right lateral view

POST SCALING PHOTO



Labial view

OPERATIVE PHOTO



Gingivectomy done in relation to labial aspect of 41,42

Case-2

DEMOGRAPHIC DATA

PATIENT NAME : Ms.Niranjamma Devi

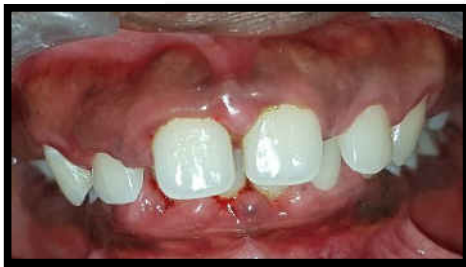DATE: 8/5/18

OP NO: 201805050127

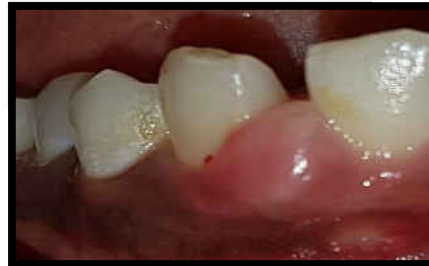AGE/SEX: 19/F

PROCEDURE: Gingivoplasty in 31,32,41,42

PRE OPERATIVE PHOTO – 8.5.18

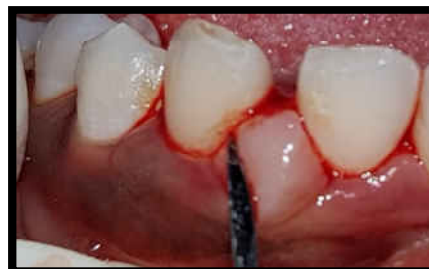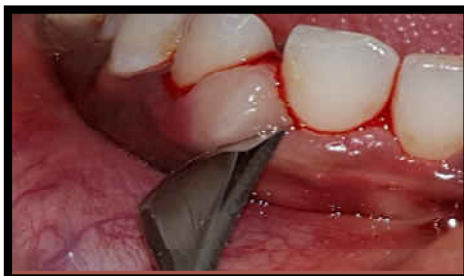


Frontal view

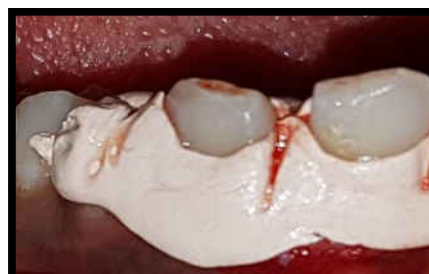
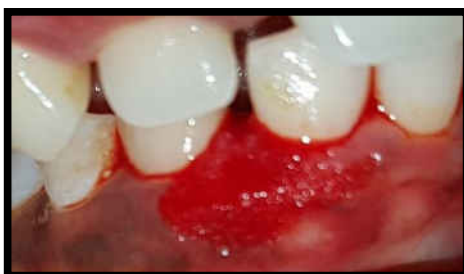
42,43 Buccal aspect

OPERATIVE PHOTO – 22.5.18

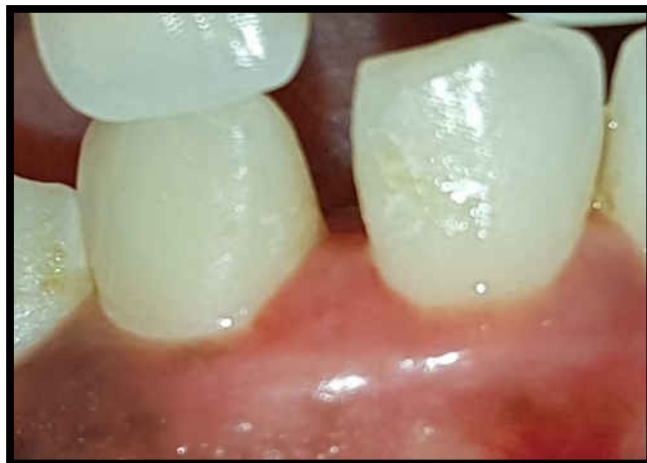

Gingivoplasty using Kirkland and Orban knife



Immediate Post-operative photo

POST-OPERATIVE PHOTO – I MONTH (12.6.18)



LABIAL ASPECT 42, 43

CASE-3

DEMOGRAPHIC DATA

PATIENT NAME : Mr .Parthiban

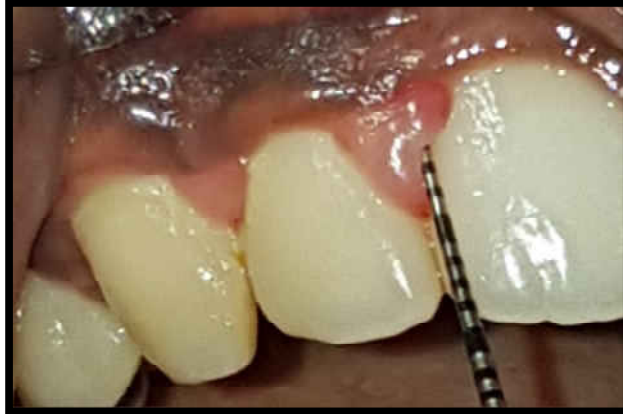
DATE: 4.4.18

OP NO: 201711110077

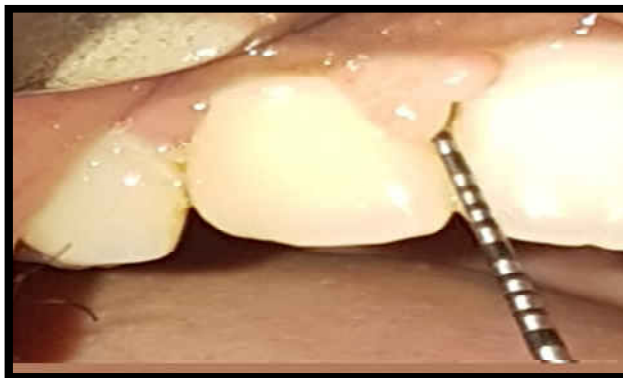AGE/SEX: 21M

PROCEDURE: Gingivectomy at 11,12 region

PRE OPERATIVE PHOTO – 4.4.18

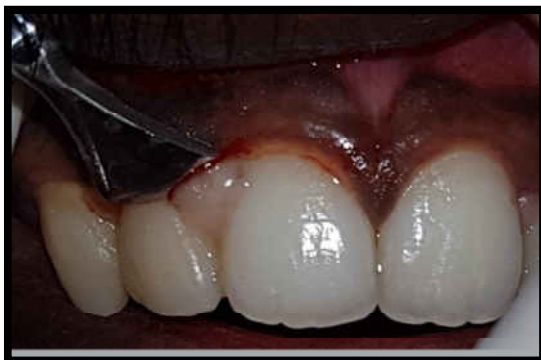

Frontal view

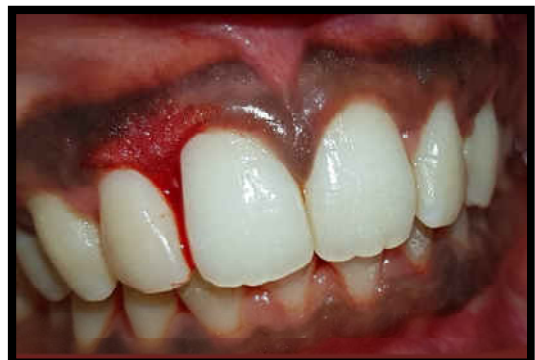

Pocket probing depth-4mm

OPERATIVE PHOTO –4.4.18

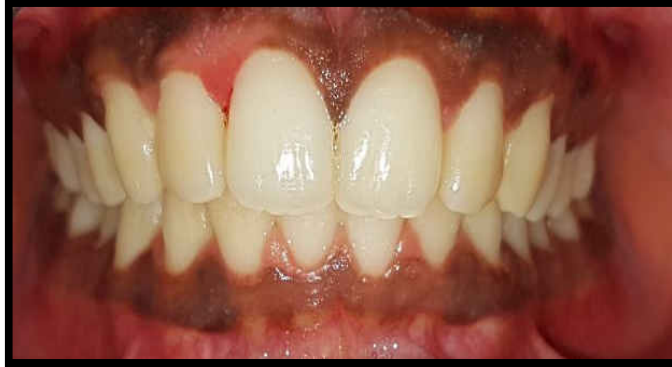

Gingivectomy - 48



Post operative photo-48

**1 MONTH POST OPERATIVE PHOTO-
9.5.2018**



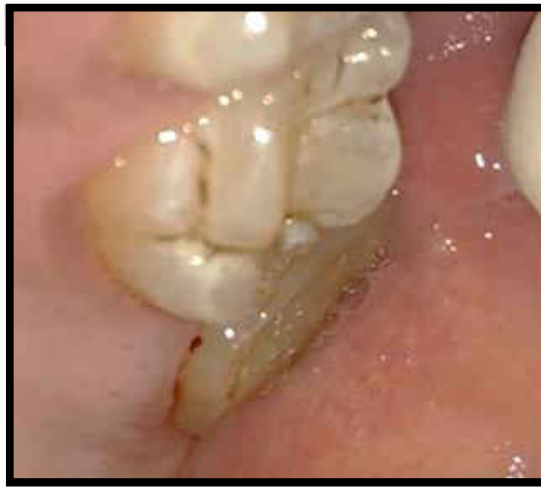OCCLUSAL VIEW 48

CASE-4

DEMOGRAPHIC DATA

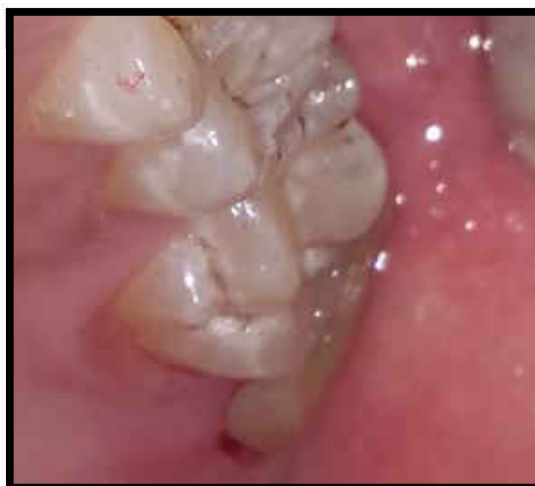PATIENT NAME: MR. ABRANIL CHATERJEE **DATE:** 30.08. 2018
OP NO: 289162 **AGE/SEX:** 27/M
PROCEDURE: Crown lengthening in relation to 27

PRE OPERATIVE PHOTOGRAPH



INADEQUATE CROWN HEIGHT IN RELATION TO LINGUAL ASPECT OF 27

POST OPERATIVE PHOTOGRAPH

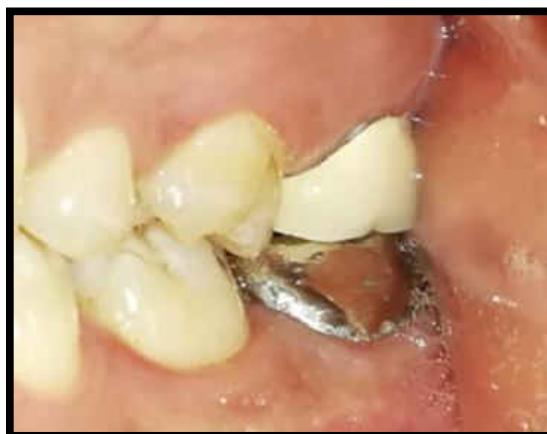
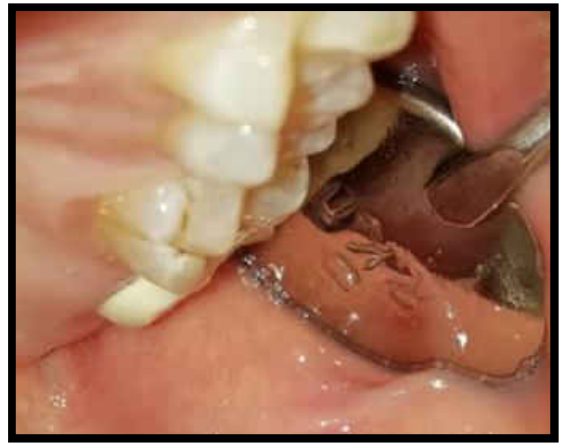
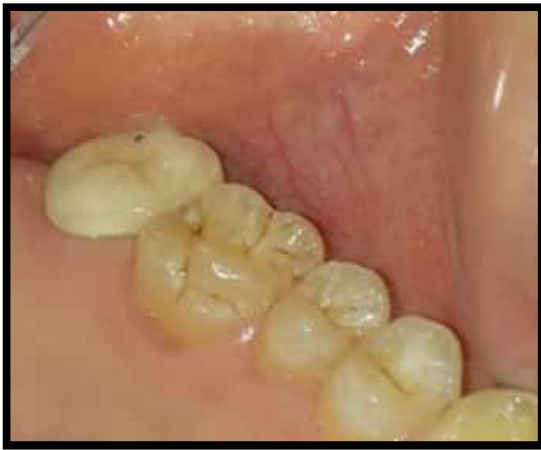EXTERNAL BEVEL CROWN LENGTHENING DONE IN RELATION TO LINGUAL ASPECT OF 27

DEMOGRAPHIC DATA

PATIENT NAME: MR. ABRANIL CHATERJEE **DATE:** 09.10. 2018
OP NO: 289162 **AGE/SEX:** 27/M
PROCEDURE: Crown lengthening in relation to 27

POST OPERATIVE PHOTOGRAPHS- 1 MONTH



CASE-5

DEMOGRAPHIC DATA

PATIENT NAME: MRS. BRIDGET

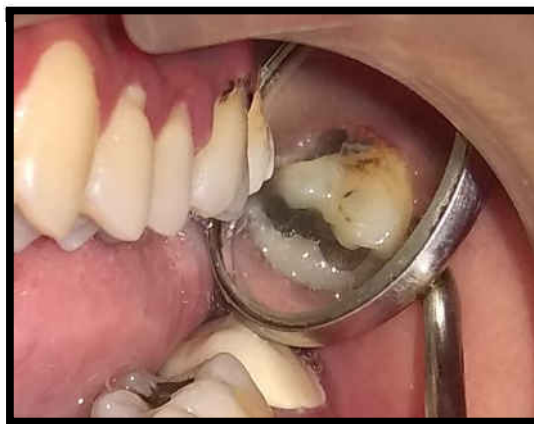DATE: 29.10. 2018

OP NO: 201807190051

AGE/SEX: 26/F

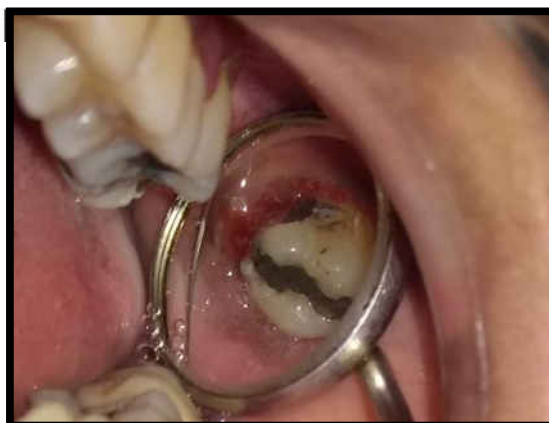PROCEDURE: Crown lengthening in relation to 27

PRE OPERATIVE PHOTOGRAPH



SUBGINGIVAL CARIES IN RELATION TO 27

OPERATIVE PHOTOGRAPH



CROWN LENGTHENING DONE IN RELATION TO LINGUAL ASPECT OF 27

DEMOGRAPHIC DATA

PATIENT NAME: MRS. BRIDGET

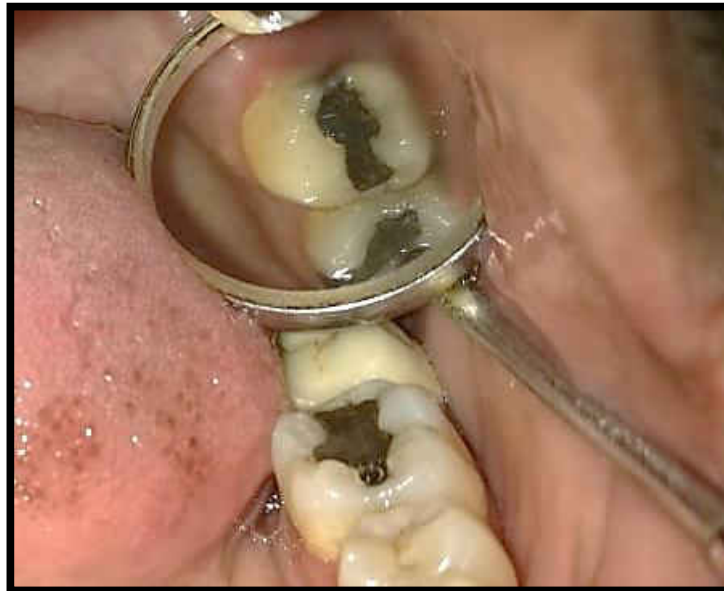DATE: 28.11. 2018

OP NO: 201807190051

AGE/SEX: 26/F

PROCEDURE: Crown lengthening in relation to 27

POST- OPERATIVE PHOTOGRAPH- 1 MONTH



GINGIVECTOMY

DEMOGRAPHIC DATA

PATIENT NAME: MRS. GEETHA

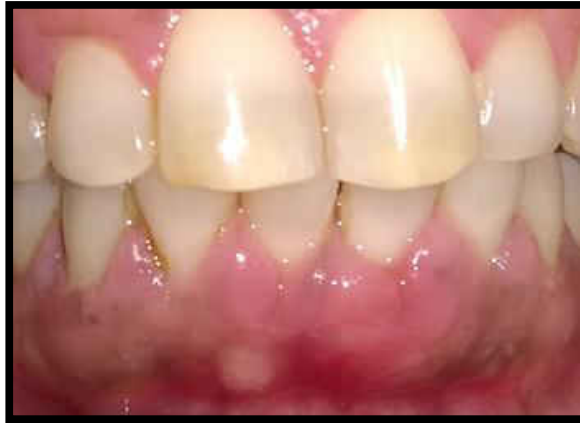DATE: 20.11. 2018

OP NO: 201811100095

AGE/SEX: 35/F

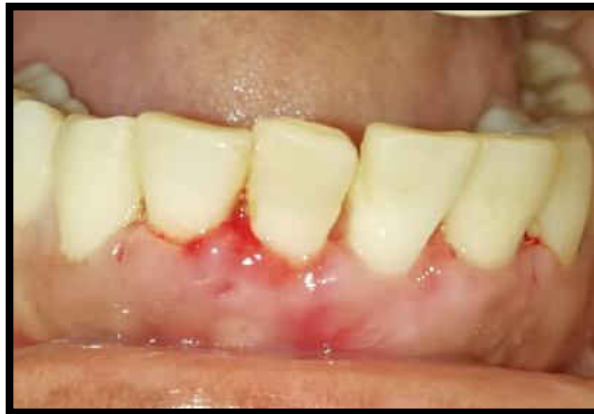PROCEDURE: Gingivectomy in relation to 31,32,33,41,42,43

PRE OPERATIVE PHOTOGRAPH



DRUG INFLUENCED GINGIVAL ENLARGEMENT IN 31,32,33,31,32,43

POST OPERATIVE PHOTOGRAPH



GINGIVECTOMY DONE IN RELATION TO 31,32,33,41,42,43

GINGIVECTOMY

DEMOGRAPHIC DATA

PATIENT NAME: MRS. GEETHA

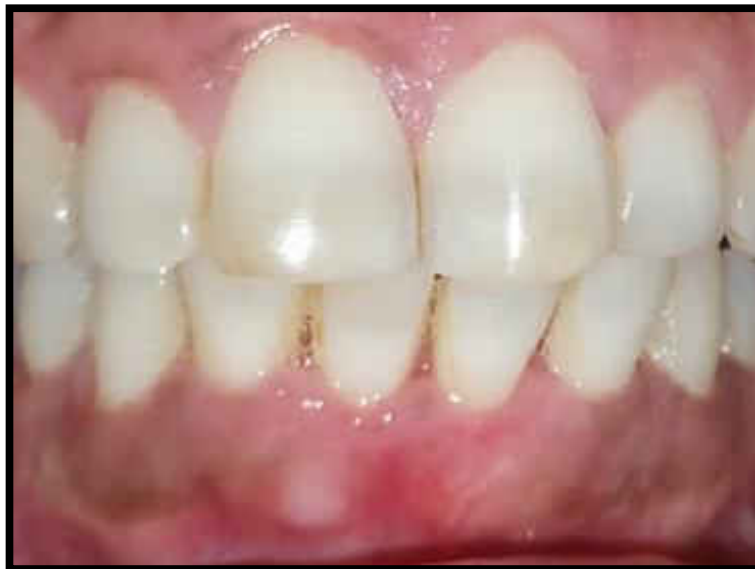DATE: 13.12. 2018

OP NO: 201811100095

AGE/SEX: 35/F

PROCEDURE: Gingivectomy in relation to 31,32,33,41,42,43

POST OPERATIVE PHOTOGRAPH- 1 MONTH



GINGIVOPLASTY

Case-1

DEMOGRAPHIC DATA

PATIENT NAME : Ms.Jeevitha

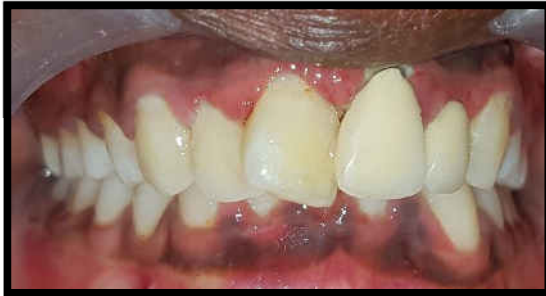DATE: 23/2/18

OP NO: 201802220092

AGE/SEX: 18/F

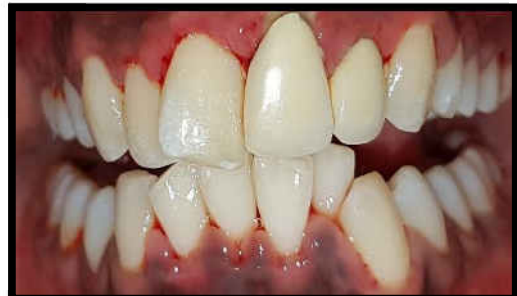PROCEDURE: Gingivoplasty in 31,32,41,42

PRE OPERATIVE PHOTO – 23.2.18

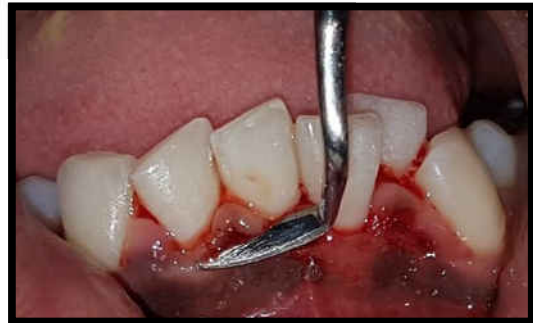
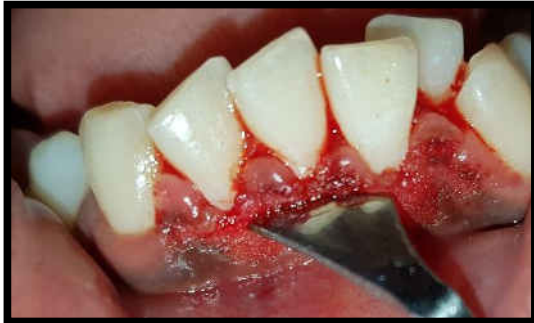
Frontal view

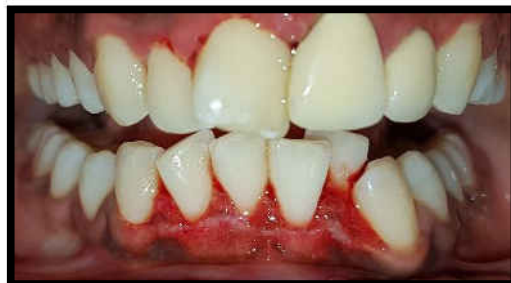POST SCALING



OPERATIVE PHOTO – 23.2.18

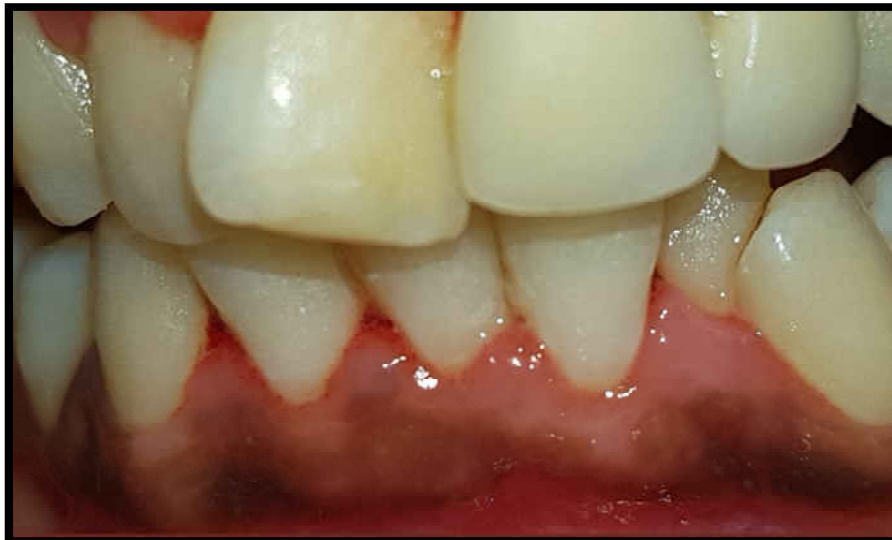

Gingivoplasty using Kirkland and Orban knife



Immediate Post-operative photo

POST-OPERATIVE PHOTO – I MONTH (7.4.18)



LABIAL ASPECT 31,32,41,42

Case-2

DEMOGRAPHIC DATA

PATIENT NAME : Ms.Kavitha

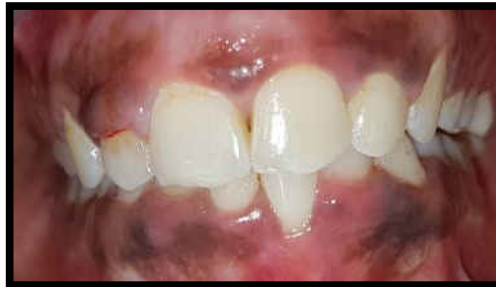DATE:25.5.18

OP NO:201405270002

AGE/SEX:21 /F

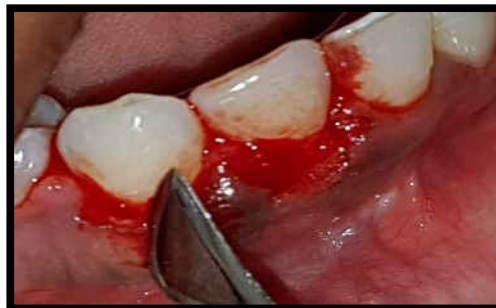
PROCEDURE: Gingivoplasty in 12,32,41,42

PRE OPERATIVE PHOTO – 25.5.18

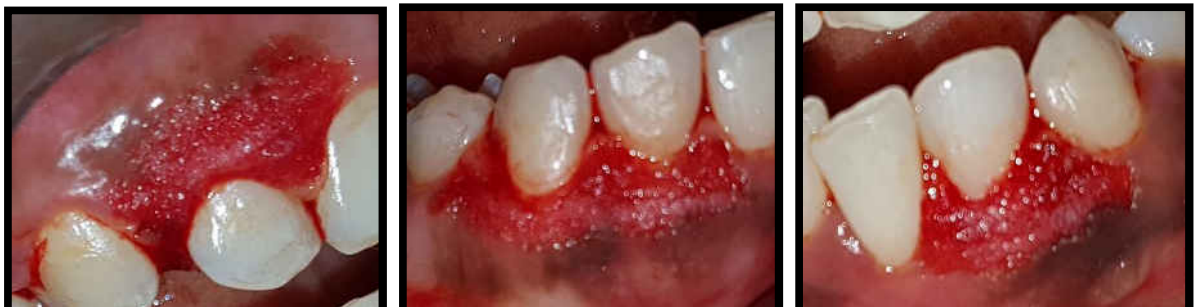

Frontal view

OPERATIVE PHOTO – 25.5.18

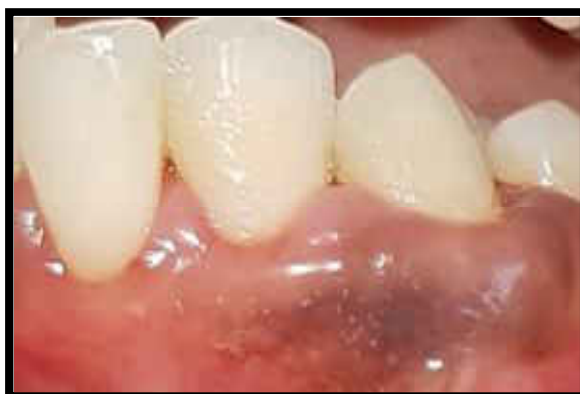
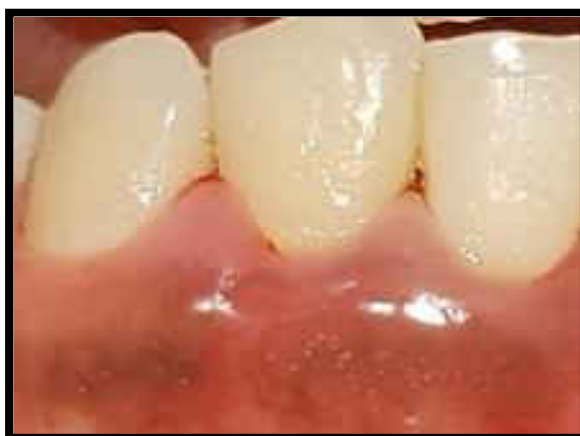
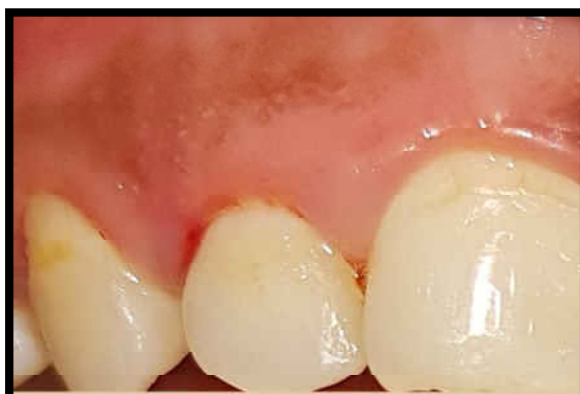Gingivoplasty using Kirkland and Orban knife



Immediate Post-operative photo

POST-OPERATIVE PHOTO – I MONTH (26.7.18)



LABIAL ASPECT 12,32,41,42

Case-3

DEMOGRAPHIC DATA

PATIENT NAME : Mrs Lakshmi

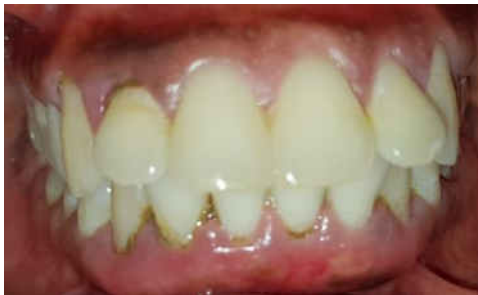DATE: 24.7.18

OP NO: 201807020027

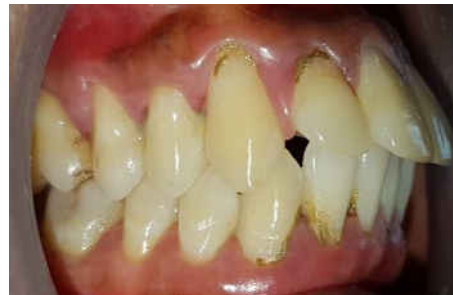AGE/SEX: 39/F

PROCEDURE: Gingivoplasty in 31,32,41,42

PRE OPERATIVE PHOTO – 24.7.18

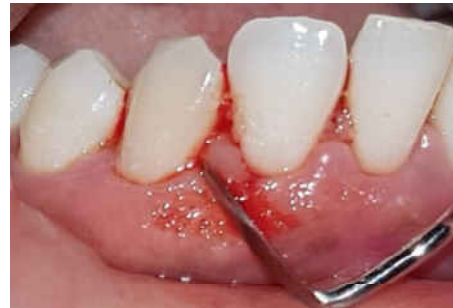
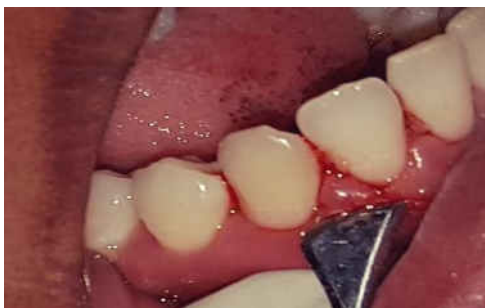
Frontal view

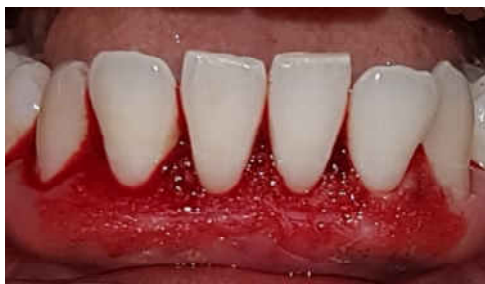

Right Lateral

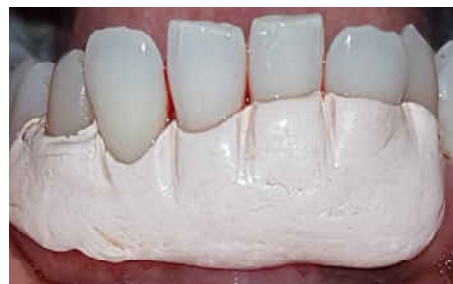OPERATIVE PHOTO – 24.7.18



Gingivoplasty using Kirkland and Orban knife



Immediate Post-operative photo



Periodontal dressing

Case-4

DEMOGRAPHIC DATA

PATIENT NAME : Mr Maheshwara Rao

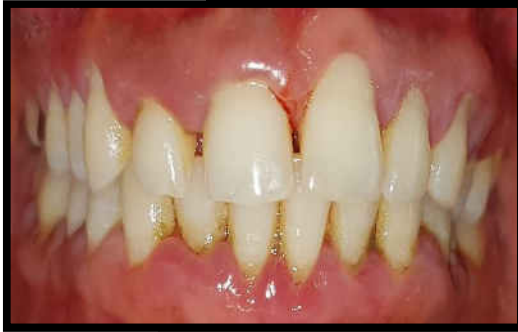DATE: 13.7.18

OP NO: 201807130068

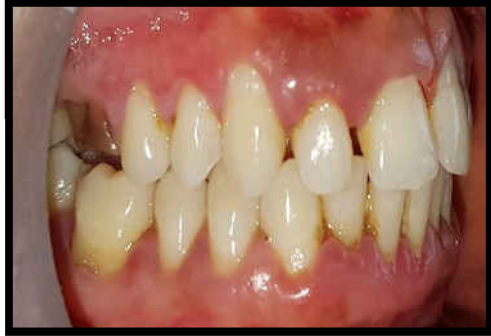AGE/SEX: 26/M

PROCEDURE: Gingivoplasty in 31,32,41,42

PRE OPERATIVE PHOTO – 13.7.18

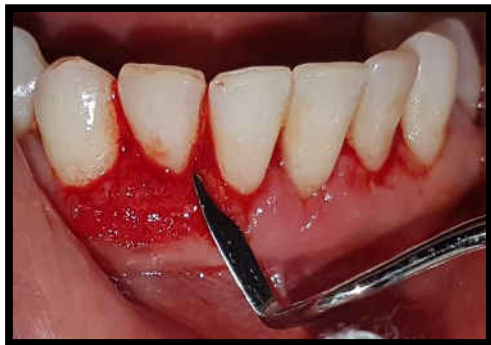
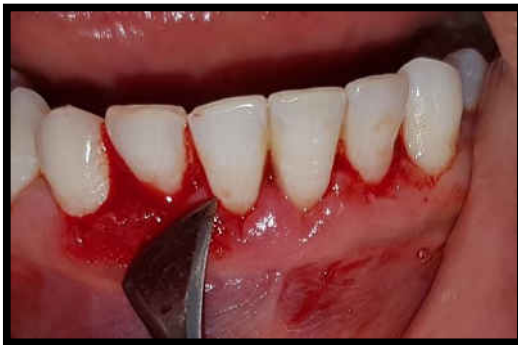
Frontal view

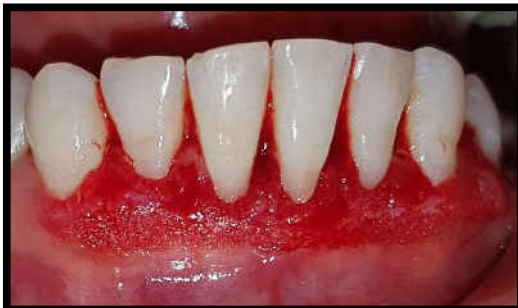

Right Lateral

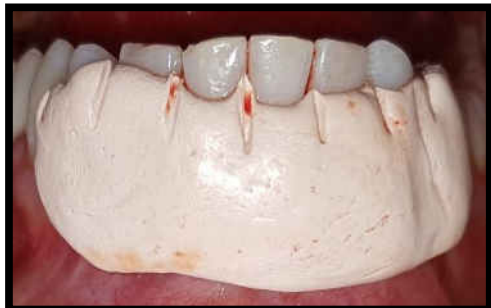OPERATIVE PHOTO – 13.7.18



Gingivoplasty using Kirkland and Orban knife

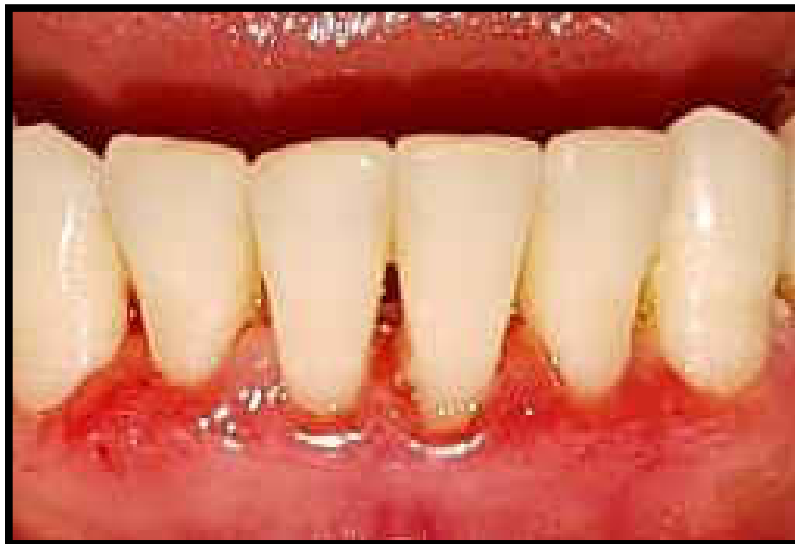

Immediate Post-operative photo



Periodontal dressing

POST-OPERATIVE PHOTO – I MONTH



LABIAL ASPECT 31,32,41,42

Case-5

DEMOGRAPHIC DATA

PATIENT NAME : Ms.Niranjamma Devi

DATE: 8/5/18

OP NO: 201805050127

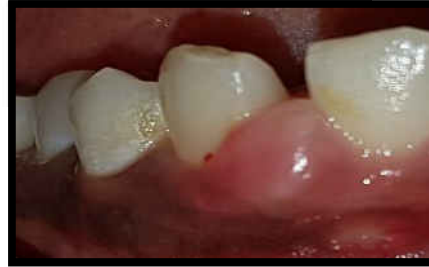AGE/SEX: 19/F

PROCEDURE: Gingivoplasty in 31,32,41,42

PRE OPERATIVE PHOTO – 8.5.18

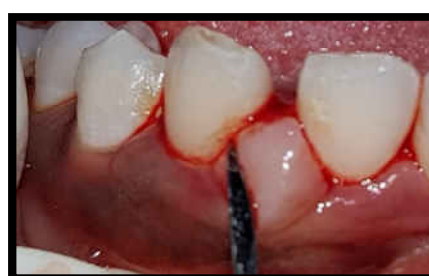
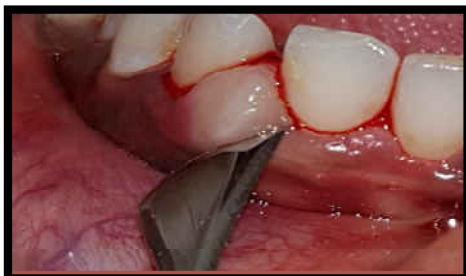
Frontal view


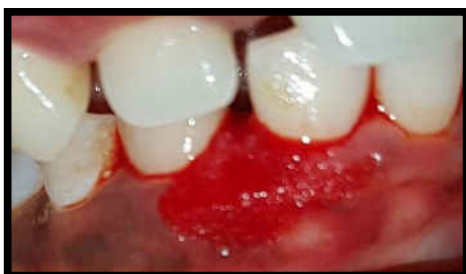
42,43 Buccal aspect

OPERATIVE PHOTO – 22.5.18



Gingivoplasty using Kirkland and Orban knife



Immediate Post-operative photo

POST-OPERATIVE PHOTO – I MONTH (12.6.18)



LABIAL ASPECT 42, 43

Case-6

DEMOGRAPHIC DATA

PATIENT NAME : Ms.Niranjamma Devi

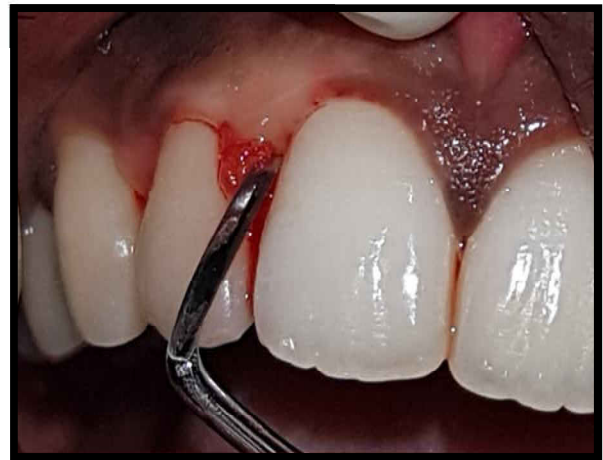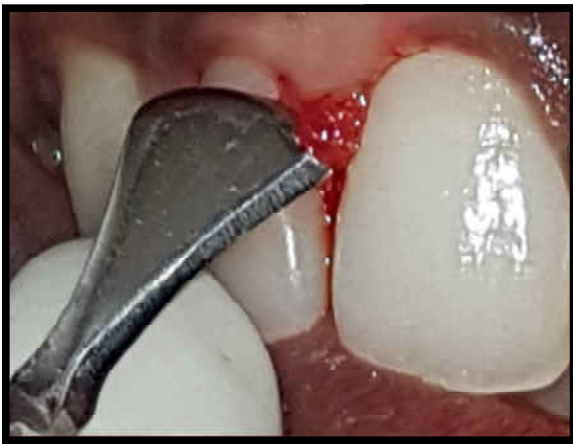DATE: 8/5/18

OP NO: 201805050127

AGE/SEX: 19/F

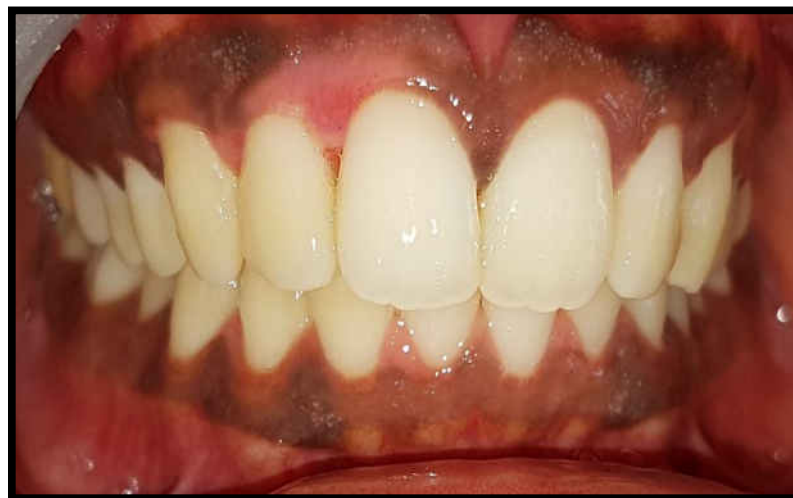PROCEDURE: Gingivoplasty in 31,32,41,42

OPERATIVE PHOTO – 22.5.18



Gingivoplasty using Kirkland and Orban knife

POST-OP OPERATIVE PHOTO



Immediate Post-operative photo

Case-7

DEMOGRAPHIC DATA

PATIENT NAME : Mrs.Selvarani

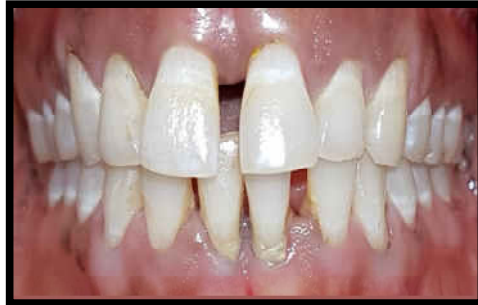DATE: 19.7.18

OP NO: 201807180152

AGE/SEX: 33/F

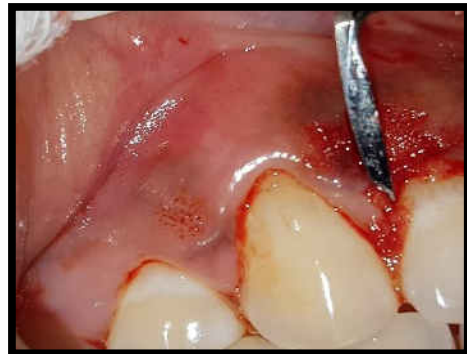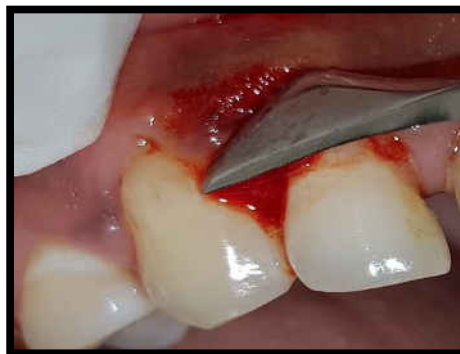PROCEDURE: Gingivoplasty in 11,12,21,22

PRE OPERATIVE PHOTO – 19.7.18

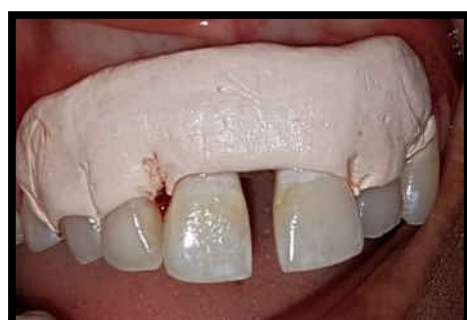
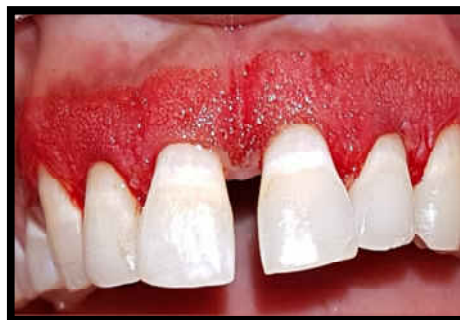
Frontal view

OPERATIVE PHOTO – 19.7.18



Gingivoplasty using Kirkland and Orban knife



Immediate Post-operative photo

Case-8

DEMOGRAPHIC DATA

PATIENT NAME : Mrs.Sundari

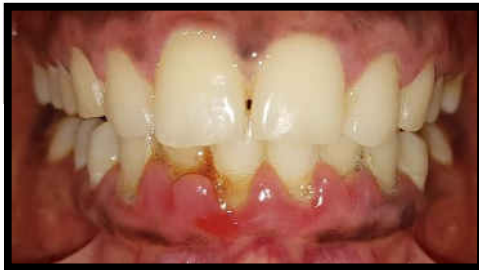DATE: 28/5/18

OP NO: 201805280063

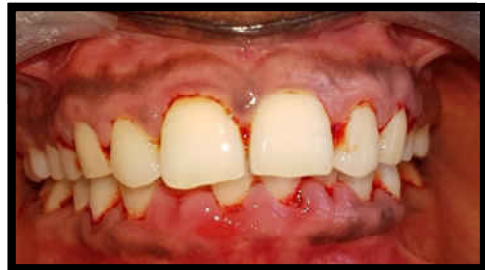AGE/SEX: 35/F

PROCEDURE: Gingivoplasty in 31,32,41,42

PRE OPERATIVE PHOTO – 28.5.18

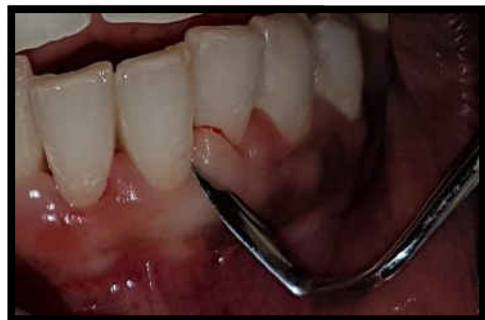
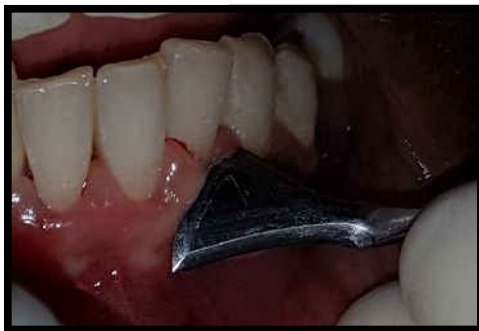
POST SCALING

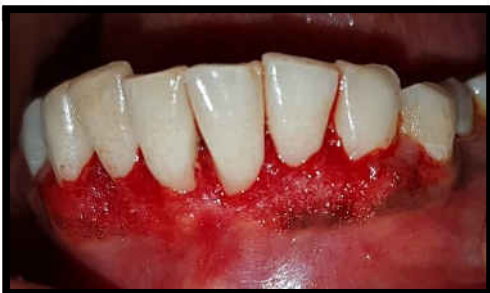

Frontal view

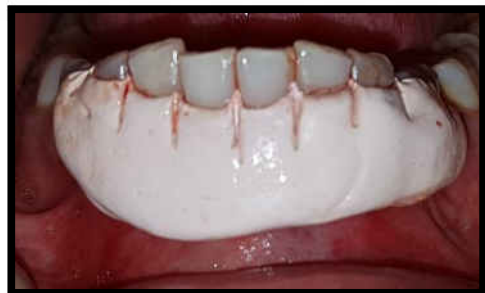OPERATIVE PHOTO – 4.6.18



Gingivoplasty using Kirkland and Orban knife



Immediate Post-operative photo



Periodontal dressing

Case-9

DEMOGRAPHIC DATA

PATIENT NAME : Ms.Vanitha

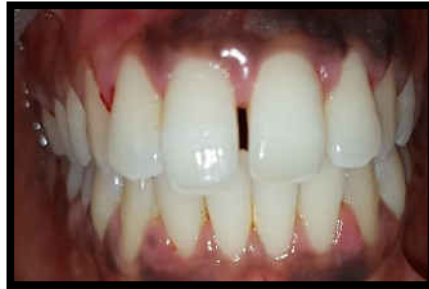DATE: 29.5.18

OP NO: 201804070062

AGE/SEX: 26/F

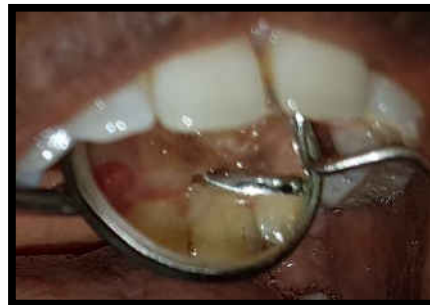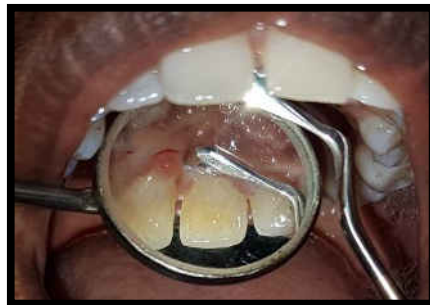PROCEDURE: Gingivoplasty in 11,12,21,22

PRE OPERATIVE PHOTO – 29.5.18

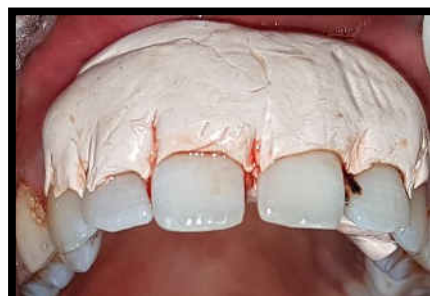
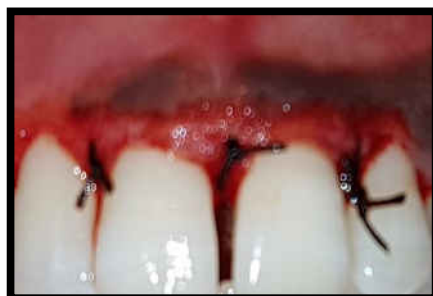
Frontal view

OPERATIVE PHOTO – 5.6.18

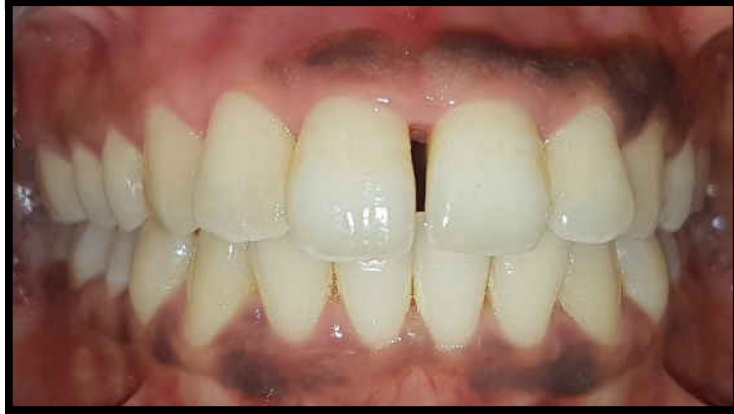

Gingivoplasty using Kirkland and Orban knife

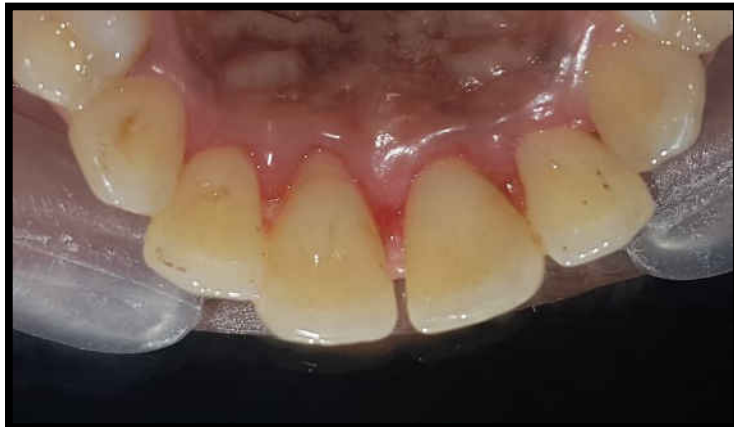

Immediate Post-operative photo

POST-OPERATIVE PHOTO – I MONTH (3.7.18)



LABIAL ASPECT 11,12,21,22



PALATAL ASPECT 11,12,21,22

Case-10

DEMOGRAPHIC DATA

PATIENT NAME: MR. LAKSHMANA DASS

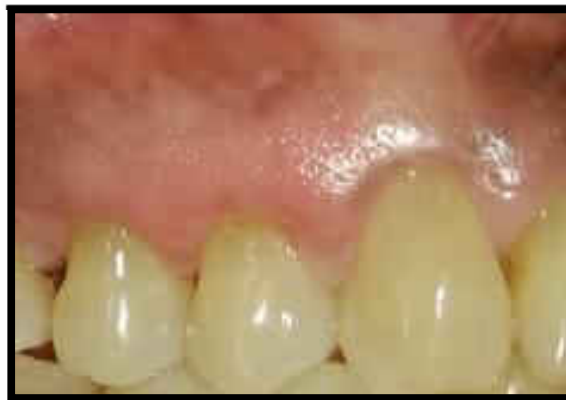DATE: 19.09. 2018

OP NO: 201809150222

AGE/SEX: 53/M

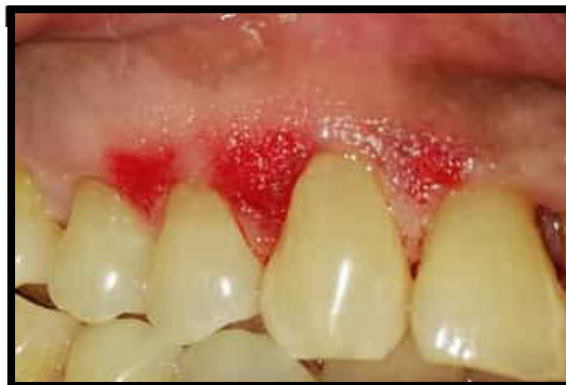PROCEDURE: Gingivoplasty done in relation to 31,32,33,41,42,43

PRE OPERATIVE PHOTOGRAPH



FIBROTIC GINGIVAL ENLARGEMENT IN RELATION TO 13, 14, 15

OPERATIVE PHOTOGRAPH

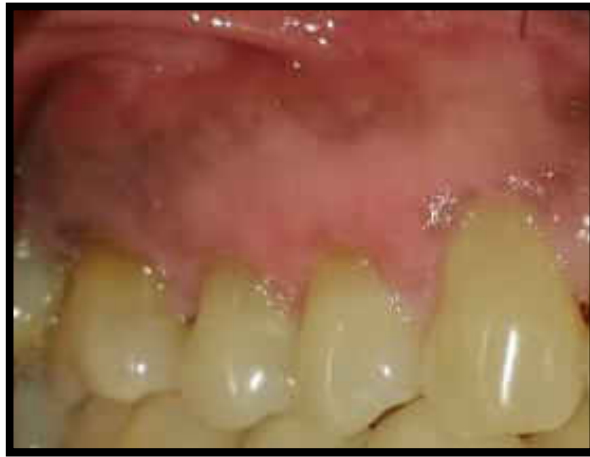

GINGIVOPLASTY DONE IN RELATION TO 13, 14, 15

DEMOGRAPHIC DATA

PATIENT NAME: MR. LAKSHMANA DASS **DATE:** 20.02. 2019
OP NO: 201809150222 **AGE/SEX:** 53/M
PROCEDURE: Gingivoplasty done in relation to 13, 14, 15

POST OPERATIVE PHOTOGRAPH- 1 MONTH



Case-11

DEMOGRAPHIC DATA

PATIENT NAME: MR.MURUGAN

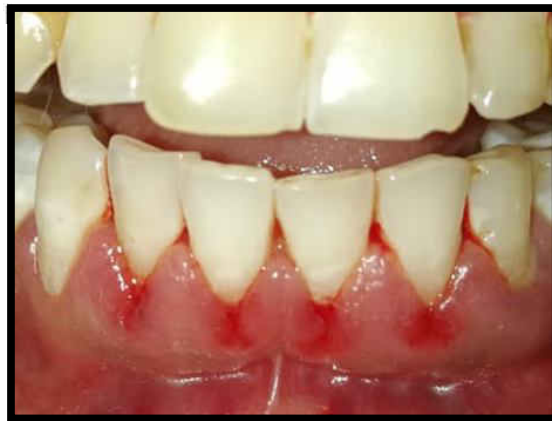DATE: 19.09. 2018

OP NO: 201809180623

AGE/SEX: 32/M

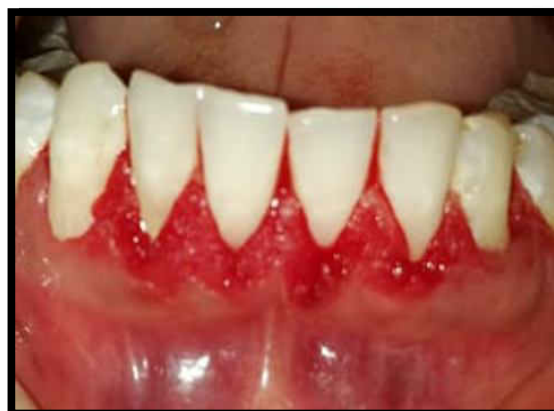PROCEDURE: Gingivoplasty done in relation to 31,32,33,41,42,43

PRE OPERATIVE PHOTOGRAPHS



FIBROTIC GINGIVAL ENLARGEMENT IN RELATION TO 31,32,33,41,42,43

OPERATIVE PHOTOGRAPHS



GINGIVOPLASTY DONE IN RELATION TO 31,32,33,41,42,43

DEMOGRAPHIC DATA

PATIENT NAME: MR.MURUGAN

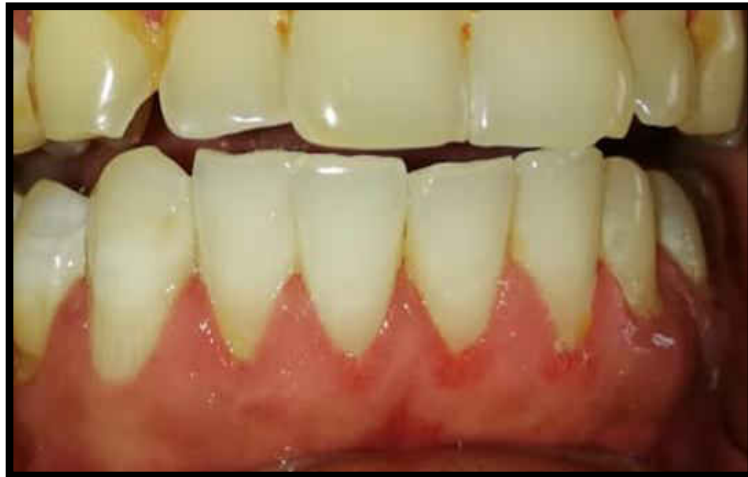DATE: 07.11. 2018

OP NO: 201809180623

AGE/SEX: 32/M

PROCEDURE: Gingivoplasty done in relation to 31,32,33,41,42,43

POST OPERATIVE PHOTOGRAPH- 1 MONTH



Case-12

DEMOGRAPHIC DATA

PATIENT NAME: MR. SATYA PRAKASH

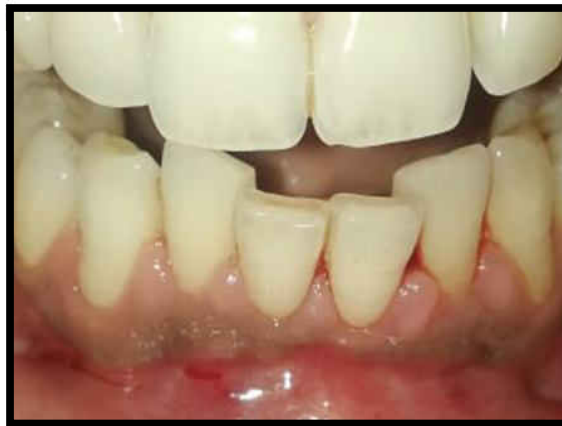DATE: 20.09. 2018

OP NO: 201809140069

AGE/SEX: 28/M

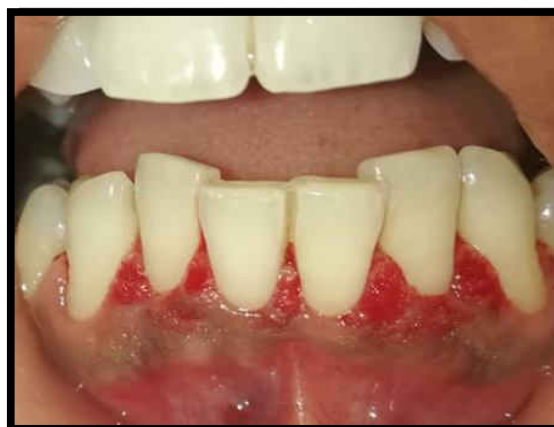PROCEDURE: Gingivoplasty done in relation to 31,32,33,41,42,43

PRE OPERATIVE PHOTOGRAPHS



FIBROTIC GINGIVAL ENLARGEMENT IN RELATION TO 31,32,33,41,42,43

OPERATIVE PHOTOGRAPHS



GINGIVOPLASTY DONE IN RELATION TO 31,32,33,41,42,43

DEMOGRAPHIC DATA

PATIENT NAME: MR. SATYA PRAKASH

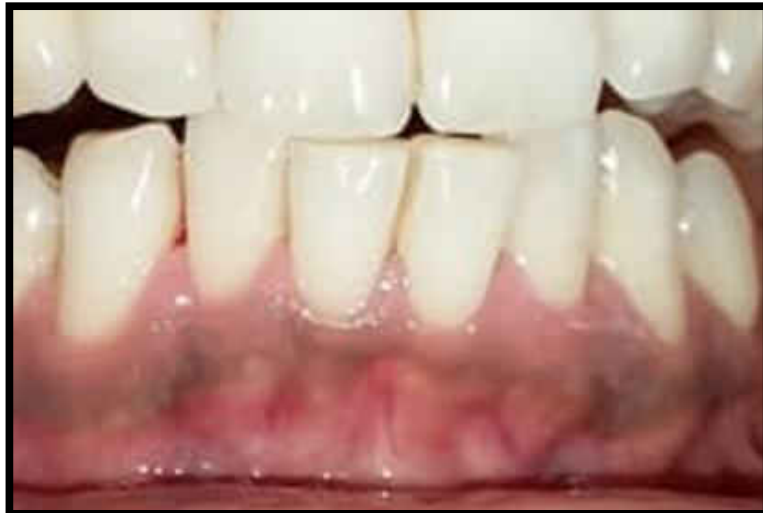DATE: 13.10. 2018

OP NO: 201809140069

AGE/SEX: 28/M

PROCEDURE: Gingivoplasty done in relation to 31,32,33,41,42,43

POST OPERATIVE PHOTOGRAPH- 1 MONTH



Case-13

DEMOGRAPHIC DATA

PATIENT NAME: MRS. SUDHA

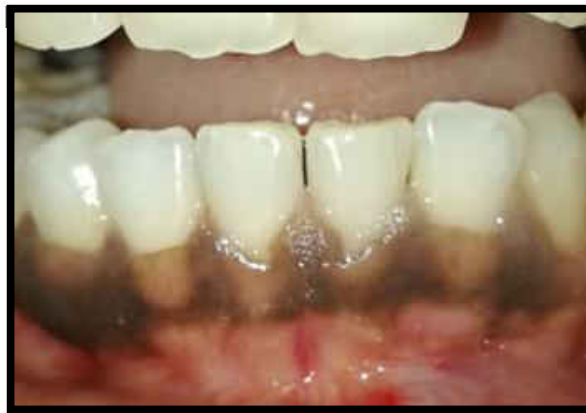DATE: 22.02. 2019

OP NO: 201805190037

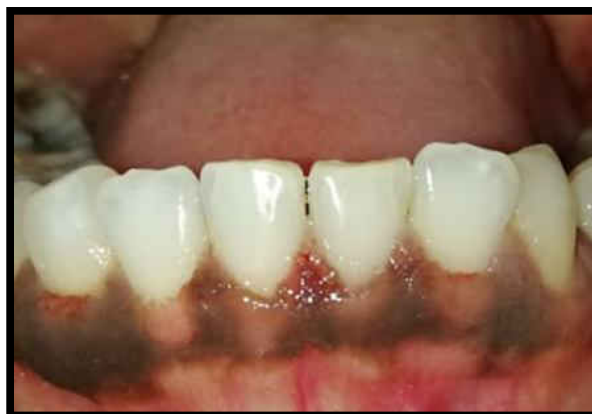AGE/SEX: 27/F

PROCEDURE: Gingivoplasty in relation to 31, 32,41,42

PRE OPERATIVE PHOTOGRAPH



POST OPERATIVE PHOTOGRAPH



Gingivoplasty done in relation to 31,32,41,42

DEMOGRAPHIC DATA

PATIENT NAME: MRS. SUDHA

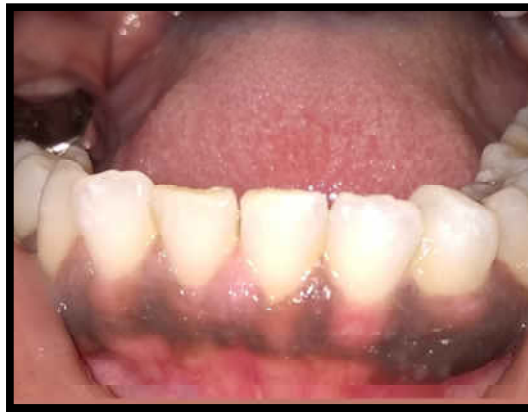DATE: 13.03. 2019

OP NO: 201805190037

AGE/SEX: 27/F

PROCEDURE: Crown lengthening in relation to 37

POST OPERATIVE PHOTOGRAPH



Case-14

DEMOGRAPHIC DATA

PATIENT NAME: Ms.Hemavathy

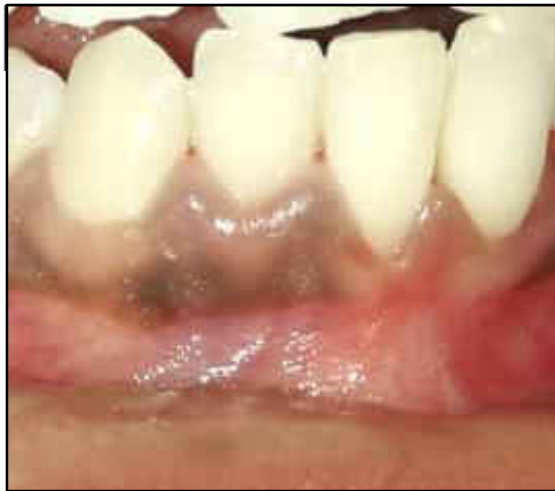DATE: 8.2.2019

OP NO: 201902010063

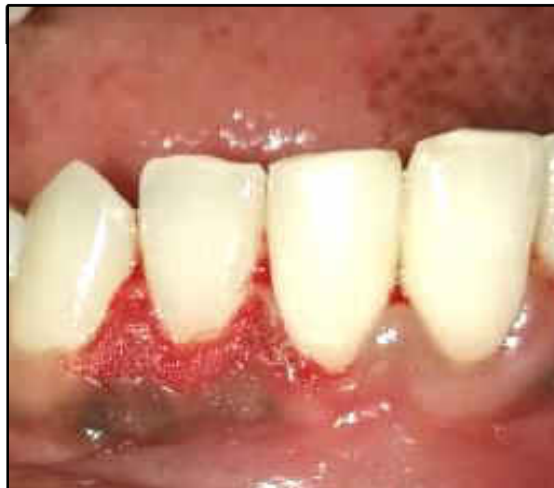AGE/SEX: 22/F

PROCEDURE: Gingivoplasty done in relation to 42

PRE OPERATIVE PHOTO



OPERATIVE PHOTOGRAPH



DEMOGRAPHIC DATA

PATIENT NAME: Ms.Hemavathy

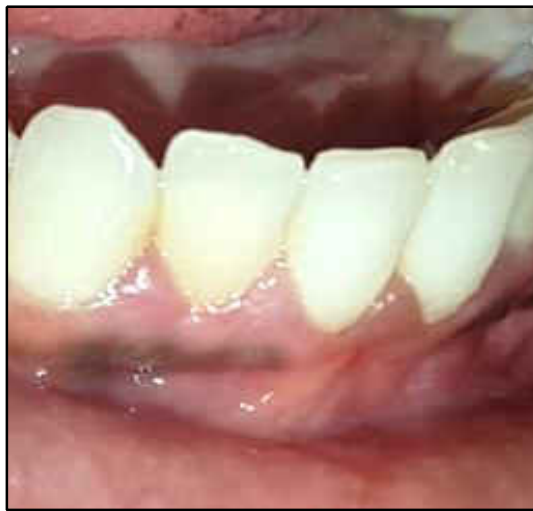DATE: 19.2.2019

OP NO: 201902010063

AGE/SEX: 22/F

PROCEDURE: Gingivoplasty done in relation to 42

POST OPERATIVE PHOTO



Case-15

DEMOGRAPHIC DATA

PATIENT NAME: Mr.Sambasiva Rao

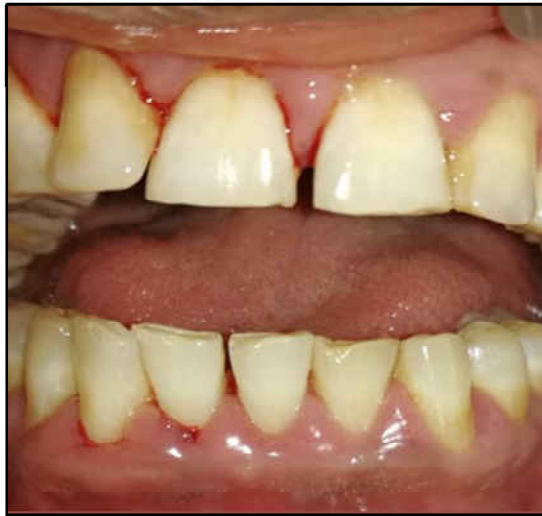DATE: 31.1.2019

OP NO: 201901170168

AGE/SEX: 45/M

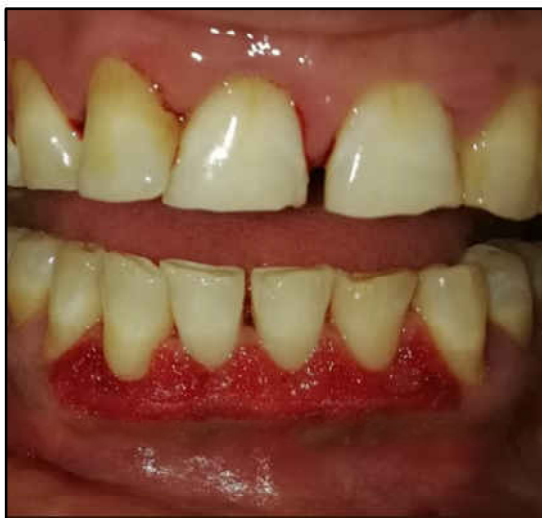PROCEDURE: Gingivoplasty done in relation to 31,32,33,41,42,43

PRE OPERATIVE PHOTO



Gingival enlargement in relation to 31,32,33,41,42,43

OPERATIVE PHOTOGRAPH



Gingivoplasty done in relation to 31,32,33,41,42,43

DEMOGRAPHIC DATA

PATIENT NAME: Mr.Sambasiva Rao

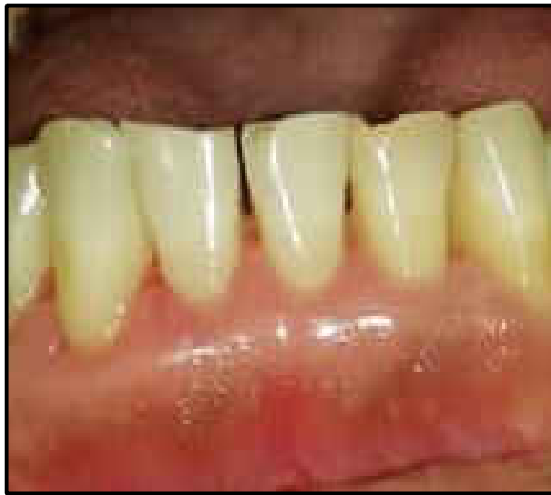DATE: 15.3.2019

OP NO: 201901170168

AGE/SEX: 45/M

PROCEDURE: Gingivoplasty done in relation to 31,32,33,41,42,43

POST OPERATIVE PHOTO



EXCISION OF PULP POLY

Case-1

DEMOGRAPHIC DATA

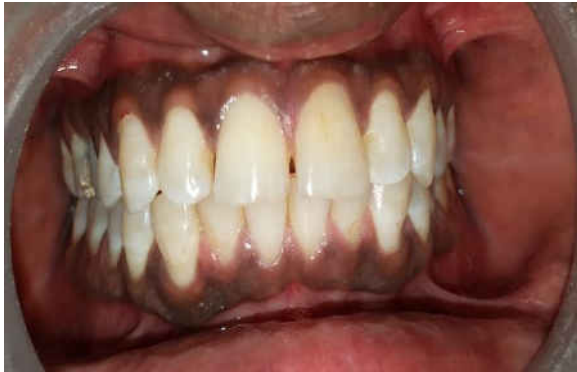PATIENT NAME: Mr. Santhosh Kumar Reddy **DATE:** 4.7.2018

OP NO: 201805210179

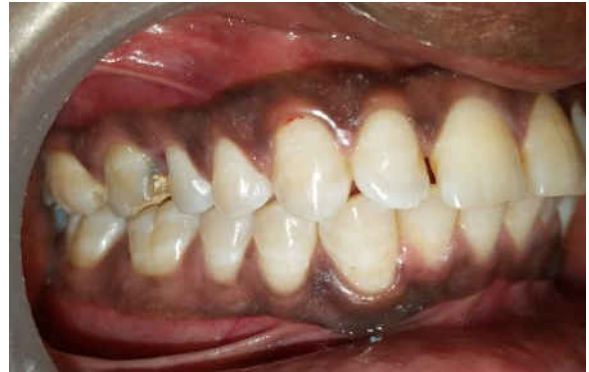AGE/SEX: 25/M

PROCEDURE: Excision of gingival poly done in relation to 15

PRE OPERATIVE PHOTO

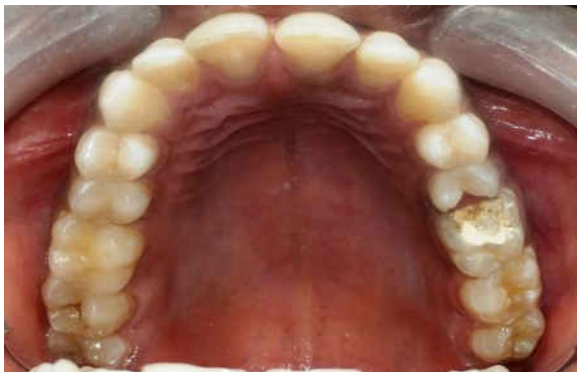

Frontal view

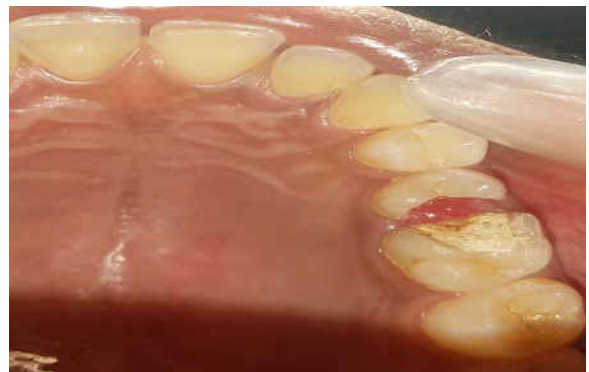

Right lateral view

PRE OPERATIVE PHOTO

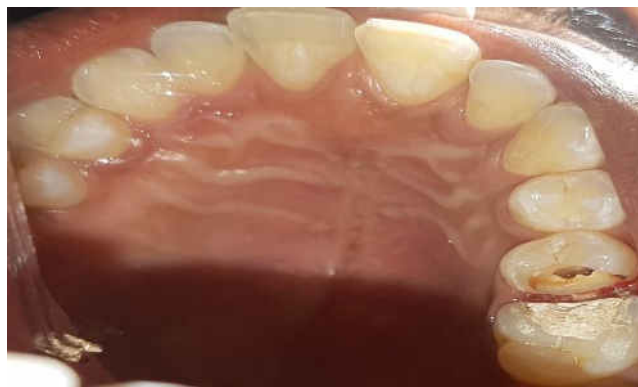

Occlusal view



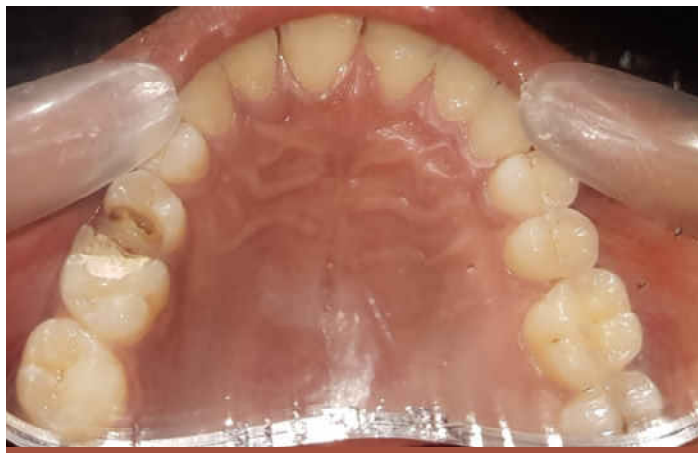Gingival polyp in 15

OPERATIVE PHOTO



Excision of gingival polyp done in relation to 15

POST OPERATIVE PHOTO – 1 WEEK



Occlusal view

GINGIVOPLASTY

Case-1

DEMOGRAPHIC DATA

PATIENT NAME: Miss. Janaki Priya

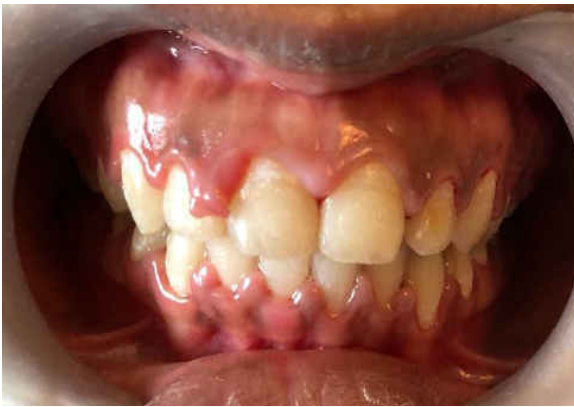DATE: 10.4.2018

OP NO: 201606160055

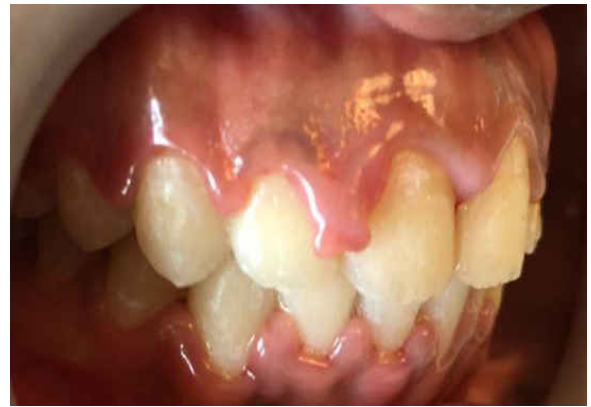AGE/SEX: 20/F

PROCEDURE: Gingivoplasty done in relation to 31,32,33, 41,42,43 and
Gingivectomy done in relation to 12,11

PRE OPERATIVE PHOTO

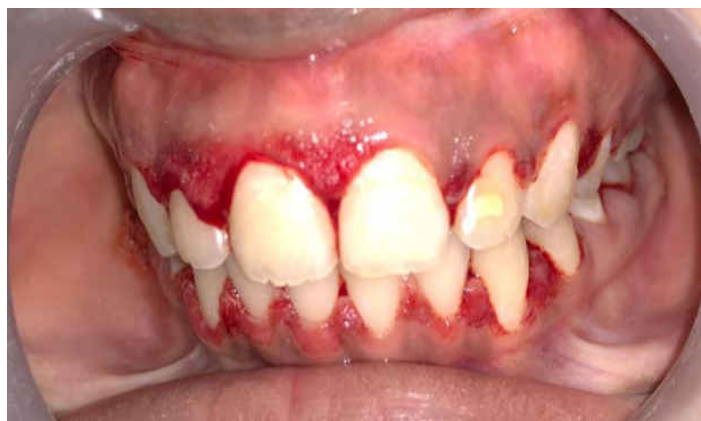

Frontal view



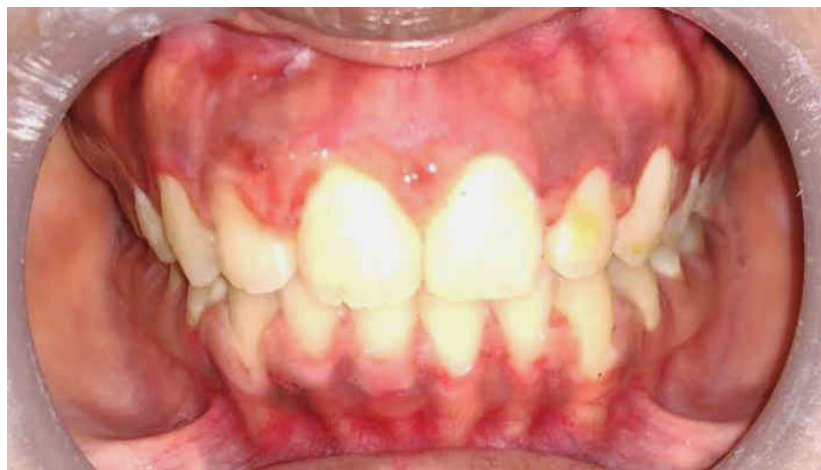Right lateral view

OPERATIVE PHOTO



Gingivoplasty done in relation to 31,32,33,42,43

POST OPERATIVE PHOTO



Frontal view

Case-2

DEMOGRAPHIC DATA

PATIENT NAME: Mr. David

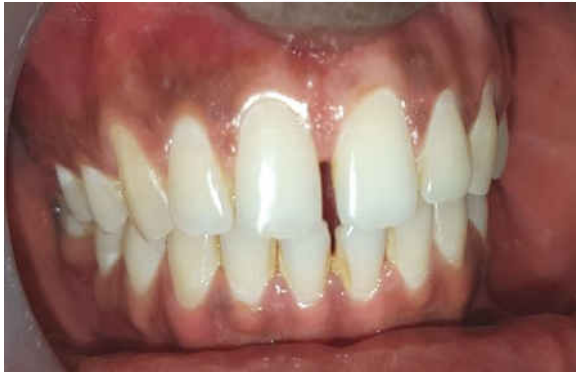DATE: 7.3.2018

OP NO: 20180301005

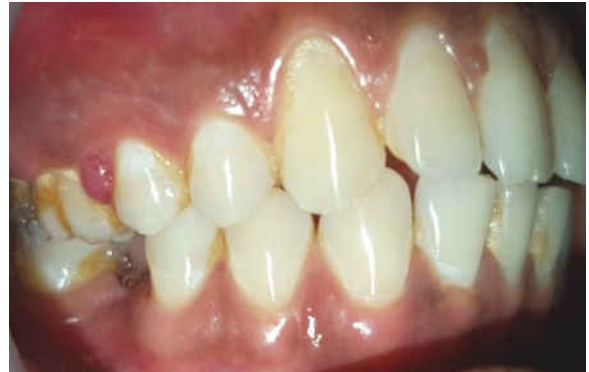AGE/SEX: 40/M

PROCEDURE: Gingivoplasty done in relation to 15,16

PRE OPERATIVE PHOTO

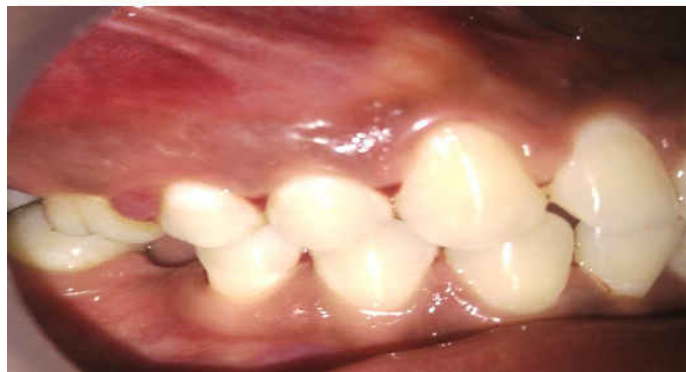

Frontal view



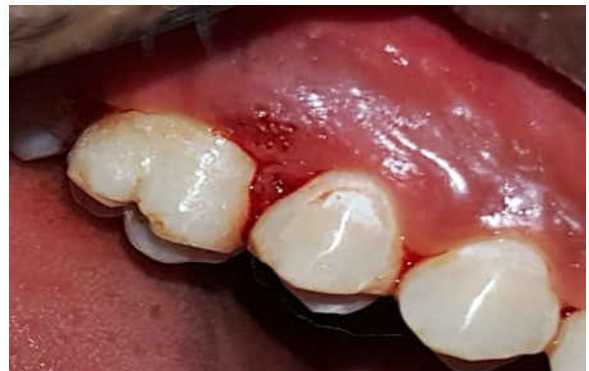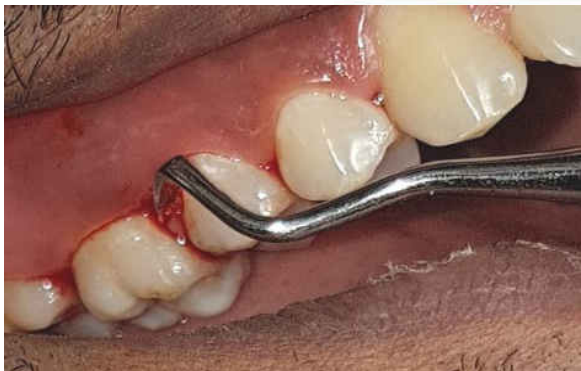Right lateral view

POST SCALING PHOTO



Right lateral view

OPERATIVE PHOTO



Gingivoplasty done in relation to 15,16

Case-3

DEMOGRAPHIC DATA

PATIENT NAME: Mr. Ramesh

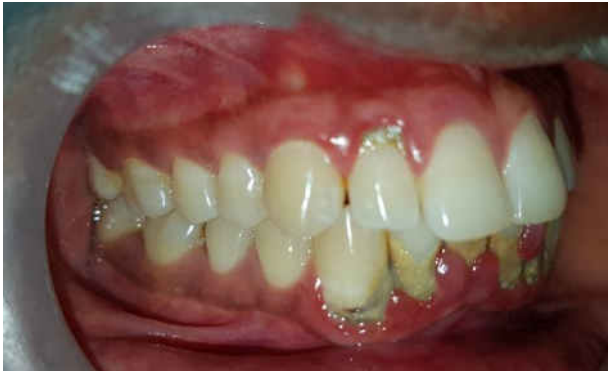DATE: 8.3.2018

OP NO: 201803060061

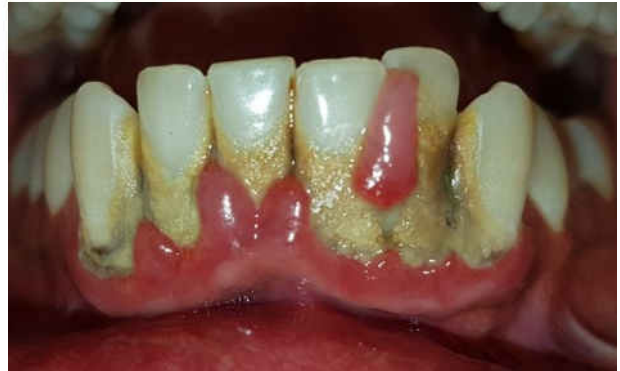AGE/SEX: 35/M

PROCEDURE: Gingivoplasty done in relation to 31,32,33,43 and gingivectomy done in to 41,42

PRE OPERATIVE PHOTO

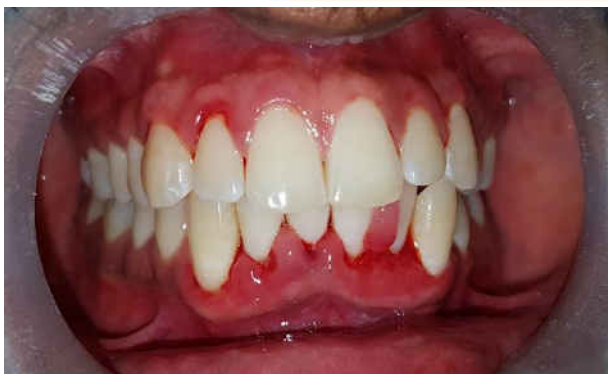

Right lateral view

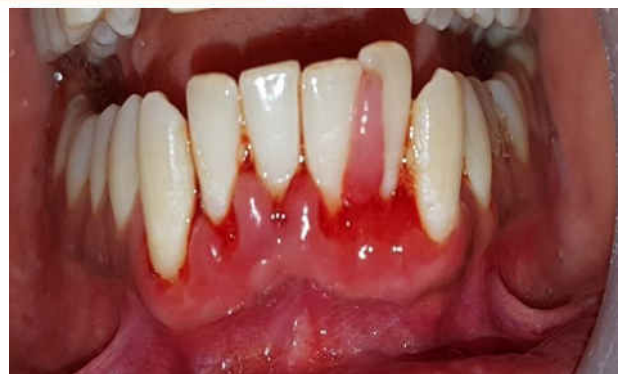

Lower anterior view

POST OPERATIVE SCALING

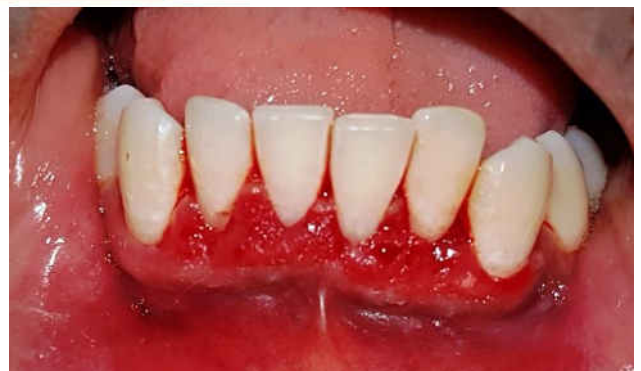
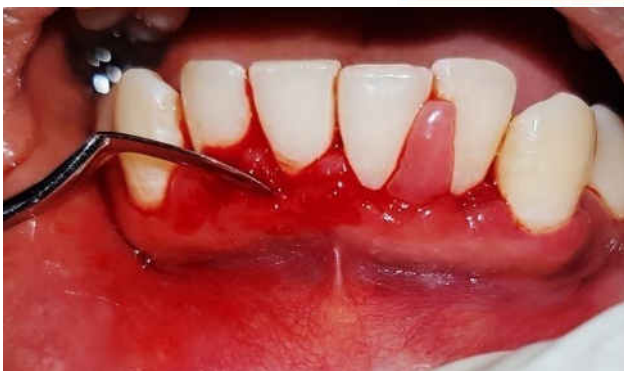
Frontal view



Lower anterior view

OPERATIVE PHOTO



Gingivoplasty done in relation to 31,32,33,43

Case-4

DEMOGRAPHIC DATA

PATIENT NAME: Miss. Nisha

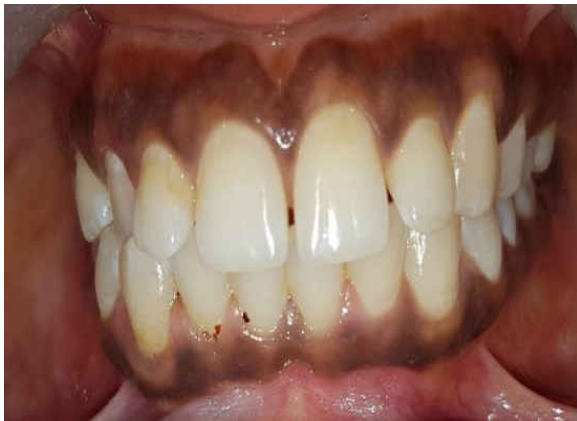DATE: 6.4.2018

OP NO: 201804041104

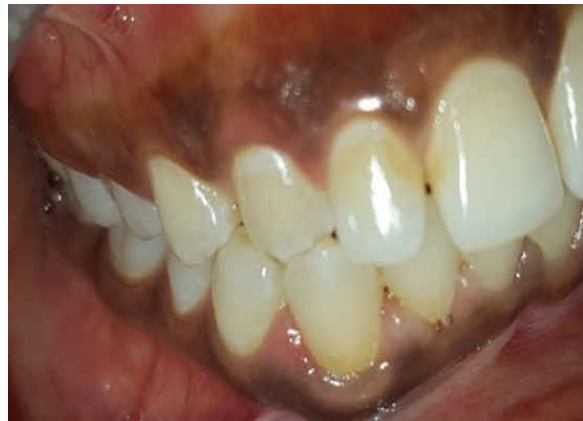AGE/SEX: 20/F

PROCEDURE: Gingivoplasty done in relation to 42,43

PRE OPERATIVE PHOTO

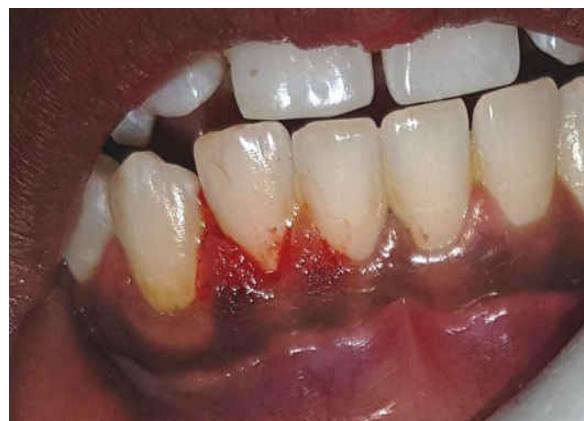
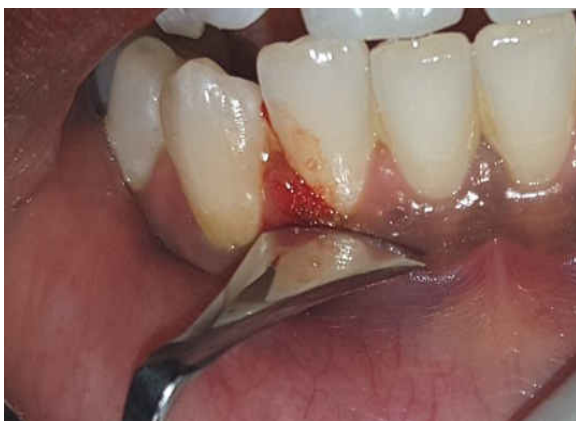
Frontal view



Right lateral view

OPERATIVE PHOTO



Gingivoplasty done in relation to 42,43

Case-5

DEMOGRAPHIC DATA

PATIENT NAME: Mrs. Jasmine

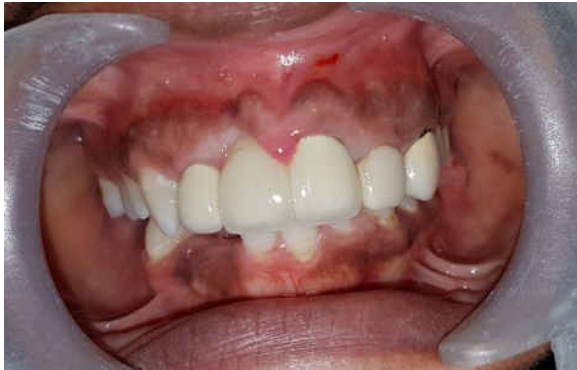DATE: 12.4.2018

OP NO: 20184120093

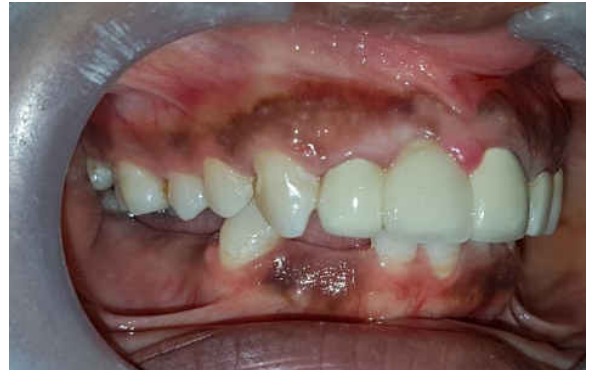AGE/SEX: 37/F

PROCEDURE: Gingivoplasty done in relation to 11,21

PRE OPERATIVE PHOTO

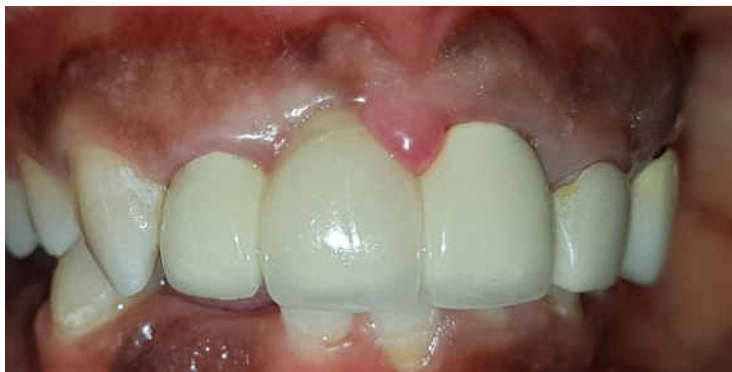

Frontal view



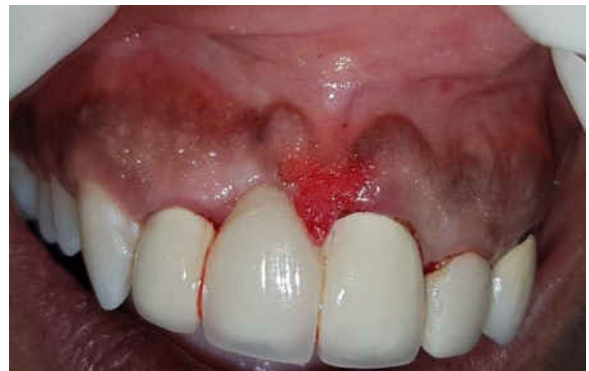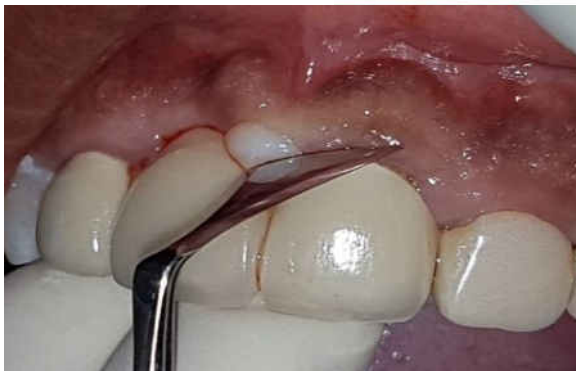Right lateral view

POST SCALING PHOTO



Labial view

OPERATIVE PHOTO



Gingivoplasty done in relation to 11,21

Case-6

DEMOGRAPHIC DATA

PATIENT NAME: Mr. Vignesh Kumar

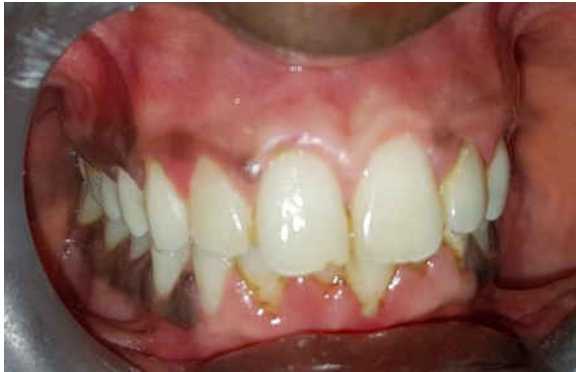DATE: 12.4.2018

OP NO: 201803100087

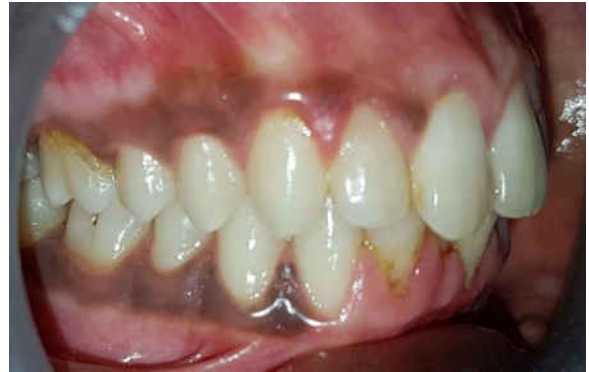AGE/SEX: 21/M

PROCEDURE: Gingivoplasty done in relation to 31,41,42,43

PRE OPERATIVE PHOTO

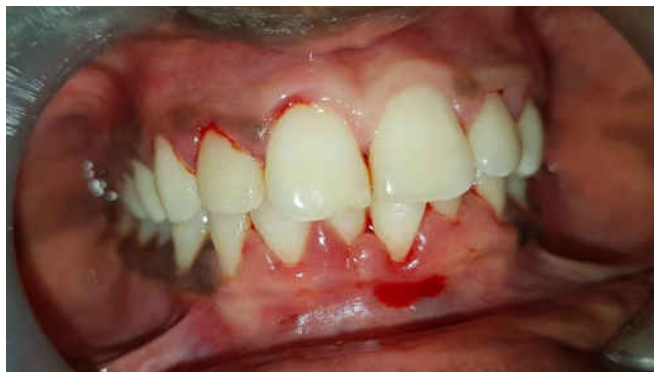

Frontal view



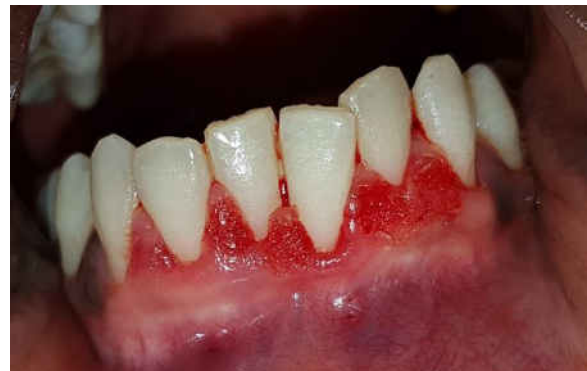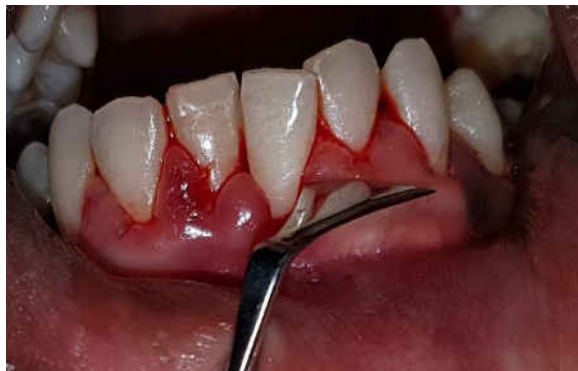Right lateral view

POST OPERATIVE SCALING



Frontal view

OPERATIVE PHOTO



Gingivoplasty done in relation to 31,41,42,43

Case-7

DEMOGRAPHIC DATA

PATIENT NAME: Miss. Mohana

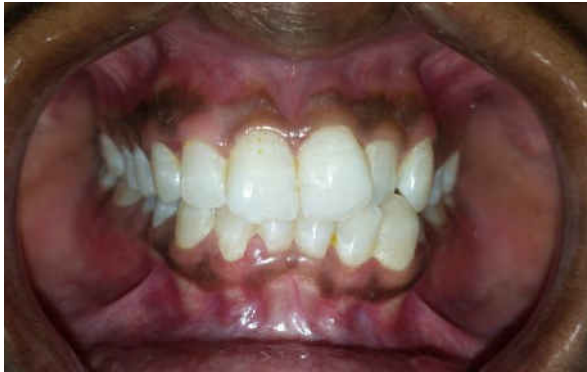DATE: 18.7.2018

OP NO: 201807180210

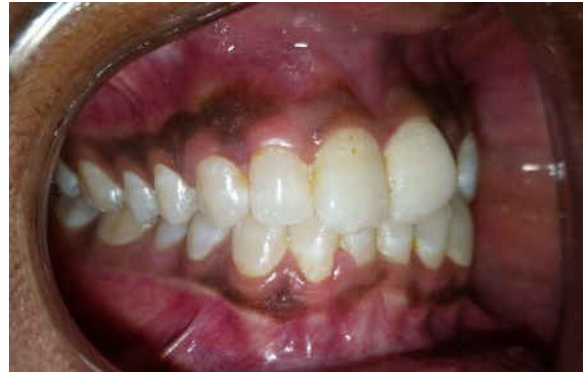AGE/SEX: 22/F

PROCEDURE: Gingivoplasty done in relation to 41,42

PRE OPERATIVE PHOTO

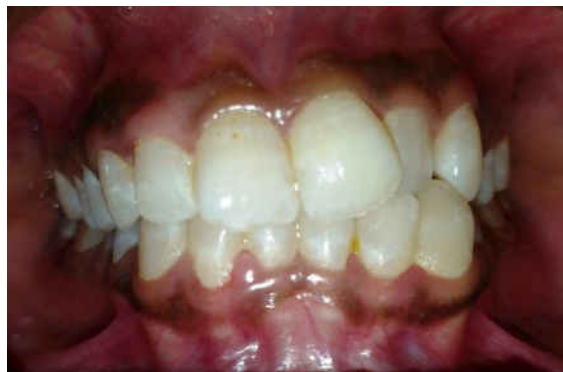

Frontal view



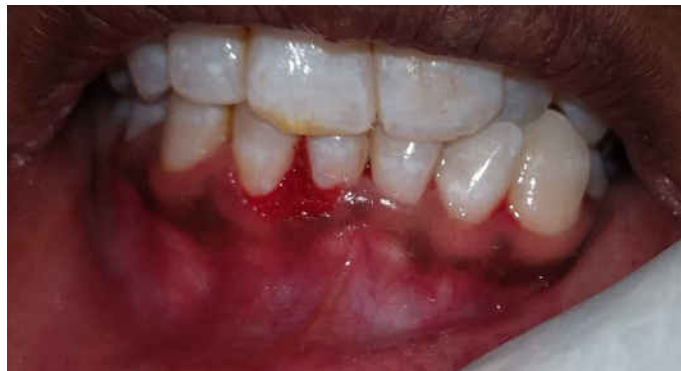Right lateral view

POST OPERATIVE SCALING



Frontal view

OPERATIVE PHOTO



Gingivoplasty done in relation to 41,42

Case-8

DEMOGRAPHIC DATA

PATIENT NAME: Mr. Naveen

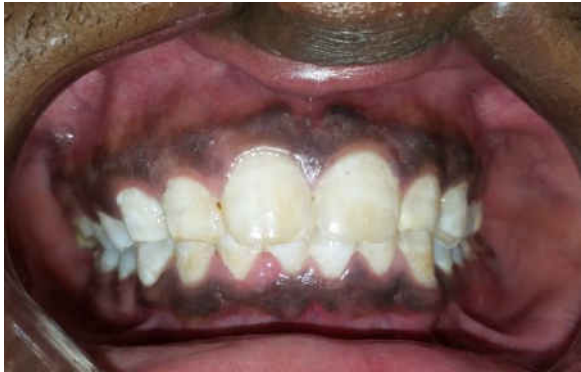DATE: 18.7.2018

OP NO: 201807180211

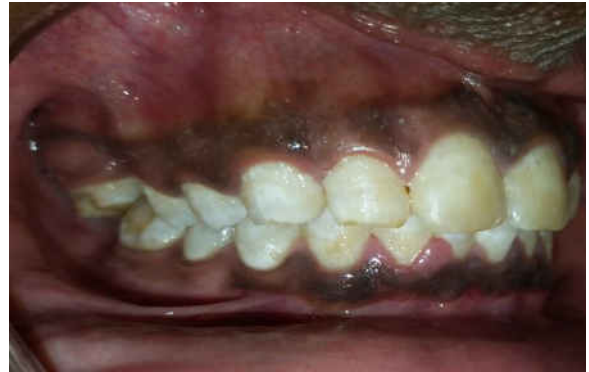AGE/SEX: 22/M

PROCEDURE: Gingivoplasty done in relation to 41,42

PRE OPERATIVE PHOTO

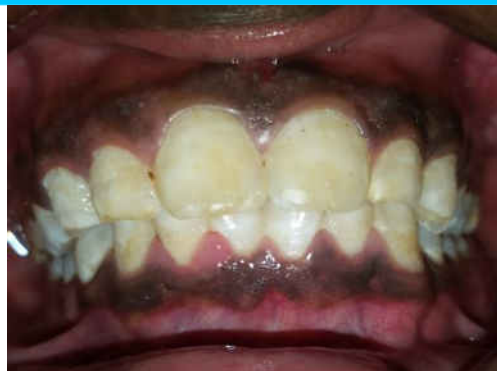

Frontal view



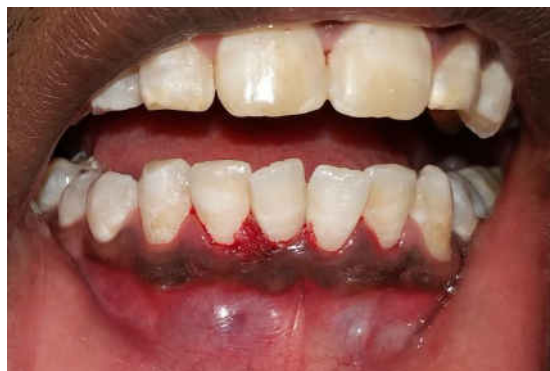Right lateral view

POST OPERATIVE SCALING



Frontal view

OPERATIVE PHOTO



Gingivoplasty done in relation to 41,42

Case-9

DEMOGRAPHIC DATA

PATIENT NAME: Miss. Anusuya

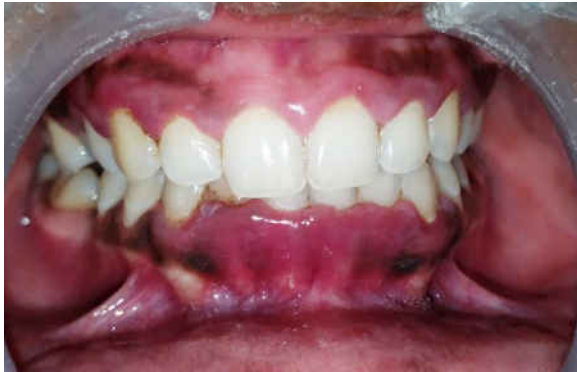DATE: 30.7.2018

OP NO: 201807300073

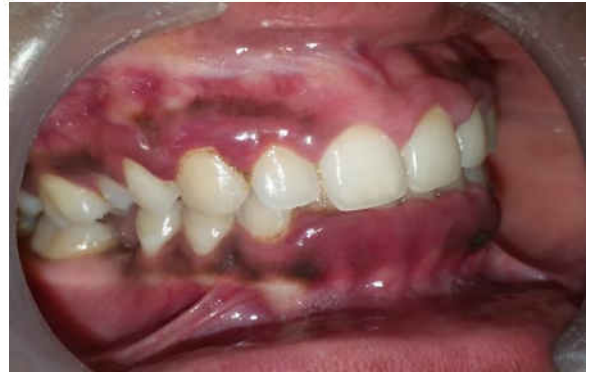AGE/SEX: 20/F

PROCEDURE: Gingivoplasty done in relation to 31,32,33,41,42,43

PRE OPERATIVE PHOTO

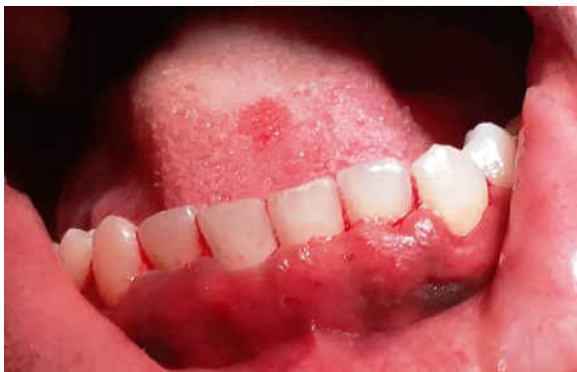

Frontal view

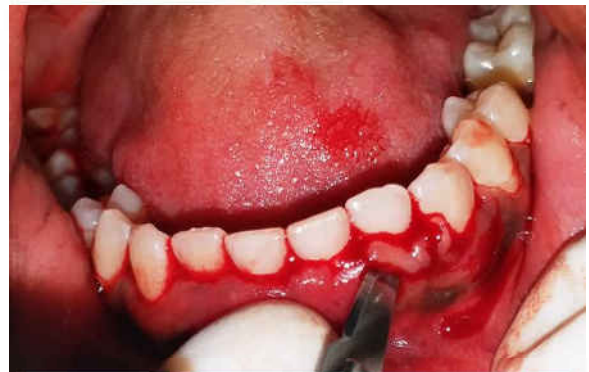

Right lateral view

OPERATIVE PHOTO

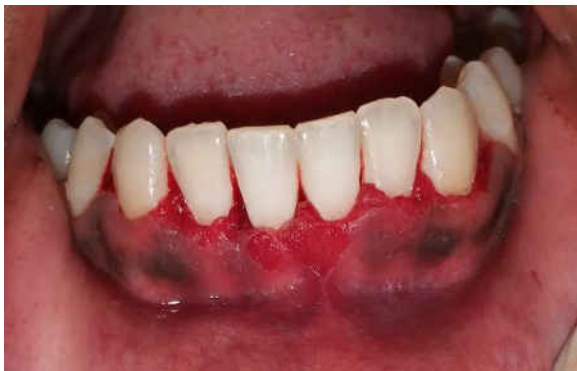

Pocket marking done

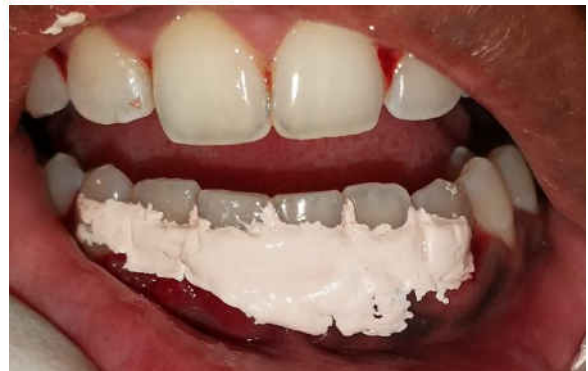

Gingivectomy done in 31,32,33,41,42,43

OPERATIVE PHOTO



Gingivoplasty done in 31,32,33,41,42,43



Periodontal dressing given in 31,32,33,41,42,43

PERIO-PLASTIC SURGERY

RIDGE REDUCTION

DEMOGRAPHIC DATA

PATIENT NAME: Mrs.Renuka

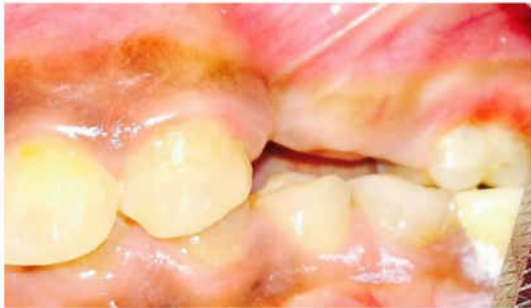DATE: 18.8.2017

OP NO: 201603090008

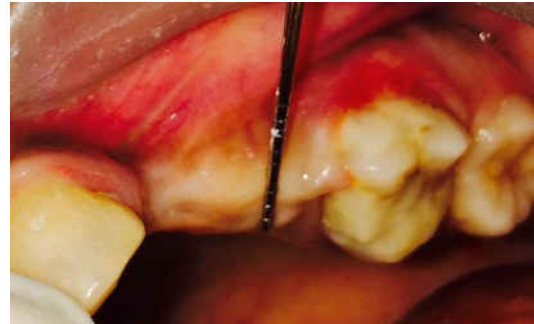AGE/SEX:24years/female

PROCEDURE: Ridge Reduction done in relation to 24,25

PRE OPERATIVE PHOTO

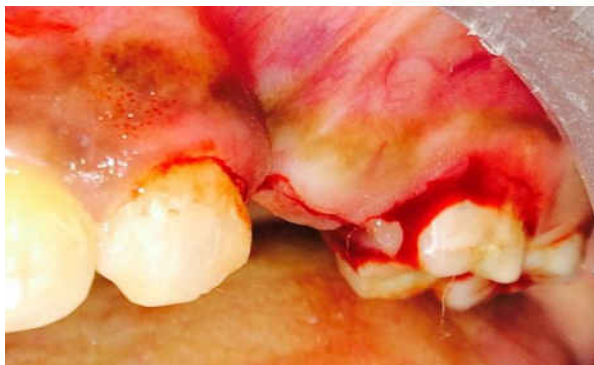

Left lateral view

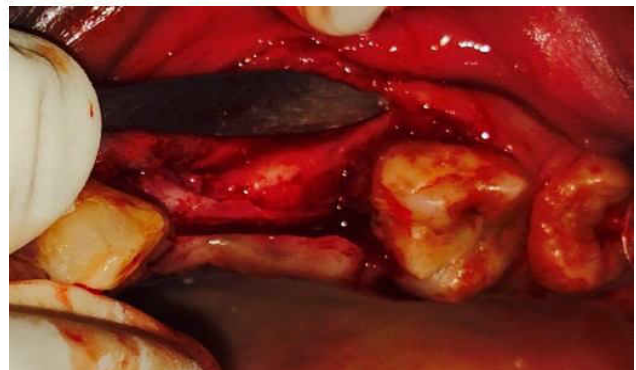

Ridge width

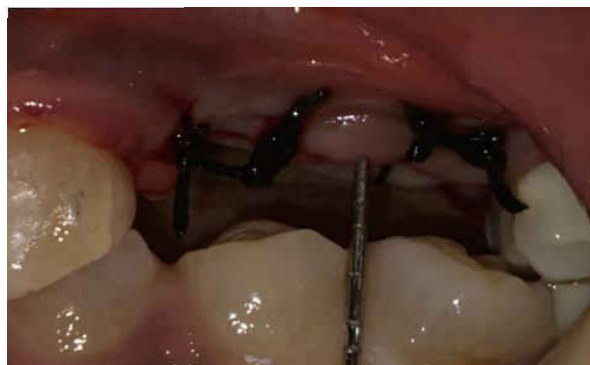OPERATIVE PHOTO



Incision placed

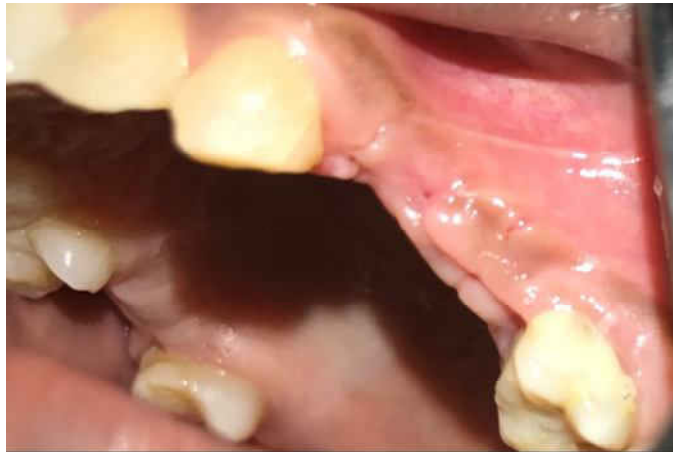

Flap Reflection Done



Sutures Placed

POST- OPERATIVE PHOTO



Frontal view

SUBEPITHELIAL CONNECTIVE TISSUE GRAFT

DEMOGRAPHIC DATA

PATIENT NAME: Mr. Sivaprasad

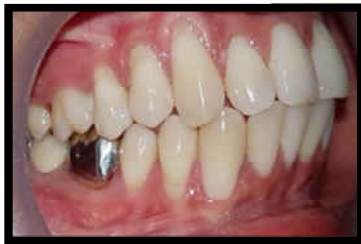DATE:14.12.18

OP NO: 201811270031

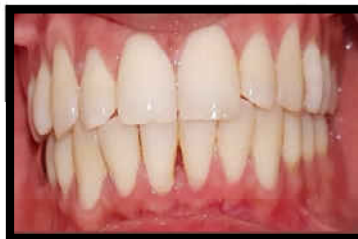AGE/SEX: 34/M

PROCEDURE: Subepithelial connective tissue graft at 23,24- macrosurgical technique

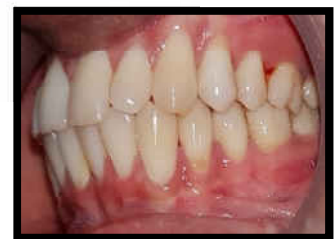PRE OPERATIVE PHOTO



Right lateral view

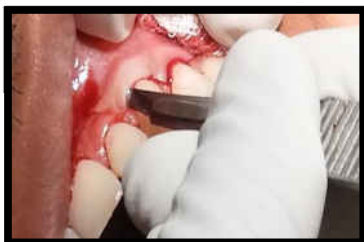

Frontal view

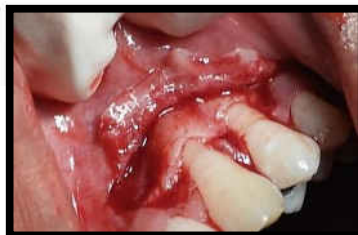

Left lateral view

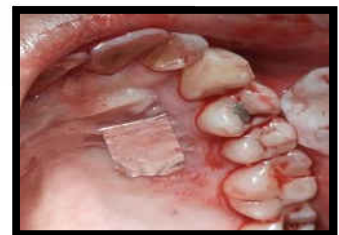OPERATIVE PHOTO 27.12.18



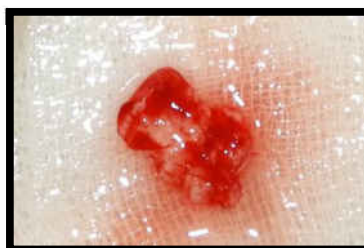Horizontal and vertical Incision placed



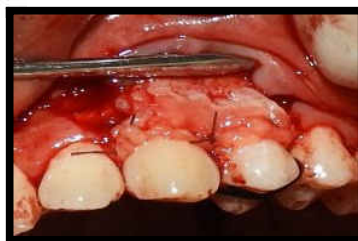
Flap raised at recipient site



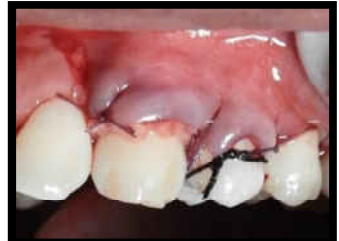Template at donor site



Harvested Subepithelial connective tissue graft



Graft secured at 23,24



Flap approximated and sutured

PATIENT NAME: Mr. Sivaprasad

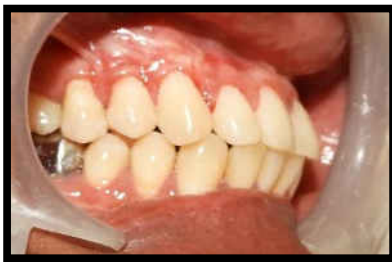DATE:14.12.18

OP NO: 201811270031

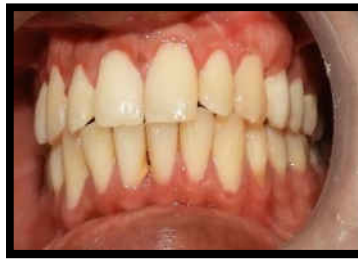AGE/SEX: 34/M

PROCEDURE: Subepithelial connective tissue graft at 13,14- microsurgical technique

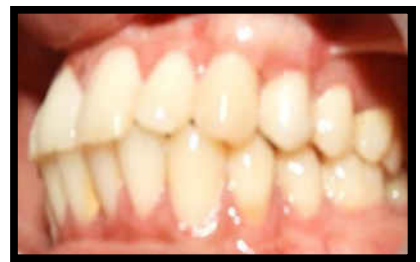3 MONTH POST OPERATIVE PHOTO
9.3.19



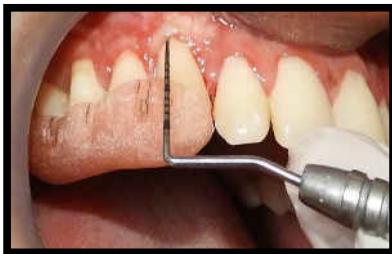Right lateral view



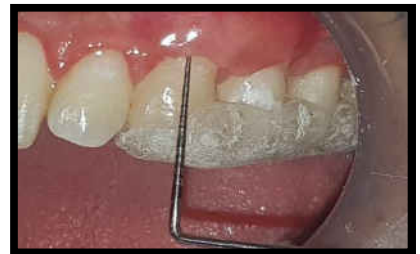Frontal view



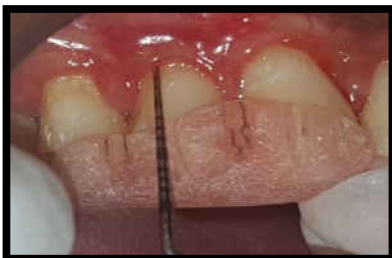Left lateral view



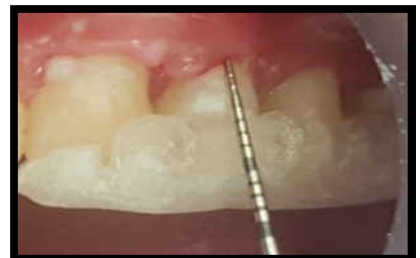13



23



14



24

CORONALLY ADVANCED FLAP, BRIDGE FLAP

DEMOGRAPHIC DATA

PATIENT NAME: Mrs.Suneetha

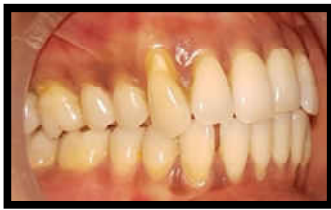DATE: 9.11.2018

OP NO: 201811090074

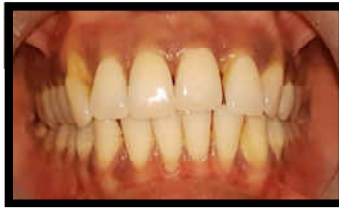AGE/SEX: 32/F

PROCEDURE: Coronally advanced flap done at 13, Bridge flap 31,32,41,42

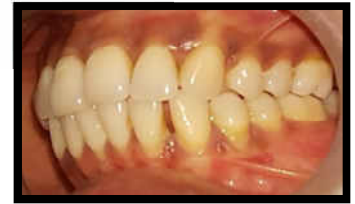PRE OPERATIVE PHOTO



Right lateral view

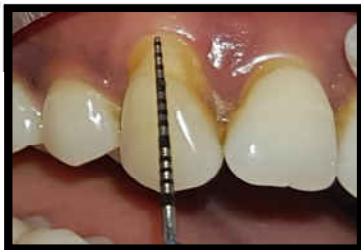

Frontal view

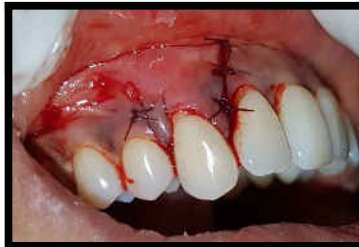

Left lateral view

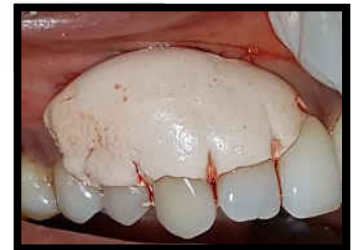OPERATIVE PHOTO 23.11.18, 30.11.18



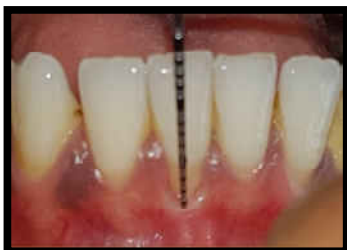Class I gingival recession 13



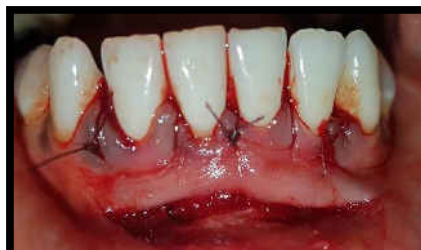Coronally advanced flap 13



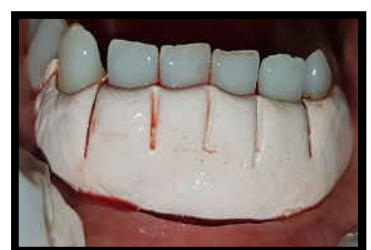Periodontal dressing placed



Class I gingival recession
31,32,41,42



Bridge flap 31,32,41,42



Periodontal dressing placed

PATIENT NAME: Mrs.Suneetha

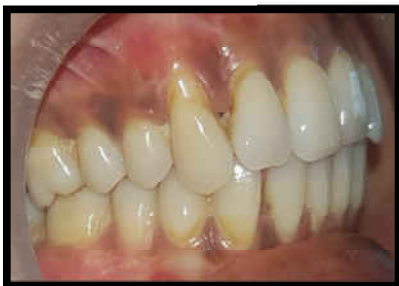DATE: 9.11.2018

OP NO: 201811090074

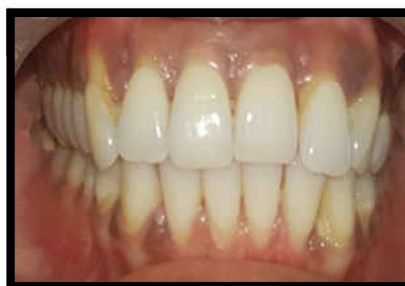AGE/SEX: 32/F

PROCEDURE: Coronally advanced flap done at 13, Bridge flap 31,32,41,42

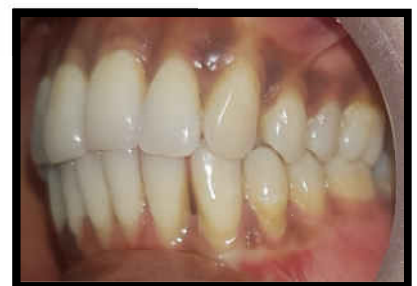1 MONTH POST OPERATIVE PHOTO
12.1.19



Right lateral view

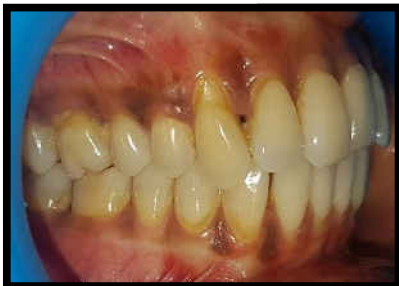

Frontal view

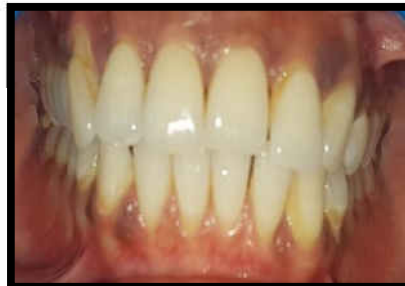

Left lateral view

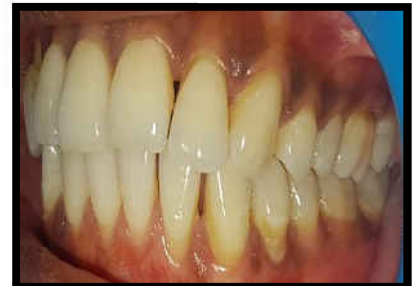3 MONTH POST OPERATIVE PHOTO
15.3.19



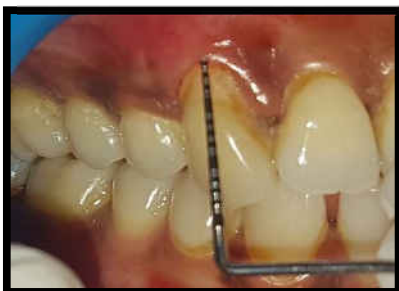Right lateral view



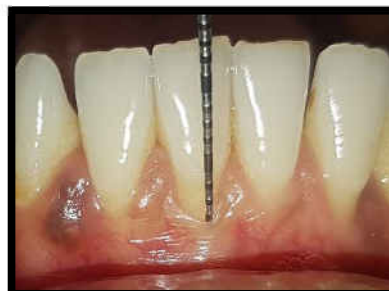Frontal view



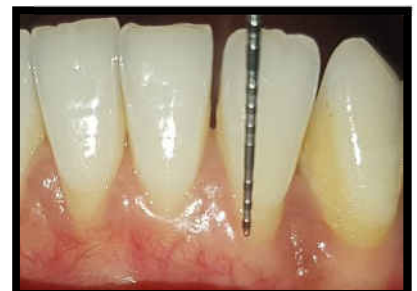Left lateral view



13



41



32

SUBEPITHELIAL CONNECTIVE TISSUE GRAFT

DEMOGRAPHIC DATA

PATIENT NAME: Mr. Vasu

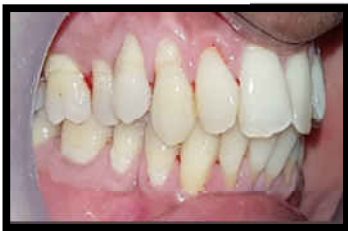DATE: 5.1.19

OP NO: 201804020055

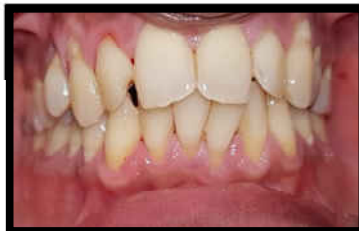AGE/SEX: 45/M

PROCEDURE: Subepithelial connective tissue graft at 23,24- macrosurgical technique

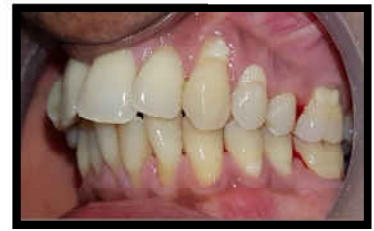PRE OPERATIVE PHOTO



Right lateral view

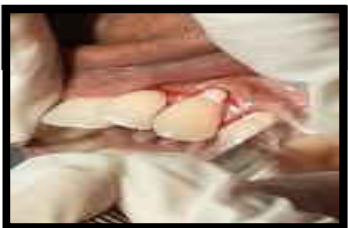

Frontal view

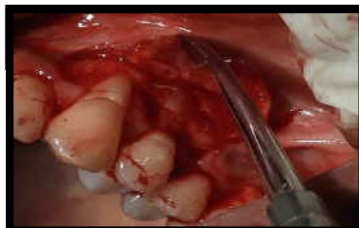


Left lateral view

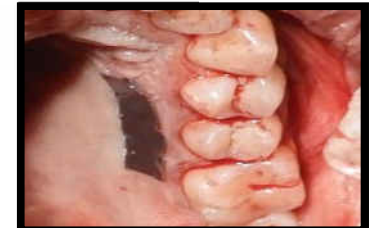OPERATIVE PHOTO 29.1.19



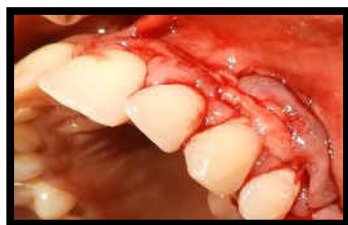Horizontal and vertical Incision placed



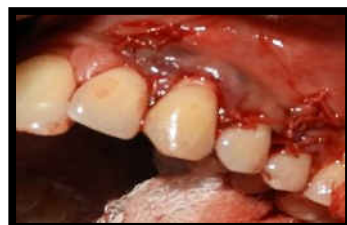Flap raised at recipient site



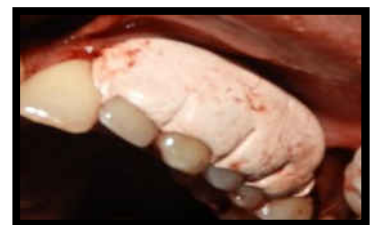Template at donor site



Harvested Subepithelial connective tissue graft secured



Flap approximated and sutured



Periodontal dressing placed

BIOPSY

EXCISION BIOPSY

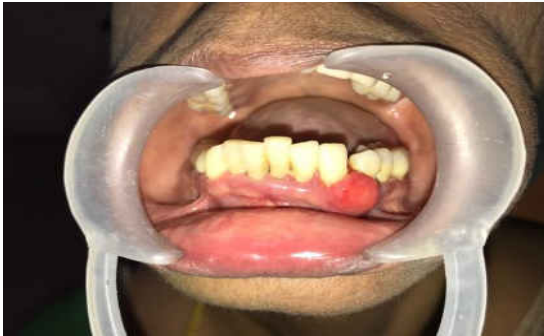DEMOGRAPHIC DATA

PATIENT NAME: Mrs.Kowsalya

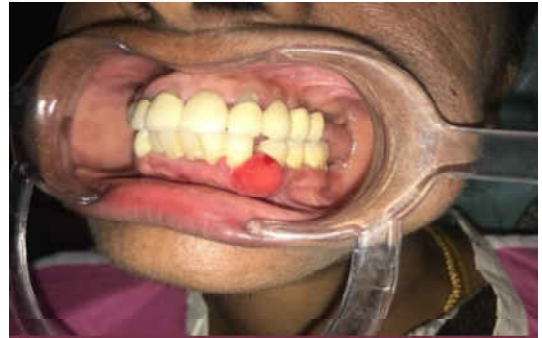OP NO: 201712140024

AGE/SEX:60year/Female

PRE OPERATIVE PHOTO

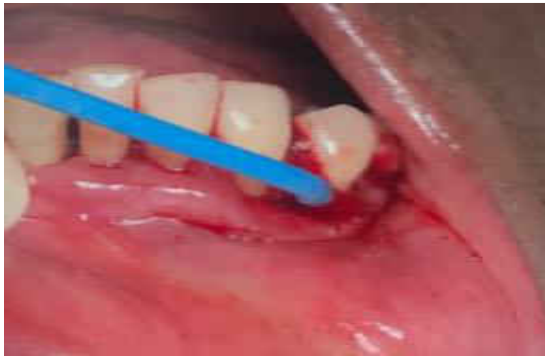

Frontal view

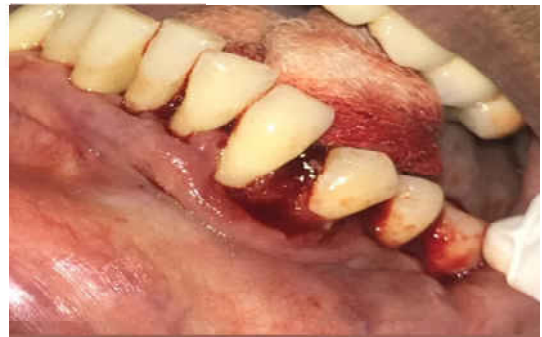

Post- Phase-I therapy

OPERATIVE PHOTO

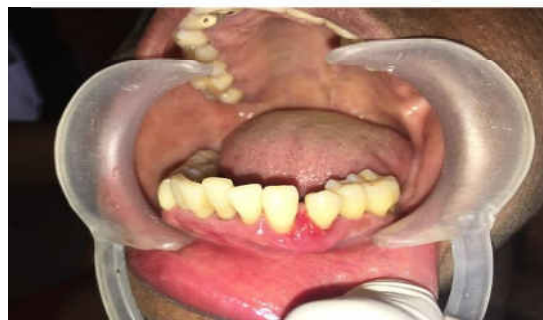

Excision done using Cautry



Excision Done

POST- OPERATIVE PHOTO



Frontal view

MUCOCELE EXCISION

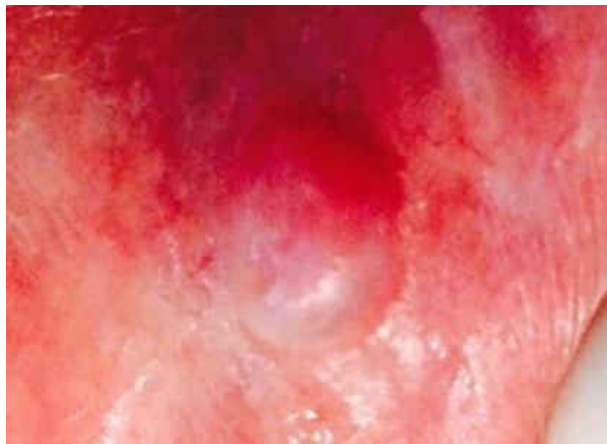DEMOGRAPHIC DATA

PATIENT NAME: Ms.Akshara

AGE/SEX: 21/F

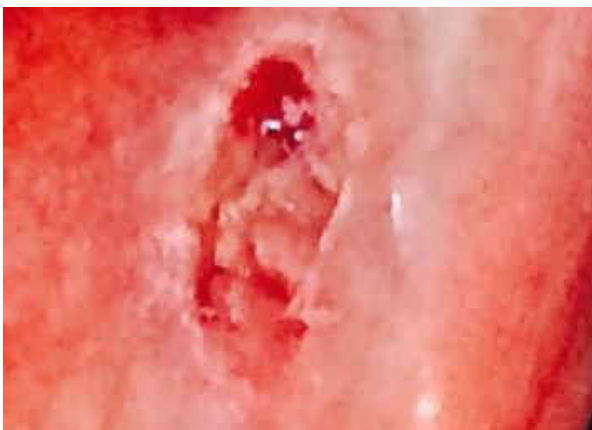OP NO:201701040021

PRE- OPERATIVE PHOTO

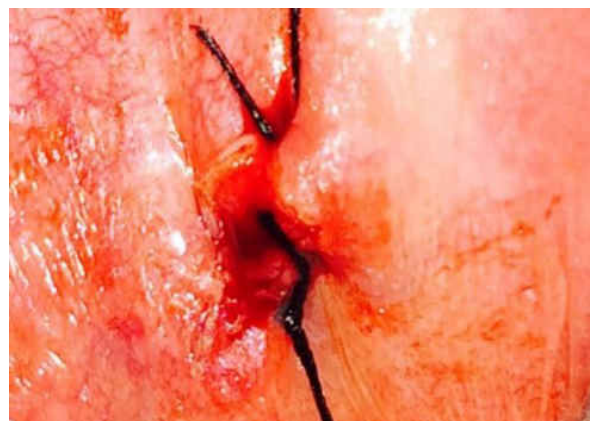

Mucoccele

OPERATIVE PHOTO



Excision done



Sutures placed

Mucocele

DEMOGRAPHIC DATA

PATIENT NAME: Mr. Sourav kumar

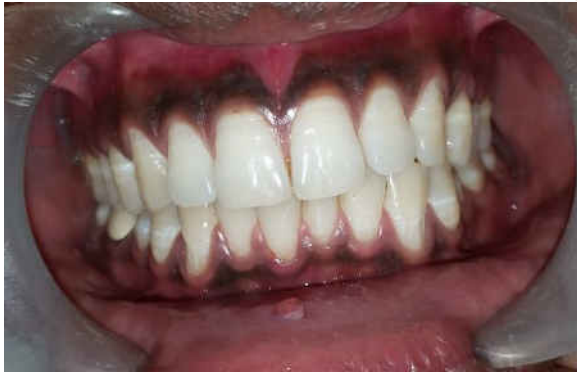DATE: 13.7.2018

OP NO: 201807030113

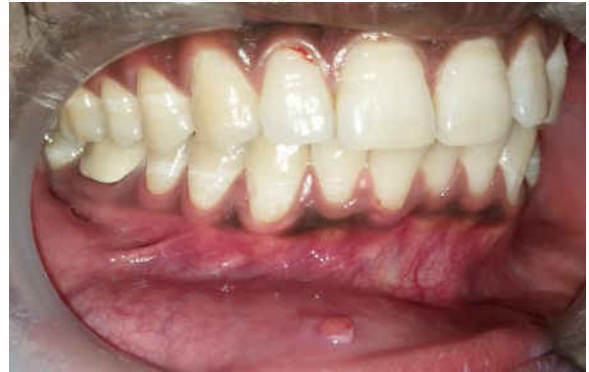AGE/SEX: 24/M

PROCEDURE: Excision of traumatic fibroma done in relation to lower labial mucosa

PRE OPERATIVE PHOTO

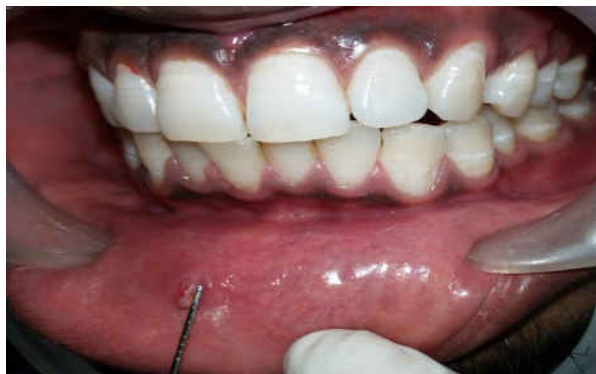

Frontal view



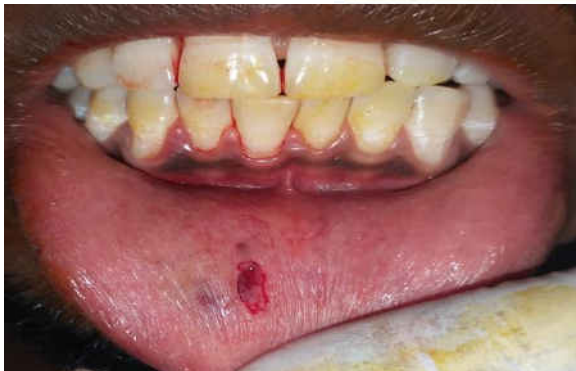Right lateral view

PRE OPERATIVE PHOTO

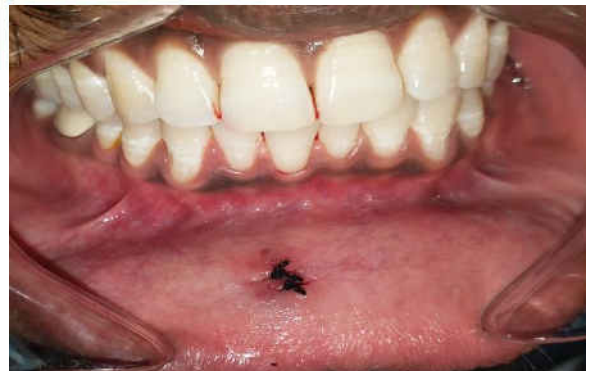

3*3mm traumatic fibroma in lower labial mucosa

OPERATIVE PHOTO



Excision done in lower labial mucosa



Sutures given in lower labial mucosa

FLAP SURGERY

Case-1

DEMOGRAPHIC DATA

PATIENT NAME: Mr. Elumalai

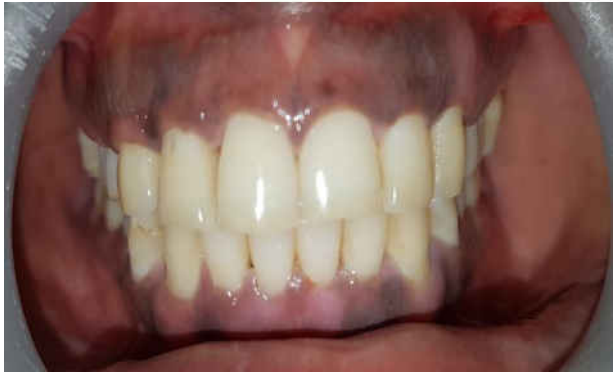DATE: 12.7.2018

OP NO: 201709180002

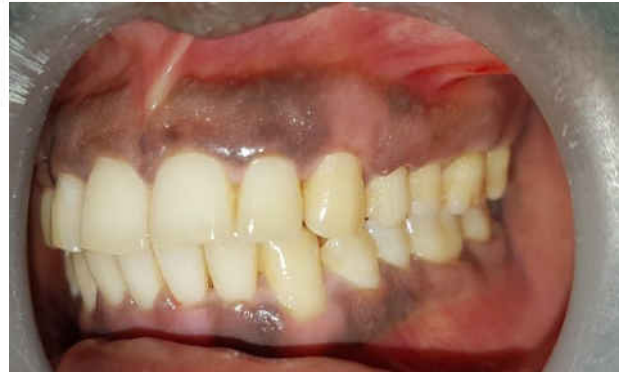AGE/SEX: 62/M

PROCEDURE: Flap and surgery done in relation to I quadrant

PRE OPERATIVE PHOTO

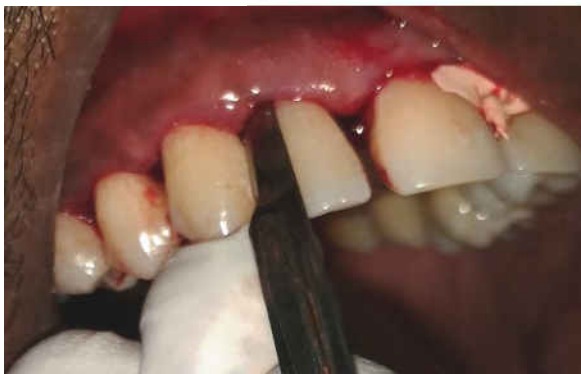

Front view

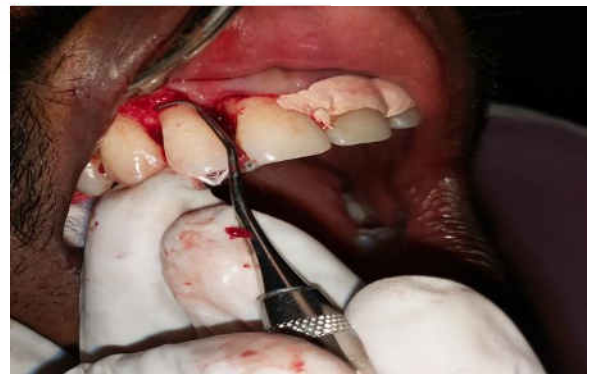

Left lateral view

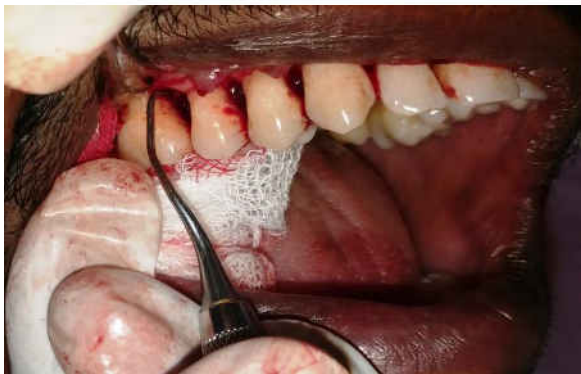OPERATIVE PHOTO



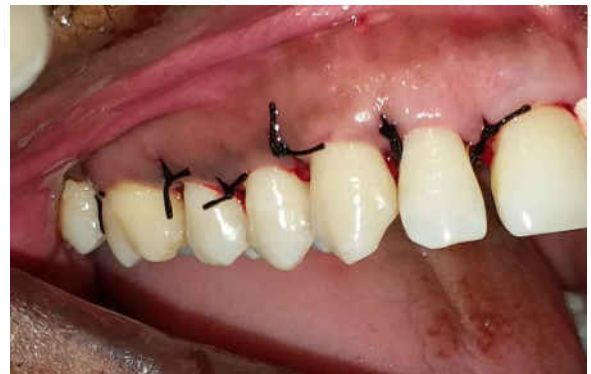Intrasulcular incision given in 12



Scaling & root planning in 12 midlabial aspect



Scaling & root planning in 16 mesiobuccal aspect



Simple interrupted sutures given

Case-2

DEMOGRAPHIC DATA

PATIENT NAME: Mr. Kulakulantahyan

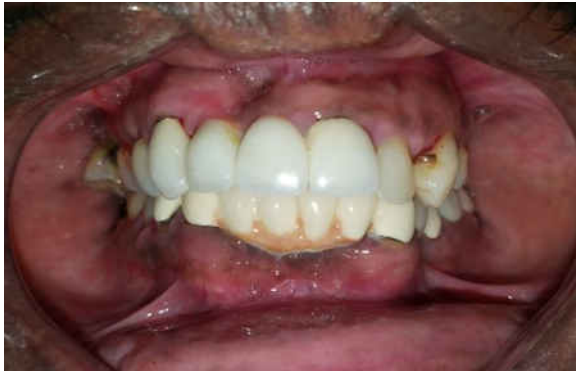DATE: 14.7.2018

OP NO: 201806230083

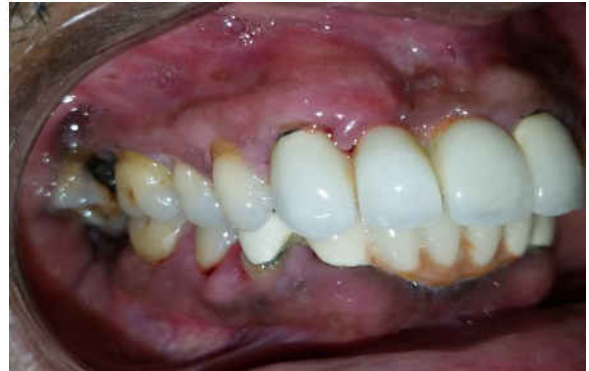AGE/SEX: 50/M

PROCEDURE: Flap and surgery done in relation to I and II quadrant

PRE OPERATIVE PHOTO

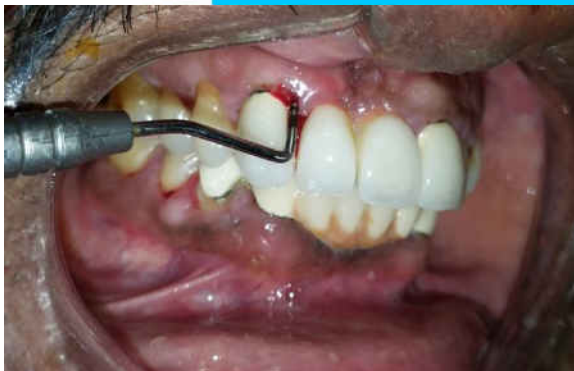

Front view

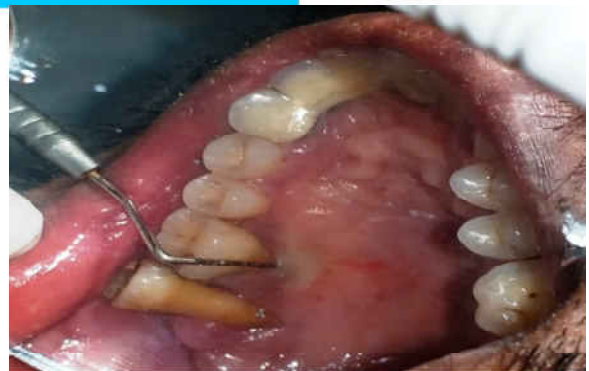

Right lateral view

PRE OPERATIVE MEASUREMENTS

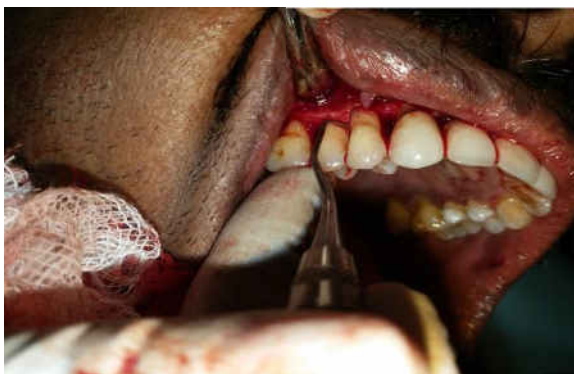

PPD 13mm in mesiobuccal aspect of 13

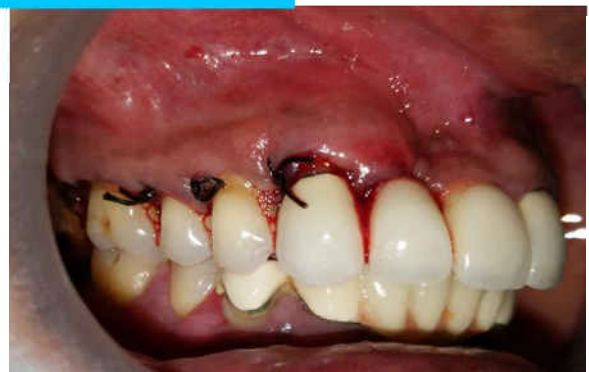

PPD 7mm in midlingual aspect of 16

OPERATIVE PHOTO



Scaling & root planning in 15 mesiolabial aspect



Simple interrupted sutures given

CASE-3

DEMOGRAPHIC DATA

PATIENT NAME : Mrs. Annapoorna Pol

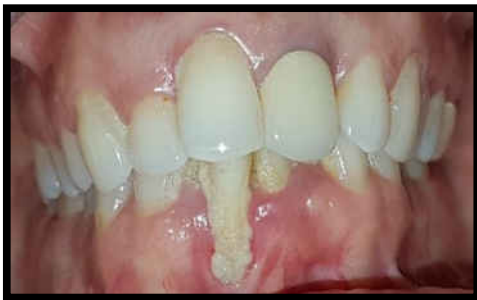DATE: 29.5.18

OP NO: 201711270037

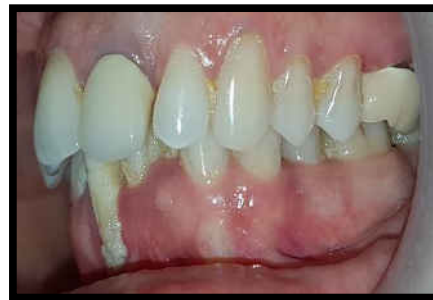AGE/SEX: 53/F

PROCEDURE: Localized Flap Surgery -26,27

PRE OPERATIVE PHOTO – 29.5.18

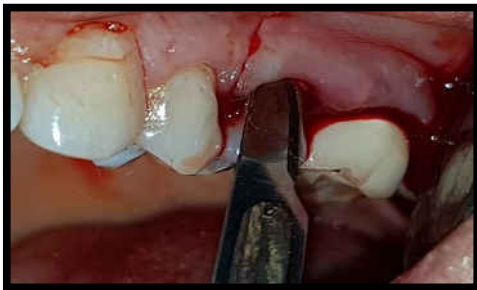


Frontal view

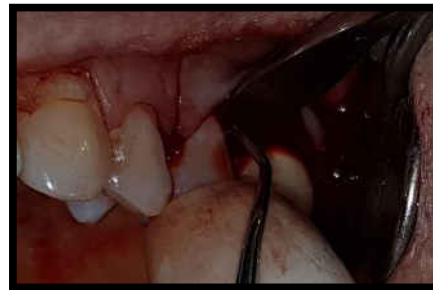

Left lateral view

PRE OPERATIVE MEASUREMENTS

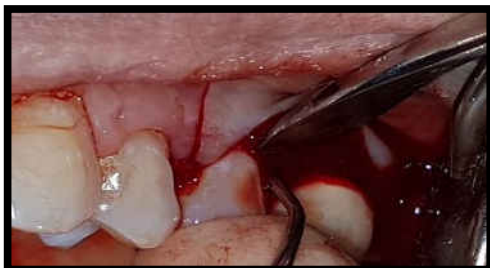

Incision placed 26,27

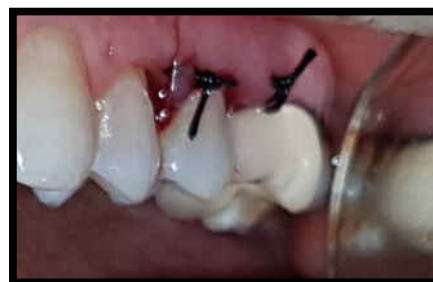

Mucoperiosteal flap elevated 26,27

OPERATIVE PHOTO-



SRP -26,27



3-0 Black silk interrupted sutures placed

CASE-4

DEMOGRAPHIC DATA

PATIENT NAME :Mr. Selvaraja

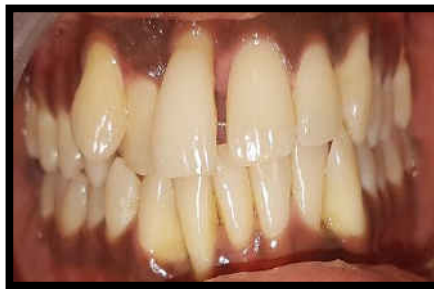DATE: 8.5.18

OP NO: 201805050100

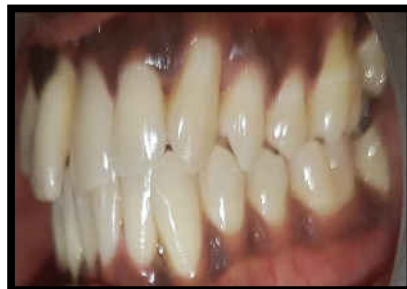AGE/SEX: 27//M

PROCEDURE: Flap surgery 1st & 2nd Quadrant

PRE OPERATIVE PHOTO – 8.5.18

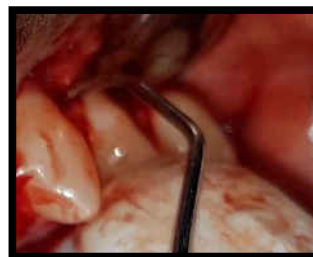
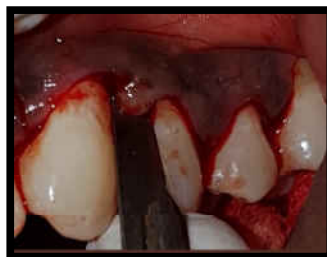
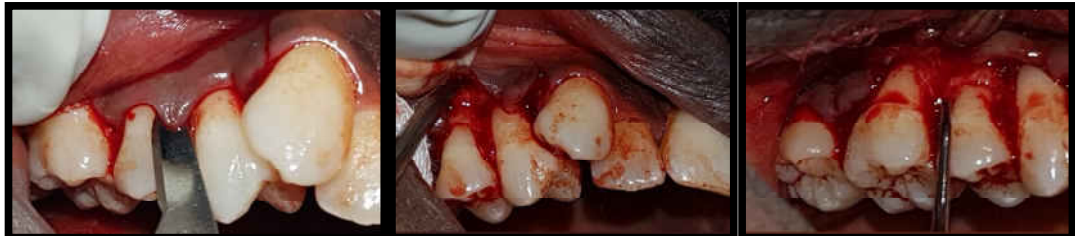
Frontal view



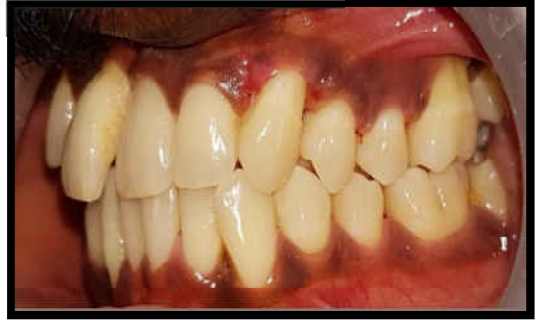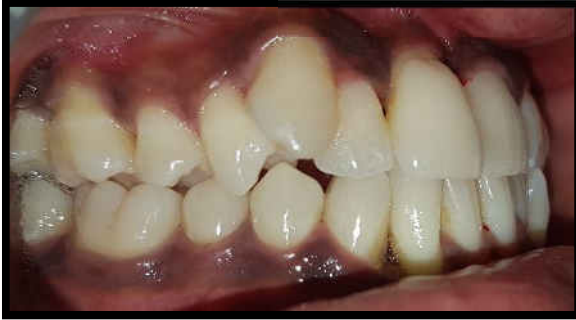Left lateral view

OPERATIVE PHOTO 22.5.18, 25.5.18



Incision, flap elevation and SRP 1st, 2nd Quadrant

1 WEEK POST OPERATIVE



1st and 2nd Quadrant

CASE-5

DEMOGRAPHIC DATA

PATIENT NAME : Mrs. Sonia Pudota

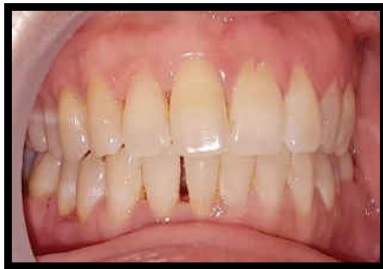DATE: 31.7.18

OP NO: CSSH 294040

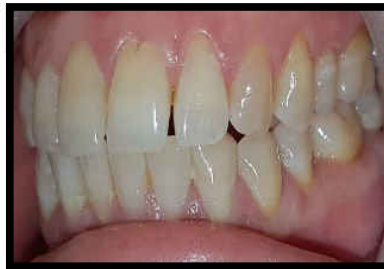AGE/SEX: 46/F

PROCEDURE: Localized Flap Surgery -34,35,36,37

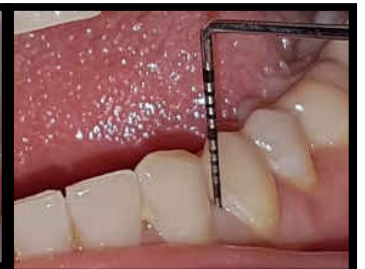PRE OPERATIVE PHOTO – 31.7.18



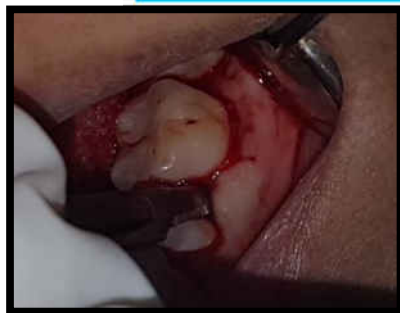Frontal view



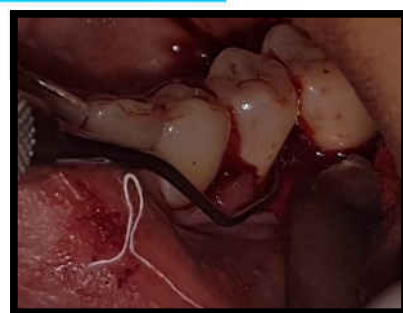
Left lateral view



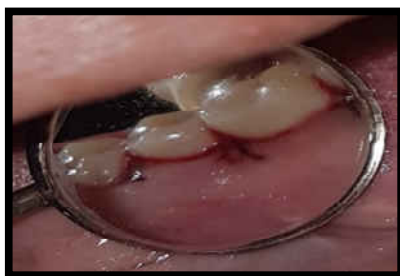OPERATIVE PHOTO-31.7.18



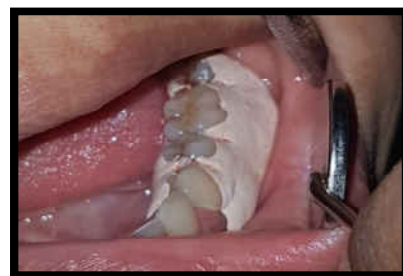Incision placed



Mucoperiosteal flap elevated, SRP 34,35,36,37



3-0 Black silk interrupted sutures placed



Periodontal dressing given

CASE-6

DEMOGRAPHIC DATA

PATIENT NAME: Mr. Chengalvaryan

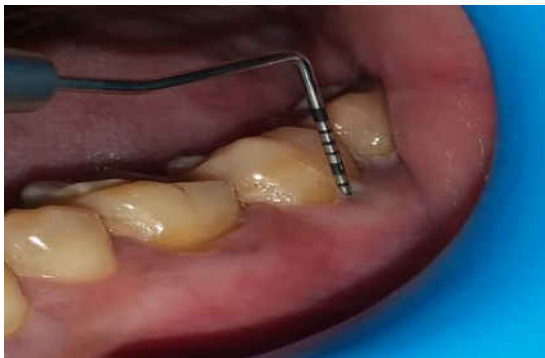DATE: 2.3.2019

OP NO: 201809180133

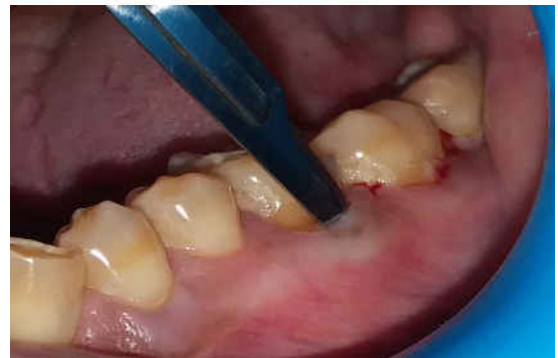AGE/SEX: 63/M

PROCEDURE: Flap surgery done in 36,37,38 with graft in 37

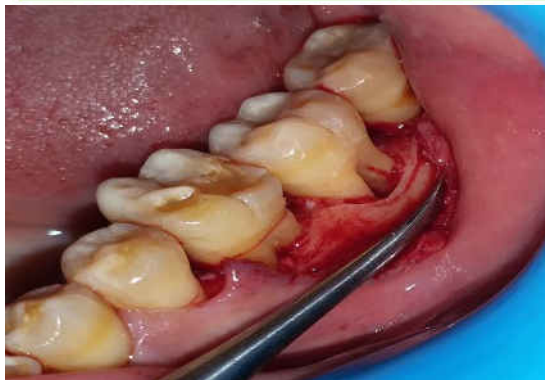OPERATIVE PHOTO



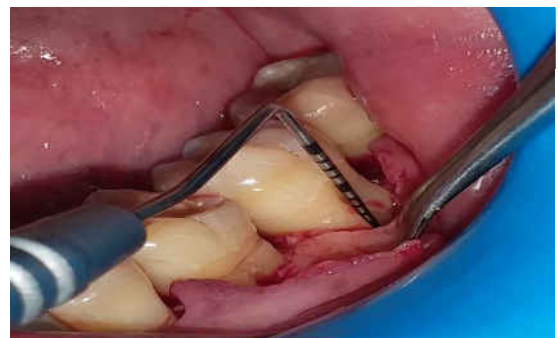PPD -7 mm in midbuccal aspect of 37



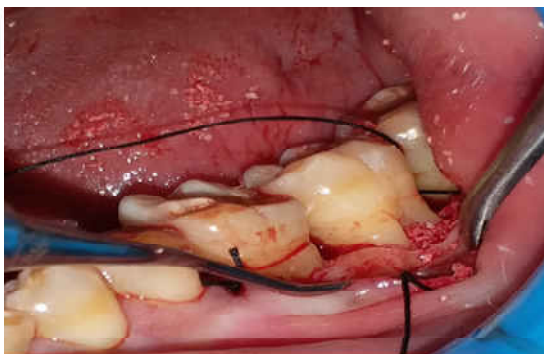
Intrasulcular incision given in 36



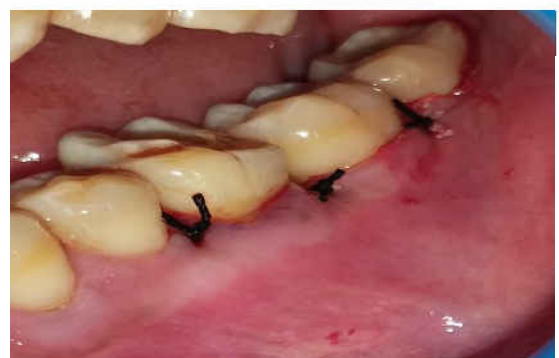Full thickness mucoperiosteal flap elevation done



5mm intrabony defect in midbuccal aspect of 37



Bone graft placed in to 36 distobuccal aspect



Simple interrupted sutures given

CASE-7

DEMOGRAPHIC DATA

PATIENT NAME: Mrs. Revathi Sampath

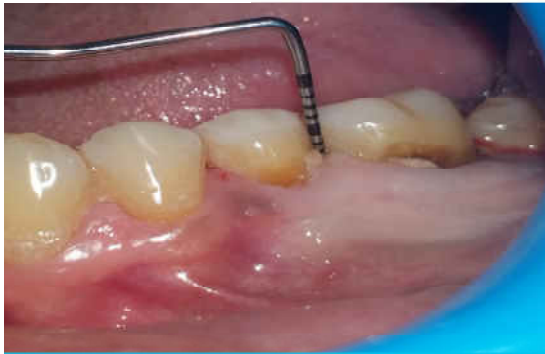DATE: 26.2.2019

OP NO: 20190206012

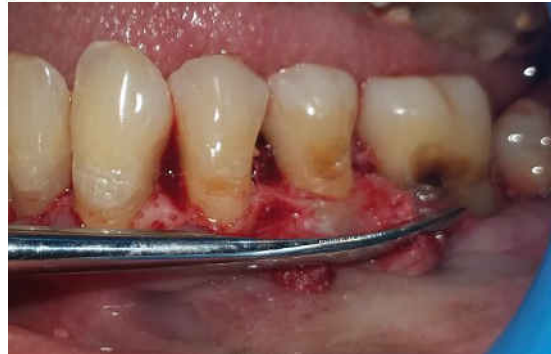AGE/SEX: 62/F

PROCEDURE: Flap surgery done in relation to III quadrant with bone graft in 36

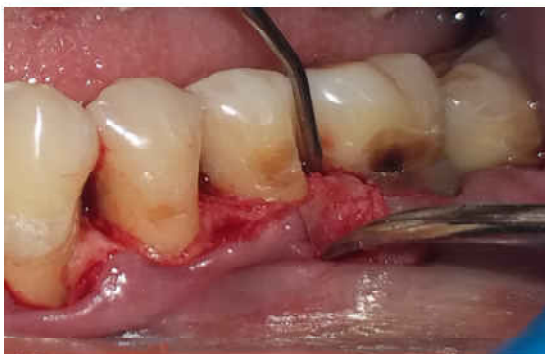OPERATIVE PHOTO



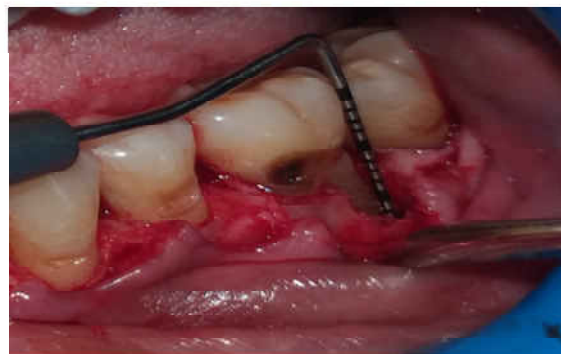PPD -7 mm in mesiobuccal aspect of 36



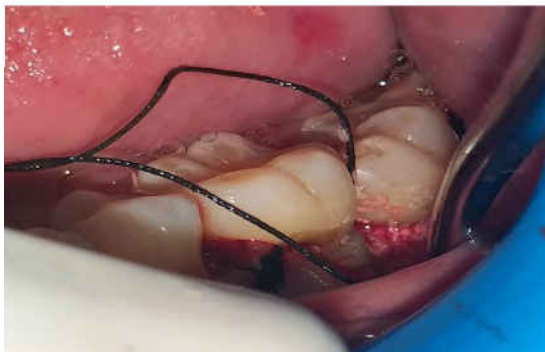Full thickness mucoperiosteal flap elevation done



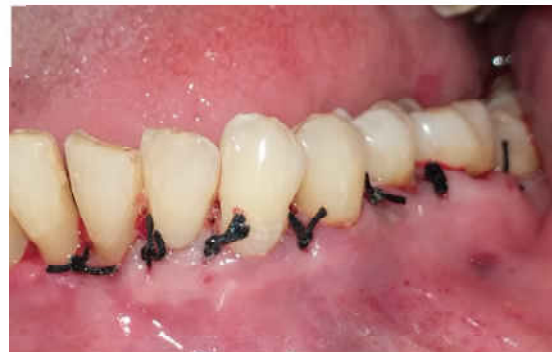Scaling & root planning in 36 mesiolabial aspect



3mm intrabony defect in distobuccal aspect of 36



Bone graft placed in to 36 distobuccal aspect



Simple interrupted sutures given

CASE-8

DEMOGRAPHIC DATA

PATIENT NAME: Mr. Dhandapani

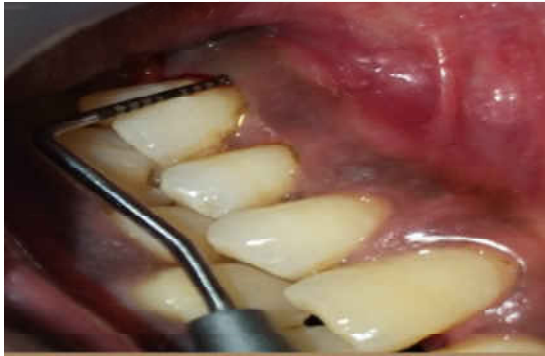DATE: 15.12.2018

OP NO:2018111500138

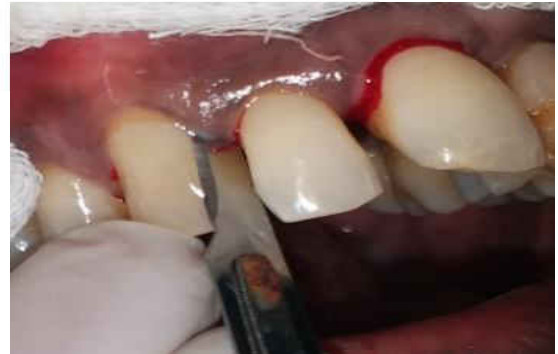AGE/SEX: 39/M

PROCEDURE: Flap surgery done in relation to I quadrant with graft placed in 16

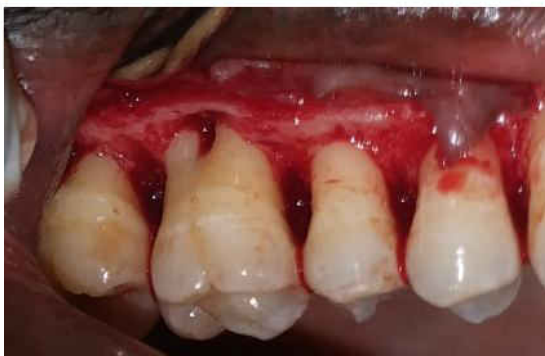OPERATIVE PHOTO



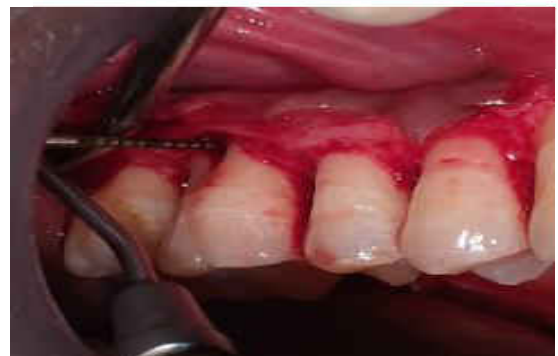PPD -7 mm in distobuccal aspect of 16



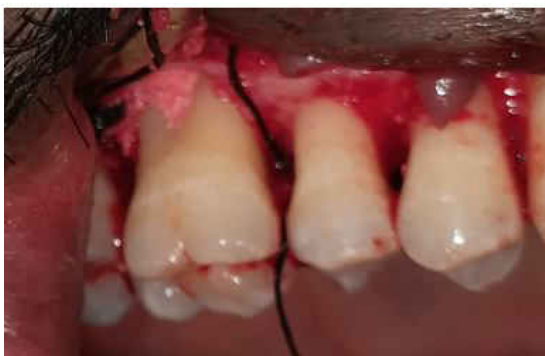Intrasulcular incision given in 13



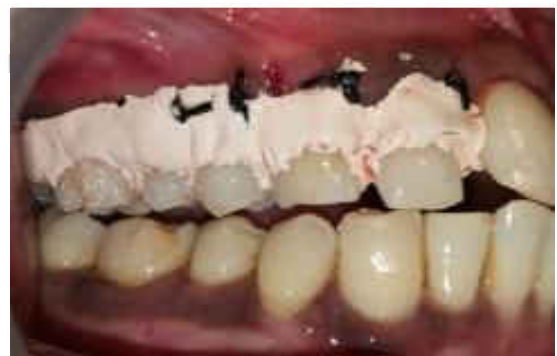Full thickness mucoperiosteal flap elevation done



PPD- 6mm horizontal component of furcation defect



Bone graft placed in to 16 furcation defect



Simple interrupted sutures & COE pack given

CASE-8

DEMOGRAPHIC DATA

PATIENT NAME: Mr. Murali kannan

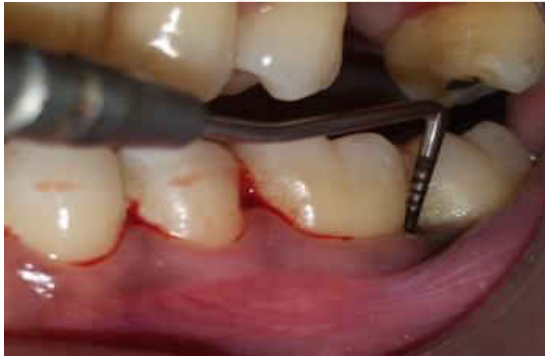DATE: 26.12.2018

OP NO: CSSH 309998

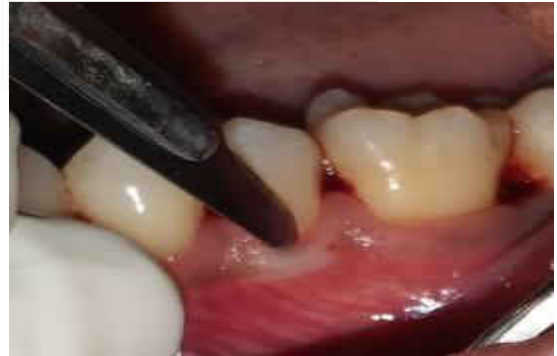AGE/SEX: 41/M

PROCEDURE: Flap surgery done in III and IV quadrant with graft in 46,47 &37

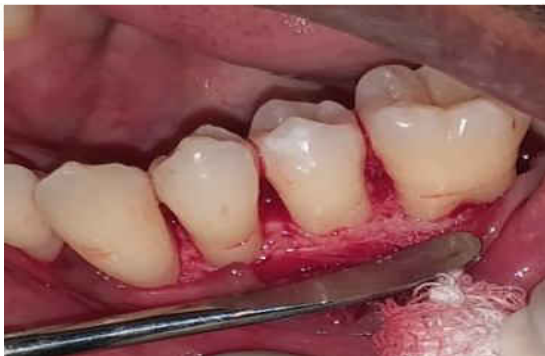OPERATIVE PHOTO



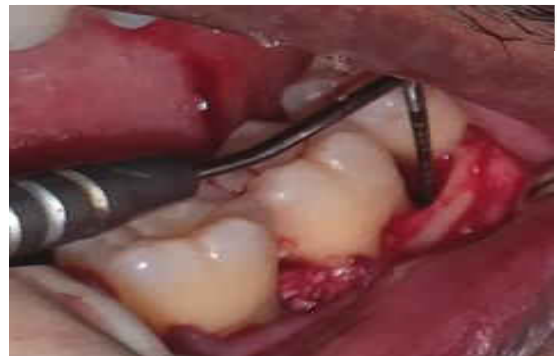PPD -10 mm in distobuccal aspect of 36



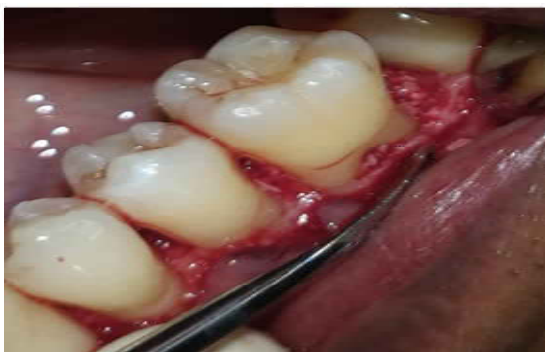Intrasulcular incision given in 35



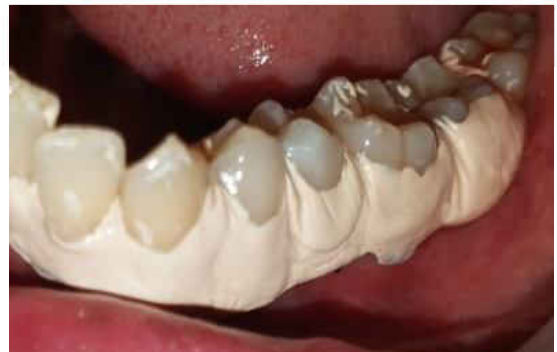Full thickness mucoperiosteal flap elevation done



6mm intrabony defect in distobuccal aspect of 37



Bone graft placed in to 36 distobuccal aspect



Simple interrupted sutures & COE pack given

CASE-9

DEMOGRAPHIC DATA

PATIENT NAME: Mr.Praveen Kumar Bhagat

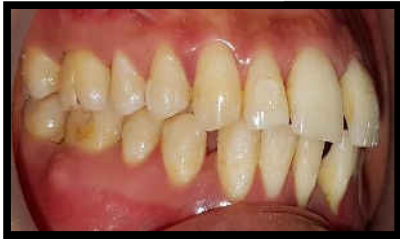DATE: 18.8.2018

OP NO: 201807120043

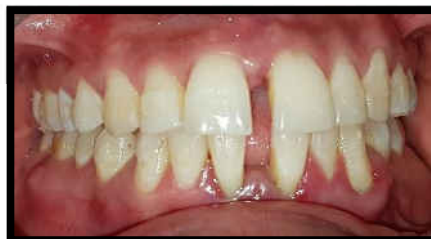AGE/SEX: 29/M

PROCEDURE: Flap and surgery done in relation to I quadrant ,bone graft placed at 15,16

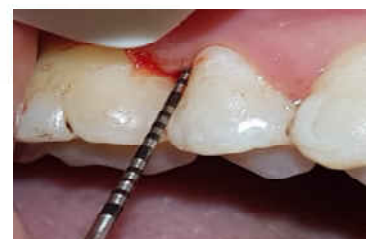PRE OPERATIVE PHOTO



Right lateral view

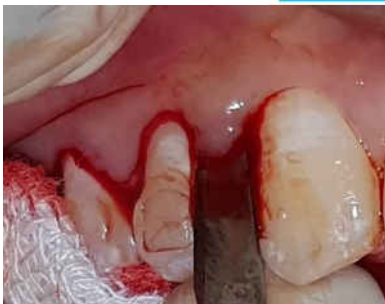

Frontal view

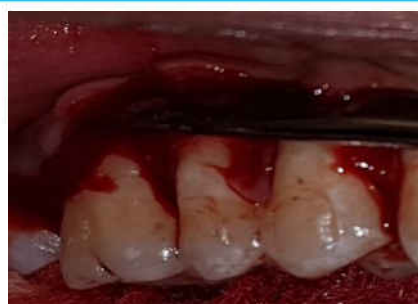

PPD (UNC- 15probe) -5mm in mesiolabial aspect of 16

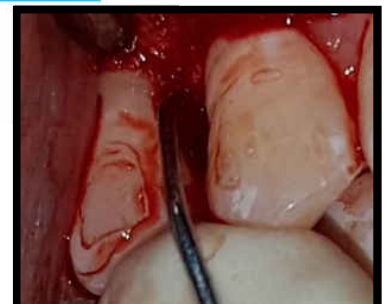
OPERATIVE PHOTO



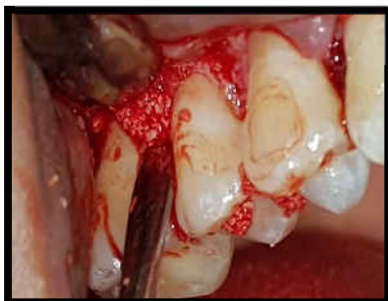
Incision placed



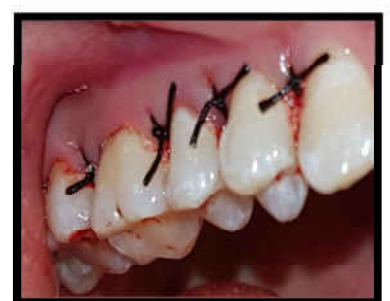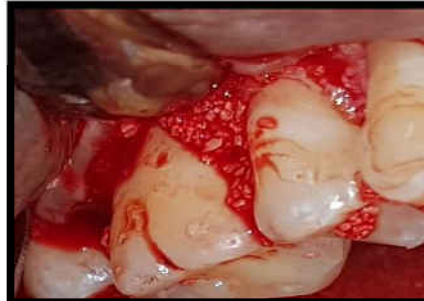
Full thickness mucoperiosteal flap elevated



Open flap debridement done



Bone graft placed at 15,16



Sutures placed

CASE-10

DEMOGRAPHIC DATA

PATIENT NAME: Mrs.Suriya

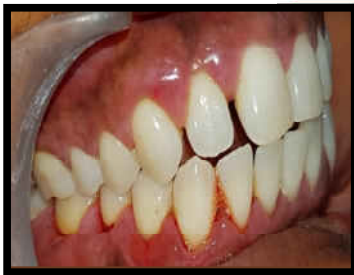DATE: 26.12.18

OP NO: 201807120043

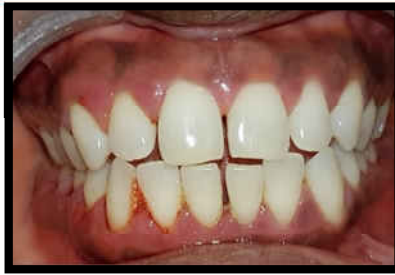AGE/SEX:36/F

PROCEDURE: Flap and surgery done in relation to I,II quadrant ,bone graft placed at 26

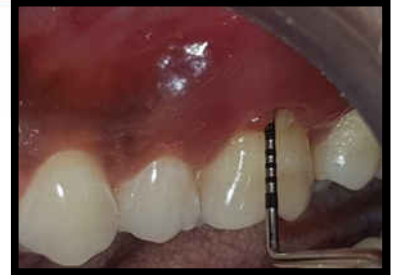PRE OPERATIVE PHOTO 26.12.18



Right lateral view

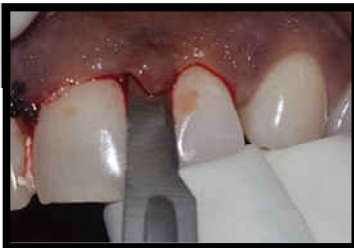

Frontal view

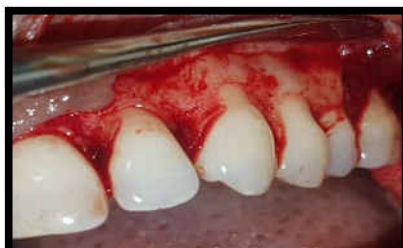

PPD (UNC- 15probe) -1o mm in midbuccal aspect of 26

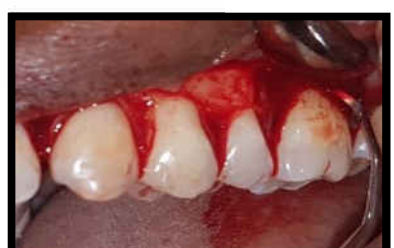OPERATIVE PHOTO 31.1.19



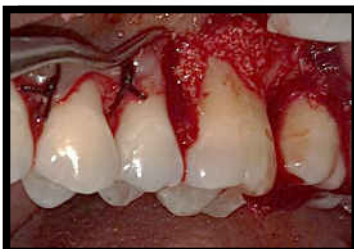Incision placed



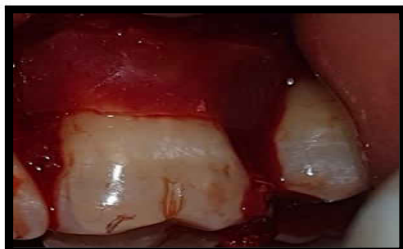
Full thickness mucoperiosteal flap elevated



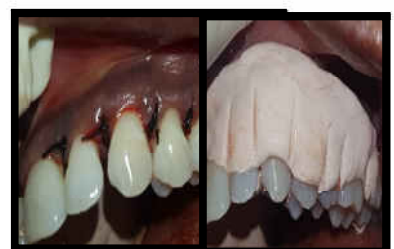Open flap debridement done



Bone graft placed at 26



GTR membrane placed at 26



Sutures,periodontal dressing placed

IMPLANT AND PERI-IMPLANTITIS MANGEMENT

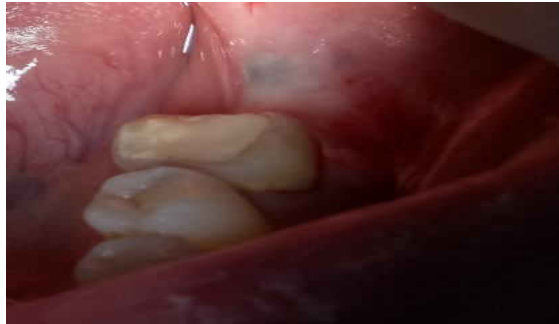Case-1

DEMOGRAPHIC DATA

PATIENT NAME: Mr. Latha **AGE/SEX:** 54/Female

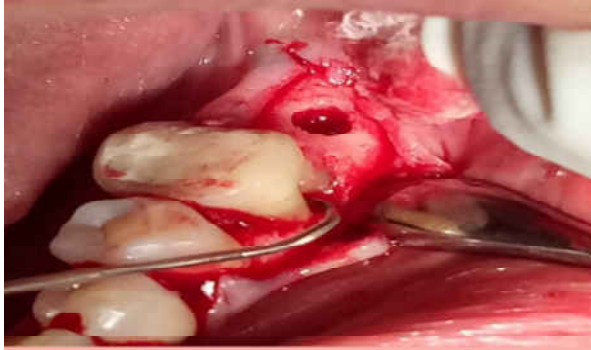
OP NO: 201802160052

PRE OPERATIVE PHOTO

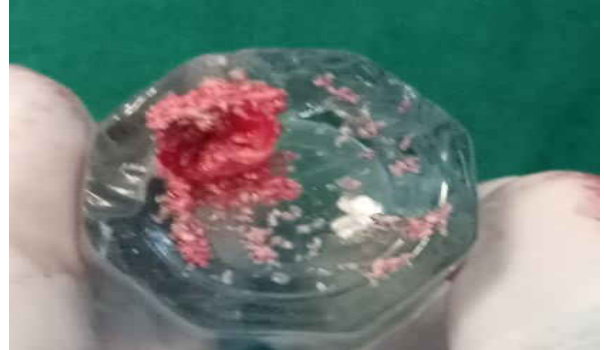

Occlusal view-37

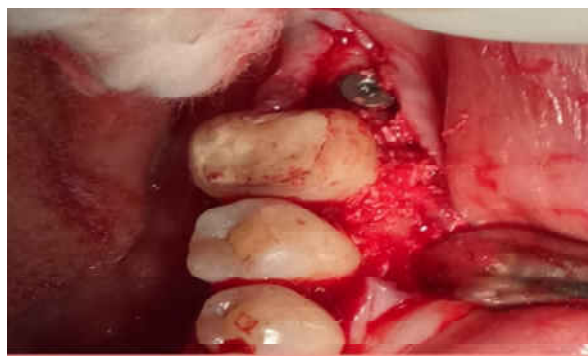
PRE OPERATIVE MEASUREMENTS



Implant site prepared-37

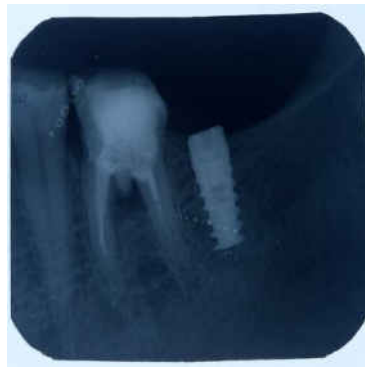

PRF+ graft mixture



Implant placed-37

POST- OPERATIVE PHOTO



Post-op IOPA

RIDGE SPLIT WITH IMPLANT PLACEMENT

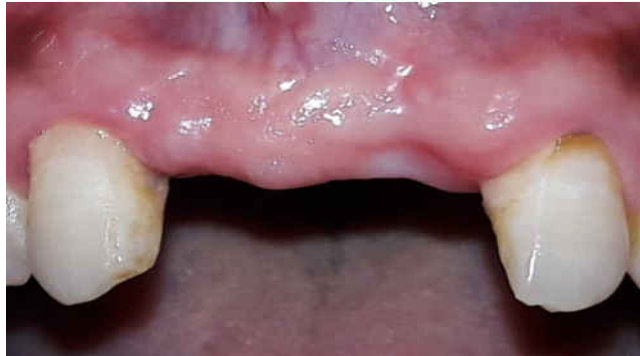DEMOGRAPHIC DATA

PATIENT NAME DATE:

OP NO: AGE/SEX:

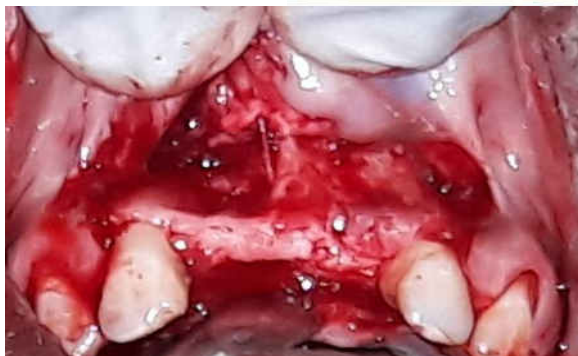PROCEDURE:

PRE OPERATIVE PHOTO

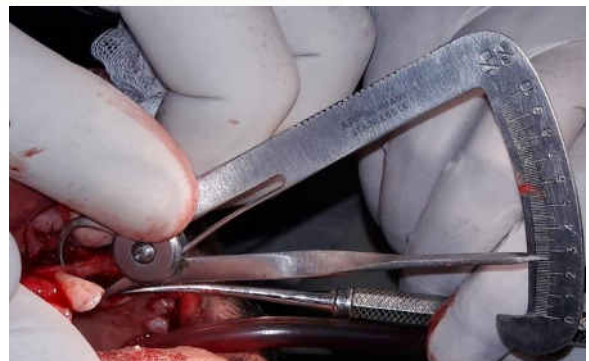


Frontal view

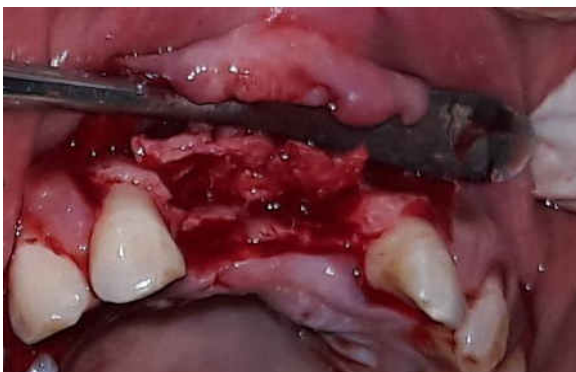OPERATIVE PHOTOS



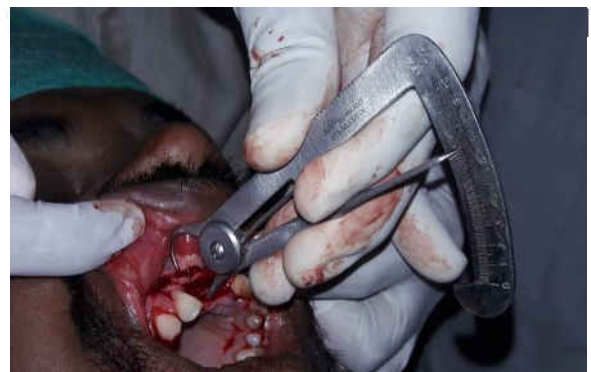Flap reflection done



Ridge width measured

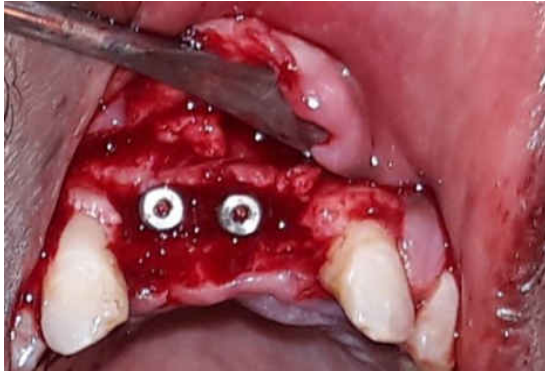


Ridge-split done

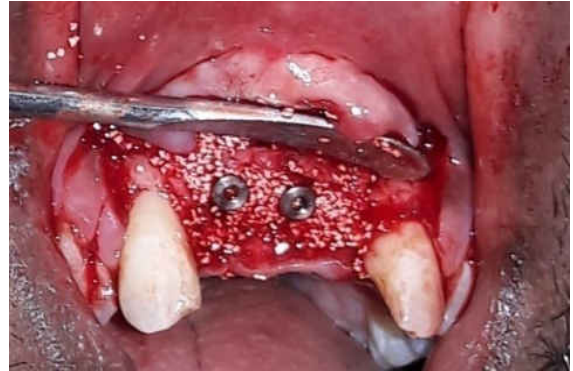


Ridge width post split

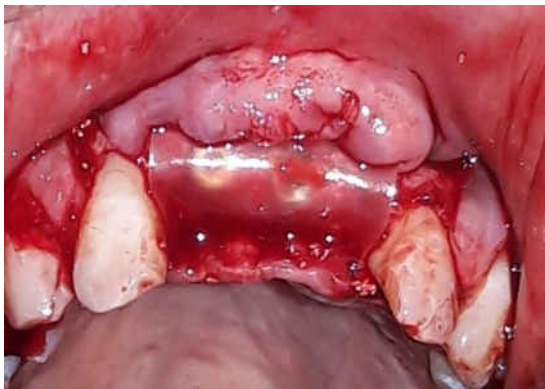
OPERATIVE PHOTO



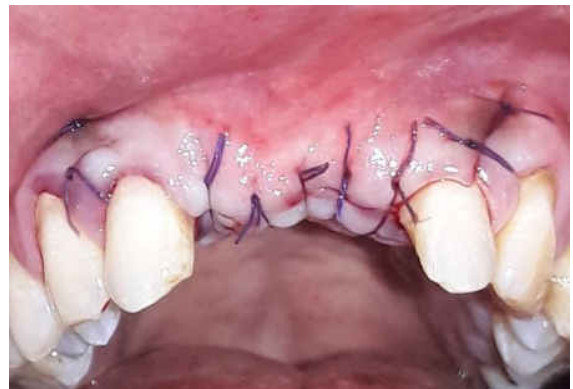Implants placed



Graft placed



Membrane Placed



Sutures given

PERI-IMPLANT MANAGEMENT

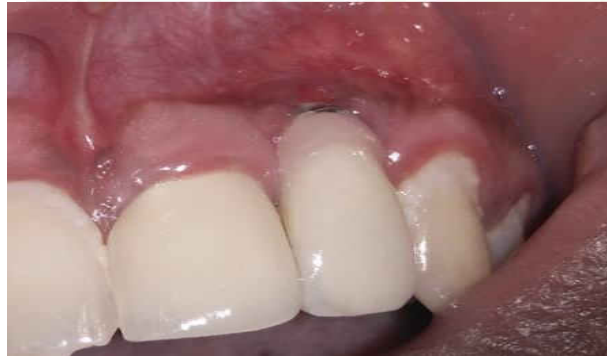DEMOGRAPHIC DATA

PATIENT NAME: Mr.Shiv Shankar

OP NO: 201803130128

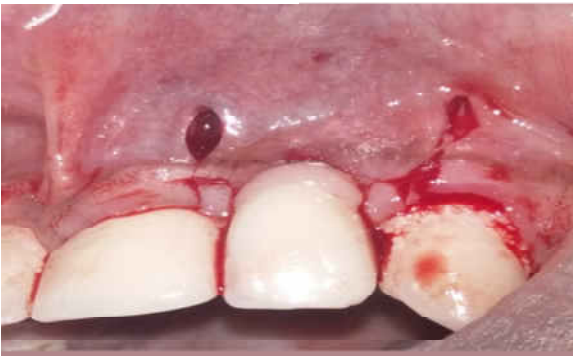
AGE/SEX:28years/Male

PRE OPERATIVE PHOTO

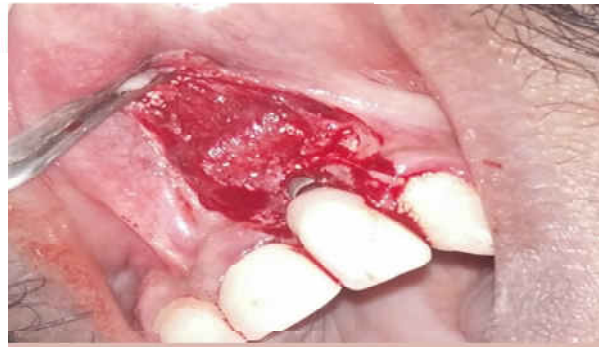

Left lateral view

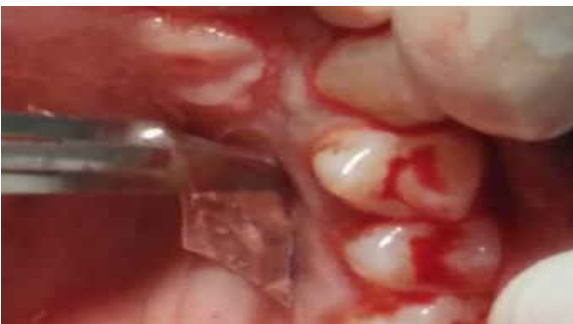OPERATIVE MEASUREMENTS



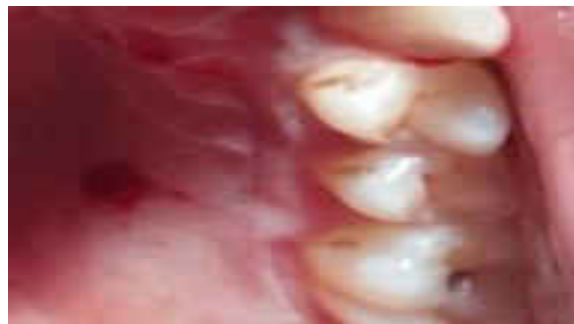Incision placed-21



Flap reflection done

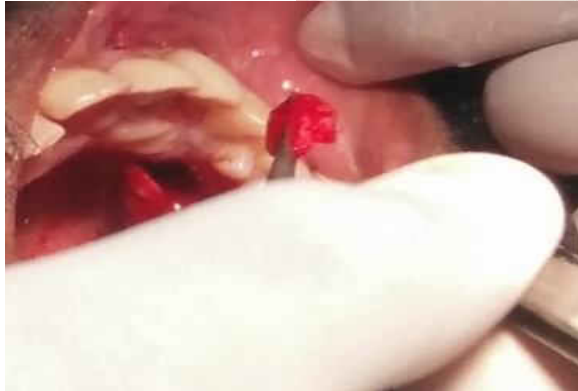

Aluminum foil stent placed

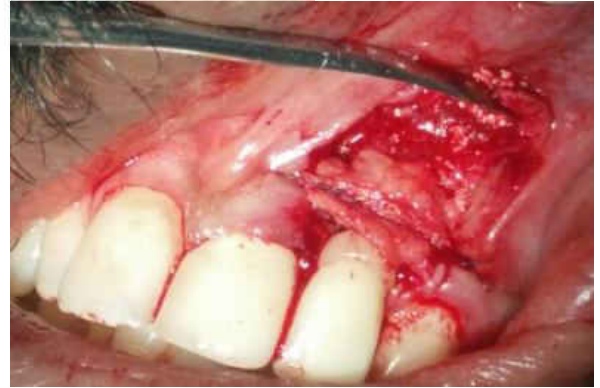

Incision outline placed

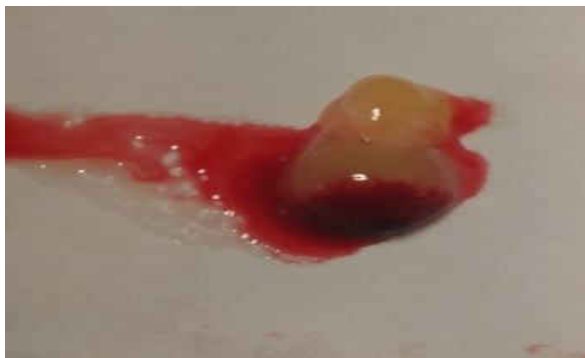OPERATIVE MEASUREMENTS



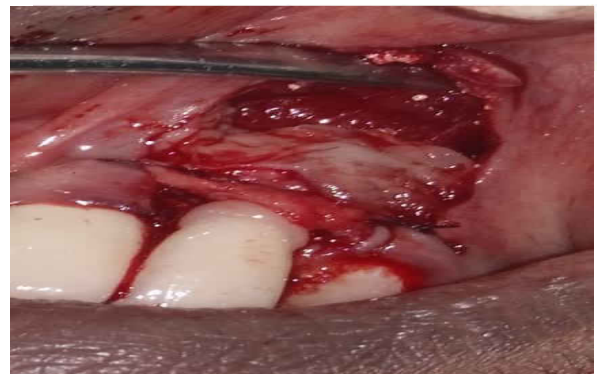CTG procured



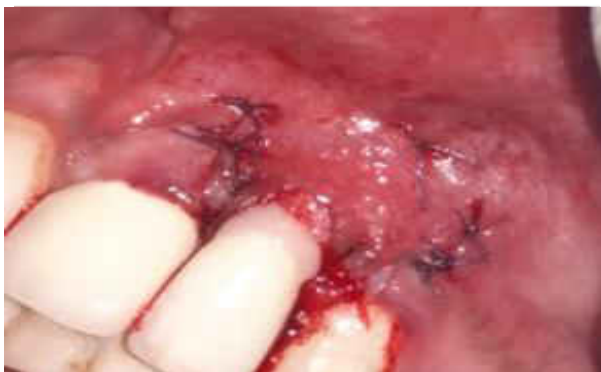CTG stabilized at receipient site



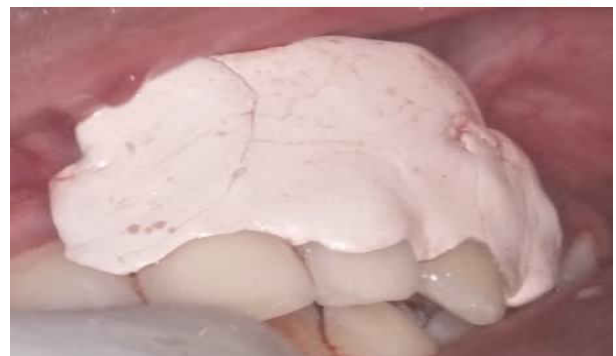PRF procured



PRF stabilized



Sutures placed



Coe-pack placed