



**Chettinad**  
Dental College & Research Institute

**Department of Conservative Dentistry and Endodontics**  
**E-Learning Classes**  
**CRI Students Involving Postgraduates**

S.No	Date	Faculty In-charge	Topic of discussion	No of students attended
1.	06/07/2020	Year end evaluation		
2.	07/07/2020	Year end evaluation		
3.	08/07/2020	Year end evaluation		
4	09/07/2020	Year end evaluation		
5	10/07/2020	Dr. Manjiri Honap	Class I composite restoration	23
6	11/07/2020	Webinar		

Department of Conservative Dentistry & Endodontics

Attendance Report

Date: 06.07.2020

Interns (2015-16 Batch)

Staff: Dr. Manu Unnikrishnan

Timings: 10.45 A.M to 2 P. M

Manu Unnikrishnan is inviting you to a scheduled Zoom meeting.

for Interns Practical - D Batch

Date: 06.07.2020

Time : 10.45 A.M to 2 P.M

Join Zoom Meeting

<https://us04web.zoom.us/j/74749749824?pwd=YzV3U3Y0RXJDdWZHMnE1b0VHRkVNQT09>


Meeting ID: 747 4974 9824

Password: 643789




Number of Participants: 12


4G 10:49 99.6%  
LTE 74%

Close Participants (7)








Raj Prithivika. R (me)









Manu Unnikrishnan (host)









Jeevan Joshua









Praveen R









Kavitha Mohan








Ramya Rajaram








Sriharika Raavi



Invite



12:07




VLTE




4G




46%




Close




Participants (7)




 Praveen R (me)   >




 Manu Unnikrishnan (host)   >

 Raj Prithivika. R   >

 Jeevan Joshua   >

 Kavitha Mohan   >

 Ramya Rajaram   >

 Sriharika Raavi   >

Invite




4G 4G 1:27 33.5 Kb/s (1) ...



Voice LTE1 4G 48


Close

Participants (7)



S


Rani Santhiya Suresh (me)

 >






Manu Unnikrishnan (host)

 >



R


Rebecca Joseph

 >



All things are possible if you believe


Rizvi Chouhan

 >



RM


Raveena Manogaran

 >





Revanth Kumar




 >

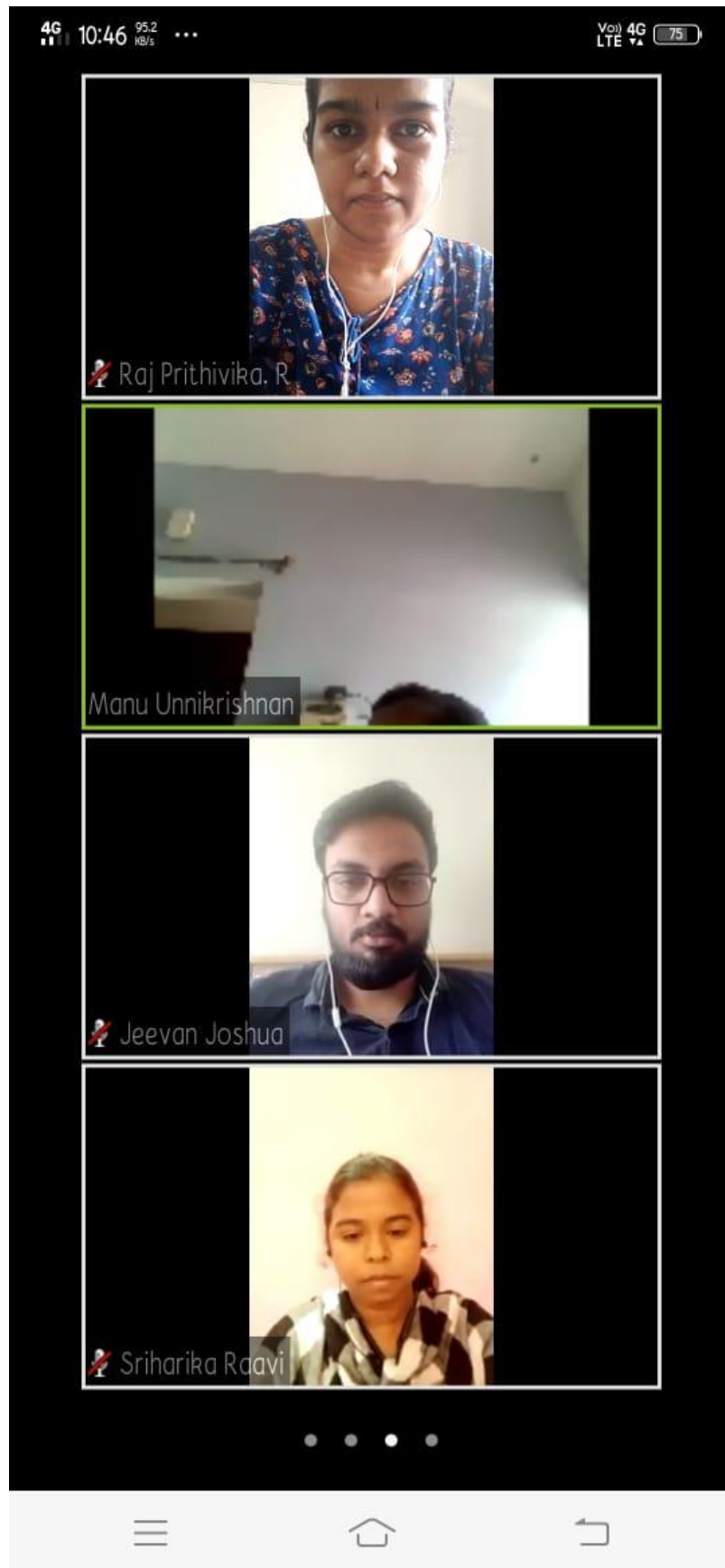


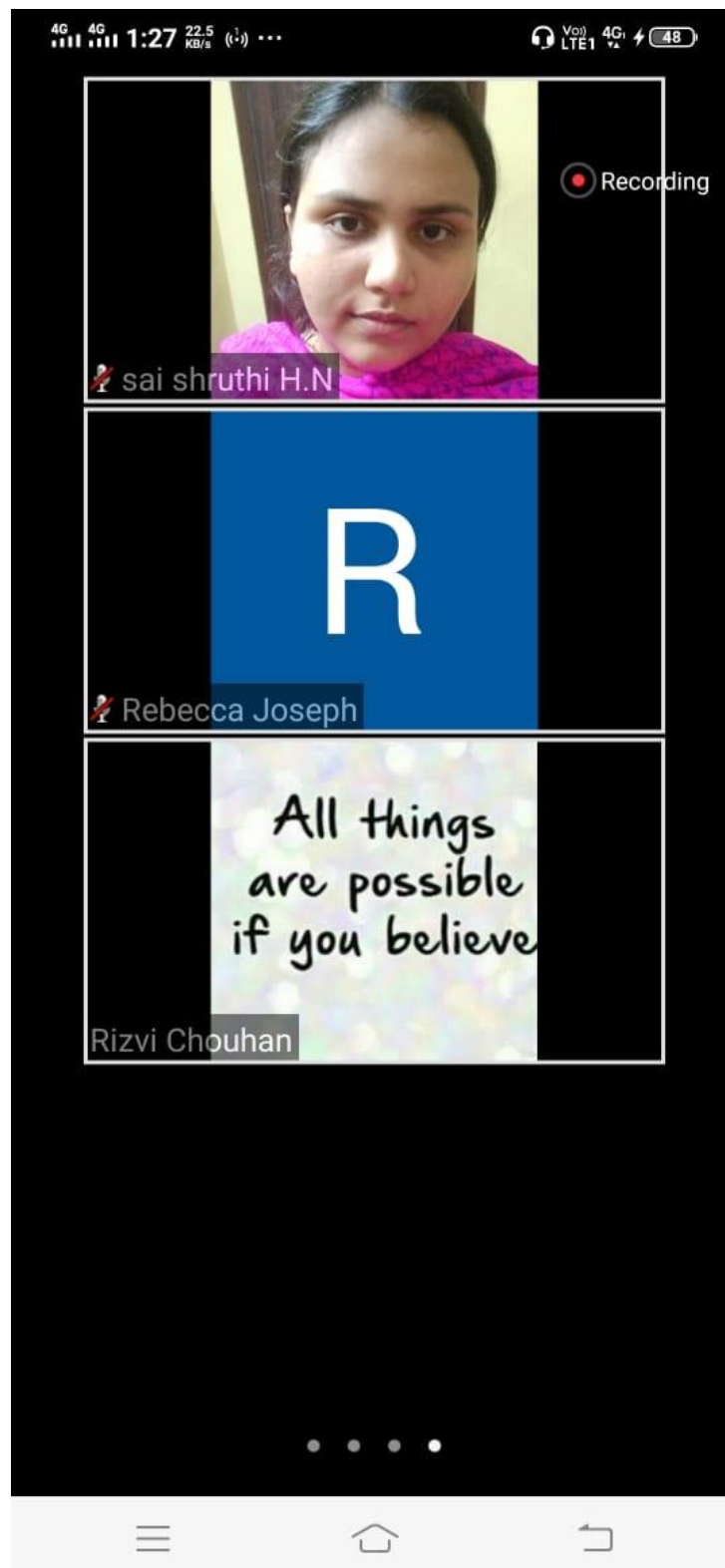sai shruthi H.N

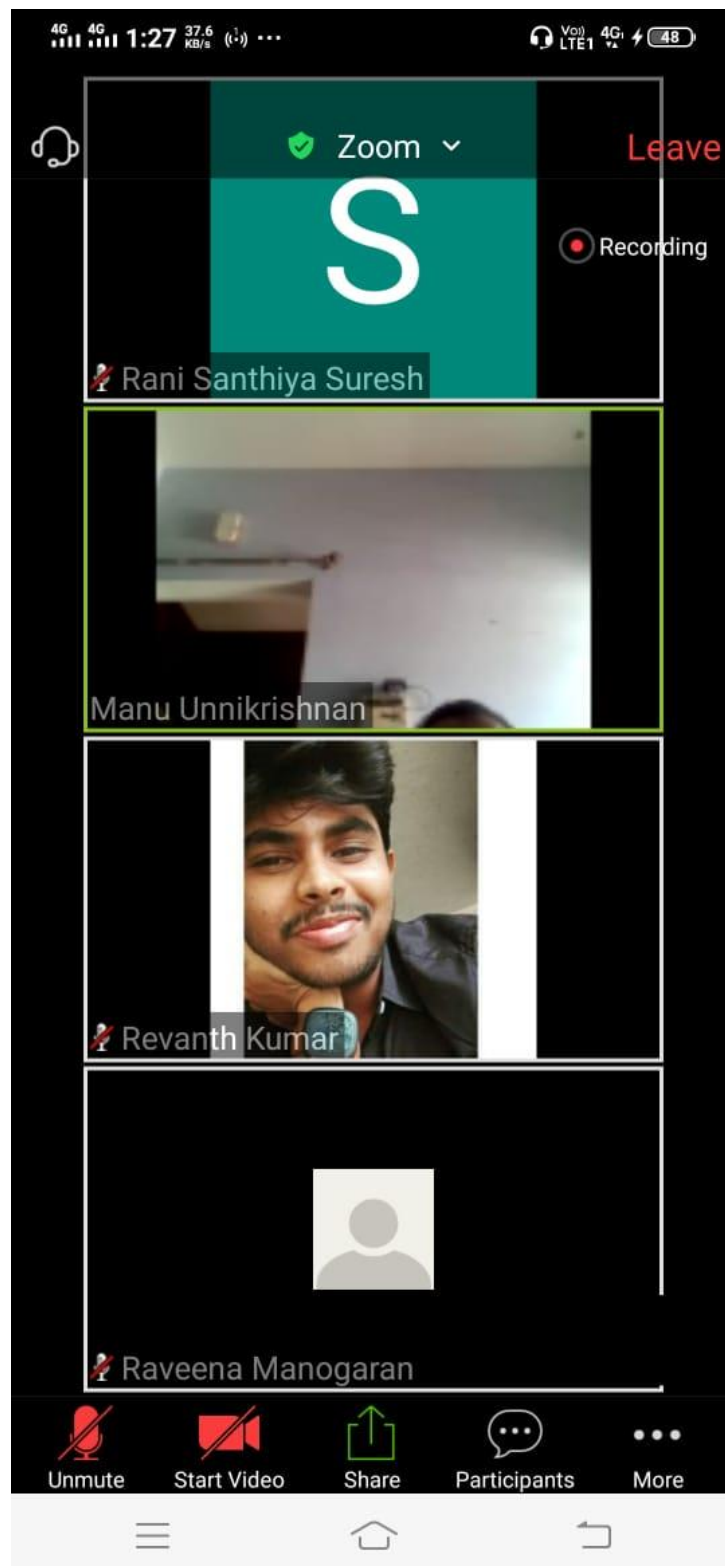
 >

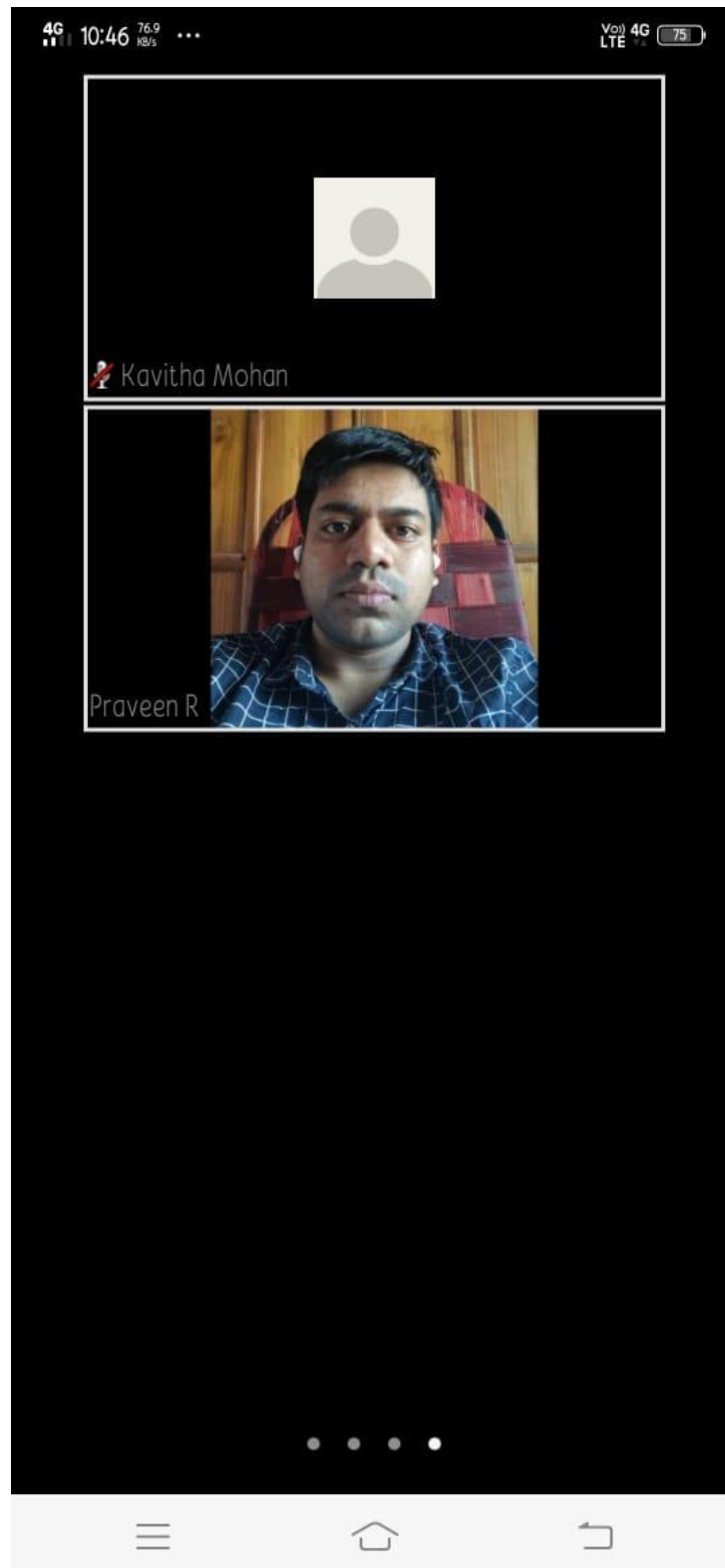
Invite













Department of Conservative Dentistry & Endodontics

Attendance Report

Date: 06.07.2020

Interns Evaluation

Staff: Dr Anupama.

Timings: to 11.15 AM -2.30 PM

Anupama R is inviting you to a scheduled Zoom meeting.

Topic: Intern evaluation

Time: Jul 6, 2020 11:15 AM Mumbai, Kolkata,  
New Delhi

Join Zoom Meeting

<https://us04web.zoom.us/j/6107038974?pwd=TUZRR2xRQWdiOTlCc3NnNFRCbEovQT09>

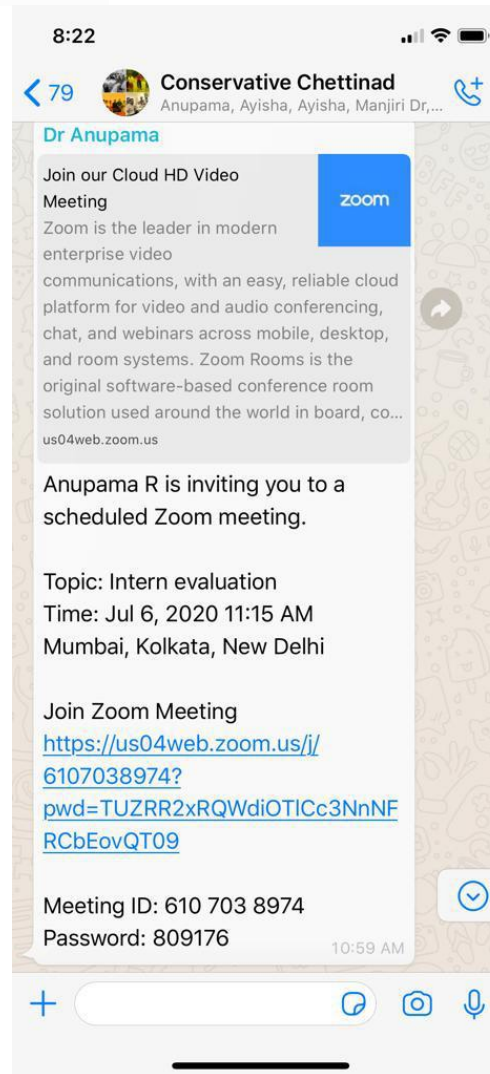
Meeting ID: 610 703 8974

Password: 809176

No of students participated: 12



**Chettinad**  
Dental College & Research Institute







**Chettinad**  
Dental College & Research Institute

11:20

102 KB/S 5G VPLTE 4G



Close


Participants (13)

Search



L


Lavanya (me)







Anupama R (host)







Dakshin D





MV


Madhu Vathani R





U


Mahalakshmi








Nandhini R








Naresh Boobalan







NIVASHINI C







POOJA LAKSHMANAN





PS

Poornima Srinivasan





PU

prathusha umakhanth



SP

sruthi p



Invite

11:20



115 KB/S 5G VPLTE 4G


Close

Participants (13)



L


Lavanya (me)







Anupama R (host)







Dakshin D





MV


Madhu Vathani R





U


Mahalakshmi








Nandhini R








Naresh Boobalan







NIVASHINI C







POOJA LAKSHMANAN





PS

Poornima Srinivasan





PU


prathusha umakhanth





SP

sruthi p





Vi Mukilan



Invite



A screenshot of a WhatsApp group chat titled "Kannur". The chat shows a vertical list of participants. Each participant's name is preceded by a small red icon of a person with a speech bubble. The participants are: Anupama R (wearing a green face mask), prathusha u..., sruthi p, Mahalakshmi, Madhu Vatha..., and Nandhini R. The chat interface includes a status bar at the top showing the time as 12:00 and a battery level of 100%. The chat title "Kannur" is at the top, and the participants list is below it.


Recording Remaining Meeting Time: 07:04

OSCE amalgam.docx

Font: Cambria (Body) 14 Paragraph Styles: Normal, No Spacing, Heading 1, Heading 2, Title, Subtitle, Subtle Emph., Emphasis, Intense Emph.

Insert: Text Box, Shape, Picture, Themes

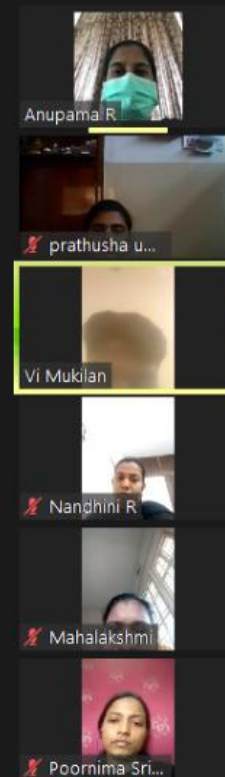CASE SCENARIO - 2



QUESTIONS-

1. What is the carving defect in the above restoration?
2. What are the consequences of this error in the long term?

Print Layout View Sec 1 Pages: 2 of 3 Words: 84 of 142 150%





Recording Remaining Meeting Time: 09:30

OSCE amalgam.docx


Font: Cambria (Body) 14 Paragraph Styles: Normal, No Spacing, Heading 1, Heading 2, Title, Subtitle, Subtle Emph., Emphasis, Intense Emph. Insert: Text Box, Shape, Picture, Themes

**OBJECTIVE STRUCTURED CLINICAL EXAMINATION**

**TOPIC - AMALGAM CARVING & POLISHING**

**CASE SCENARIO - 1**

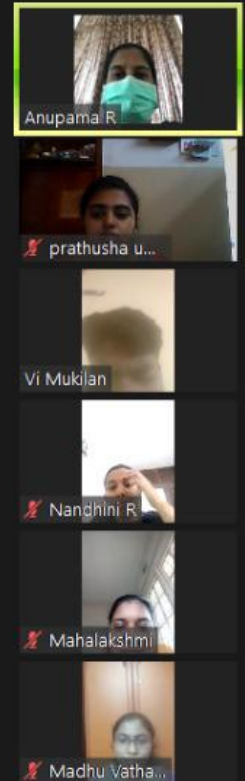
A patient with a class I amalgam restoration done 5 months back has reported with food impaction between the premolar & molar



A

B

Print Layout View Sec 1 Pages: 1 of 3 Words: 0 of 142 150%





Recording

OSCE class v.docx

Home Layout Document Elements Tables Charts SmartArt Review

Font Paragraph Styles


Cambria (Body) 14

Strong Quote Intense Quote Subtle Reference Intense Reference Book Title List Paragraph

Text Box Shape Picture Themes

Q Search in Document

CASE SCENARIO - 3



A

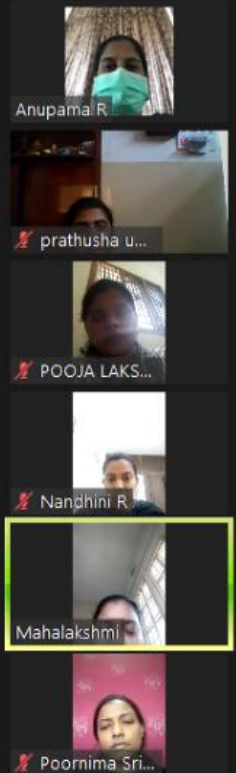B

C

QUESTIONS-

1. What is the treatment plan for A, B & C?
2. How will you isolate while restoring lesion B?
3. What are the steps in restoration for B?

Print Layout View Sec 1 Pages: 3 of 3 Words: 116 of 116 150%







Recording

You are viewing Anupama R's screen  
Remaining Meeting Time: 00:01

View Options

Speaker View

Exit Full Screen

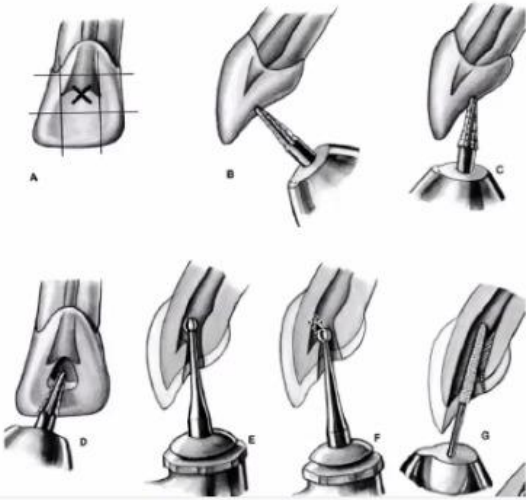
osce access.docx

Search in Document

Font: Cambria (Body) 12, Paragraph, Styles: Normal, No Spacing, Heading 1, Heading 2, Title, Subtitle, Subtle Emph., Emphasis, Intense Emph., Insert: Text Box, Shape, Picture, Themes

QUESTION - 3

Give appropriate captions for the picture describing the steps in access opening procedure.



Print Layout View | Sec 1 | Pages: 3 of 4 | Words: 106 of 122 | 150%

Unmute

Stop Video

Participants 13

Chat

Share Screen

Record

Reactions

Leave

Anupama R

prathusha u...

Lavanya

Nareesh Boob...

sruthi p

Vi Mukilan



Recording

You are viewing Anupama R's screen

View Options

Speaker View

Exit Full Screen

osce access.docx

Search in Document

Home Layout Document Elements Tables Charts SmartArt Review

Font Paragraph Styles


Insert Themes

OBJECTIVE STRUCTURED CLINICAL EXAMINATION

TOPIC - ACCESS OPENING

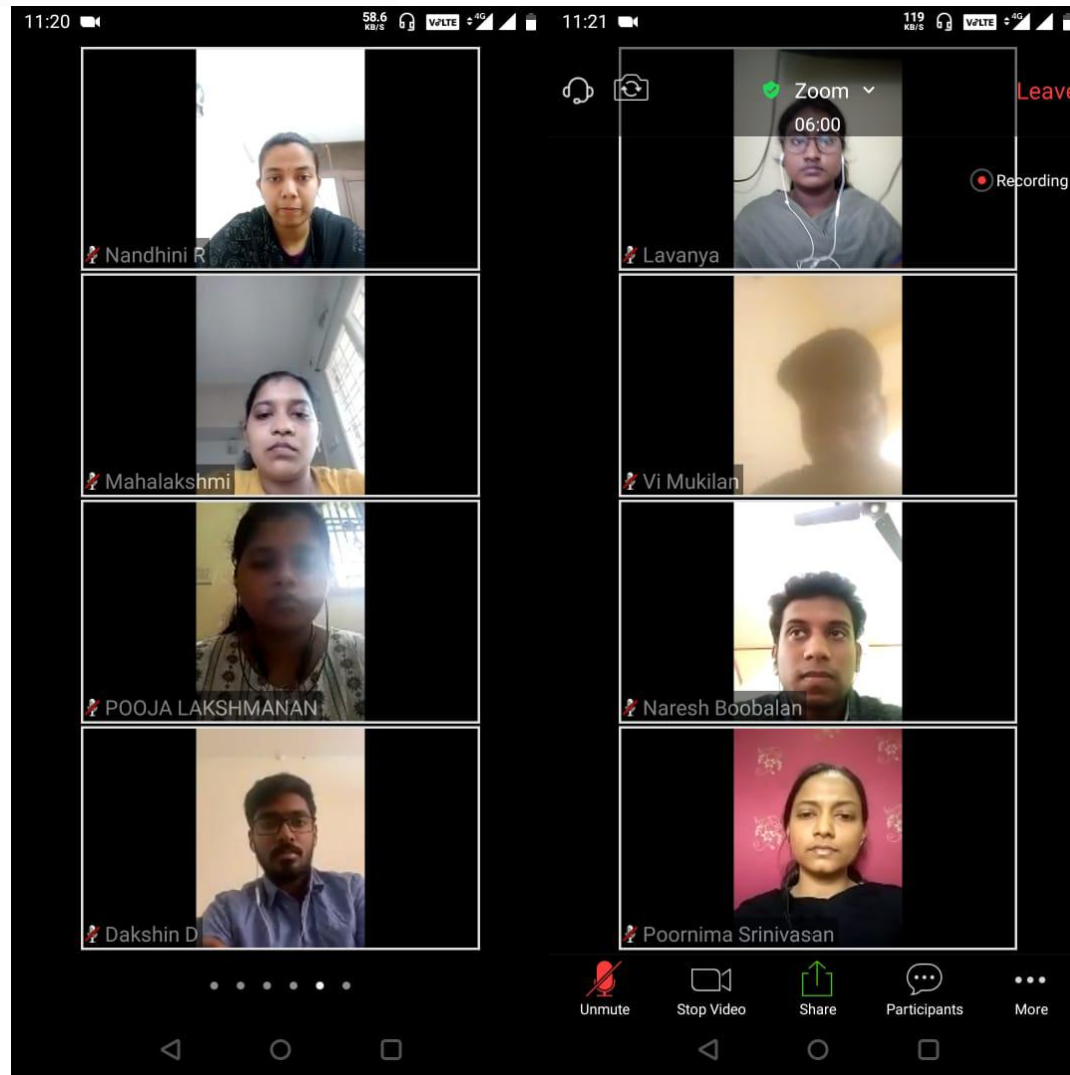
CASE SCENARIO - 1

A patient reports to the clinic with trauma of the upper central incisor. O/E, a fracture of the middle one third of the dental crown, with significant pulp involvement is seen, necessitating RCT. How will you proceed with access opening in this case?

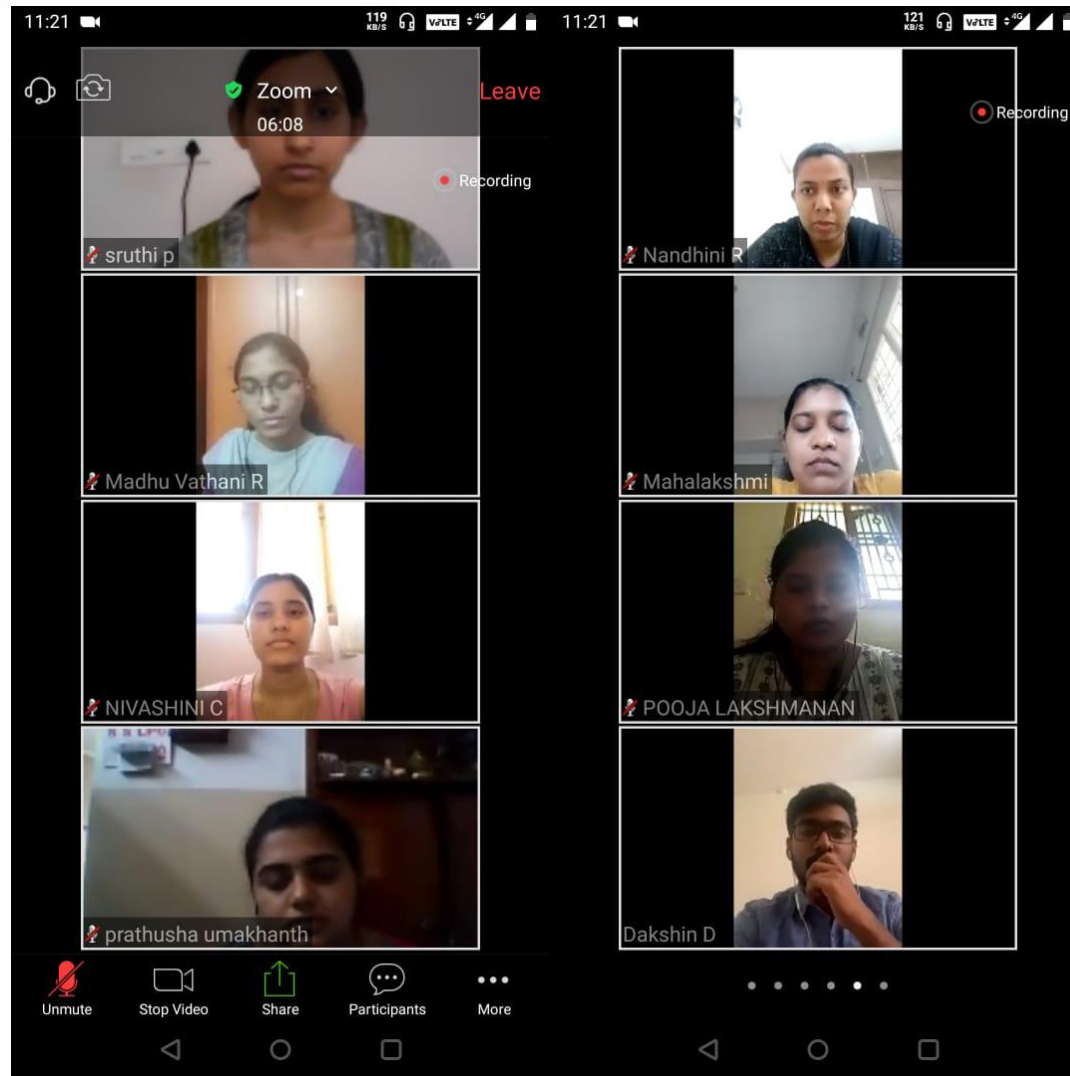


Print Layout View Sec 1 Pages: 1 of 4 Words: 0 of 122 150%

Unmute Stop Video Participants 13 Chat Share Screen Record Reactions Leave









Recording

Word File Edit View Insert Format Font Tools Table Window Help

osce - posterior composite 2.docx

150%

Home Layout Document Elements Tables Charts SmartArt Review

Font Paragraph Styles

Cambria (Body) 12


Normal No Spacing Heading 1 Heading 2 Title Subtitle Subtitle Emph... Emphasis Intense Emph...

Text Box Shape Picture Themes

2. Give caption for pictures U-V.  
3. List the advantages of this technique.

**CASE SCENARIO - 3**

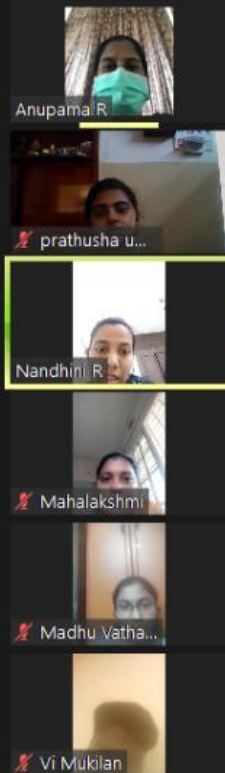
A 30 yr old patient reported to the clinic with c/o carious lower molar tooth. IOPA revealed no pulpal involvement. After tooth preparation, the following scenario emerged as seen in the picture.



**QUESTIONS-**

1. What is the restoration would you prefer in this case and why?
2. Advantages & disadvantages of your chosen restoration?

Print Layout View Sec 1 Pages: 3 of 3 Words: 173 of 173 150%



## Department of Conservative Dentistry & Endodontics

Attendance Report

Date: 07.07.2020

Interns Evaluation

Staff: Dr K Senthil Kumar.

Timings: to 11.00 AM -2.00 PM

Senthil Kumar is inviting you to  
a scheduled Zoom meeting.

Interns Evaluation

[https://us04web.zoom.us/j/3225943888?pwd=y\\_BFHILDzEywFcjDGTYEzw3yq\\_RA-qo](https://us04web.zoom.us/j/3225943888?pwd=y_BFHILDzEywFcjDGTYEzw3yq_RA-qo)

Meeting ID: 322 594 3888

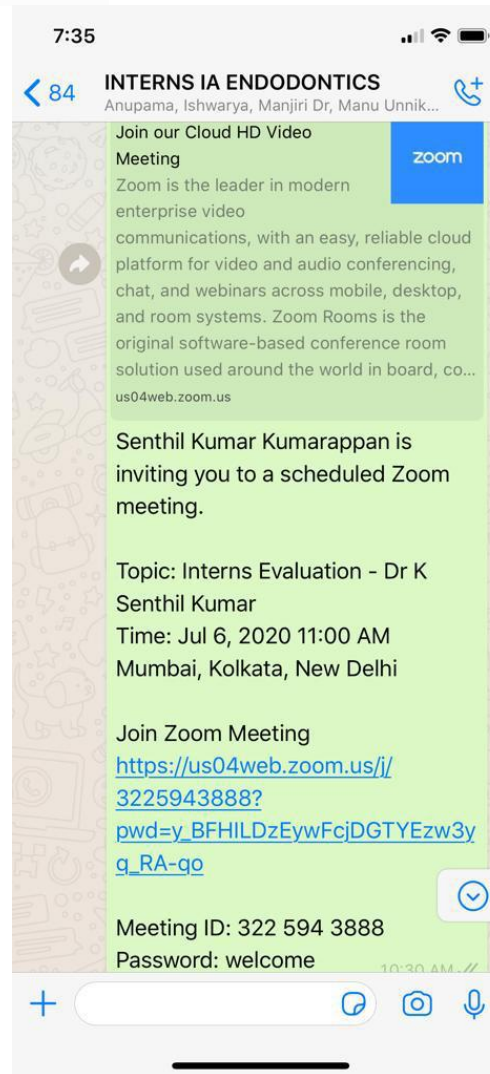
Password: welcome

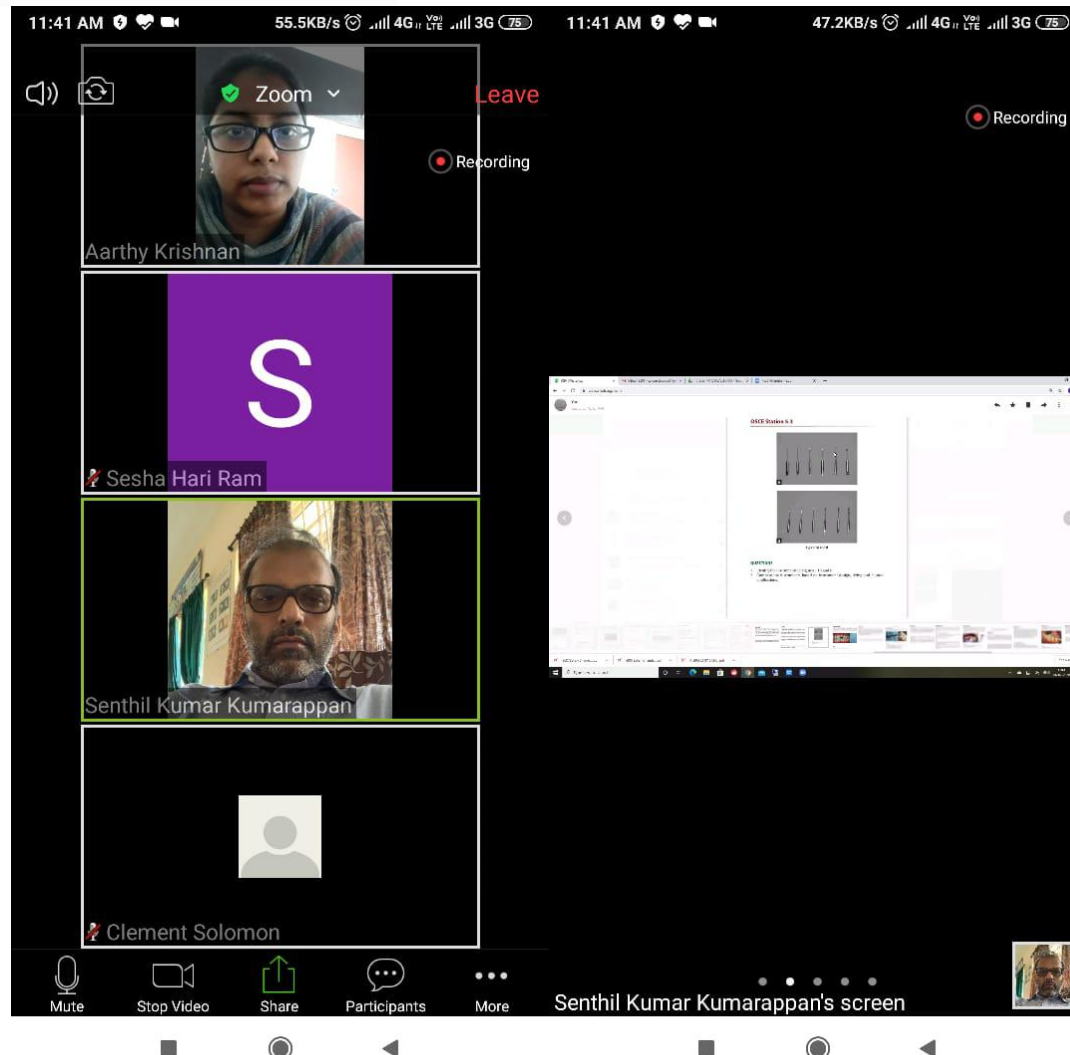
No of students participated: 11

No of Students Present - 11	No of Students Absent - 3
1. Sesha Hariram	Ashwathaman
2. Aarthy	Yuganthi
3. Akansha Tini	Pavithra
4. Akshaya M N	
5. Anurekha	
6. Aswini	
7. Bhavana	
8. Clement Solomon	
9. Deepika	
10. Gayathri	
11. Geerthana	



**Chettinad**  
Dental College & Research Institute







**Chettinad**  
Dental College & Research Institute

4G 4G LTE 9:59 0.00 MB/s 0-0 10:12 AM

https://docs.google.com/forr 29

# DEPARTMENT OF CONSERVATIVE DENTISTRY AND ENDODONTICS

Total points 24/50 ?

CRRI IA EXAMINATION - 6 JULY 2020

Full Name \*

Gayathri S 541516019

Batch \*

Aug batch

4G 4G LTE 9:59 0.00 MB/s 0-0 10:12 AM

# DEPARTMENT OF CONSERVATIVE DENTISTRY AND ENDODONTICS

Total points 29/50 ?

CRRI IA EXAMINATION - 6 JULY 2020

Full Name \*

Geerrthana J

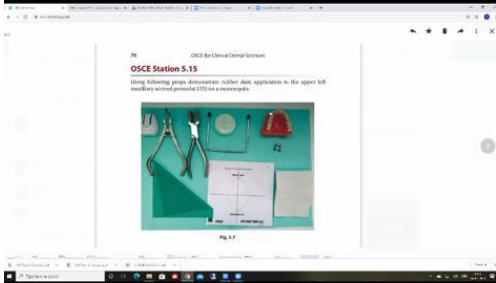
Batch \*

August 2015 -16

✓ 1 - Major pattern of accessory canals in mandibular molar is 1/1



REC REC



OSCE Station 5.15  
Using retracting force dissector to bring down application in the upper left mandibular second premolar (U2) on maxillary arch.

Fig. 5.17

Deepika L

Clement Solomon


Bhavana B

Senthil Kumar Kumarappan

Senthil Kumar Kumarappan's screen



REC



**OSCE Station 5.13**

A patient reports to your dental clinic with the chief complaint of notching of teeth near the gumline of left lower teeth. He also complains of sensitivity to cold drinks with those teeth.

Patient is using a hard brush and scrub technique for brushing his teeth.




Fig. 5.6

**QUESTIONS**

1. What is your clinical diagnosis?
2. Educate the patient regarding the problem and explain patient how are you going to treat.

10:11 docs.google.com

## DEPARTMENT OF CONSERVATIVE DENTISTRY AND ENDODONTICS

Total points 30/50 ?

CRRI IA EXAMINATION - 6 JULY 2020

Full Name \*

Akansha Tini P

Batch \*

2015-16 - A batch

✓ 1 - Major pattern of accessory canals in mandibular molar is 1/1


1:01 PM
45.7KB/s

1:03 PM
76.1KB/s

TICAL EXAM - Google
Launch Meeting - Zoom

## OSCE TEST

### Case 1




- 45 year old patient c/o food lodgement in Right lower tooth with no h/o pain and wants economical treatment option
- On clinical examination DB and DL cusp is extensively involved in caries
- Give the additional investigation required
- Treatment options
- Diagram of cavity prep and location of PINS for complex amalgam rest

Department of Conservative Dentistry & Endodontics

### Case 2

Tooth prep done for Complex amalgam restoration, enumerate the further steps for completing the restoration



Aswini S

Senthil Kumar Kumarappan

Mute
Stop Video
Share
Participants
More

11:37
195 KB/s
35%
Zoom
Leave
Recording

## DEPARTMENT OF CONSERVATIVE DENTISTRY AND ENDODONTICS

Total points **25/50** ?

CRR I A EXAMINATION - 6 JULY 2020

Full Name \*

T M Sessa Hari Ram

Batch \*

2015-2016

✓ 1 - Major pattern of accessory canals in mandibular molar is 1/1

☒ 1. A lateral canal extends from coronal 3rd to furcal region in distal canal. ✓

☐ 2. Presence of both lateral & furcal canal.

☐ 3. Single furcation canal extends from

**OSCE Station 5.2**

Francis is a 21-year-old male, reports to your dental clinic complaining of a single discolored upper front tooth. He gives history of fall from a bicycle which occurred 5 years ago. He noticed that after the fall, the tooth initially turned pink and later on started to discolor to greyish black. He never experienced pain. Francis wants esthetic treatment for the discolored tooth.

**QUESTIONS**

1. What is the cause of tooth discoloration following trauma in this case?
2. List three esthetic treatment options available for single tooth discoloration.

Mute
Stop Video
Share
Participants
More



**Chettinad**  
Dental College & Research Institute

OSCE Station 5.11

A female patient aged 13 years reports to your dental clinic with a complaint of recurrent pain, swelling and pus discharge from her upper teeth. She gave history of trauma about 6 years back and incomplete RCT. On clinical examination, teeth 11 and 21 were tender, with pus discharge from a sinus tract present in the vestibule in relation to tooth 21. Radiographic examination revealed open apices and periapical radiolucencies in relation with 11 and 21.

**QUESTIONS**

1. What is your clinical diagnosis?
2. Enumerate two causes of open apex.
3. List two difficulties encountered during RCT of open apex cases.
4. List two treatment modalities for endodontic treatment of this case.





**Chettinad**  
Dental College & Research Institute

## DEPARTMENT OF CONSERVATIVE DENTISTRY AND ENDODONTICS

Total points **30/50** ?

CRRRI IA EXAMINATION - 6 JULY 2020

Full Name \*

Clement Solomon

Batch \*

2015 -2016

12:44
Zoom
Leave
Recording

74 OSCE for Clinical Dental Sciences  
**OSCE Station 5.10**  
While performing RCT on a maxillary central incisor, you have accidentally injected sodium hypochlorite (NaOCl) beyond the apex. Patient immediately complained of excruciating pain inspite of the tooth being anesthetized already.  
**QUESTIONS**  
1. Enumerate two causes of NaOCl injection beyond apical foramen.  
2. List four symptoms usually accompanying after such accident.  
3. Briefly outline the steps for immediate management in this case.

Unmute Start Video Share Participants More

12:44
Zoom
Leave
Recording

Bhavana B  
Akshaya Narayanan  
Anurekha Azhaguvel  
Deepika L

Unmute Start Video Share Participants More



**Chettinad**  
Dental College & Research Institute

10:15

docs.google.com/forms/d/

6

DEPARTMENT OF  
CONSERVATIVE  
DENTISTRY AND  
ENDODONTICS

Total points **32/50** ?

CRR I A EXAMINATION - 6 JULY 2020

Full Name \*

B. Bhavana

Batch \*

2015 - 2016 A batch

✓ 1 - Major pattern of accessory canals in mandibular molar is

1 - A lateral canal extends from

Recording

OSCE Station 5.9

Patika, a 30-year-old female patient, reports to your dental clinic, complaining of pain with lower left back tooth since six months. Patient gives history of pain on chewing and swelling around buccal incisors and back.

On clinical examination, you find fracture of nearly 1/2 originating from occlusal surface extending to the cervical third of the crown on both mesial and distal aspects.

The tooth is vital and radiographic evaluation is unremarkable.



Fig. 5.9a and b

QUESTIONS

1. What type of longitudinal tooth fracture is noticed in the above case?
2. List 3 causes of fracture in the above case.
3. Outline the management for this case.

12:36 PM

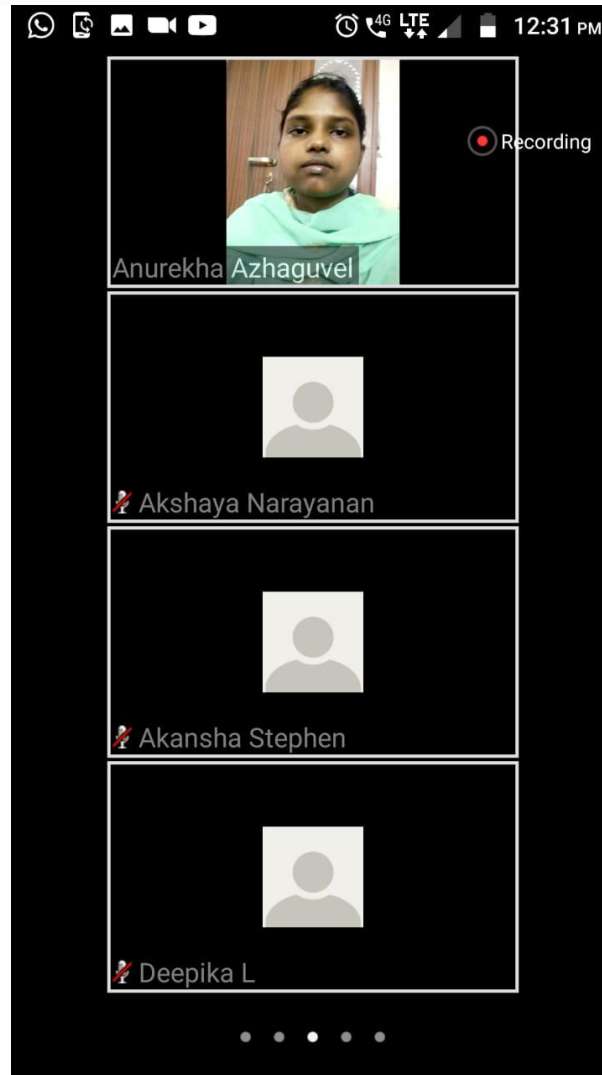
4G LTE

84





**Chettinad**  
Dental College & Research Institute





Department of Conservative Dentistry & Endodontics  
Practical Internal Assessment Exam

Date: 06.07.2020

CRRI

Staff: Dr. Manjiri Honap

Timings: to 11:00 am- 2.15 pm

Manjiri Honap is inviting you  
to a scheduled Zoom meeting.

CRRI IA Exam

Time: July 06, 2020, 11:00

AM India

[https://us04web.zoom.us/j/  
72802583308?pwd=cmt2  
U3Nsa0pIUep6d3pUMmF  
teFVMdz09](https://us04web.zoom.us/j/72802583308?pwd=cmt2U3Nsa0pIUep6d3pUMmFteFVMdz09)

Meeting ID: 72802583308

Password: CDCRI

No of students participated: 12



zoom

## Join our Cloud HD Video Meeting

Zoom is the leader in modern  
enterprise video communications, ...  
us04web.zoom.us

Manjiri Honap is inviting you to a scheduled  
Zoom meeting.

Topic: CRR I A EXAM

Time: Jul 6, 2020 11:00 AM India

Join Zoom Meeting

<https://us04web.zoom.us>

[/j/72802583308?pwd=](https://us04web.zoom.us/j/72802583308?pwd=cmt2U3Nsa0pIUep6d3pUMmFteFVMdz09)

[cmt2U3Nsa0pIUep6d3pUMmFteFVMdz09](https://us04web.zoom.us/j/72802583308?pwd=cmt2U3Nsa0pIUep6d3pUMmFteFVMdz09)

Meeting ID: **728 0258 3308**

Password: CDCRI

1:51 pm



12:38 4G

80

Close

Participants (7)

VA

Vinitha Ashokkumar (me)

>

M

Manjiri Honap (host)

>

VR

Vignesh Ravi

>

P vishanth

>

Valar Mathi

>

y

Yamini N

>

Yuva Ranjani

>

Invite

12:38 4G

80

Close

Participants (7)

VA

Vinitha Ashokkumar (me)

>

M

Manjiri Honap (host)

>

VR

Vignesh Ravi

>

P vishanth

>

Valar Mathi

>

y

Yamini N

>

Yuva Ranjani

>

Invite

Close

## Participants (7)



Subhashini Raju (me)



Manjiri Honap (host)



Monisha Durairaj



Sruthi S



Steffy Selastin



Sumithra ..



Qurathul Ayn Fathima

[Invite](#)



Airplane mode

73% 11:24 AM



Zoom

Leave

Recording

Monisha Durairaj

Sumithra ..

Steffy Selastin

Unmute

Stop Video

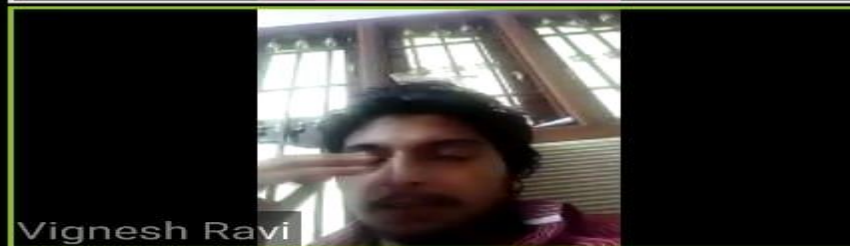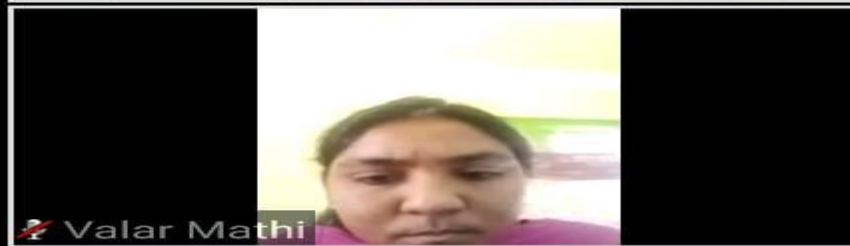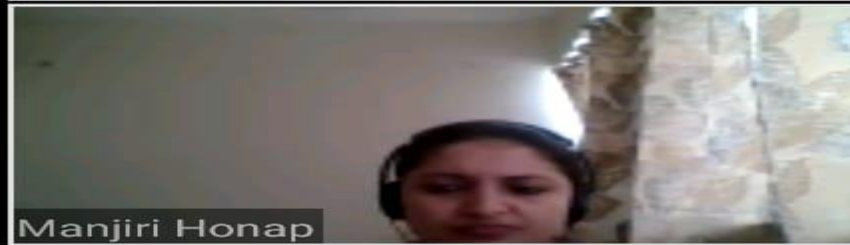
Share

Participants

More

12:39 4G

80





Airplane mode

73% 11:24 AM



Zoom

Leave

Recording

Subhashini Raju

Manjiri Honap

Qurathul Ayn Fathima

Sruthi S

Unmute


Stop Video


Share


Participants

More


13:44 4G

 58














 Zoom

Leave

 Recording


OSCE.pdf Adobe Acrobat Reader DC

Tools Ethetic OSCE.pdf OSCE DIAGNOSIS... OSCE RUBRIC DA...

CASE SCENARIO -2


A 39 yr old patient reports to the clinic with complaint of discoloured upper front teeth and seeks a solution from you





Questions-


1. What are the investigations to be done?


type here to search





 Unmute

 Start Video

 Share

 Participants

 More



13:35 4G

61

Recording

pdf - Adobe Acrobat Reader DC


Esthetic OSCE.pdf

OSCE DIAGNOSIS...

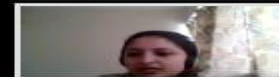
OSCE RUBBER DA...

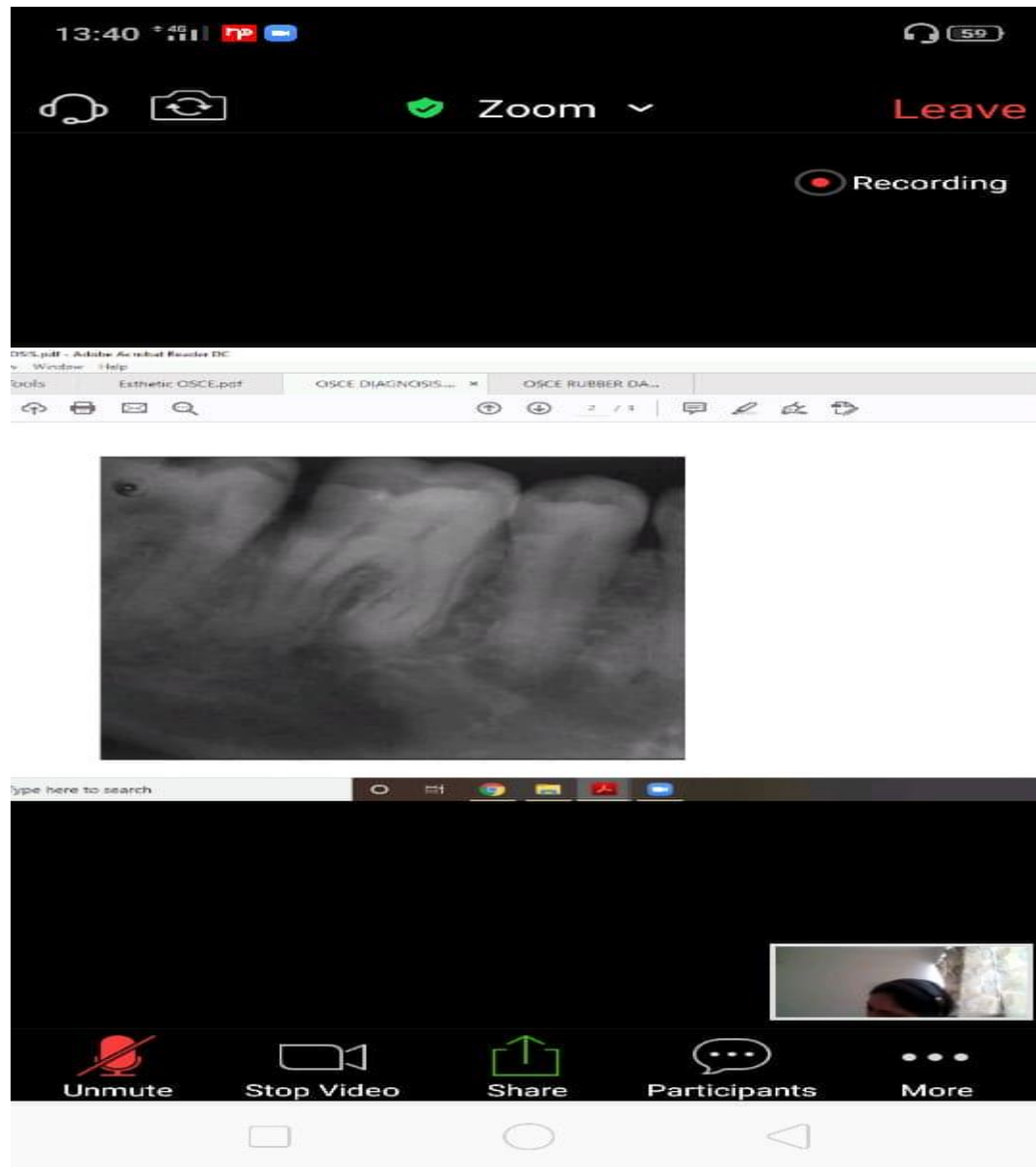
2 / 3

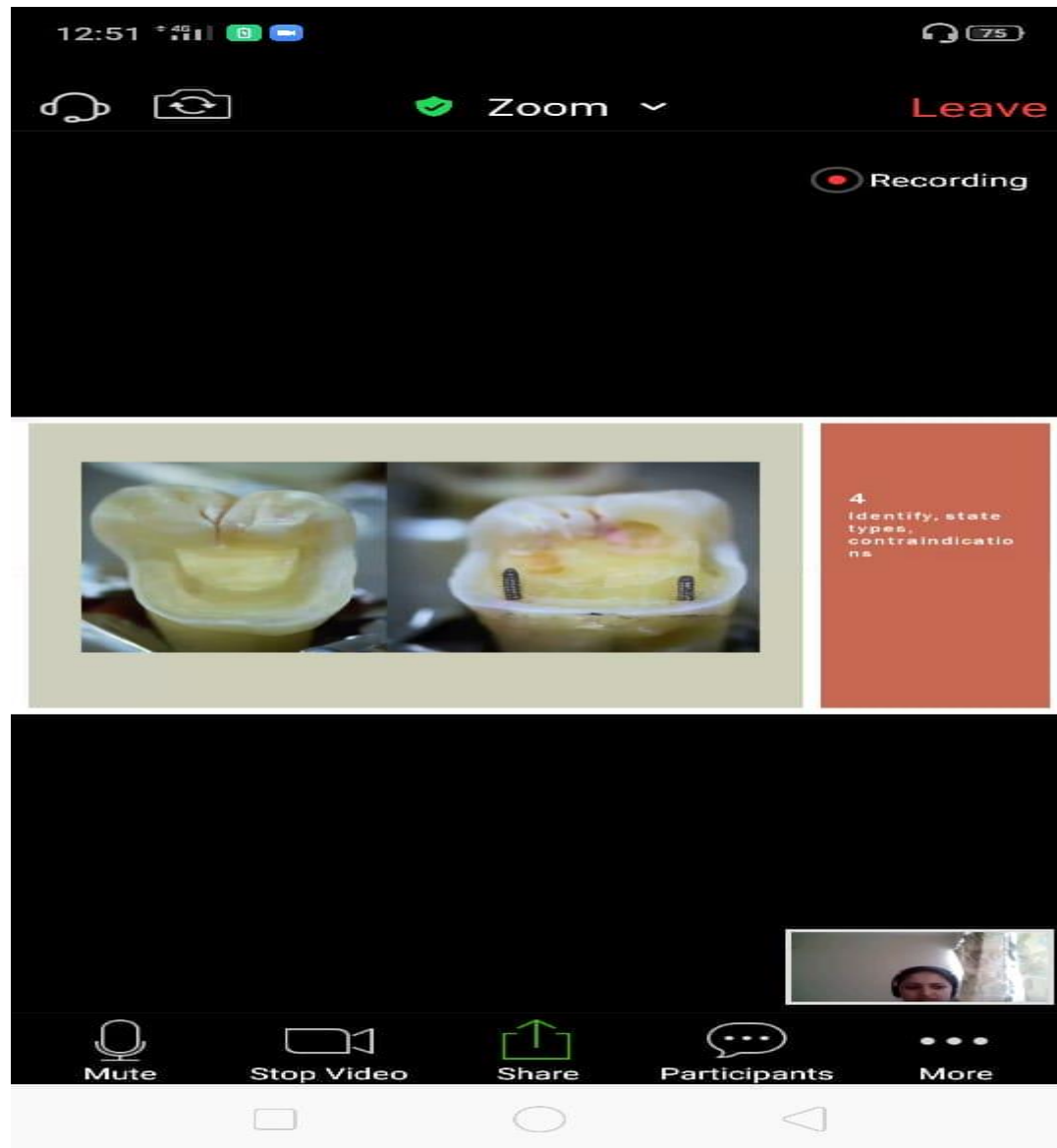
WHAT IS DEPICTED IN PICTURE? WHAT IS THE USE? STATE A SPECIFIC TREATMENT WHERE ITS MANDATORY.



srch





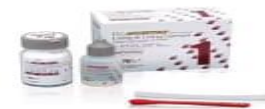



**Chettinad**  
Dental College & Research Institute

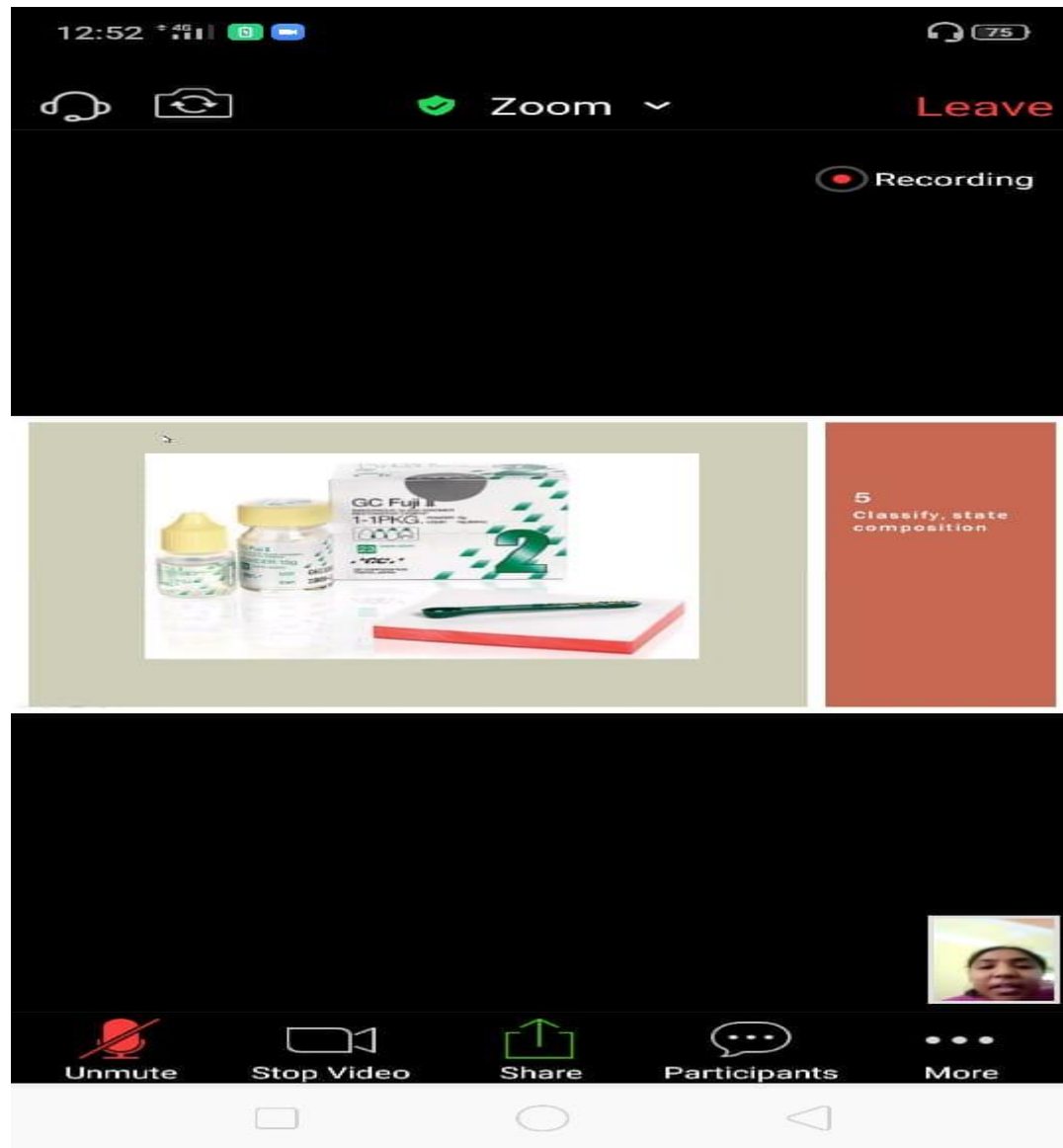
## OSPE

1. Identify the material
2. ADA Specification No
3. Composition of Powder
4. Composition of Liquid
5. Powder Liquid Ratio
6. Film Thickness
7. Uses
8. Name the spotter based on Each Classification

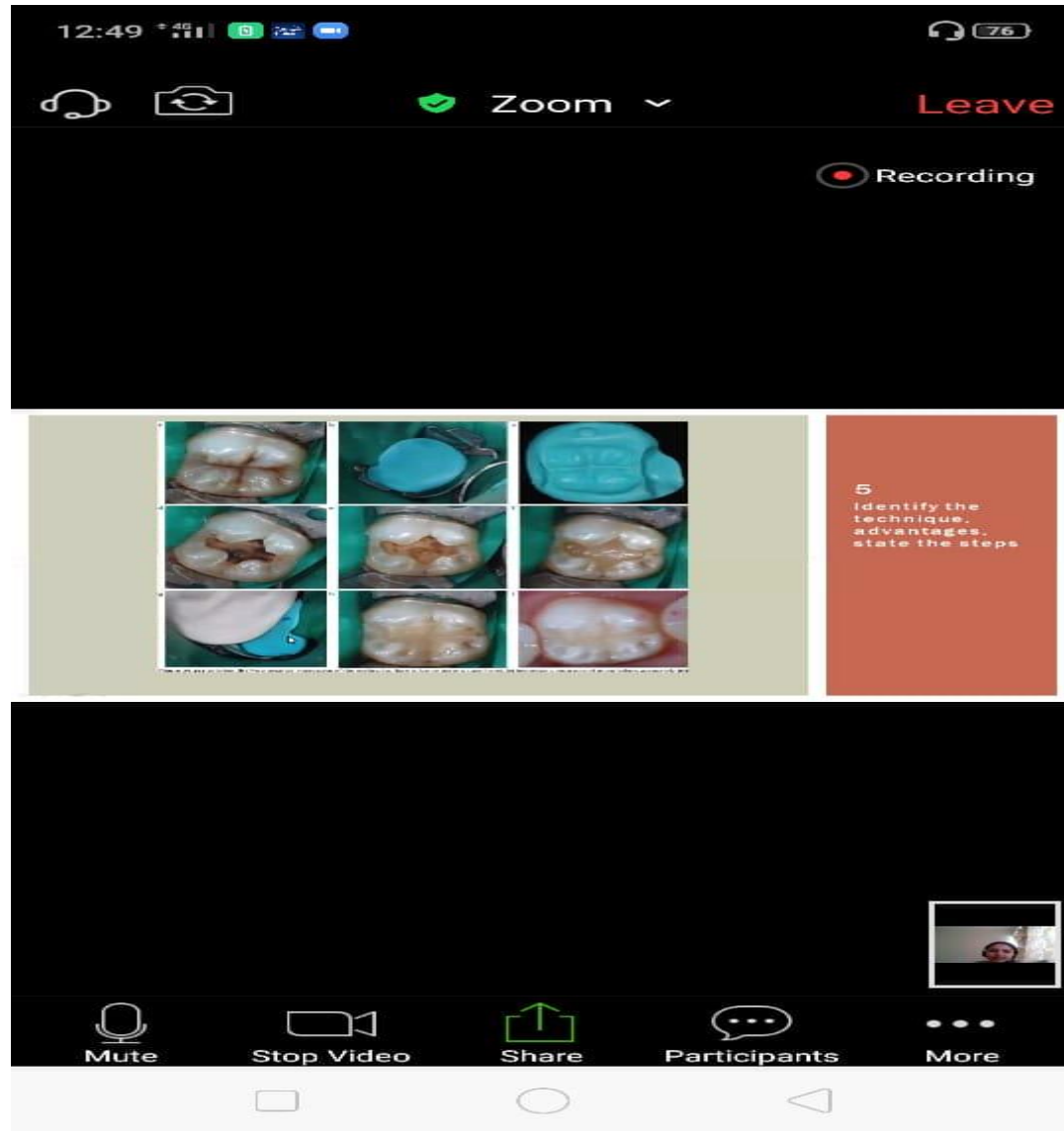


Department of Conservative Dentistry & Endodontics





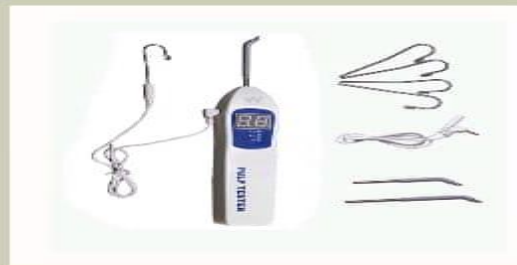



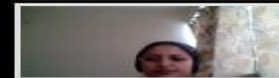
12:38 + 4G

80

Recording



3  
Identify the  
instrument,  
what it is used  
for





# DEPARTMENT OF CONSERVATIVE DENTISTRY AND ENDODONTICS

Total points **22/50** ?

CRRI IA EXAMINATION - 6 JULY 2020

Full Name \*

Valarmathi. M

Batch \*

August -K





https://docs.google.com

17



# DEPARTMENT OF CONSERVATIVE DENTISTRY AND ENDODONTICS

Total points **23/50** ?

CRRI IA EXAMINATION - 6 JULY 2020

Full Name \*

Steffy S

Batch \*

2015-16. D2 Batch



1 - Major pattern of  
accessory canals in

0/1



# DEPARTMENT OF CONSERVATIVE DENTISTRY AND ENDODONTICS

Total points **26/50** ?

CRRI IA EXAMINATION - 6 JULY 2020

Full Name \*

Sruthi S

Batch \*

Batch 2015-16 B batch

✗ 1 - Major pattern of accessory  
canals in mandibular molar is 0/1



1. A lateral canal extends from coronal



# DEPARTMENT OF CONSERVATIVE DENTISTRY AND ENDODONTICS

Total points **16/50** ?

CRRI IA EXAMINATION - 6 JULY 2020

Full Name \*

P.VISHANTH

Batch \*

2015 batch



1 - Major pattern of  
accessory canals in

0/1

AA

docs.google.com



# DEPARTMENT OF CONSERVATIVE DENTISTRY AND ENDODONTICS

Total points **41/50** ?

CRR I A EXAMINATION - 6 JULY 2020

Full Name \*

Qurathul Ayn Fathima

Batch \*

Feb batch



1 - Major pattern of accessory

1/1





# DEPARTMENT OF CONSERVATIVE DENTISTRY AND ENDODONTICS

Total points **38/50** ?

CRR I A EXAMINATION - 6 JULY 2020

Full Name \*

Vignesh R

Batch \*

2015-2016 August batch B batch



# DEPARTMENT OF CONSERVATIVE DENTISTRY AND ENDODONTICS

Total points **28/50** ?

CRR I A EXAMINATION - 6 JULY 2020

Full Name \*

monisha



Batch \*



# DEPARTMENT OF CONSERVATIVE DENTISTRY AND ENDODONTICS

Total points **24/50** ?

CRRI IA EXAMINATION - 6 JULY 2020

Full Name \*

M.Sumithra

Batch \*



Aug 2015-F batch



10:12 4G

91



DEPARTMENT OF CONSERVATIVE D...



# DEPARTMENT OF CONSERVATIVE DENTISTRY AND ENDODONTICS

Total points 21/50

CRRI IA EXAMINATION - 6 JULY 2020

Full Name \*

A.Vinitha

Batch \*

August 2015-16





# DEPARTMENT OF CONSERVATIVE DENTISTRY AND ENDODONTICS

Total points **26/50** ?




CRR I A EXAMINATION - 6 JULY 2020





Full Name \*

SUBHASHINI.R


Batch \*

Aug 2015-16 (F batch)


10:10  V-JLTE2  4G  86%

  docs.google.com/forms/d/e/1  3 


# DEPARTMENT OF CONSERVATIVE DENTISTRY AND ENDODONTICS

Total points **27/50** 


CRRI IA EXAMINATION - 6 JULY 2020

Full Name 


Yamini.N

Batch 

August 2015 F batch

 1 - Major pattern of accessory  
canals in mandibular molar is 0/1

☐ 1. A lateral canal extends from coronal 3rd  
to furcal region in distal canal.

☒ 2. Presence of both lateral & furcal  
canal. 

☐ 3. Single furcation canal extends from



# DEPARTMENT OF CONSERVATIVE DENTISTRY AND ENDODONTICS

Total points **30/50** ?

CRR I A EXAMINATION - 6 JULY 2020

Full Name \*

Yuvaranjani.P

Batch \*

2015- 16/




1 - Major pattern of accessory  
canals in mandibular molar is

1/1

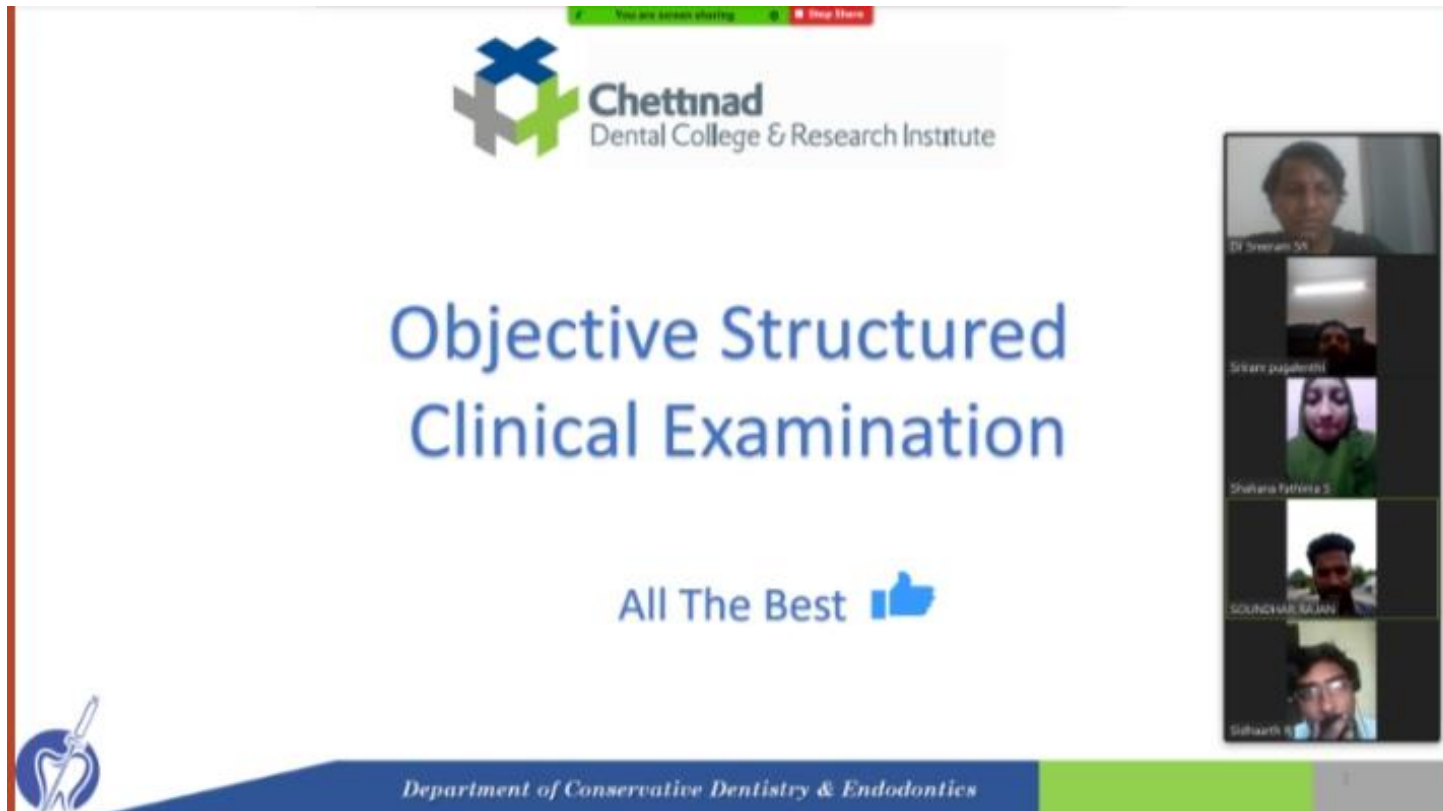





## E- Practical Knowledge Assessment and Evaluation for Interns

<b>Date</b>	<b>06/07/2020</b>
<b>Subject</b>	<b>Preclinical Conservative</b>
<b>Department</b>	<b>Department of Conservative Dentistry and Endodontics</b>
<b>Time</b>	<b><u>11:30 am</u></b>
<b>Name of the Faculty</b>	<b>Dr.Sreeram S R</b>
<b>Topic of the webinar</b>	<b>Objective Structured Clinical Examination</b>
<b>No of students attended</b>	<b>12</b>
<b>E-Resource Platform</b>	
<b>Meeting ID</b>	<b>730 1227 1091</b>
<b>Password</b>	<b>Chettinad</b>

## SCREEN IMAGES



The screenshot shows a Zoom meeting interface. At the top, a status bar indicates "You are screen sharing" with a green bar and a "Stop Screen" button. The main presentation slide features the Chettinad Dental College & Research Institute logo at the top left. The title "Objective Structured Clinical Examination" is displayed in large blue font. Below the title, the text "All The Best" is followed by a blue thumbs-up icon. In the bottom left corner of the slide, there is a small icon of a tooth with a dental instrument. The bottom of the slide has a blue footer bar with the text "Department of Conservative Dentistry & Endodontics". On the right side of the screen, a vertical stack of five video feeds shows participants: Dr. Srinivas SN, Srikanth puppalapati, Shiksha Pythina S, SOUNDEVAR, KUNJ, and Sathya R.

 You are screen sharing. Stop Share

A patient reports to your dental clinic with the chief complaint of notching of teeth near the gumline of left lower teeth. He also complains of sensitivity to cold drinks with those teeth.  
Patient is using a hard brush and scrub technique for brushing his teeth.






Fig. 3.6

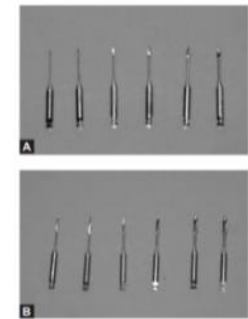
**QUESTIONS**

1. What is your clinical diagnosis?
2. Educate the patient regarding the problem and explain patient how are you going to treat.

 Department of Conservative Dentistry & Endodontics 2.2

Dr. Sreenivas SK  
Sourabh Rajan  
Shanthi Rajan  
Sivandhini  
Srinivas Rajan


 You are screen sharing. Stop Share



Figs 5.1A and B

**QUESTIONS**

1. Identify the instruments in Figures 5.1A and B.
2. Compare the instruments based on instrument design, sizing and clinical applications.

 Department of Conservative Dentistry & Endodontics 2.3

Dr. Sreenivas SK  
Shruthi Rajan S  
Sourabh Rajan  
Sivandhini  
Shanthi Rajan

 You are screen sharing. Stop Share

Suma is a 21-year-old female patient, who reports to your dental clinic complaining of a discolored tooth colored restoration of an upper front tooth. Clinical examination of I1 reveals deep carious lesion. RDP reveals that caries was involving the pulp. The proposed treatment plan was root canal treatment followed by post and core and crown. However as the tooth was grossly decayed, it was not possible to apply a rubber dam.



Figs 5.2A and B

**QUESTIONS**

1. What are the consequences of performing RCT without a rubber dam?
2. Suggest any three pre-endodontic treatment procedures that can be undertaken in this case to aid in application of rubber dam clamp to I1.

 Department of Conservative Dentistry & Endodontics 2.4

Dr. Sreenivas SK  
Shruthi Rajan S  
Sourabh Rajan  
Sivandhini  
Srinivas Rajan

 You are screen sharing. Stop Share

Maria is a 22-year-old patient, reports to your dental clinic with fractured left upper central incisor (21) involving pulp and insufficient coronal tooth structure. Treatment plan decided for the tooth is root canal treatment followed by post and core and crown restoration.




Figs 5.2A and B

**QUESTION**

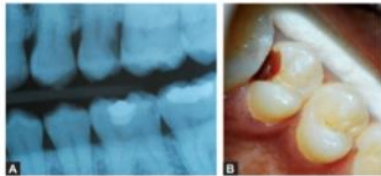
Explain to the patient about post and core procedure.

 Department of Conservative Dentistry & Endodontics 2.5

Dr. Sreenivas SK  
Shruthi Rajan S  
Sourabh Rajan  
Sivandhini  
Shanthi Rajan

 You are screen sharing. Stop Share


While excavation of deep proximal caries on 25 with a round diamond, you find a small bleeding point indicative of pulp exposure.




**Fig 5.3A and B**

**QUESTIONS**

1. Enumerate two vital pulp therapy procedures that can be done in this case instead of root canal treatment.
2. List three factors essential for successful vital pulp therapy.
3. List two contraindications for vital pulp therapy.
4. Name two materials commonly used for vital pulp therapy.


 Department of Conservative Dentistry & Endodontics


 You are screen sharing. Stop Share

You are a junior dental officer in a government dental clinic. While performing root canal treatment on (46) you encounter difficulty in determining working length on the radiograph due to presence of large lingual tori.

**QUESTIONS**

1. Suggest any alternative technique that can determine working length with reasonable accuracy.
2. Name any two radiographic methods of working length determination.
3. What are the limitations of radiographic method of working length


 Department of Conservative Dentistry & Endodontics

 You are screen sharing. Stop Share

Farah, a 38-year-old female patient, reports to your dental clinic complaining of pain with lower left back tooth since six months. Patient gives history of pain on chewing and sensitivity to cold beverages and food.

On clinical examination, you find fracture of tooth 37 originating from occlusal surface extending to the cervical third of the crown on both mesial and buccal aspect.


The tooth is vital and radiographic evaluation inconclusive.




**Fig 5.4A and B**

**QUESTIONS**


1. What type of longitudinal tooth fracture is noticed in the above case?
2. List 2 causes of fracture in the above case.
3. Outline the management for this case.

 Department of Conservative Dentistry & Endodontics


 You are screen sharing. Stop Share

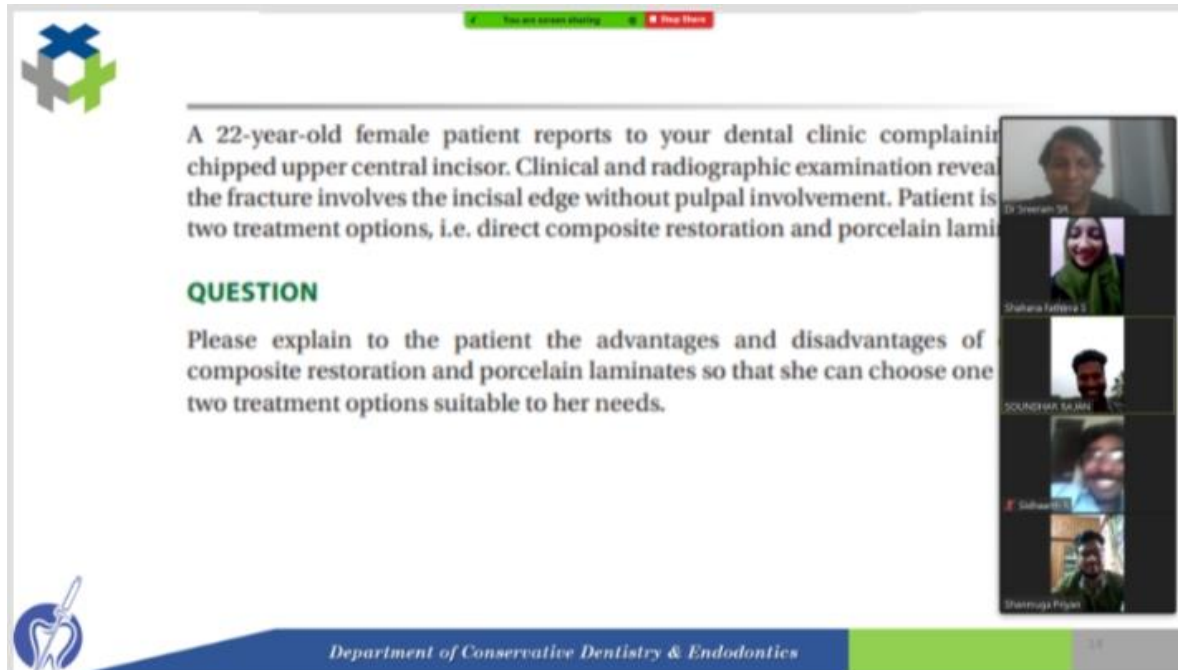
Below are the illustrations of different types of failure of amalgam restoration.

- Identify the type of failure and state 2 reasons each for the failure.



**Fig 5.8A to C**

 Department of Conservative Dentistry & Endodontics



A 22-year-old female patient reports to your dental clinic complaining of a chipped upper central incisor. Clinical and radiographic examination reveal the fracture involves the incisal edge without pulpal involvement. Patient is considering two treatment options, i.e. direct composite restoration and porcelain laminates.

**QUESTION**

Please explain to the patient the advantages and disadvantages of composite restoration and porcelain laminates so that she can choose one of the two treatment options suitable to her needs.


Dr. Sreenivas SR

Shahana Fathima S


SOUNDRAK KARAN

Saharshi S


Shanmuga Priya








































 Department of Conservative Dentistry & Endodontics

## PARTICIPANTS LIST

4:50:04  45%

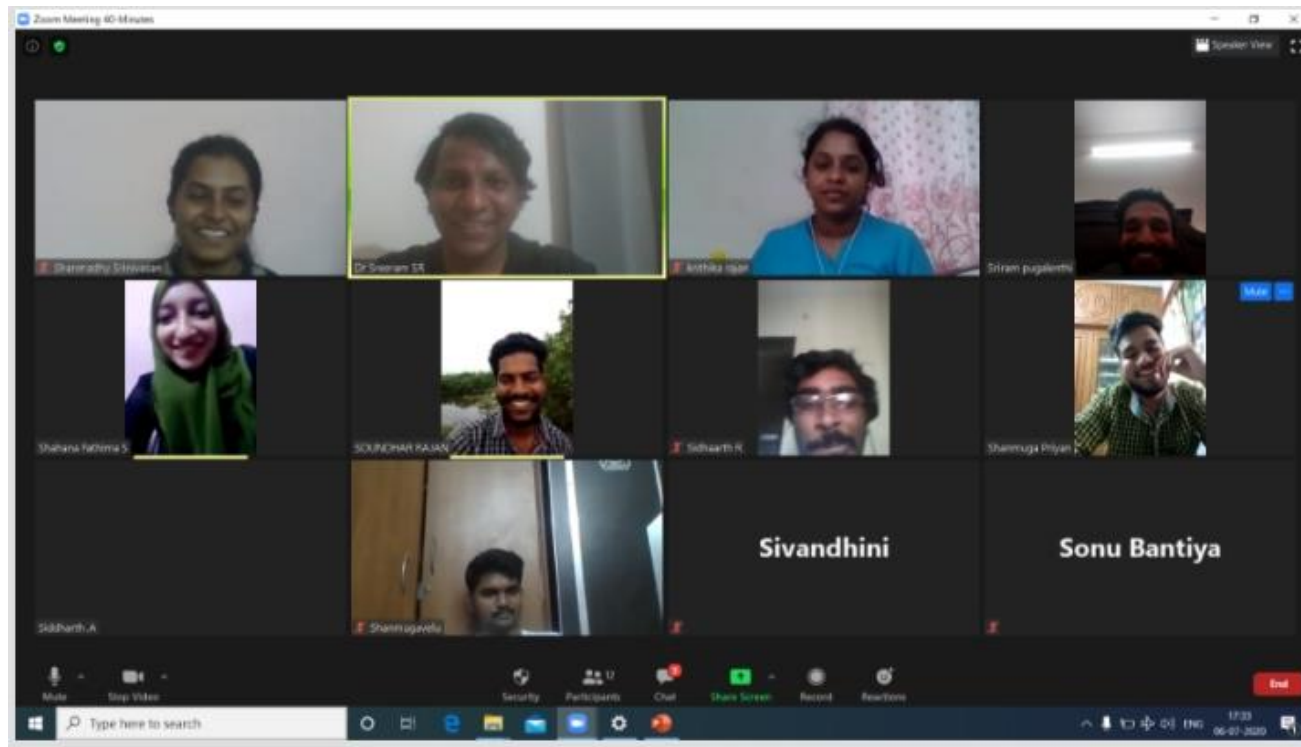
Close **Participants (13)**

 Search

	Sidhaarth R (me)	  >
	Dr Sreeram SR (host)	  >
	Shanmugavelu	  >
	Soundhar Rajan	  >
	krithika rajan	  >
	Shahana Fathima S	  >
	Shanmadhy Srinivasan	  >
	Shanmuga Priyan	  >
	Sharmista Karunakaran	  >
	Siddharth .A	  >
	Sivandhini	  >
	Sonu Bantiya	  >
	Sriram pugalenthii	  >

[Invite](#)

## VIDEO SLIDE











Department of Conservative Dentistry & Endodontics

Attendance Report

Date: 06.07.2020

Interns evaluation

Sadasiva Kadandale is inviting you to a  
scheduled Zoom meeting.

Topic: Interns B batch assessment

Time: Jul 6, 2020 10:45 AM Mumbai,  
Kolkata, New Delhi

Join Zoom Meeting

[https://us04web.zoom.us/j/76833220195?  
pwd=aEZlMEp3ZUViNWFWSmYvejZMbGhq  
dz09](https://us04web.zoom.us/j/76833220195?pwd=aEZlMEp3ZUViNWFWSmYvejZMbGhqdz09)

Meeting ID: 768 3322 0195

Password: 5zGZnG



**Chettinad**  
Dental College & Research Institute


10:54



4G LTE


22



Close


Participants (13)



 kaaviya c


  >



 Haritha RK


  >



 Hema Latha


  >



 Iswarya srinivasan


  >



 Joanna Gracy.P


  >



 kaviya boopalan


  >



 Keerthana Manikandan


  >



 Keerthana Sivaraman


  >



 Kokila S K

  >

 Rinshi Fasal

  >

 Shafeeq Ahamed

  >

Invite



**Chettinad**  
Dental College & Research Institute

10:54

4G LTE

22


Close

Participants (13)


Search

IK


Ilavarasi Kamatchi nathan (me)




Sadasiva Kadandale (host)



kaaviya c



Haritha RK



Hema Latha

IS

Iswarya srinivasan

JG


Joanna Gracy.P

KB

kaviya boopalan

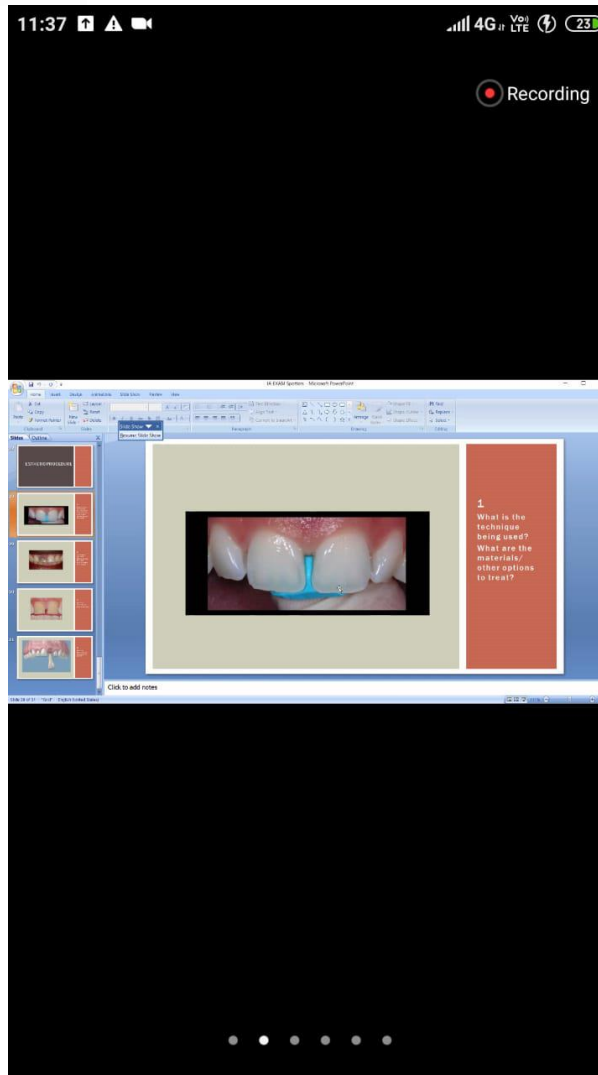
KM

Keerthana Manikandan



Keerthana Sivaraman

Invite



11:33 4G LTE 23

Zoom 07:46 Leave

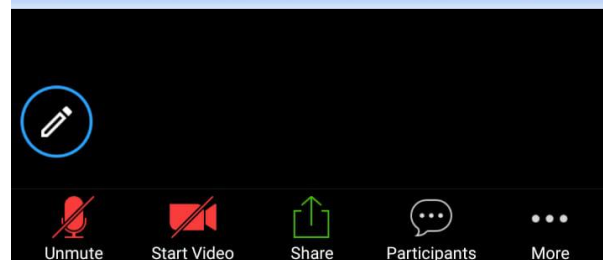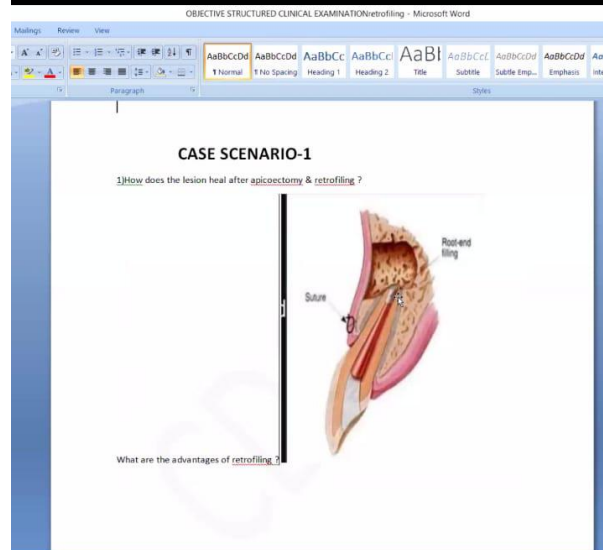
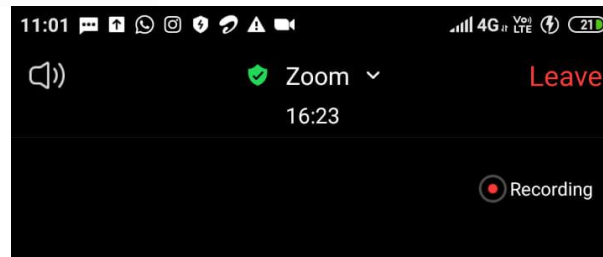
Recording

Microsoft PowerPoint - Microsoft PowerPoint

4 Identify, state types, contraindications

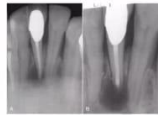
Click to add notes

Unmute Start Video Share Participants More



11:19 4G LTE 22

Recording



Question no:3:  
Discuss about this radiograph, Discuss about the treatment option for this case. Add a note on retro filling?



11:09 4G LTE 21

Zoom 23:45 Leave

Recording

Click to add notes

3 Identify, indications, contraindications, Materials used

Unmute Start Video Share Participants More

11:01 4G+ You LFE 21


Recording

OBJECTIVE STRUCTURED CLINICAL EXAMINATION - Microsoft Word

Mailings Review View

AaBbCcDd 1 Normal 1 No Spacing Heading 1 Heading 2 Title Subtitle Subtitle Emph... Emphasis Intense

Paragraph Styles



BUG Tips Endodontic Ultrasonic Ti...  
kerdental.com

ProUltra Surgical Endo Tip Size 3  
dentaplaystore.com

CPR Ultrasonic Tips | Obtura.com  
obtura.com

ProUltra Surgical Endodontic Tips (...  
dentaplaystore.com.au

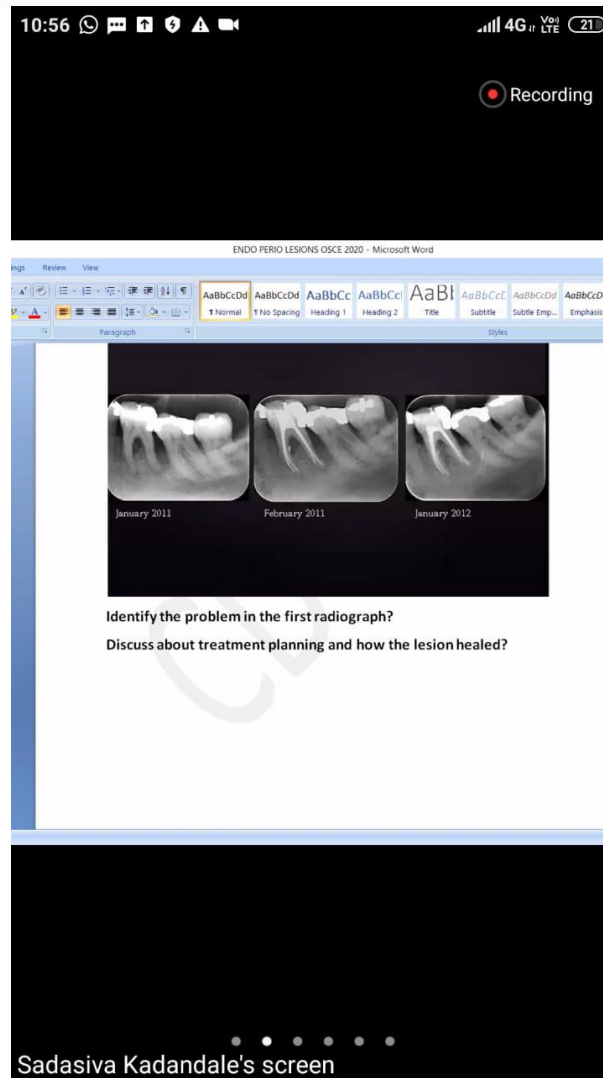
ProUltra Endo Tip Size 6  
dentaplaystore.com

Vista Piezo Ultrasonic Tips | VISTA ...  
dentalproductshopper.com

Piezoelectric ultrasonic insert / de...  
medicalexp.com

Diamond-coated stainless steel ult...

• • • • •




10:53 4G LTE 23

Zoom 08:07 Leave

Recording


Question no 3: Identify the problems seen in the radiograph? What are all the tests has to be done and treatment planning for the same?



Unmute Start Video Share Participants More

10:49 4G LTE 24

Recording



3  
Identify the  
instrument,  
what it is used  
for

Sadasiva Kadandale's screen


10:48

4G LTE 24

Zoom 03:38

Leave

Recording



2  
Identify the instrument, state uses, state the other variant

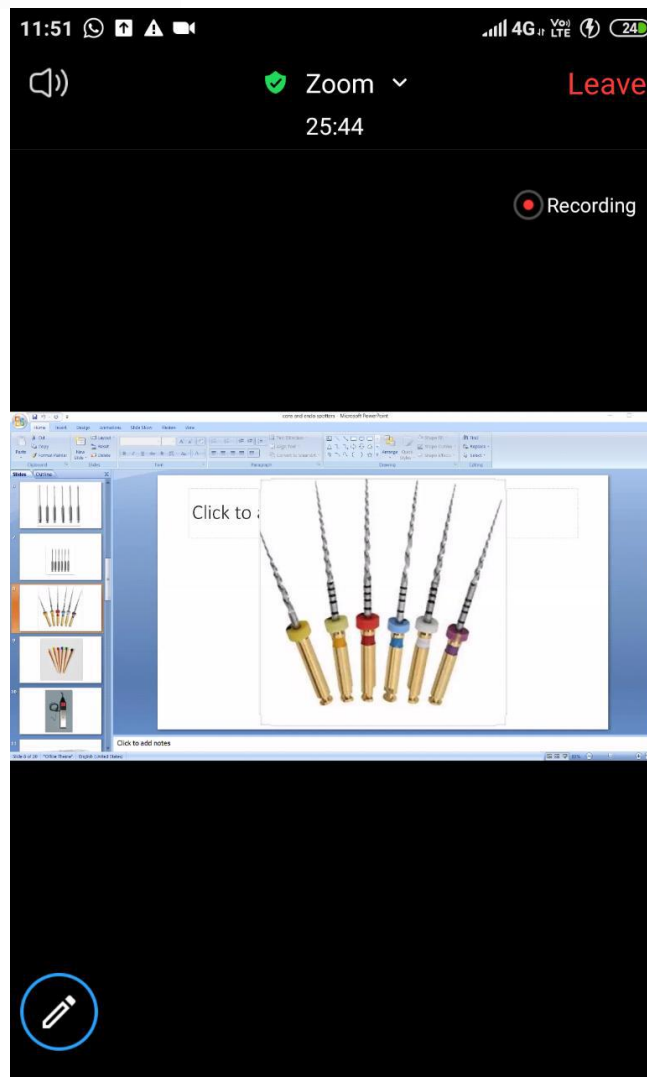
Unmute

Start Video

Share


Participants

More



13:01 4G LTE 14

Recording



3  
Composition,  
indications  
What is base,  
liner

Sadasiva Kadandale's screen






**Chettinad**  
Dental College & Research Institute

12:59 4G LTE 14

Zoom 10:32

Leave

Recording



4  
Identify the instrument, what is instrument formula?

Unmute Start Video Share Participants More

12:59 4G LTE 14

 Zoom 10:28 Leave

 Recording



5  
Identify, state  
parts



 Unmute

 Start Video

 Share

 Participants

 More

12:54

4G

Zoom

05:04

Leave

Recording



4  
Identify  
How will you  
confirm the  
diagnosis  
Treatment  
option

Unmute

Start Video

Share

Participants

More

12:56

4G LTE

13

Zoom

07:23

Leave

Recording



1

Identify, classify, state uses, state disadvantage

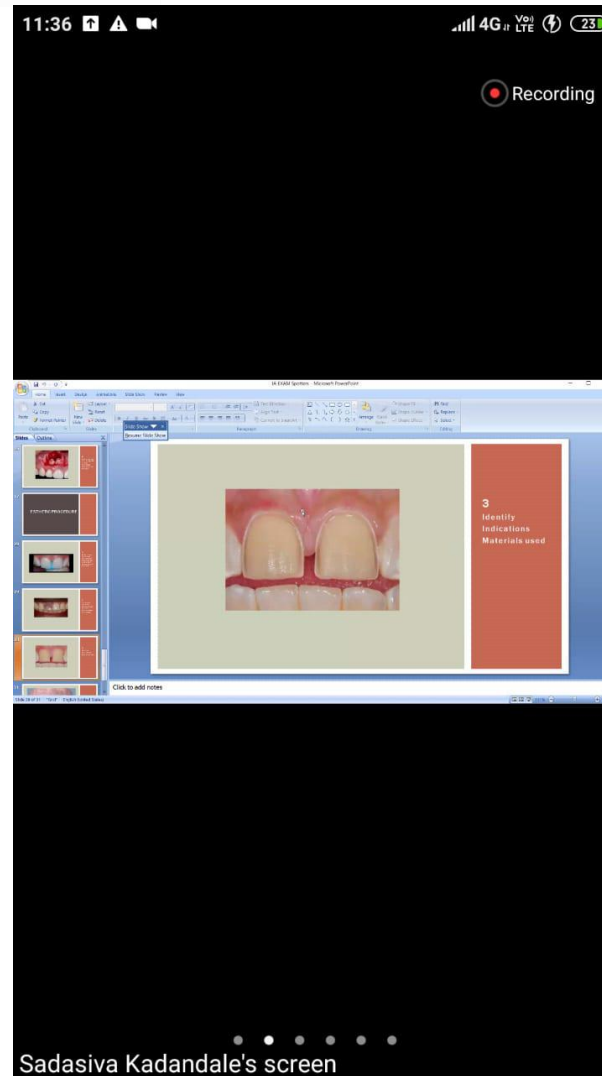
Unmute

Start Video

Share

Participants

More





## Department of Conservative Dentistry & Endodontics Attendance Report

Date: 10/07/2020  
UG Presentation- Interns meeting

Staff members:

- 1) Dr. K. Senthil Kumar
- 2) Dr. Sadasiva K.
- 3) Dr. Anupama R
- 4) Dr. Manu Unnikrishnan
- 5) Dr. Manjiri Honap
- 6) Dr. Sreeram

Timings: 12 – 12.45 pm  
UG Interns meeting  
Meeting Time: July 10/ 2020 12 pm

Zoom Meeting  
Manjiri Honap is inviting you to a scheduled Zoom meeting.

Topic: CRR I CLINICAL POSTING  
Time: Jul 10, 2020 12:00 PM India

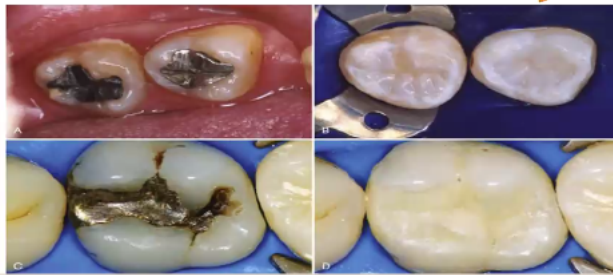
Join Zoom Meeting  
<https://us04web.zoom.us/j/75128641739?pwd=TE5tNzJxdmNZaU5LVDR3ZnB2dVBrQT09>

Meeting ID: 751 2864 1739  
Password: CDCRI  
No of members participated: 22




















































## CLASS I COMPOSITE RESTORATION



Presented by  
Yashini Thanikachalam  
PG III Year

Close	Participants (22)	
YI	Yashini's iPhone (me)	 
M	Manjiri Honap (Host)	
M	Manjiri Honap	 
	Anurekha Azhaguvel	 
GS	Gayathri S	 
IK	Ilavarasi Kamatchi nathan	 
JG	Joanna Gracy.P	 
	Keerthana Sivaraman	 
L	Lavanya	 
	Manu Unnikrishnan	 

	NIVASHINI C	 
	praveenragavan20	 
R	Ramya Vengi	 
RP	Revathy Parthasarathy	 
	Sadasiva Kadandale	 
SI	Sangita Ilango	 
	sankar vishwanath	 
	Shafeeq Ahamed	 
S	Srividhya Srinivasan	 
YT	Yashini Thanikachalam	 

Close

## Participants (22)



Manu Unnikrishnan



Monisha Durairaj



Nandhini R



NIVASHINI C



praveenragavan20



Ramya Vengi



Revathy Parthasarathy



Sadasiva Kadandale



Sangita Ilango



sankar vishwanath











Recording

Recording

**SRM KATTANKULATHUR DENTAL COLLEGE AND HOSPITAL**  
DEPARTMENT OF CONSERVATIVE DENTISTRY AND ENDODONTICS

NAAC "A++" Accredited Institution

### RESTOSCUPTIV - WEBINAR

Date: 11 July 2020, Saturday  
Time: 10.00 am - 12 Noon IST



**Dr. Ramya Raghu**  
Professor and HOD  
Conservative Dentistry and Endodontics  
Bangalore Institute of Dental Sciences



**Dr. Nandini Suresh**  
Associate Professor  
Conservative Dentistry and Endodontics  
Meenakshi Ammal Dental College

**TOPIC: OPTIMIZING TOOTH FORMS WITH DIRECT COMPOSITES**  
-RECENT TRENDS

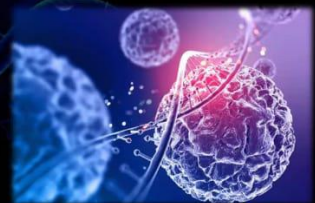
FOR FREE REGISTRATION <https://forms.gle/FHASQ5iKEITYwv8U7>

AFTER REGISTRATION, YOU WILL RECEIVE A CONFIRMATION EMAIL CONTAINING INFORMATION ABOUT JOINING THE WEBINAR. E-CERTIFICATE WILL BE PROVIDED FOR ALL THE PARTICIPANTS AFTER THE SUBMISSION OF FEEDBACK FORM.

FOR MORE DETAILS VISIT US AT : <https://www.srmkattankulathur.ac.in>

## Regenerative Endodontics- A clinical perspective

**Dr. Nandini Suresh**  
Assoc Professor, MADC  
Assoc Editor, Endodontology Journal



Dr K Vijay Venkatesh's screen



Dr Nandini Suresh's screen





10:08

79.5 KB/S VLTE 4G+



Zoom

Leave



Zoom

Leave

Recording

Recording

## Problems of immature teeth



Wide root canals

Thin dentinal walls

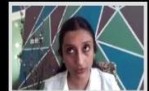Short roots

Cvek M. Endod Dent Traumatol 1992

Case selection

AAE Clinical Considerations for a Regenerative Procedure  
Revised 4/1/2018

- Tooth with necrotic pulp and an immature apex.
- Pulp space not needed for post/core, final restoration.
- Compliant patient/parent.
- Patients not allergic to medicaments and antibiotics necessary to complete procedure



Chats

Raise Hand

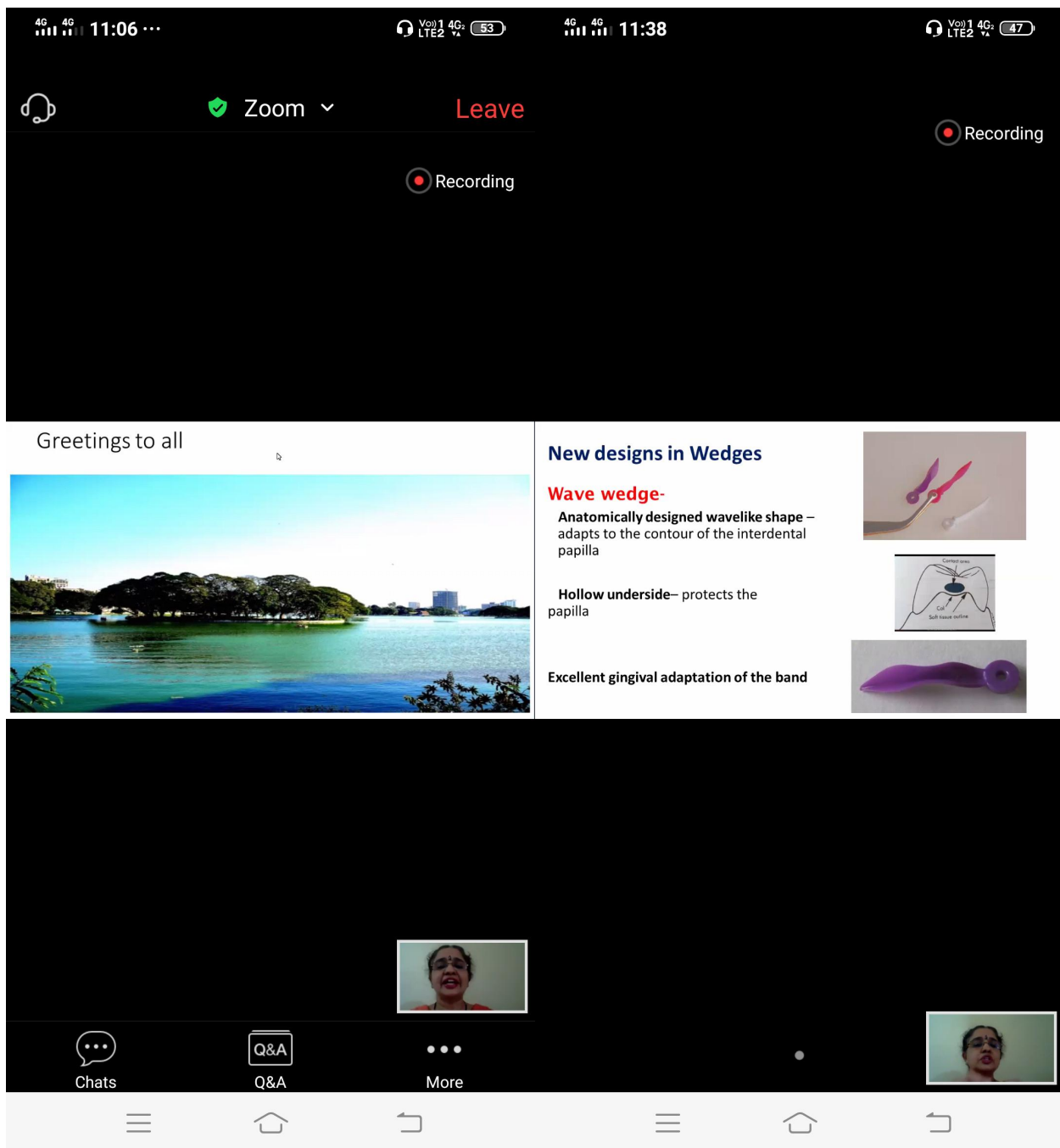
Q&A

More

Chats

Q&A

More



4G

11:38

V01 4G

LTE2 47

4G

11:11

V01 4G

LTE2 52

Zoom

Leave

Recording




Recording


### New Designs in Wedges

#### Prewedging aids

Plastic wedges with a metal fin or band to protect the adjacent tooth during cavity preparation.

Fender wedge.  
Wedge guard.





Chats

Q&A

More







