


**DEPARTMENT OF ORAL PATHOLOGY AND MICROBIOLOGY****Record of E-Class**

<b>PLATFORM</b>	 <b>zoom</b> <a href="https://us04web.zoom.us/j/8704121592">https://us04web.zoom.us/j/8704121592</a>
<b>DATE</b>	<b>04-07-2020</b>
<b>TIMING</b>	<b>8.30 – 10.00 AM</b>
<b>SESSION</b>	<b>Reiter's Syndrome And Sarcoidosis</b>
<b>PRESENTING FACULTY</b>	<b>Dr. Sreeja MDS</b>
<b>UG PARTICIPANTS</b>	<b>CRI POSTED IN ORAL PATHOLOGY- 3 Participants ( P. Akansha Tiny , B. Clement Solomon , Rinshi Mol P R ) III Year BDS</b>

# FACULTY – DR SREEJA

## PRESENTATION SHARED SCREEN

PowerPoint Slide Show – [ALLERGIC AND IMMUNOLOGIC - 3] – PowerPoint (Product Activation Failed)

### Agenda

- Reiters syndrome
- Sarcoidosis
- Wegeners granulomatosis
- Angioedema
- Contact stomatitis

# FACULTY – DR SREEJA

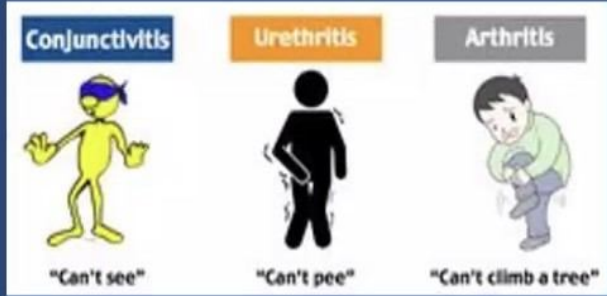
## PRESENTATION SHARED SCREEN

PowerPoint Slide Show - [ALLERGIC AND IMMUNOLOGIC - 3] - PowerPoint (Product Activation Failed)

### Reiters syndrome.....

Clinical features

- Age:20-40 yrs.
- Gender: male
- **Eye:**  
Conjunctivitis  
Uveitis
- **Genital lesion:**  
Urethritis, cervicitis, ulcers
- **Arthritis:**  
Large joints and knees,  
No fluid
- **Oral lesions:**  
painless aphthous like  
Geographic tongue  
Pruritic spots
- **Skin:**  
well circumscribed erythematous



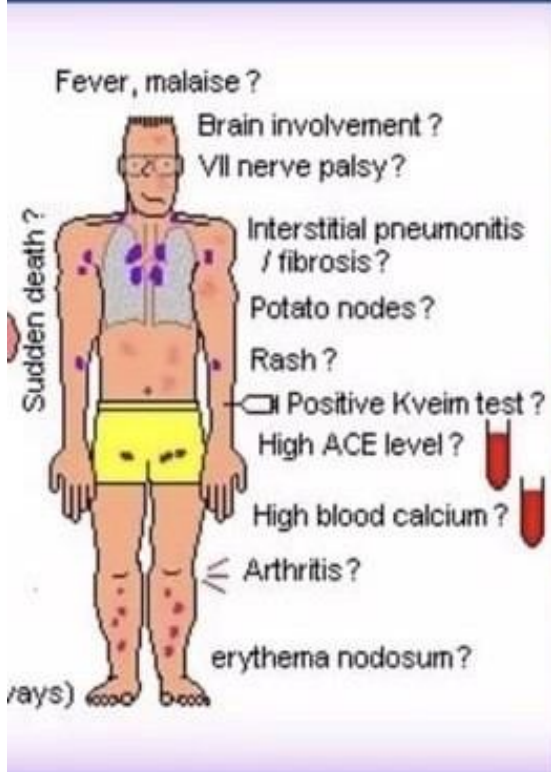
The diagram consists of three panels, each with a title and an illustration. The first panel, titled 'Conjunctivitis', shows a yellow stick figure wearing a blue eye patch and holding a white cloth to its eye, with the caption 'Can't see' below. The second panel, titled 'Urethritis', shows a black silhouette of a person with a white line indicating pain or discharge from the urethra, with the caption 'Can't pee' below. The third panel, titled 'Arthritis', shows a person in a green shirt and blue pants struggling to climb a tree, with the caption 'Can't climb a tree' below.

SLIDE 5 OF 39

# FACULTY – DR SREEJA

## PRESENTATION SHARED SCREEN

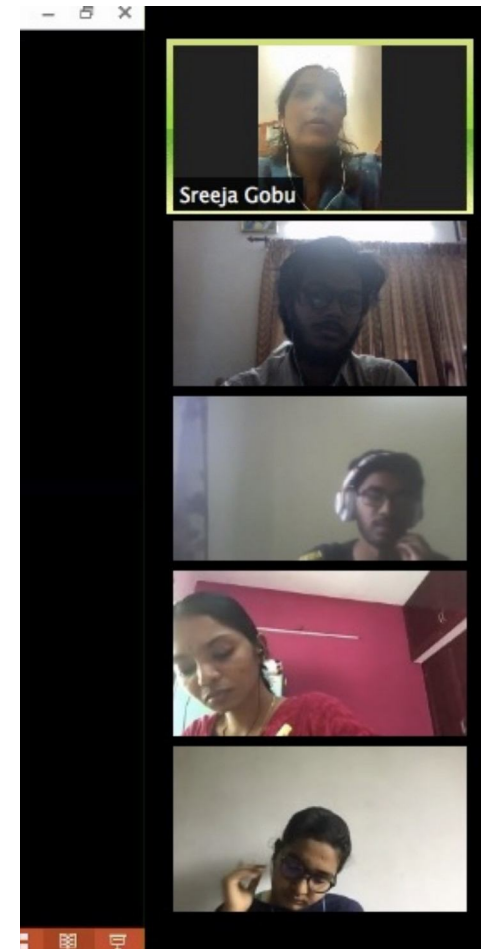
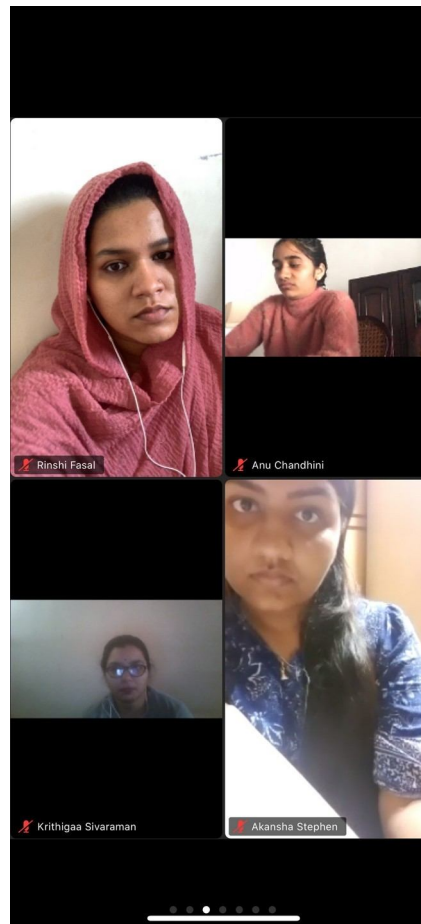
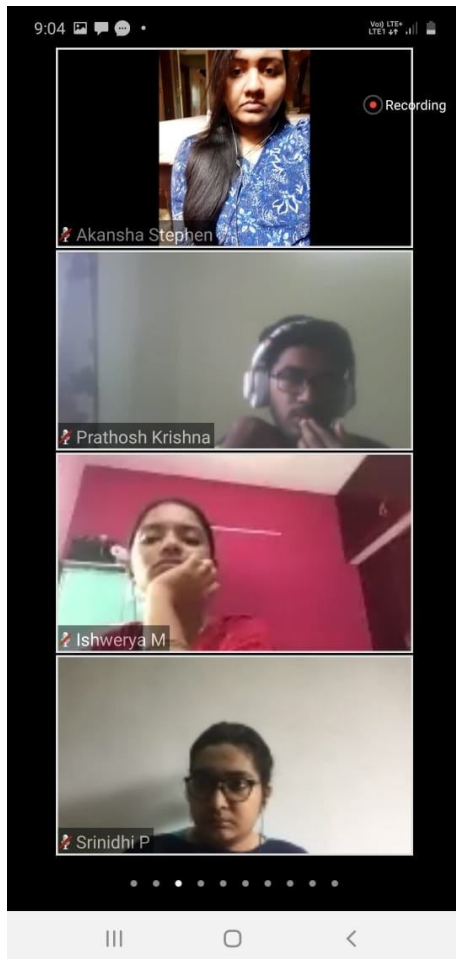
PowerPoint Slide Show - [ALLERGIC AND IMMUNOLOGIC - 3] - PowerPoint (Product Activation Failed)



- SCALP- Meningitis,
- Lupus peroni- violeceous , non painful rashes on skin (nose, cheek, lip, back, neck)
- EYE- opacity of cornea, retina, optic nerve damage, sicca
- Bilateral parotitis- xerostomia
- Hilar lymphadenopathy
- Pericarditis
- Speelnomaegaly, heaptomegaly
- Bone marrow
- LEG – Erythema nodosum- painful
- LOFGREN SYNDROME- Erythema nodosum + bilateral hilar lymphadenopathy + joint pain

# FACULTY – DR SREEJA

## VIDEO TITLES



# FACULTY – DR SREEJA

## PRESENTATION PARTICIPANTS ATTENDANCE

