

**DEPARTMENT OF PEDODONTICS AND PREVENTIVE DENTISTRY****SCHEDULE FOR INTERNS (29.6.2020-04.7.2020)**

S.NO	DATE	TOPIC	FACULTY
1.	29.6.2020	Oral Medicine IA	-
2.	30.6.2020	Paedodontics IA	Dr Joe Louis C Dr Daya Srinivasan Dr Senthil Eagappan Dr Divya Natarajan
3.	1.7.2020	Orthodontics IA	-
4.	2.7.2020	Periodontics IA	-
5.	3.7.2020	Prosthodontics IA	-
6.	4.7.2020	Pulpectomy	Dr Joe Louis C Dr Daya Srinivasan Dr Senthil Eagappan Dr Divya Natarajan

30.6.2020



DEPARTMENT OF PEDIATRICS & PREVENTIVE DENTISTRY

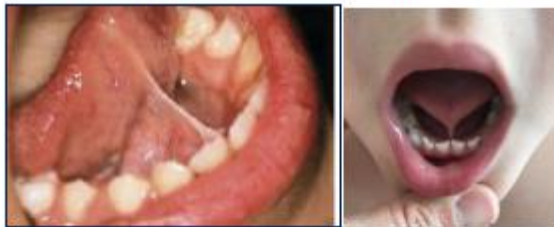General Instructions

- Kindly answer the following questions in A4 paper. Write your name, date and Reg no.
- There are 20 questions. Each carrying 5 marks each. Total is for 100 marks.
- Write the answers in the given order by clearly mentioning the question number.

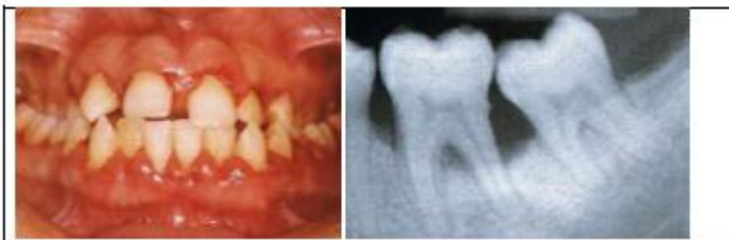Department of Pediatric & Preventive Dentistry Clinical Questions

20 questions*5marks=100 marks

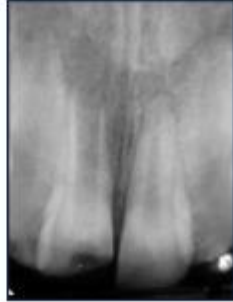1. What is the diagnoses of given condition in the pictures. What are the problems occurring because of this. What is the treatment option?



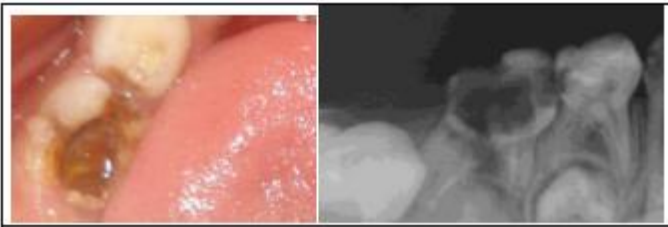2. Patient is thirteen years old, complaints of mobility of central incisors and first molars with minimal plaque accumulation. What could be the diagnosis?



4. A 9 year old patient comes to you with history three months back fall and subsequent fracture of upper central incisor(11). How will you diagnose & treat



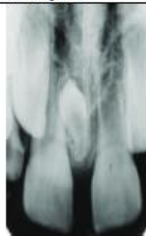
5. Five year old child complaints of pain with respect to 75? On examination, tooth is grossly decayed with abscess. What is the treatment option?



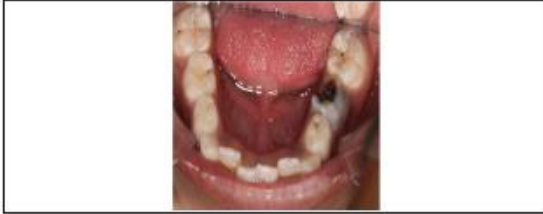6. A karate learning kid experiences frequent hits on his face. What will you suggest as a dentist. Write a note on it.



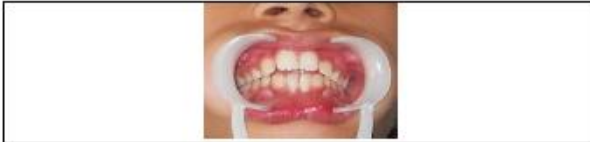7. An eight year old child is coming with complaint of spacing between teeth. What could be the treatment option



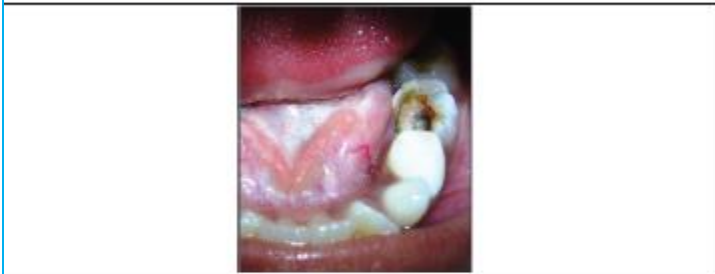8. A 7 yr old child with previous history of rheumatic fever comes to dental clinic for extraction of grossly decayed 75. What are the precautions and how will you manage the patient?



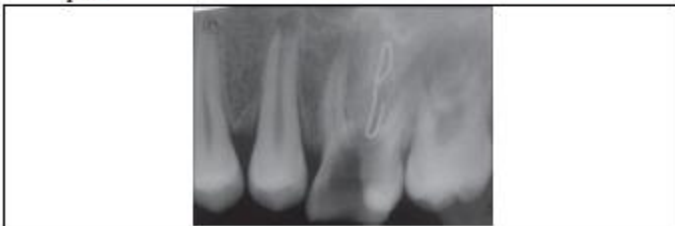9. The parents of 9 year old girl child complaints that their child sucks her right thumb when she is alone and before going to bed. On examination her upper anterior are proclined with open bite. The child is willing but unable to stop the habit. Devise the treatment plan for the patient



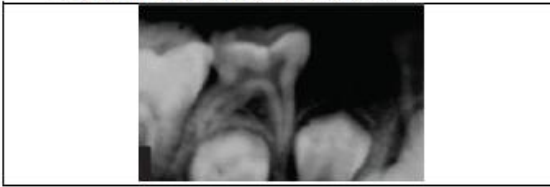
10. A 7 year old child is coming with swelling and pain wrt 75. O/E it is found 75 is grossly decayed with pus discharge. The child weighs 28kg and is not allergic to any medication. Write the prescription for the patient so that extraction could be done in subsequent appointment.



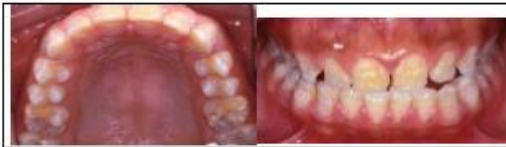11. A 12 year old patient complaints of pain in upper permanent first molar for past one week. IOFA was taken. What does it reveal? What is the treatment plan?



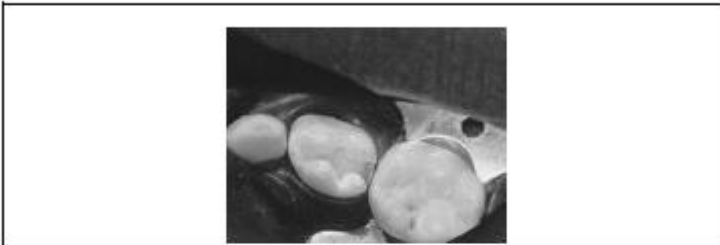12. A 7 year old complains of pain in lower right posterior region. On examination carious tooth with root stump is found. Given below is the radiograph. What is the diagnosis and management?



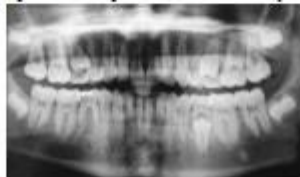
13. A 13 year old male patient came for regular dental check up. Patient was concerned about the appearance of teeth and sensitivity experienced. No medical history. Patient from optimally fluoridated area. Minimal plaque and calculus deposits. Teeth exhibited classical features of small, discrete pinpoint-to-pinhead sized pits, which were arranged in horizontal and vertical rows with open contacts between teeth. Diagnosis and management?



14. A 4 year old cooperative child presents with cavity involving proximal region in 74. History of GIC restoration done in the same teeth, 6 months back. What would be the best alternative option and explain the procedure in detail?

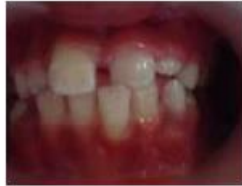

15. A healthy 13-year came with the complaint of a toothache in the mandibular right molar region. Clinical examination showed the mandibular right second primary molar (85) to be symptomatic to percussion. How can you manage?



16. A known epileptic child is getting a seizure attack while you are performing a scaling procedure. How will you manage the emergency situation

17. A 9 year old female patient is coming with complaint of irregular arrangement of upper anteriors. What is the diagnosis? How will you correct?

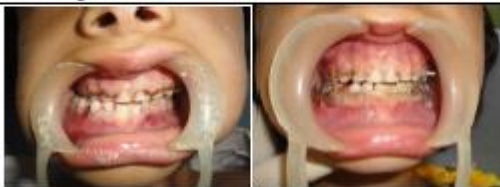

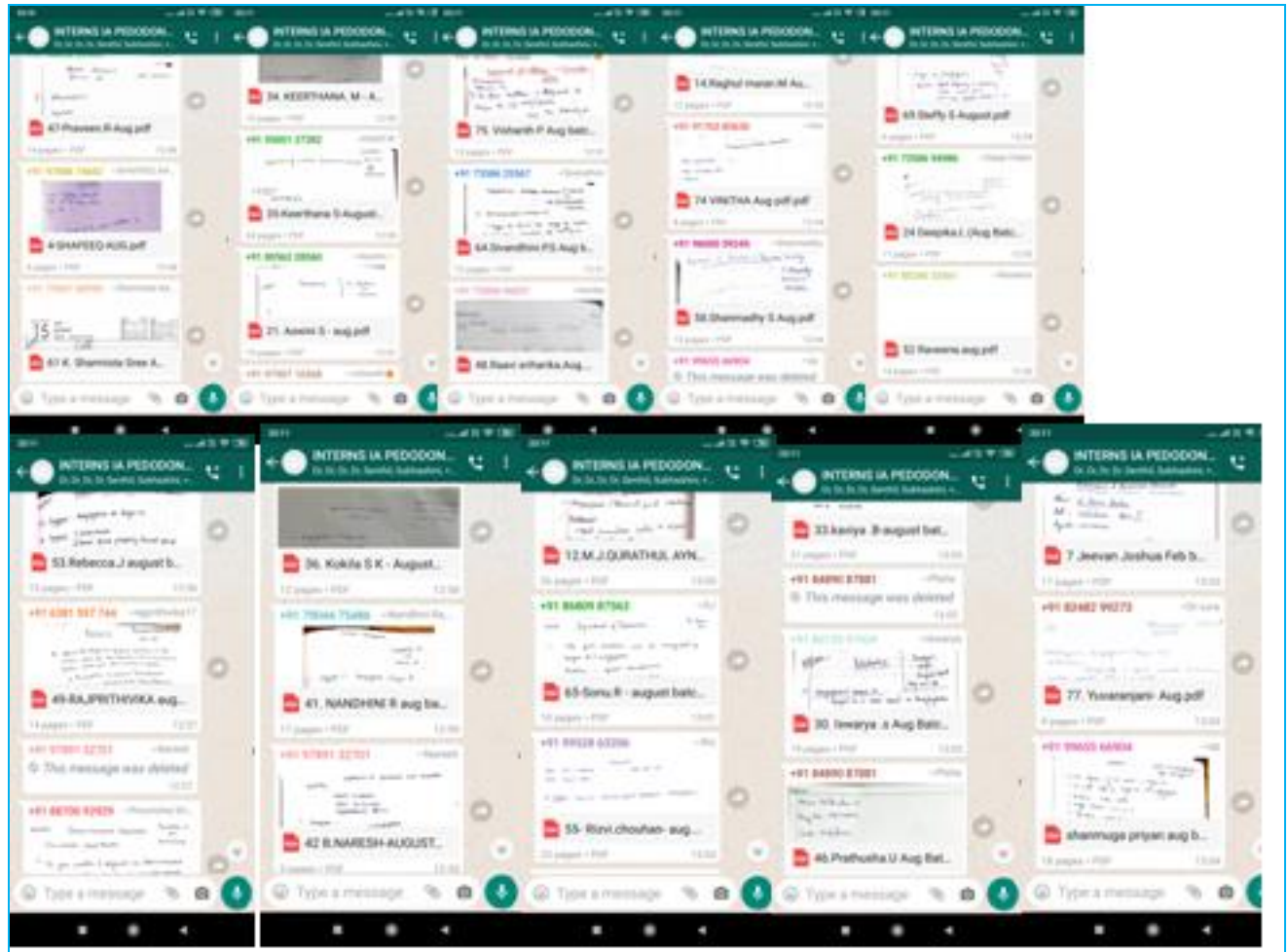
18. A 10 year old child accompanied with parent, having travel history and slight raise in temperature, sore throat is coming to you with complaint of deposits on his lower anterior teeth. How will you go about managing the case in present scenario?

19. You are working in a dental clinic, wherein you are asked to provide APF topical fluoride application to an 11 year old patient using disposable tray. How will you carry out the application? What are the post operative instructions given.



20. What is shown in the clinical picture below. Write a note on technique used in the second figure.





4.7.2020

Daya Srinivasan is inviting you to a scheduled Zoom meeting.

Topic: Daya Srinivasan's Zoom Meeting

Time: Jul 4, 2020 10:00 AM India

Join Zoom Meeting

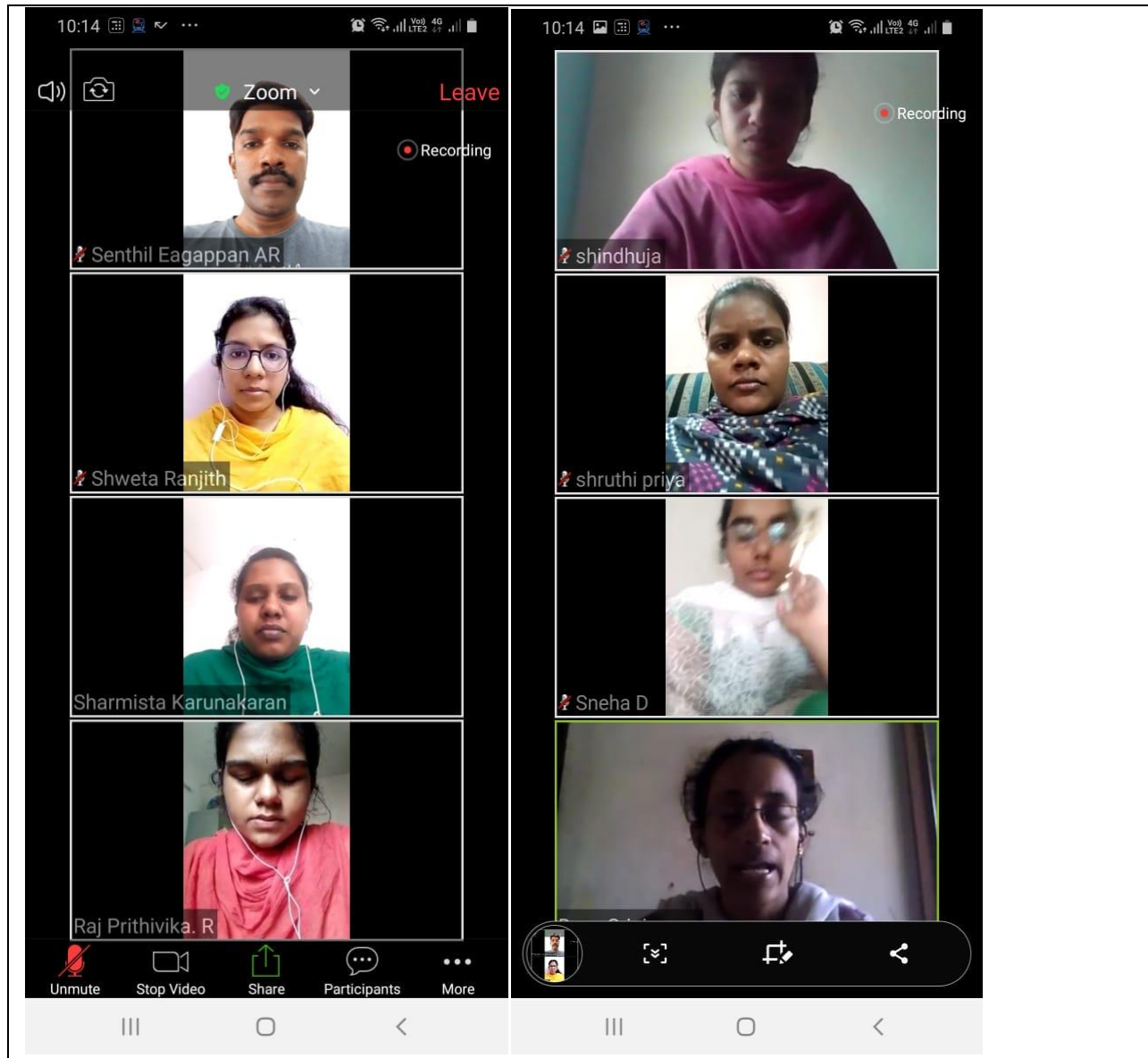
https://us04web.zoom.us/j/6664598002?pwd=z_NJGfjZjxt-7i38QxP9jDM514c

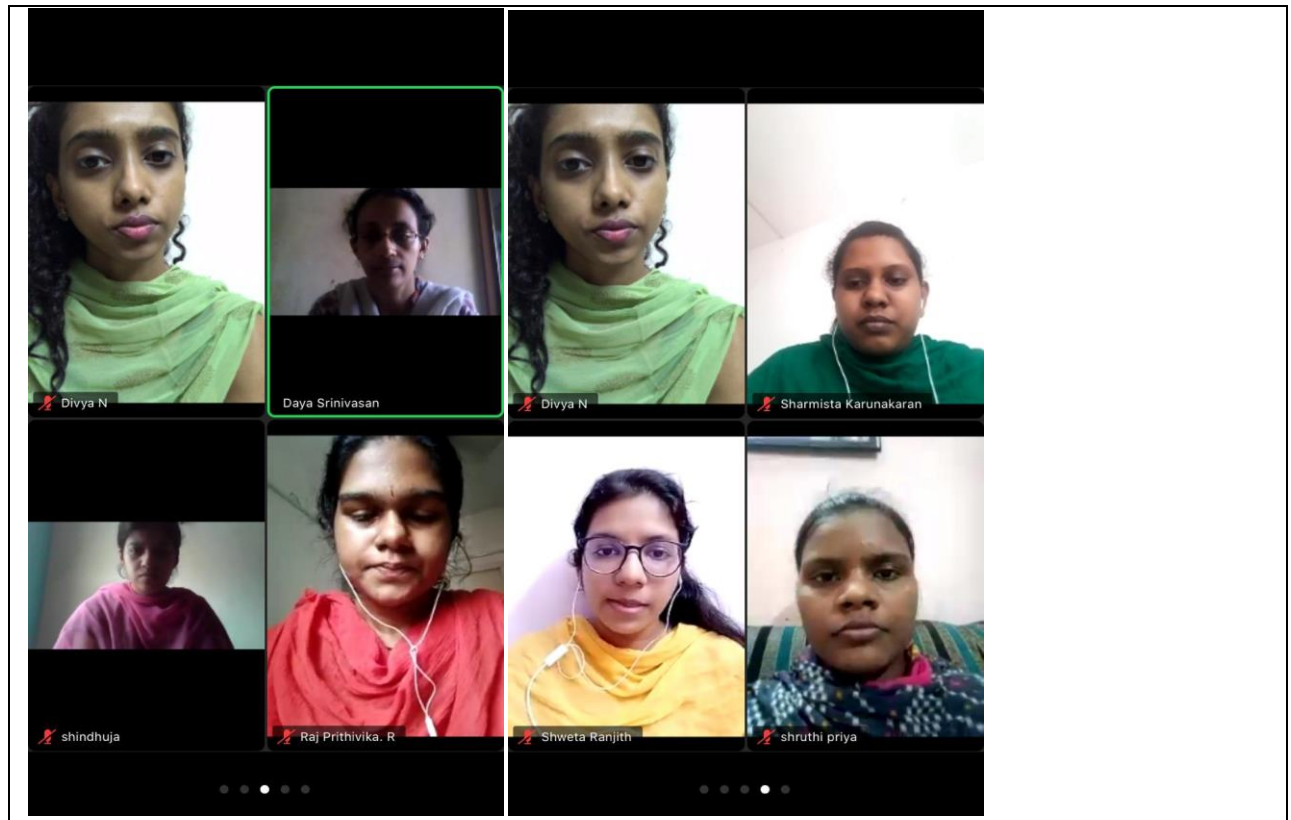
Meeting ID: 666 459 8002

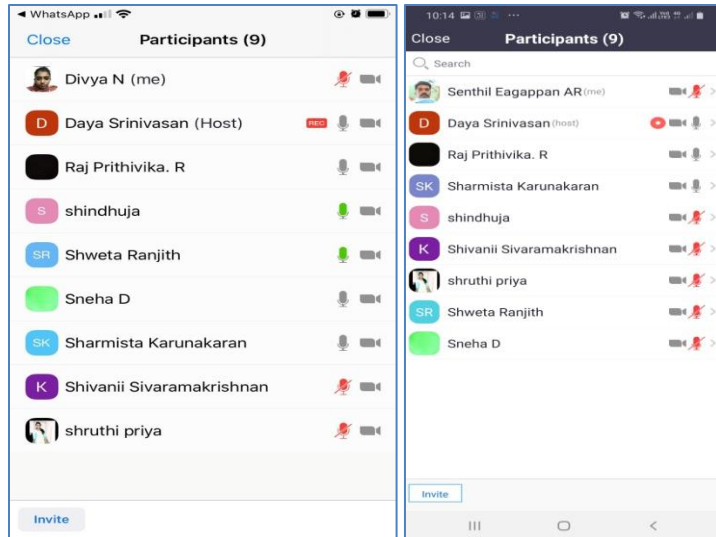
Password: pedo

Interns Present: Raj Prithvika, Sharmista Sree

Intern absent: Rizvi V.Chouhan







Pre test:

https://docs.google.com/forms/d/e/1FAIpQLSdt54AU63m59zHEXjMa0mxGxOreJZpLbAXf7vGYekdofQAYw/viewform?usp=pp_url

Email address *

rajprithivika17@gmail.com

Full official name *

Rajprithivika. R

The following are obturating techniques for Permanent teeth except *

1 point

☐ Cold Lateral Condensation
☒ Amalgam Plugger Condensation
☐ Warm Vertical condensation
☐ Thermafil technique

PULPECTOMY

Email address *

ksharmistasree@gmail.com

Full official name *

Sharmista Sree K

The following are obturating techniques for Permanent teeth except *

1 point

- ☒ Cold Lateral Condensation
- ☐ Amalgam Plugger Condensation
- ☐ Warm Vertical condensation
- ☐ Thermafil technique