


CDCRI/OP/2020/06514.05.2020

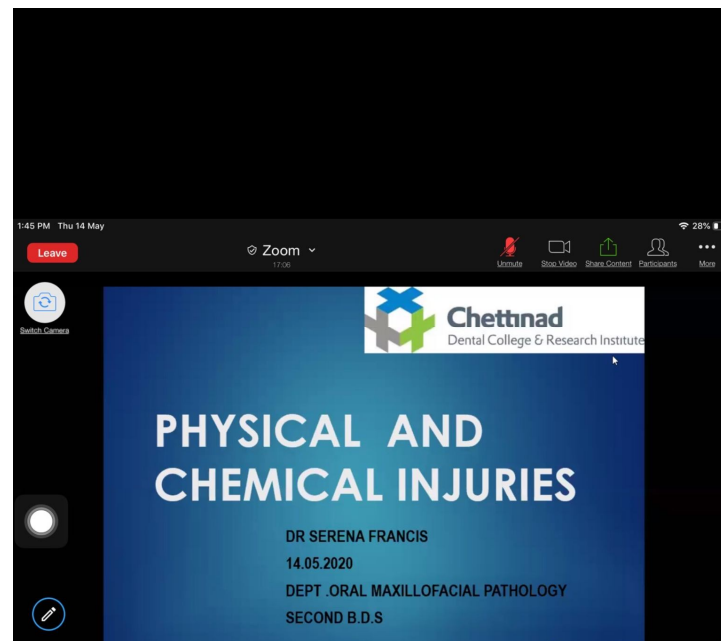
**DEPARTMENT OF ORAL PATHOLOGY AND MICROBIOLOGY**

**RECORD OF e CLASS**

<b>PLATFORM</b>	 <a href="https://us04web.zoom.us/j/78378397305?pwd=a2xkWIY4RFRsbmFkZmJwZWl1OHRudz09">https://us04web.zoom.us/j/78378397305?pwd=a2xkWIY4RFRsbmFkZmJwZWl1OHRudz09</a>
<b>SESSION</b>	<b>WEBINAR –PHYSICAL AND CHEMICAL INJURIES</b>
<b>PRESENTING FACULTY</b>	<b>Dr. SERENA FRANCIS</b>
<b>DATE</b>	<b>14.05.2020</b>
<b>TIMING</b>	<b>1:30 to 3:30 pm</b>
<b>UG PARTICIPANTS</b>	<b>Second BDS-95 participants</b>
<b>FACULTIES ATTENDED</b>	<b>DrSreeja,DrNachiammai,Dr Merlin,DrHariniPriya</b>

**FACULTY: DR.SERENAFRANCISPRESENTATION**

**SHARED SCREEN**



**FACULTY: DR.SERENA FRANCIS PRESENTATION**

**SHARED SCREEN**



The image is a screenshot of a Zoom mobile app interface. At the top, the status bar shows the time as 1:50 PM on Thursday, May 14, with a battery level of 26%. The Zoom app header includes a 'Leave' button, the Zoom logo, and icons for 'Unmute', 'Stop Video', 'Share Content', 'Participants', and 'More'. The main content area displays a presentation slide with a blue background. The slide contains a bulleted list of points regarding chemical injuries in dental procedures. Below the text is a photograph of a patient's oral mucosa showing significant redness and swelling, labeled 'Chemical burns' with a red arrow pointing to the affected area. A small video thumbnail of Dr. Serena Francis is visible in the bottom right corner of the screen.

- Similarly chemical injury could result from undue or careless handling of chemicals and dental instruments during dental treatment procedures.
- A wide array of chemicals and drugs come into contact with oral mucosa and some of them may cause direct mucosal trauma due to their caustic nature.
- Some people tend to apply certain chemicals as a remedy for their oral problems such as application of aspirin to ease toothache.
- Health care practitioners are also responsible in applying certain chemicals in the mouth for treatment or investigative procedures.

Chemical burns

FACULTY: DR.SERENA FRANCIS PRESENTATION

SHARED SCREEN

2:37 PM Thu 14 May

Zoom

Leave

How to Remember Side Effects of Phenytoin

H	HIRSUTISM
O	OSTEOMALACIA
T	TERATOGENICITY
M	MEGALOBLASTIC ANEMIA
A	ARRHYTHMIA (at toxic doses)
I	INHIBITS INSULIN RELEASE
L	LYMPHADENOPATHY
G	GUM HYPERTROPHY
A	ATAXIA (at toxic doses)
N	NYSTAGMUS (at toxic doses)
D	DIPLOPIA (at toxic doses)
K	VITAMIN K DEFICIENCY

**HOW TO REMEMBER  
SIDE EFFECTS OF  
PHENYTOIN**

IN 2 MINS

**FETAL HYDANTOIN  
SYNDROME**

- Cleft Lip
- Cleft Palate
- Microcephaly
- Hypoplastic pharynx

Serena Francis

