

DEPARTMENT OF ORAL AND MAXILLOFACIAL PATHOLOGY & MICROBIOLOGY

E-LEARNING CLASS RECORDS

COURSE: BACHELOR OF DENTAL SURGERY

YEAR: III BDS REGULAR & SUPPLEMENTARY

SUBJECT: ORAL AND MAXILLOFACIAL PATHOLOGY

DATE: 06.04.2020 to 11.04.2020

CIRCULAR NO	DATE	TIMING	TOPIC	PRESENTING FACULTY/ FACULTY IN CHARGE	FACULTY ATTENDED	NO OF STUDENTS ATTENDED
CDCRI/OP/2020/030	04.04.2020	08.30 am - 10.00 am	Malignant Salivary Gland Neoplasms - Adenoid Cystic Carcinoma (ACC)	Dr. Merlin Jayaraj	Dr. R. Sathish Muthukumar	87
CDCRI/OP/2020/032	04.04.2020	02.00 pm - 04.00 pm	Oral Pathology Lab	Dr. Nachiammai Dr. Merlin Jayaraj, Dr. Serena, Dr. Harini		72
CDCRI/OP/2020/033	04.04.2020	02.00 pm - 04.00 pm	Oral Pathology Lab - Assignment on ACC	Dr. Merlin Jayaraj	Dr. R. Sathish Muthukumar	9
CDCRI/OP/2020/034	06.04.2020	08.30 am - 10.00am	Malignant Salivary Gland Neoplasms - Mucoepidermoid carcinoma	Dr. Merlin Jayaraj	Dr. R. Sathish Muthukumar	84


CDCRI/OP/2020/041	11.04.2020	08.30 am-09.30 am	Malignant Salivary Gland Neoplasms - Polymorphous Low-grade Adeno carcinoma, Carcinoma Ex-Pleomorphic Adenoma	Dr. Merlin Jayaraj	Dr. R. Sathish Muthukumar	87
CDCRI/OP/2020/043	11.04.2020	02.00 pm - 03.00 pm	Malignant Salivary Gland Neoplasms- Acinic Cell Carcinoma	Dr. Merlin Jayaraj		90

CDCRI/OP/2020/034

06.04.2020

DEPARTMENT OF ORAL AND MAXILLOFACIAL PATHOLOGY AND MICROBIOLOGY

RECORD OF e-CLASS

PLATFORM	 https://us04web.zoom.us/j/9586815047?pwd=MnJKWWdWd3BMdk5XcUlxEgVtUxCdz09
SESSION	WEBINAR - MALIGNANT SALIVARY GLAND NEOPLASM - MUCOEPIDERMOID CARCINOMA
PRESENTING FACULTY	DR. MERLIN JAYARAJ
DATE	06.04.2020
TIMING	08.30 am to 10.00am
UG PARTICIPANTS	Third BDS (77 Regular Batch and 7 Supplementary Batch) - 84 participants
FACULTY ATTENDED	Dr. R. Sathish Muthukumar



Chettinad
Dental College & Research Institute

FACULTY: DR. MERLIN JAYARAJ PRESENTATION

SHARED SCREEN



MALIGNANT SALIVARY GLAND NEOPLASM- MUCOEPIDERMOID CARCINOMA

DR.MERLIN JAYARAJ MDS
DEPT OF ORAL PATHOLOGY
04.04.2020





Chettinad
Dental College & Research Institute

FACULTY: DR. MERLIN JAYARAJ PRESENTATION

SHARED SCREEN

Recording

Bavadharini

Merlin Jayaraj

Sathish Muthukun

Prathosh Kris

Kaviya samp

MUCOEPIDERMOID CARCINOMA

- is a malignant epithelial tumour composed of varying proportions of mucous secreting cells, epidermoid cells and intermediate cells forming cysts and solid islands.
- WHO – malignant glandular epithelial neoplasm characterized by **mucous, intermediate and epidermoid** [Squamous] cells, with columnar, clear cell and oncocytoid features.
- Principal tumour of radiation related to SG malignancies. seen in survivors of atomic bombing of Hiroshima and Nagasaki and children treated for leukemia with radiotherapy
- Most common malignant salivary gland neoplasm and second highest frequency of occurrence among all salivary gland tumours.
- Most common malignant salivary gland neoplasm in children

FACULTY: DR. MERLIN JAYARAJ PRESENTATION


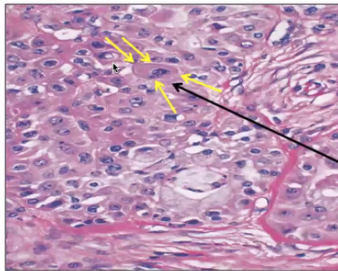
SHARED SCREEN

Recording

Bavadarini... Merlin Jayaraj Sathish Muthuk... Manigandan T Barath kumar Shanmugavel...

Microscopic features of MEC

Epidermoid or Squamoid cells



- ✓ Epidermoid/squamous cells predominate
- ✓ Scanty mucous cells
- ✓ Extremely less cystic area

Epidermoid or squamous cells

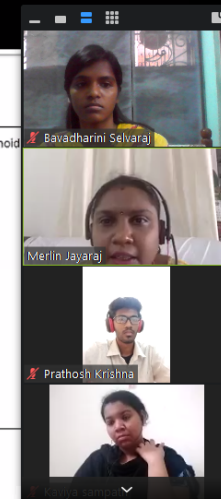
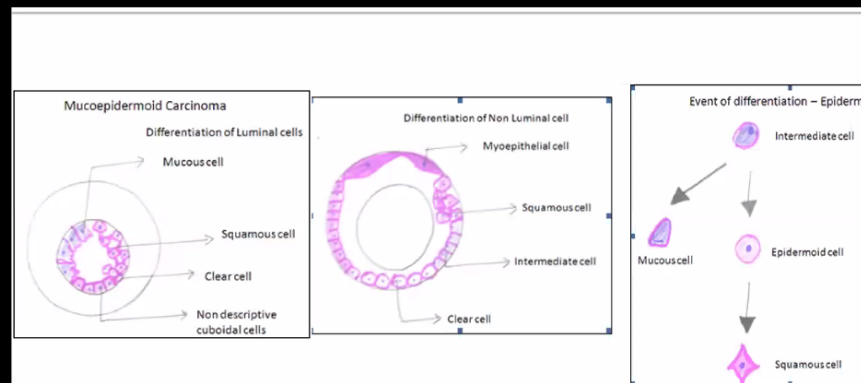


Chettinad
Dental College & Research Institute

FACULTY: DR. MERLIN JAYARAJ PRESENTATION

SHARED SCREEN

HISTOGENESIS OF MEC

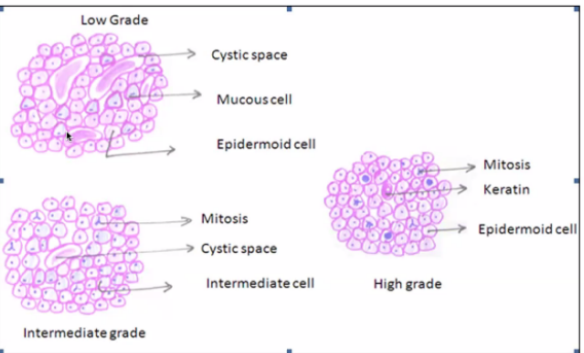


FACULTY: DR. MERLIN JAYARAJ PRESENTATION

SHARED SCREEN

Recording

H/P- GRADING

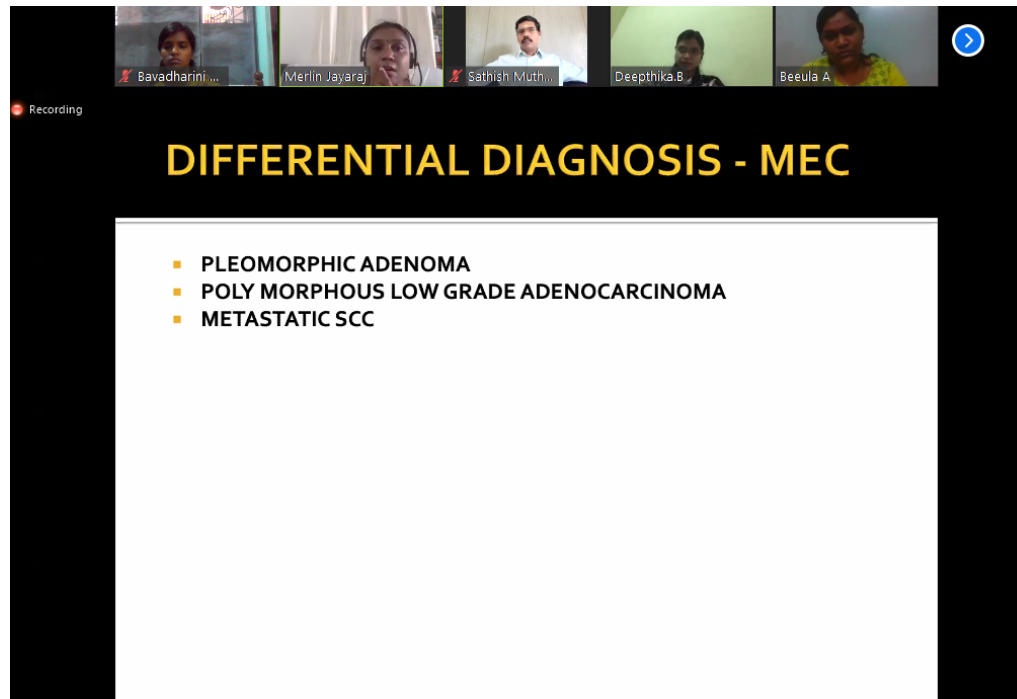


The diagram illustrates the H/P-Grading of dental lesions, showing three distinct grades of cellular organization:

- Low Grade:** Characterized by a well-organized structure with a central **Cystic space**, surrounded by **Mucous cells** and **Epidermoid cells**.
- Intermediate grade:** Shows a more disorganized structure with **Mitosis** and **Cystic space** present, along with **Intermediate cells**.
- High grade:** Displays a highly disorganized structure with **Mitosis**, **Keratin**, and **Epidermoid cells**.

FACULTY: DR. MERLIN JAYARAJ PRESENTATION

SHARED SCREEN



Recording

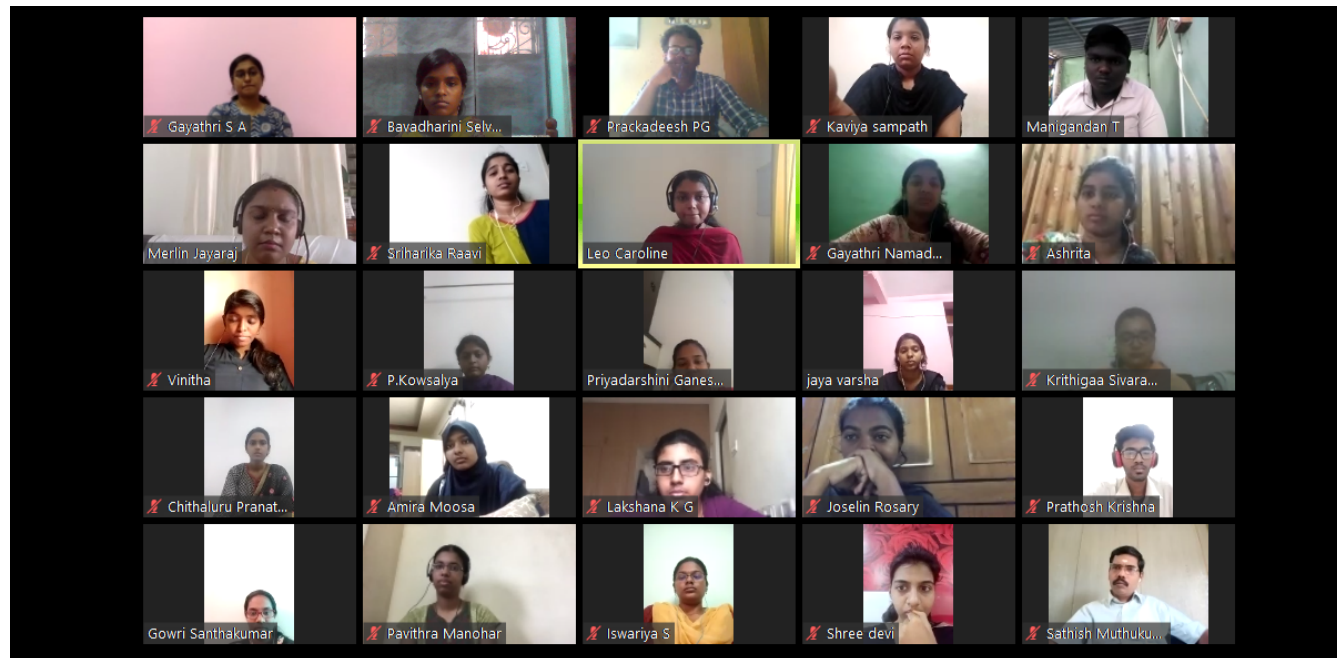Bavadarini ... Merlin Jayaraj Sathish Muthi... Deepthika.B Beeula A

DIFFERENTIAL DIAGNOSIS - MEC

- PLEOMORPHIC ADENOMA
- POLY MORPHOUS LOW GRADE ADENOCARCINOMA
- METASTATIC SCC

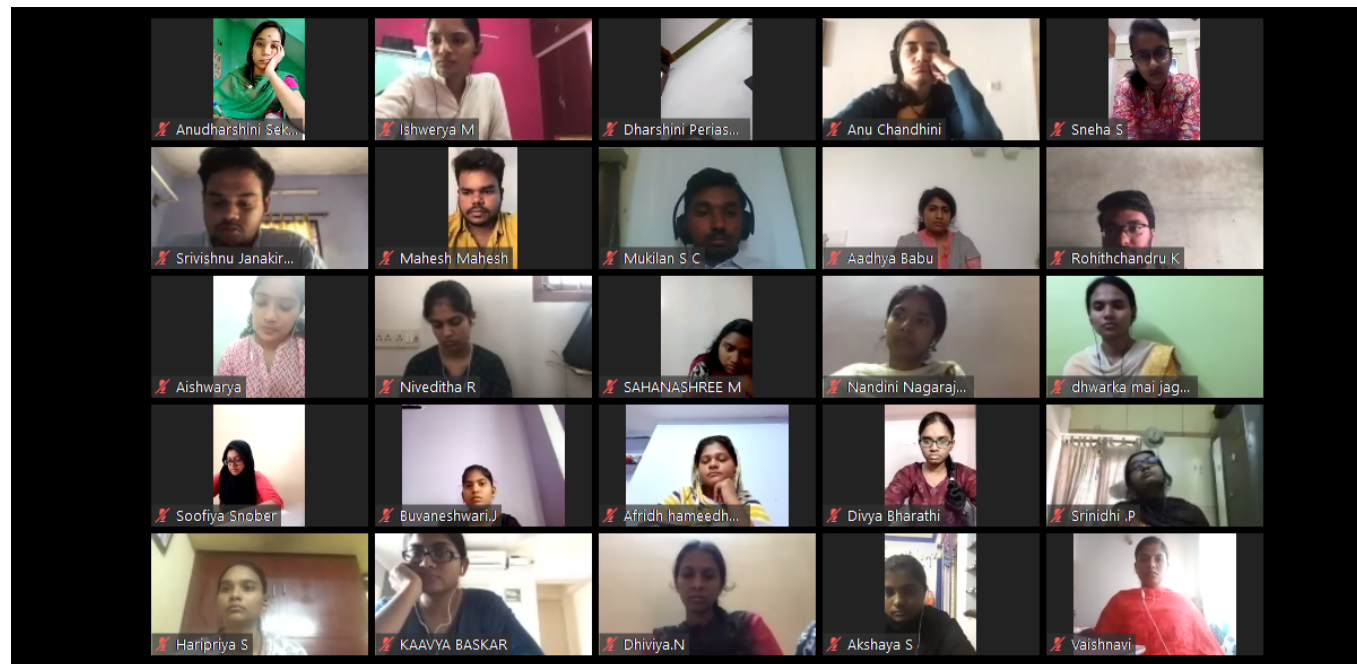
FACULTY: DR. MERLIN JAYARAJ PRESENTATION

PARTICIPANT VIDEO TILES



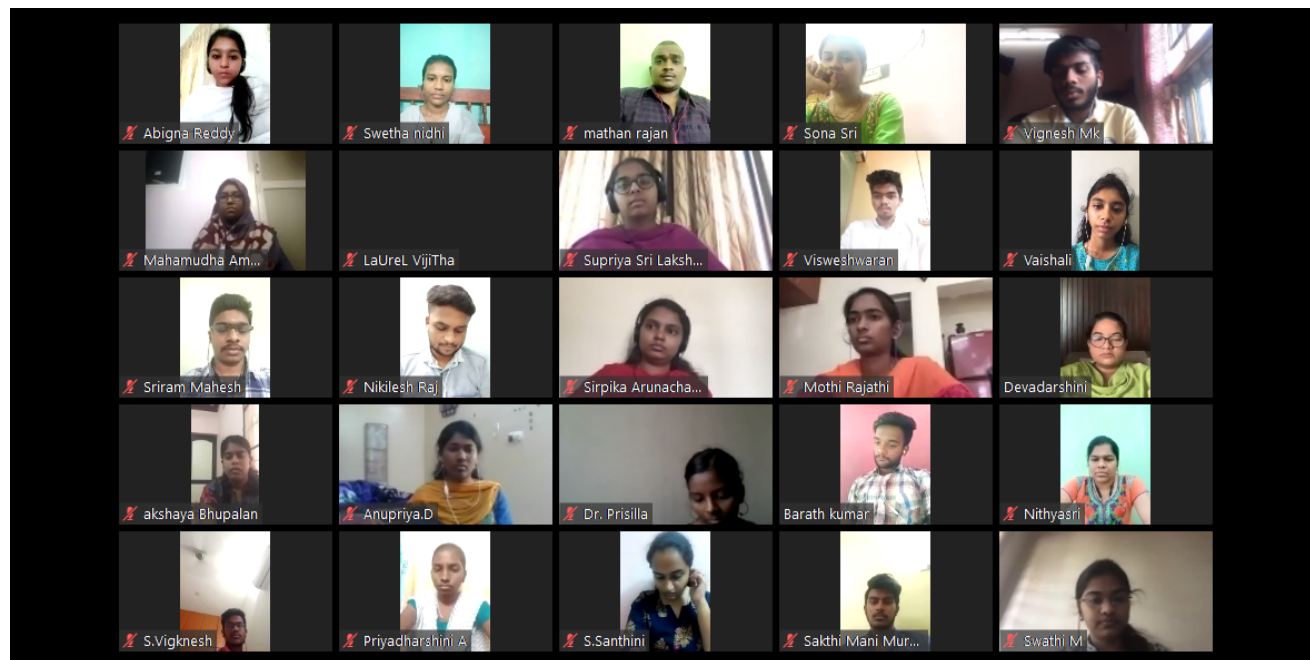
FACULTY: DR. MERLIN JAYARAJ PRESENTATION

PARTICIPANT VIDEO TILES




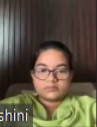




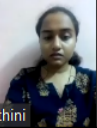


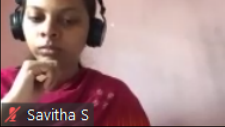

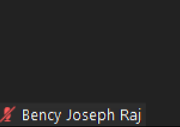
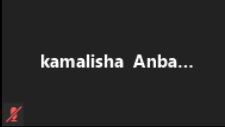

FACULTY: DR. MERLIN JAYARAJ PRESENTATION

PARTICIPANT VIDEO TILES



FACULTY: DR. MERLIN JAYARAJ PRESENTATION

PARTICIPANT VIDEO TILES

 Nikilesh Raj	 Sirpika Arunacha...	 Mothi Rajathi	 Devadarshini	 akshaya Bhupalan
 Anupriya.D	 Dr. Prisilla	 Nithyasri	 S.Vignesh	 Priyadarshini.A
 S.Santhini	 Sakthi Mani Mur...	 Swathi M	 RAKSHA RAMKU...	 Divya Dharshini
 Savitha S	 P.Kowsalya	 Bency Joseph Raj	 kamalisha Anba...	 Suvetha Manoh...
 Pavithra G	 Logeshwari M	 Revanth Kumar	 Kanishka Nandhini	 Saranya Jayashankar

FACULTY: DR. MERLIN JAYARAJ PRESENTATION

PARTICIPANTS ATTENDANCE

Participants (94)

Find a participant

BS	Bavadharini Selvaraj (Me)		
M	Merlin Jayaraj (Host)		
SM	Sathish Muthukumar		
D	Devadarshini		
AB	Aadhya Babu		
AR	Abigna Reddy		
AH	Afridh hameedha.M		
A	Aishwarya		
	akshaya Bhupalan		
AS	Akshaya S		
AM	Amira Moosa		
AC	Anu Chandhini		
	Anudharshini Sekar		
A	Anupriya.D		

AN	Anusha Naidu			GS	Gayathri S A		
A	Ashrita				Gokul S		
BK	Barath kumar			G	Gowri Santhakumar		
	Beeula A			HS	Haripriya S		
B	Buvaneshwari.J			IM	Ishwerya M		
P	Chithaluru Pranathi			IS	Iswariya S		
D	Deepthika.B				jaya varsha		
DP	Dharshini Periasamy				Joselin Rosary		
D	Dhiviya.N			KB	KAAYVA BASKAR		
	dhwarka mai jagatheesh			KA	kamalisha Anbarasu		
DB	Divya Bharathi			K	Kanishka Nandhini		
DD	Divya Dharshini			k	Kaviya sampath		
	Dr. Prisilla			KS	Krithigaa Sivaraman		
GN	Gayathri Namadevan			LK	Lakshana K G		



Chettinad
Dental College & Research Institute

FACULTY: DR. MERLIN JAYARAJ PRESENTATION

PARTICIPANTS ATTENDANCE


LV	LaUreL VijiTha		P	P.ABIRAMI		SR	Sriram Mahesh			Sakthi Mani Murugan P	
	Leo Caroline		P	P.Kowsalya		SR	Srividhya Rajesh		SS	Savitha S	
	Logeshwari M			Pavithra G		SJ	Srivishnu Janakiraman		SS	Shanmugavelu S	
MA	Mahamudha Ameerulla			Pavithra Manohar		S	Subhathi.B		SD	Shree devi	
	Mahesh Mahesh			Prackadeesh PG			Supriya Sri Lakshmi			Sirpika Arunachalam	
MT	Manigandan T			Prathosh Krishna		SM	Suvetha Manoharan			Sneha S	
	mathan rajan		PG	Priyadarshini Ganesan		SM	Swathi M		SS	Sona Sri	
MR	Mothi Rajathi		PA	Priyadarshini A		SN	Swetha nidhi		SS	Soofiya Snober	
	Mukilan S C		R	RAKSHA RAMKUMAR		V	Vaishali		SR	Sriharika Raavi	
NN	Nandini Nagarajan		RK	Revanth Kumar		V	Vaishnavi		S	Srinidhi .P	
	Narendhar Sreedhran		RK	Rohithchandru K			Vignesh Mk			Sriram Mahesh	
	Nikilesh Raj		S	S.Santhini		V	Vinitha		SR	Srividhya Rajesh	
NB	Nithyasri B R		S	S.Vignesh		BJ	Bency Joseph Raj		SJ	Srivishnu Janakiraman	
NR	Niveditha R		SM	SAHANASHREE M			Saranya Jayashankar		S	Subhathi.B	

CDCRI/OP/2020/041

11.04.2020

DEPARTMENT OF ORAL PATHOLOGY AND MICROBIOLOGY

RECORD OF e CLASS

PLATFORM	 https://us04web.zoom.us/j/942442047
SESSION	MALIGNANT SALIVARY GLAND NEOPLASM – POLYMORPHOUS LOW-GRADE ADENOCARCINOMA & CARCINOMA EX PLEOMORPHIC ADENOMA
PRESENTING FACULTY	DR. MERLIN JAYARAJ
DATE	11.04.2020
TIMING	08.30 am to 10.30 am
UG PARTICIPANTS	Third BDS (79 Regular Batch And 8 Supplementary Batch) – 87 participants
FACULTY ATTENDED	Dr. R. Sathish Muthukumar

FACULTY: DR. MERLIN JAYARAJ PRESENTATION

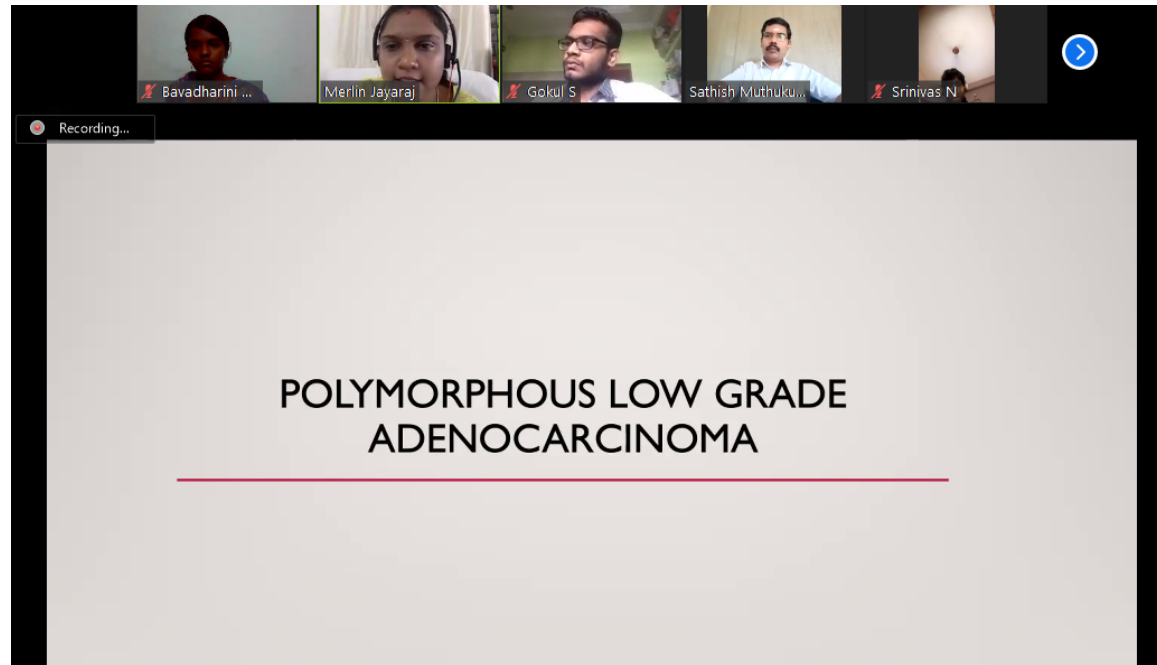
SHARED SCREEN



The screenshot shows a Zoom meeting interface with a presentation slide displayed. The slide is titled "MALIGNANT SALIVARY GLAND NEOPLASMS - 3" and is presented by Dr. Merlin Jayaraj MDS, Senior Lecturer, Department of Oral & Maxillofacial Pathology. The slide also includes the date 11.04.2020. The presentation is titled "MALIGNANT SALIVARY GLAND NEOPLASM 3" and is being shared from a PowerPoint application. The Zoom interface shows several participants in the top bar: Bavadharini, Merlin Jayaraj, Gokul S, Sathish Muthu, and Srinivas N. The presentation slide features the Chettinad Dental College & Research Institute logo and a list of five topics: 1. MALIGNANT SALIVARY GLAND NEOPLASMS - 3, 2. POLYDIPLOID LOW GRADE ADENOCARCINOMA, 3. POLYDIPLOID LOW GRADE ADENOCARCINOMA, 4. POLYDIPLOID LOW GRADE ADENOCARCINOMA, and 5. POLYDIPLOID LOW GRADE ADENOCARCINOMA.

FACULTY: DR. MERLIN JAYARAJ PRESENTATION

SHARED SCREEN



Recording...

**POLYMORPHOUS LOW GRADE
ADENOCARCINOMA**

The image shows a Zoom meeting interface. At the top, there is a row of participant thumbnails. From left to right, the participants are: Bavadharini, Merlin Jayaraj (who is wearing a headset), Gokul S, Sathish Muthuku, and Srinivas N. To the right of these thumbnails is a blue circular button with a white arrow pointing right. Below the thumbnails, there is a small red circle icon followed by the text 'Recording...'. The main part of the screen is a large, light gray rectangle. In the center of this rectangle, the text 'POLYMORPHOUS LOW GRADE ADENOCARCINOMA' is displayed in a bold, black, sans-serif font. A thin red horizontal line is positioned below the text.



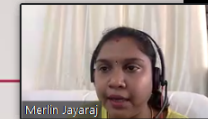
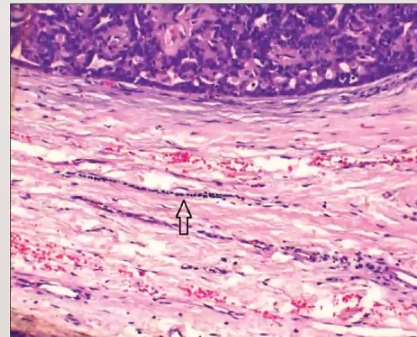
Chettinad
Dental College & Research Institute

FACULTY: DR. MERLIN JAYARAJ PRESENTATION

SHARED SCREEN

POLYMORPHOUS LOW GRADE ADENOCARCINOMA

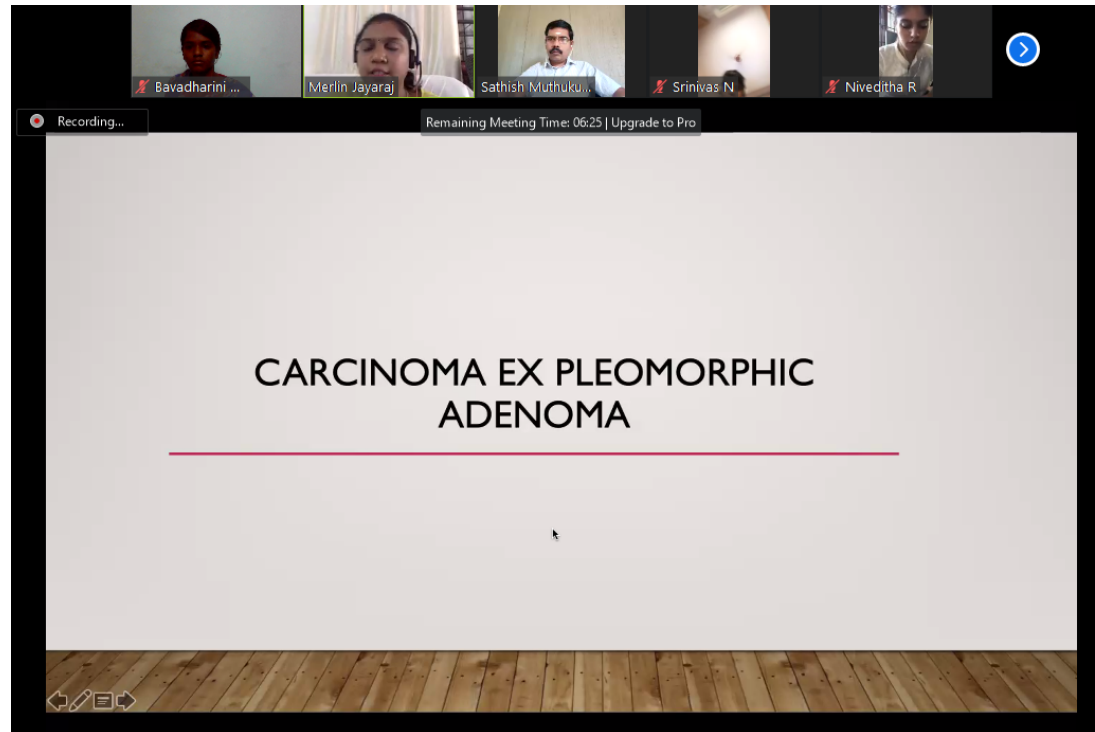
- In areas, usually at the periphery of the tumor, there are cells aligned in single files – SINGLE FILE PATTERN/INDIAN FILE PATTERN



At the tumor periphery, the cells are arranged in a linear, single cell pattern resembling "indian file" or beads on a string pattern of infiltration (H&E stain, $\times 100$)

FACULTY: DR. MERLIN JAYARAJ PRESENTATION

SHARED SCREEN



Recording...

Remaining Meeting Time: 06:25 | Upgrade to Pro

**CARCINOMA EX PLEOMORPHIC
ADENOMA**

Navigation icons: back, forward, search, etc.

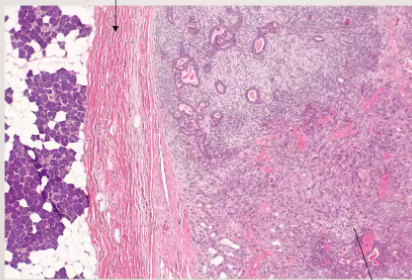
The image shows a Zoom meeting interface. At the top, there are five participant video thumbnails with names: Bavadharini, Merlin Jayaraj, Sathish Muthuku, Srinivas N, and Niveditha R. Below the thumbnails is a status bar with 'Recording...' and 'Remaining Meeting Time: 06:25 | Upgrade to Pro'. The main area is a shared screen displaying a presentation slide with the title 'CARCINOMA EX PLEOMORPHIC ADENOMA' in bold black text, underlined. The bottom of the screen shows a wooden floor texture and navigation icons.

SCREEN IMAGE

FACULTY: DR. MERLIN JAYARAJ PRESENTATION

Recording... Less than 1 minute | Upgrade to Pro

CARCINOMA EX PLEOMORPHIC ADENOMA



The carcinoma component is on the lower right of the image. Benign parotid gland is seen at the left and pleomorphic adenoma is seen at the upper right

Navigation icons: back, forward, search, etc.


SCREEN IMAGE

FACULTY: DR. MERLIN JAYARAJ PRESENTATION

CARCINOMA EX PLEOMORPHIC ADENOMA

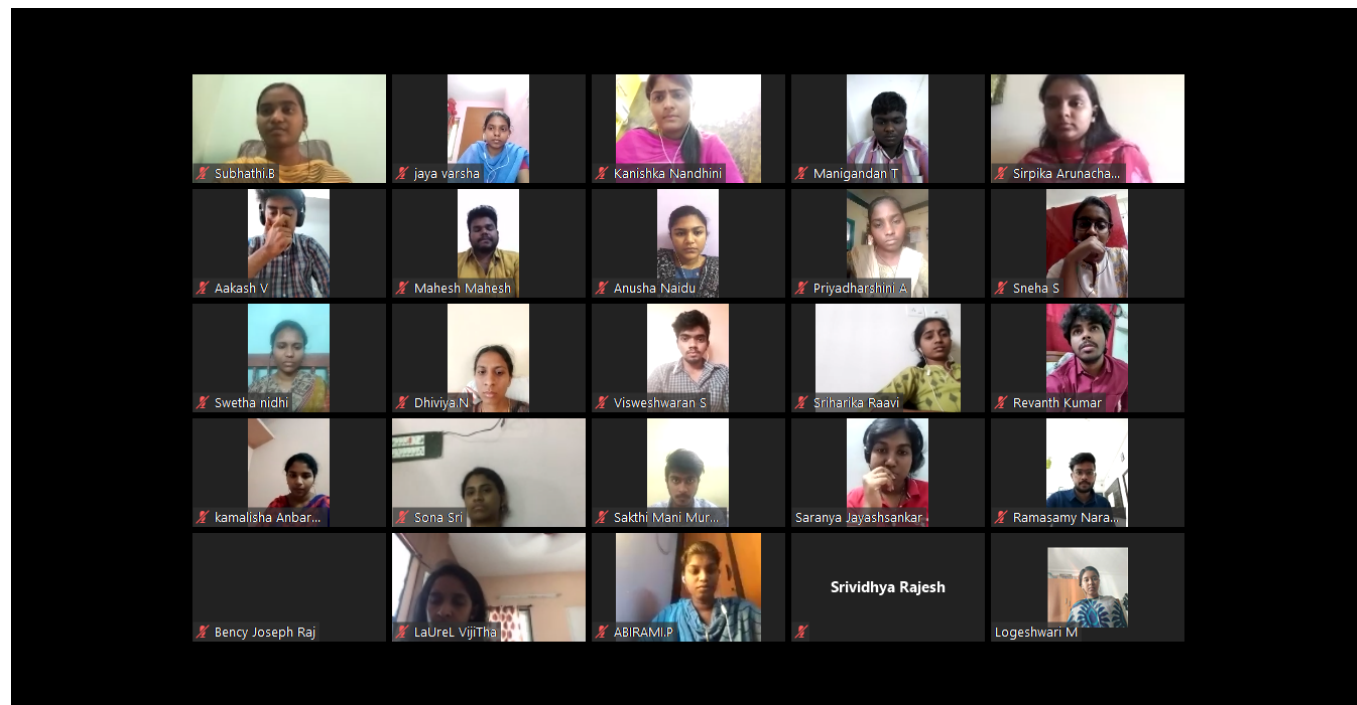
DIFFERENTIAL DIAGNOSIS

- A Ca ex PA can be mistaken for a benign PA.
- It can also be misdiagnosed as other benign and malignant salivary gland tumours.
- Metastatic mixed tumour is less common than Ca ex PA and is differentiated from Ca ex PA by having no carcinomatous component.



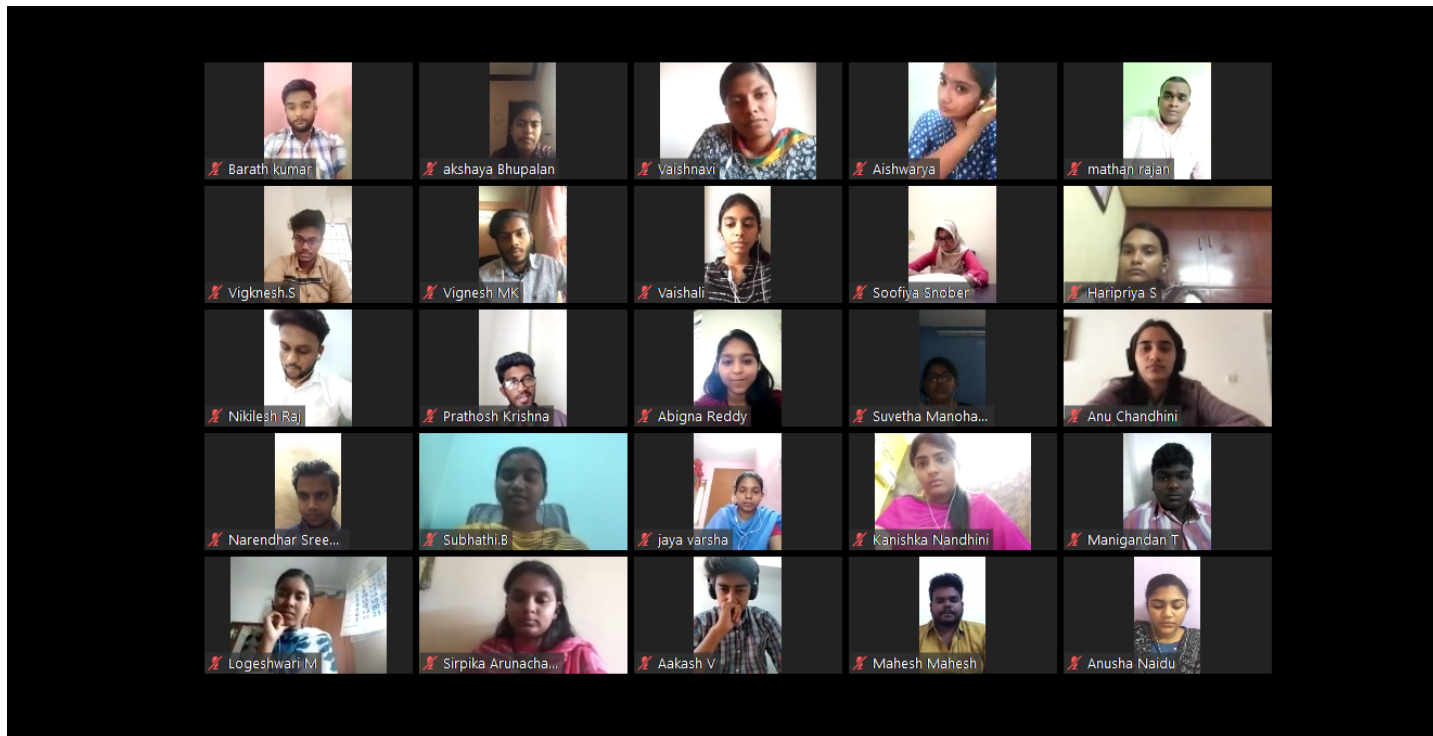
FACULTY: DR. MERLIN JAYARAJ PRESENTATION

PARTICIPANT VIDEO TILES



FACULTY: DR. MERLIN JAYARAJ PRESENTATION

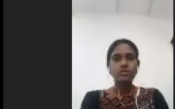


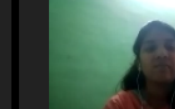

PARTICIPANT VIDEO TILES



FACULTY: DR. MERLIN JAYARAJ PRESENTATION

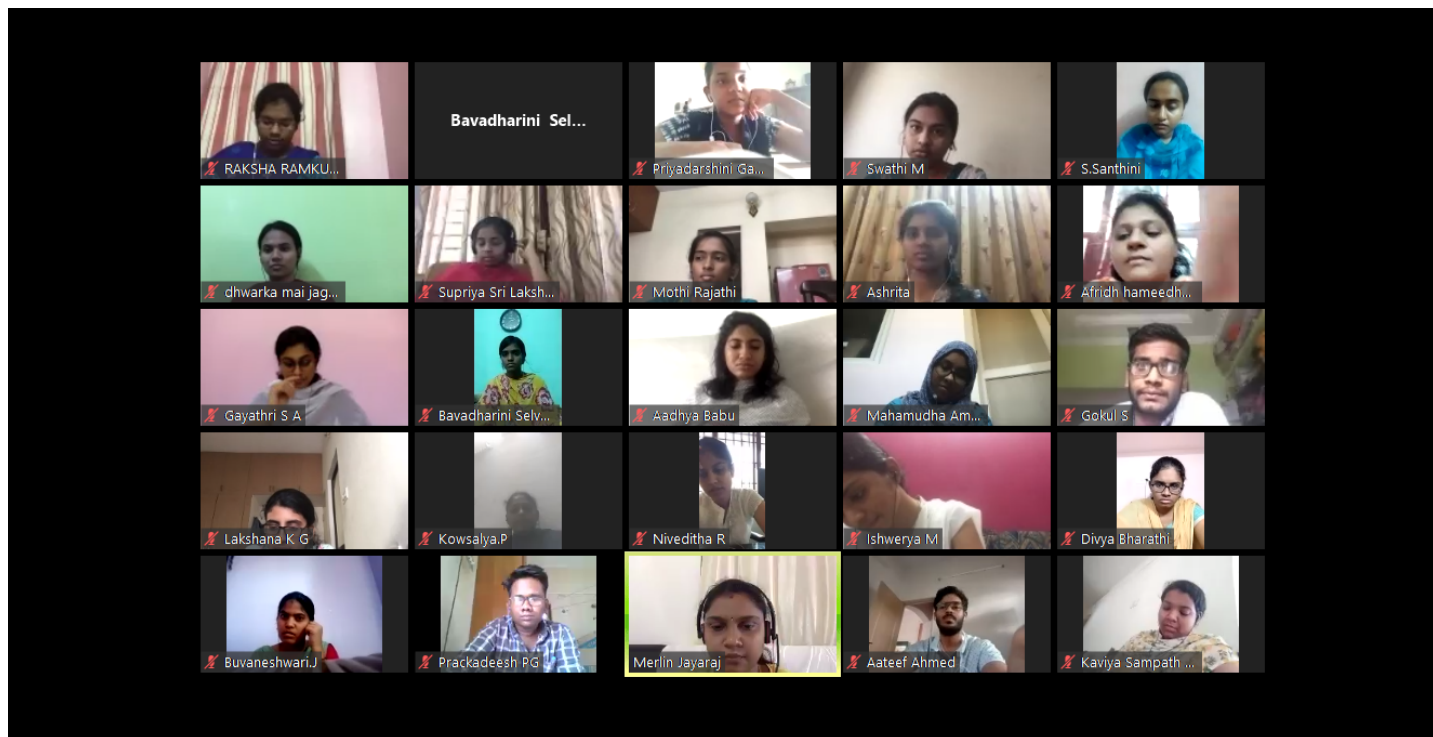
PARTICIPANT VIDEO TILES



 Chithaluru Pranat...	 Mukilan S C	 Joselin Rosary	 Kaviya Sampath ...	 Pavithra G
 SAHANASHREE M	 Savitha S	 Nandini Nagaraj...	 Anudharshini Sek...	 Sriram Mahesh
 Rohithchandru K	 Deepthika.B	 Divya Dharshini	 Nithyasri	 Gayathri Namdev
 Vinitha	 Amira Moosa	 Srivishnu Janakir...	 Kavya Maran	 Shree devi Elang...
 Iswariya S	 KAAVYA BASKAR	 Akshaya S	 Pavithra Manohar	 Barath kumar

FACULTY: DR. MERLIN JAYARAJ PRESENTATION

PARTICIPANT VIDEO TILES





Chettinad
Dental College & Research Institute

FACULTY: DR. MERLIN JAYARAJ PRESENTATION

PARTICIPANTS ATTENDANCE

Participants (98)

Find a participant

BS	Bavadharini Selv... (Host, me)		
MJ	Merlin Jayaraj		
SM	Sathish Muthukumar		
AB	Aadhya Babu		
	Aakash V		
AA	Aateef Ahmed		
	Abigna Reddy		
A	ABIRAMI.P		
AH	Afridh hameedha.M		
A	Aishwarya		
	akshaya Bhupalan		
AS	Akshaya S		
AM	Amira Moosa		
AC	Anu Chandhini		


















	Anudharshini Sekar				Dr. Prisilla		
A	Anupriya.D				Gayathri Namdev		
AN	Anusha Naidu			GS	Gayathri S A		
A	Ashrita				Gogula Krishnan		
BK	Barath kumar				Gokul S		
B	Buvaneshwari.J			g	Gowri Santhakumar		
P	Chithaluru Pranathi			HS	Haripriya S		
D	Devadarshini			IM	Ishwerya M		
DP	Dharshini Periasamy			IS	Iswariya S		
D	Dhiviya.N				jaya varsha		
	dhwarka mai jagatheesh				Joselin Rosary		
DB	Divya Bharathi			KB	KAAYYA BASKAR		
DD	Divya Dharshini			KA	kamalisha Anbarasu		
	Dr. Prisilla				Kanishka Nandhini		



Chettinad
Dental College & Research Institute

FACULTY: DR. MERLIN JAYARAJ PRESENTATION

PARTICIPANTS ATTENDANCE

KS Kaviya Sampath Kumar	/ <input type="checkbox"/>	NN Nandini Nagarajan	/ <input type="checkbox"/>	RK Revanth Kumar	/ <input type="checkbox"/>
KM Kavya Maran	/ <input checked="" type="checkbox"/>	 Narendhar Sreedharan	/ <input type="checkbox"/>	RK Rohithchandru K	/ <input type="checkbox"/>
K Kowsalya.P	/ <input type="checkbox"/>	 Nikilesh Raj	/ <input type="checkbox"/>	S S.Santhini	/ <input type="checkbox"/>
KS Krithigaa Sivaraman	/ <input type="checkbox"/>	N Nithyasri	/ <input type="checkbox"/>	SM SAHANASHREE M	/ <input type="checkbox"/>
LK Lakshana K G	/ <input type="checkbox"/>	NR Niveditha R	/ <input type="checkbox"/>	 Sakthi Mani Murugan P	/ <input type="checkbox"/>
LV LaUreL VijiTha	/ <input type="checkbox"/>	 Pavithra G	/ <input type="checkbox"/>	SS Savitha S	/ <input type="checkbox"/>
 Leo Caroline	/ <input type="checkbox"/>	 Pavithra Manohar	/ <input type="checkbox"/>	 Shanmugavelu S	/ <input type="checkbox"/>
 Logeshwari M	/ <input type="checkbox"/>	 Prackadeesh PG	/ <input checked="" type="checkbox"/>	 Shree devi Elangovan	/ <input type="checkbox"/>
MA Mahamudha Ameerulla	/ <input type="checkbox"/>	 Prackadeesh PG	/ <input type="checkbox"/>	 Sirpika Arunachalam	/ <input type="checkbox"/>
 Mahesh Mahesh	/ <input type="checkbox"/>	 Prathosh Krishna	/ <input type="checkbox"/>	 Sneha S	/ <input type="checkbox"/>
MT Manigandan T	/ <input type="checkbox"/>	PG Priyadarshini Ganesan	/ <input type="checkbox"/>	SS Sona Sri	/ <input type="checkbox"/>
 mathan rajan	/ <input type="checkbox"/>	PA Priyadharshini A	/ <input type="checkbox"/>	SS Soofiya Snober	/ <input type="checkbox"/>
MR Mothi Rajathi	/ <input type="checkbox"/>	R RAKSHA RAMKUMAR	/ <input type="checkbox"/>	SR Sriharika Raavi	/ <input checked="" type="checkbox"/>
MS Mukilan S C	/ <input type="checkbox"/>	 Ramasamy Narayanan	/ <input type="checkbox"/>	S. Srinidhi .P	/ <input type="checkbox"/>



Chettinad
Dental College & Research Institute

FACULTY: DR. MERLIN JAYARAJ PRESENTATION

PARTICIPANTS ATTENDANCE


 SN	Srinivas N	/	<input type="checkbox"/>
	Sriram Mahesh	/	<input type="checkbox"/>
 SR	Srividhya Rajesh	/	<input type="checkbox"/>
	Srivishnu Janakiraman	/	<input type="checkbox"/>
 S	Subhathi.B	/	<input type="checkbox"/>
 SS	Supriya Sri Lakshmi	/	<input type="checkbox"/>
 SM	Suvetha Manoharan	/	<input type="checkbox"/>
 SM	Swathi M	/	<input type="checkbox"/>
 SN	Swetha nidhi	/	<input type="checkbox"/>
 V	Vaishali	/	<input type="checkbox"/>
 V	Vaishnavi	/	<input type="checkbox"/>
 V	Vigknes.S	/	<input type="checkbox"/>
	Vignesh Mk	/	<input type="checkbox"/>
 V	Vinitha	/	<input type="checkbox"/>
	Visweshwaran S	/	<input checked="" type="checkbox"/>

CDCRI/OP/2020/041

11.04.2020

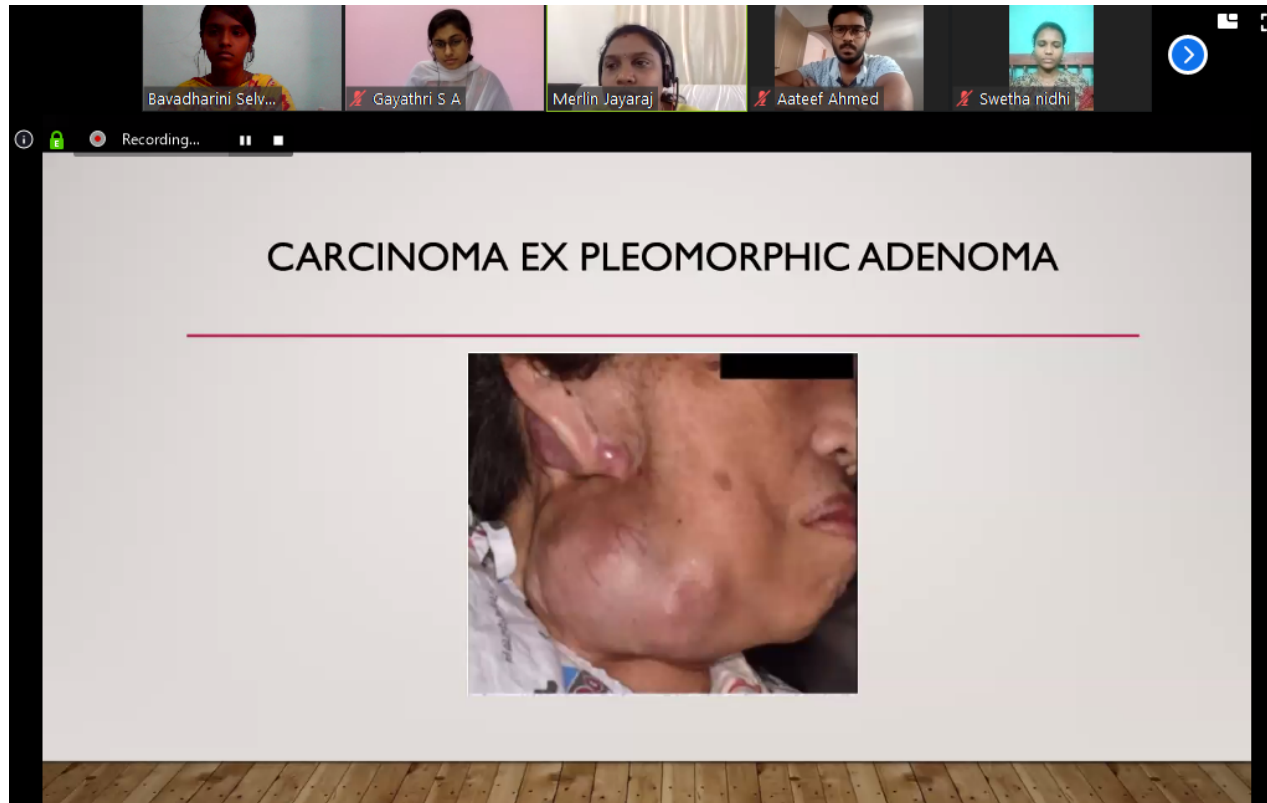
DEPARTMENT OF ORAL PATHOLOGY AND MICROBIOLOGY

RECORD OF e CLASS

PLATFORM	 https://us04web.zoom.us/j/942442047
SESSION	WEBINAR - MALIGNANT SALIVARY GLAND NEOPLASM -- ACINIC CELL CARCINOMA
PRESENTING FACULTY	Dr. MERLIN JAYARAJ
DATE	11.04.2020
TIMING	02.00 pm to 03.30 pm
UG PARTICIPANTS	Third BDS (81 Regular Batch and 9 Supplementary Batch) – 90 participants

FACULTY: DR. MERLIN JAYARAJ PRESENTATION

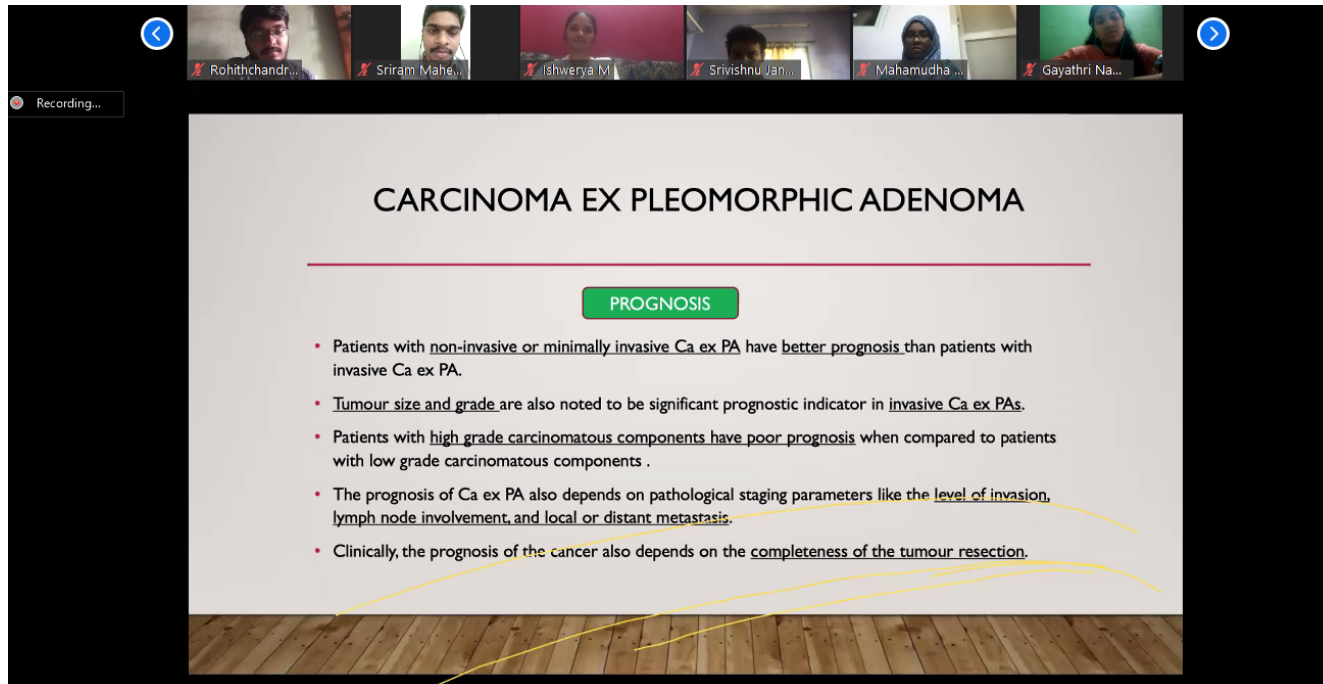
SHARED SCREEN



The image shows a Zoom meeting interface. At the top, there is a row of five participant video thumbnails with their names below them: Bavadharini Selv..., Gayathri S A, Merlin Jayaraj, Aateef Ahmed, and Swetha nidhi. Below the thumbnails is a status bar with icons for mute, video, chat, and a 'Recording...' indicator. The main area of the screen is a shared presentation slide. The slide has a light gray background and the title 'CARCINOMA EX PLEOMORPHIC ADENOMA' in bold black text. Below the title is a horizontal pink line. Underneath the line is a clinical photograph of a person's face, showing a large, rounded, reddish-pink mass on the lower cheek and jaw area. The bottom of the Zoom window shows a wooden floor texture.

FACULTY: DR. MERLIN JAYARAJ PRESENTATION

SHARED SCREEN



Recording...

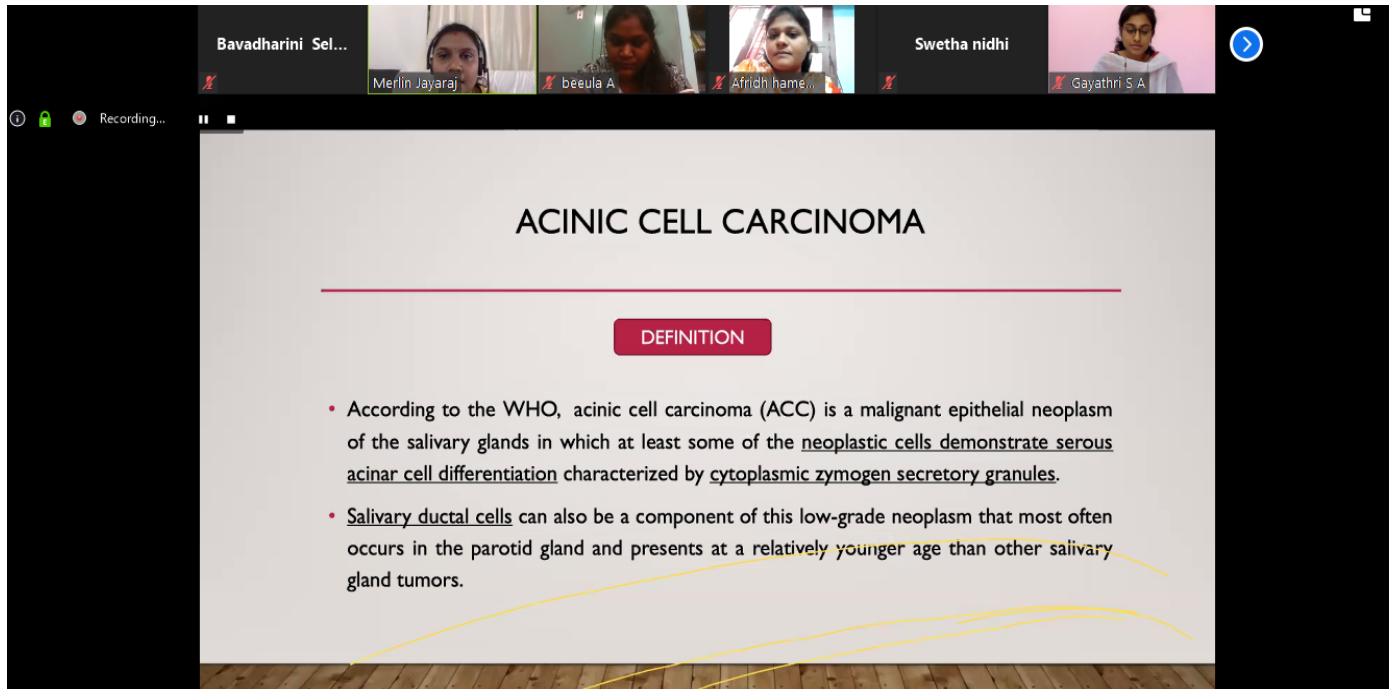
CARCINOMA EX PLEOMORPHIC ADENOMA

PROGNOSIS

- Patients with non-invasive or minimally invasive Ca ex PA have better prognosis than patients with invasive Ca ex PA.
- Tumour size and grade are also noted to be significant prognostic indicator in invasive Ca ex PAs.
- Patients with high grade carcinomatous components have poor prognosis when compared to patients with low grade carcinomatous components .
- The prognosis of Ca ex PA also depends on pathological staging parameters like the level of invasion, lymph node involvement, and local or distant metastasis.
- Clinically, the prognosis of the cancer also depends on the completeness of the tumour resection.

FACULTY: DR. MERLIN JAYARAJ PRESENTATION

SHARED SCREEN



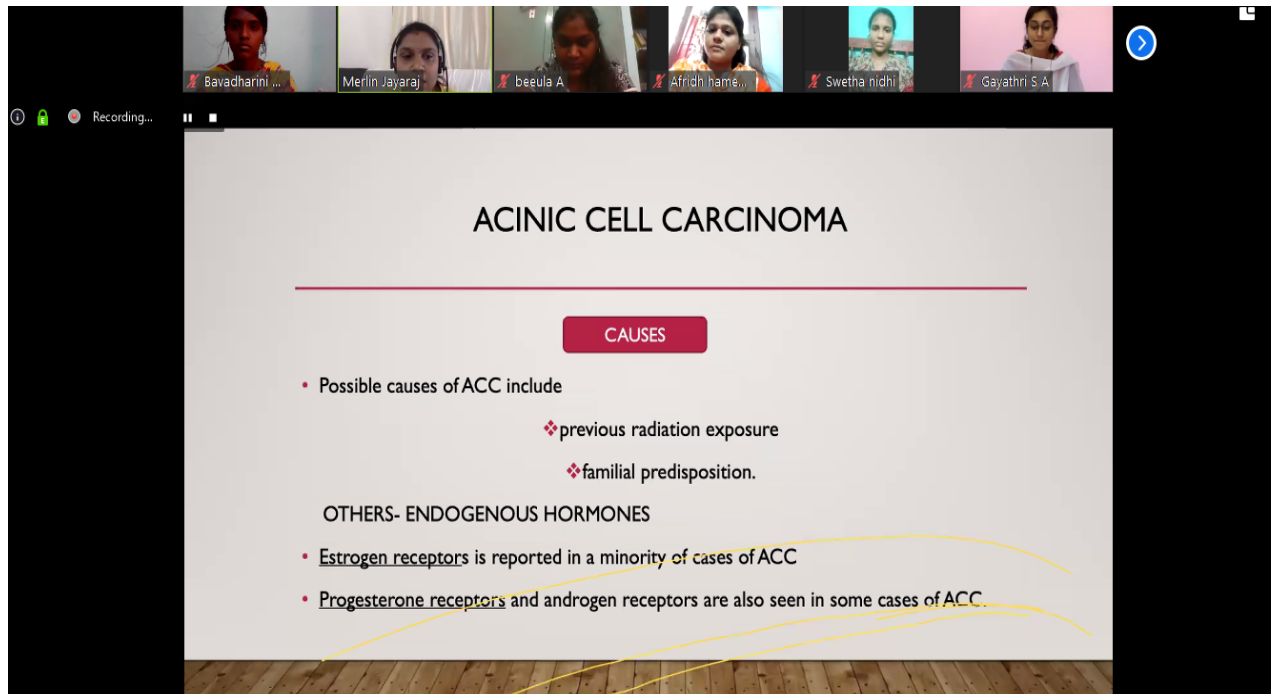
The image shows a Zoom meeting interface. At the top, there is a video gallery with five participants: Bavadharini Sel..., Merlin Jayaraj, beeula A, Afridi hame..., Swetha nidhi, and Gayathri S A. Below the gallery, the main screen displays a presentation slide titled "ACINIC CELL CARCINOMA". The slide has a pink header bar with the word "DEFINITION" in white. The content of the slide is as follows:

- According to the WHO, acinic cell carcinoma (ACC) is a malignant epithelial neoplasm of the salivary glands in which at least some of the neoplastic cells demonstrate serous acinar cell differentiation characterized by cytoplasmic zymogen secretory granules.
- Salivary ductal cells can also be a component of this low-grade neoplasm that most often occurs in the parotid gland and presents at a relatively younger age than other salivary gland tumors.

There are yellow handwritten lines at the bottom of the slide.

FACULTY: DR. MERLIN JAYARAJ PRESENTATION

SHARED SCREEN



Recording...

ACINIC CELL CARCINOMA

CAUSES

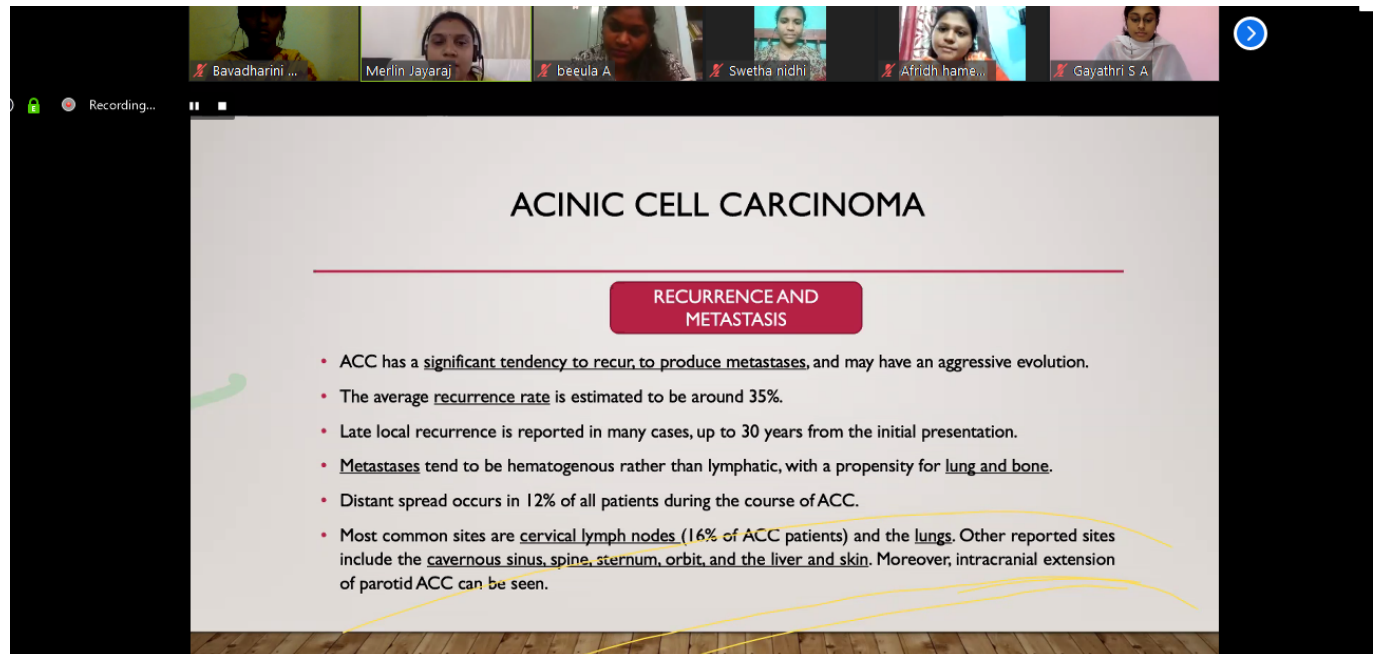
- Possible causes of ACC include
 - ❖ previous radiation exposure
 - ❖ familial predisposition.

OTHERS- ENDOGENOUS HORMONES

- Estrogen receptors is reported in a minority of cases of ACC
- Progesterone receptors and androgen receptors are also seen in some cases of ACC.

FACULTY: DR. MERLIN JAYARAJ PRESENTATION

SHARED SCREEN



Recording...

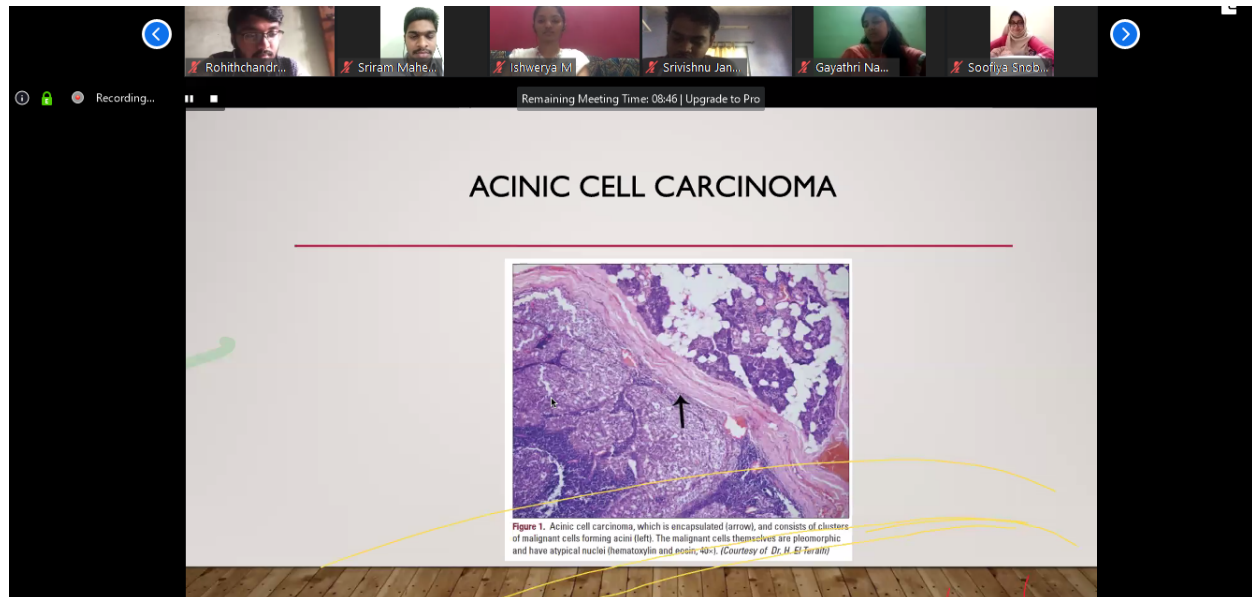
ACINIC CELL CARCINOMA

RECURRENCE AND METASTASIS

- ACC has a significant tendency to recur, to produce metastases, and may have an aggressive evolution.
- The average recurrence rate is estimated to be around 35%.
- Late local recurrence is reported in many cases, up to 30 years from the initial presentation.
- Metastases tend to be hematogenous rather than lymphatic, with a propensity for lung and bone.
- Distant spread occurs in 12% of all patients during the course of ACC.
- Most common sites are cervical lymph nodes (16% of ACC patients) and the lungs. Other reported sites include the cavernous sinus, spine, sternum, orbit, and the liver and skin. Moreover, intracranial extension of parotid ACC can be seen.

FACULTY: DR. MERLIN JAYARAJ PRESENTATION

SHARED SCREEN



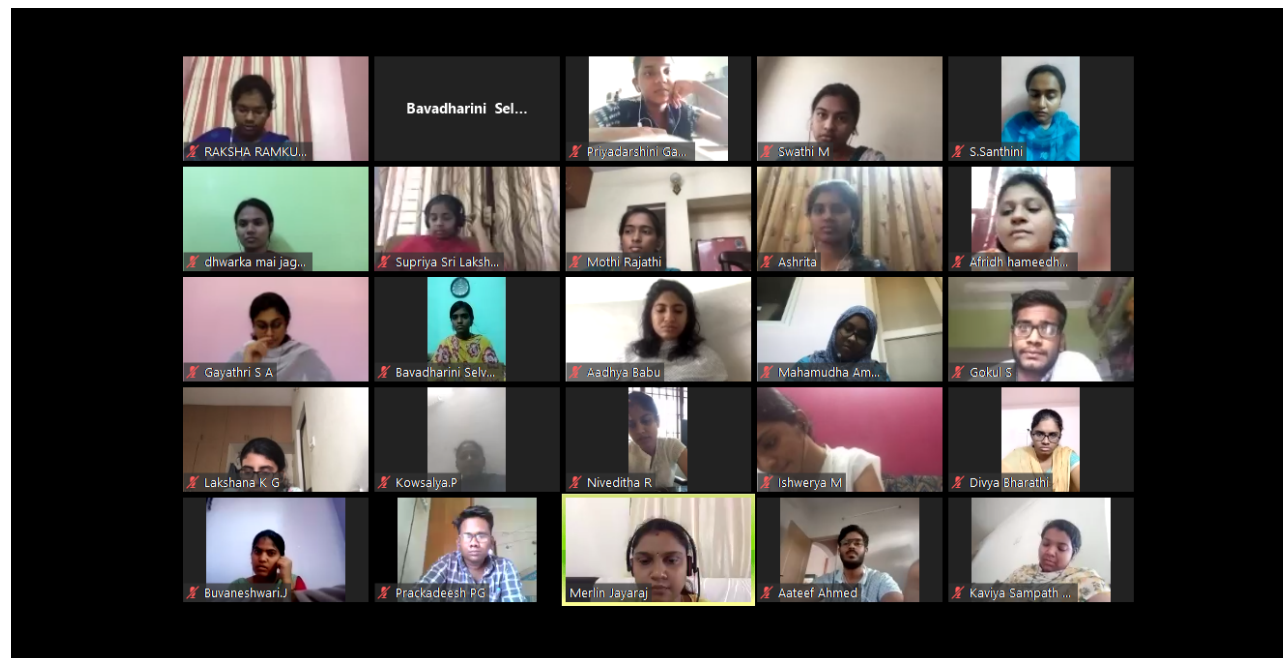
The image shows a Zoom meeting interface. At the top, there is a row of participant video thumbnails with names: Rohithchandr..., Sriram Mahe..., Ishwerya M..., Srivishnu Jan..., Gayathri Na..., and Soofiya Shobi... Below the thumbnails, a status bar indicates 'Remaining Meeting Time: 08:46 | Upgrade to Pro'. The main screen displays a presentation slide titled 'ACINIC CELL CARCINOMA'. The slide features a histological image of a tissue section. A black arrow points to a cluster of cells, and a red line is drawn across the slide. Below the image, there is a caption: 'Figure 1. Acinic cell carcinoma, which is encapsulated (arrow), and consists of clusters of malignant cells forming acini (left). The malignant cells themselves are pleomorphic and have atypical nuclei (hematoxylin and eosin, 40x). [Courtesy of Dr. H. B. Terrell]'

ACINIC CELL CARCINOMA

Figure 1. Acinic cell carcinoma, which is encapsulated (arrow), and consists of clusters of malignant cells forming acini (left). The malignant cells themselves are pleomorphic and have atypical nuclei (hematoxylin and eosin, 40x). [Courtesy of Dr. H. B. Terrell]

FACULTY: DR. MERLIN JAYARAJ PRESENTATION

PARTICIPANT VIDEO TILES



FACULTY: DR. MERLIN JAYARAJ PRESENTATION

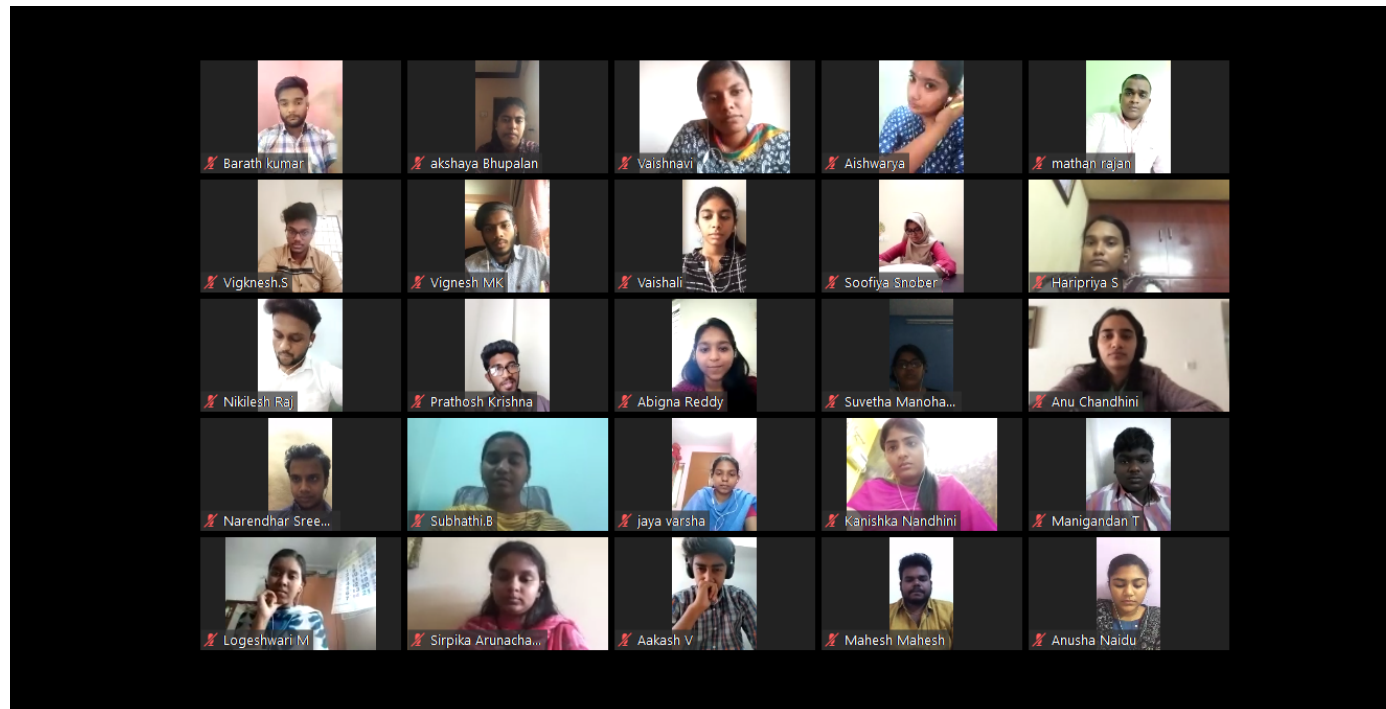
PARTICIPANT VIDEO TILES



 Chithaluru Pranat...	 Mukilan S C	 Joselin Rosary	 Kaviya Sampath ...	 Pavithra G
 SAHANASHREE M	 Savitha S	 Nandini Nagaraj...	 Anudharshini Sek...	 Sriram Mahesh
 Rohithchandru K	 Deepthika.B	 Divya Dharshini	 Nithyasri	 Gayathri Namdev
 Vinitha	 Amira Moosa	 Srivishnu Janakir...	 Kavya Maran	 Shree devi Elang...
 Iswariya S	 KAAVYA BASKAR	 Akshaya S	 Pavithra Manohar	 Barath kumar

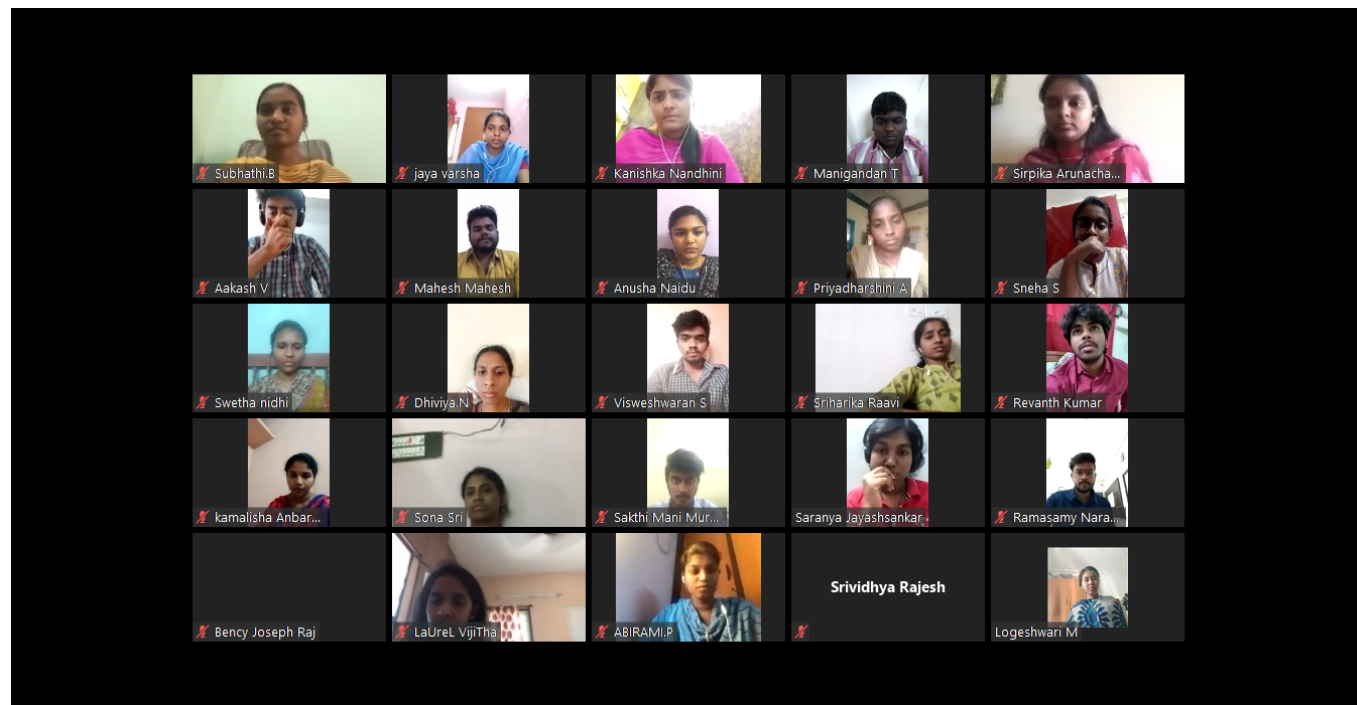
FACULTY: DR. MERLIN JAYARAJ PRESENTATION

PARTICIPANT VIDEO TILES



FACULTY: DR. MERLIN JAYARAJ PRESENTATION

PARTICIPANT VIDEO TILES



FACULTY: DR. MERLIN JAYARAJ PRESENTATION

PARTICIPANTS ATTENDANCE

Participants (100)

Find a participant

MJ

Merlin Jayaraj

BA

beeula A

AB

Aadhya Babu

Aakash V

AA

Aateef Ahmed

Abigna Reddy

A

ABIRAMI.P

AH

Afridh hameedha.M

A

Aishwarya

akshaya Bhupalan

AS

Akshaya S

AM

Amira Moosa

AS

Anudharshini Sekar

A

Anupriya.D

A

Ashrita

BK

Barath kumar

BA

beeula A

BJ

Bency Joseph Raj

B

Buvaneshwari.J

P

Chithaluru Pranathi

D

Deepthika.B

D

Devadarshini

Dharshini Periasamy

D

Dhiviya.N

DM

dhwarka mai jagatheesh

DB

Divya Bharathi

DD

Divya Dharshini

Dr. Prisilla

Gayathri Namdev

GS

Gayathri S A

Gogula Krishnan

Gokul S

g

Gowri Santhakumar

HS

Haripriya S

IM

Ishwerya M

IS

Iswariya S

jaya varsha

Joselin Rosary

KB

KAAVYA BASKAR

KA

kamalisha Anbarasu





















































































Kanishka Nandhini

KS

Kaviya Sampath Kumar

















FACULTY: DR. MERLIN JAYARAJ PRESENTATION

PARTICIPANTS ATTENDANCE

 S.Santhini		 Nikilesh Raj		 Kowsalya.P	
 SAHANASHREE M		 Nithyasri		 Krithigaa Sivaraman	
 Sakthi Mani Murugan P		 Niveditha R		 Lakshana K G	
 Savitha S		 Pavithra G		 LaUreL VijiTha	
 Shanmugavelu S		 Pavithra Manohar		 Leo Caroline	
 Shree devi Elangovan		 Prackadeesh PG		 Logeshwari M	
 Sirpika Arunachalam		 Prathosh Krishna		 Mahamudha Ameerulla	
 Sneha S		 Priyadarshini Ganesan		 Mahesh Mahesh	
 sonashree105@gmail.com		 Priyadarshini A		 Manigandan T	
 Soofiya Snober		 RAKSHA RAMKUMAR		 mathan rajan	
 Sriharika Raavi		 Ramasamy Narayanan		 Mothi Rajathi	
 Srinidhi .P		 Revanth Kumar		 Mukilan S C	
 Sriram Mahesh		 Rohithchandru K		 Nandini Nagarajan	
 Srividhya Rajesh		 S.Santhini		 Narendhar Sreedhran	

FACULTY: DR. MERLIN JAYARAJ PRESENTATION

PARTICIPANTS ATTENDANCE

	Srivishnu Janakiraman	/ <input type="checkbox"/>
	Subhathi.B	/ <input type="checkbox"/>
	Supriya Sri Lakshmi	/ <input checked="" type="checkbox"/>
	Supriya Sri Lakshmi	/ <input checked="" type="checkbox"/>
	Suvetha Manoharan	/ <input type="checkbox"/>
	Swathi M	/ <input type="checkbox"/>
	Swetha nidhi	/ <input type="checkbox"/>
	Vaishali	/ <input type="checkbox"/>
	Vaishnavi	/ <input type="checkbox"/>
	Vigknes.h	/ <input type="checkbox"/>
	Vignesh Mk	/ <input type="checkbox"/>
	Vinitha	/ <input type="checkbox"/>
	Visweshwaran S	/ <input checked="" type="checkbox"/>
	Anu Chandhini	<input type="checkbox"/>
	Haripriya S	<input checked="" type="checkbox"/>
	Saranya Jayashsankar	<input checked="" type="checkbox"/>