



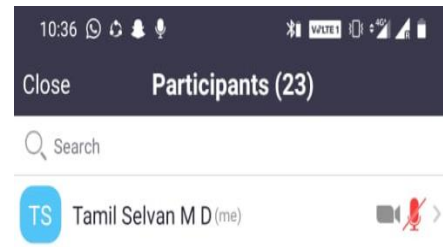
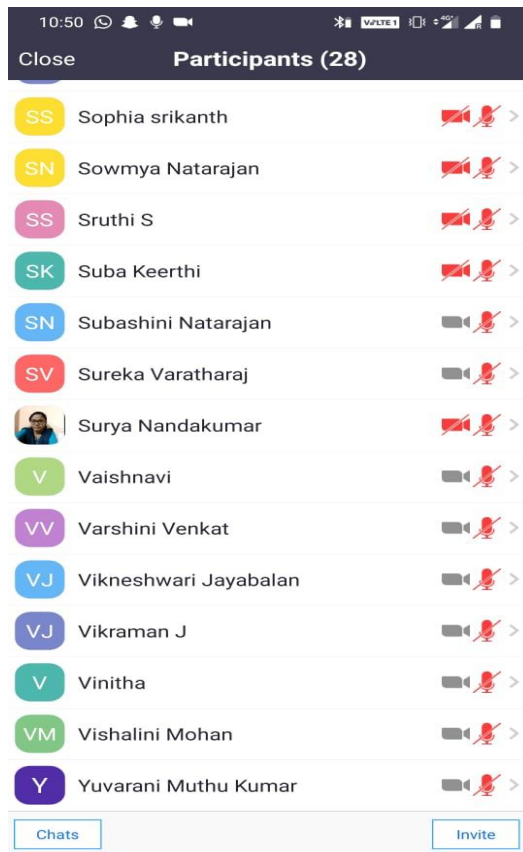
Chettinad
Dental College & Research Institute

E – Teaching/Learning Sessions for 4th year BDS
Department of ORAL AND MAXILLOFACIAL SURGERY

s.no	DATE	LECTURE TOPIC	FACULTY	PARTICIPATED STUDENTS
1	31-3-20	STEROIDS (CLINICAL POSTING)	DR.Rajesh,Dr.Alagappan	13
2	1-4-20	Anticoagulants and antiplatelets in dentistry (THEORY CLASS)	DR.Rajesh,Dr.Alagappan, DR.Semmia DR.Ramya, DR.Neethu	81
3	1-4-20	REGENERATIVE MAXILLOFACIAL SURGERY-CLINICAL POSTING	Dr. Rajesh Dr. Alagappan Dr. Semmia Dr. Ramya Dr. Neetha abhraham	13
4	2-4-20	IMPACTION (THEORY CLASS)	Dr. Rajesh Dr. Alagappan Dr. Semmia Dr. Eshwari Dr. Sheik sameerudin Dr. Shubra Dr. Ramya Dr. Neetha abhraham	98
5	2-4-20	OESEIOINTEGRATION (CLINICAL POSTING)	DR.Rajesh,Dr.Alagappan, DR.Semmia DR.Ramya, DR.Neethu	13

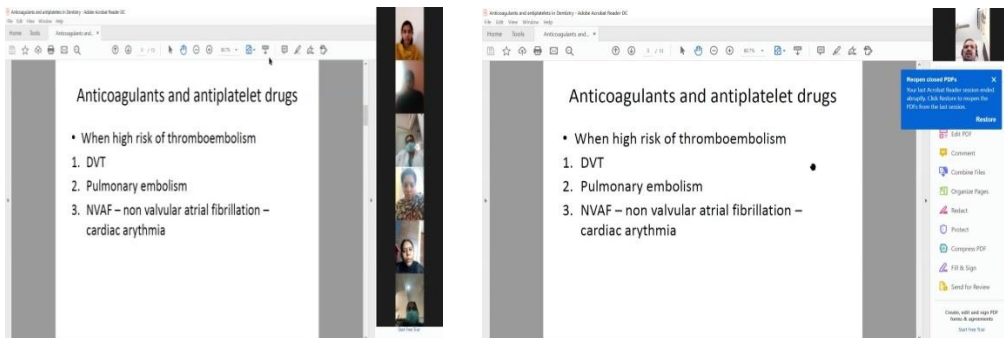
6	2-4-20	DIABETES- CLINICAL POSTING	DR.Rajesh,Dr.Alagappan, DR.Semmia DR.Ramya, DR.Neethu	13
7	3-4-20	TMJ AND ITS DISORDERS (CLINICAL POSTING)	DR.Rajesh,Dr.Alagappan, DR.Semmia DR.Ramya, DR.Neethu	13
8	4-4-20	Use ultrasoinc activated resorable sheets and pins for the management of condylar neck fracture –case series(CLINICAL POSTING)	DR.Rajesh,Dr.Alagappan, DR.Semmia,DR.Ramya, DR.Neethu	13
9	4-4-20	CASE DISCUSSION- BSSO,GENIOPL ASTY,MALAR AUGMENTATIO N (CLINICAL POSTING)	DR.Rajesh,Dr.Alagappan, DR.Semmia,DR.Ramya, DR.Neethu	13

31-3-20

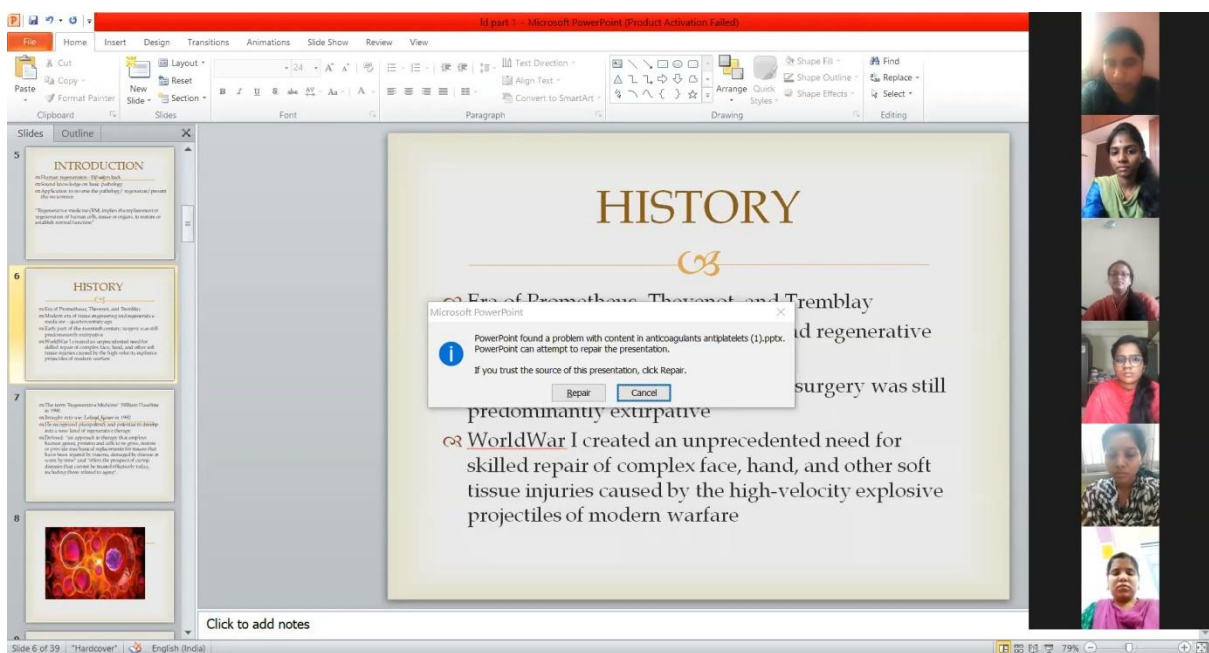


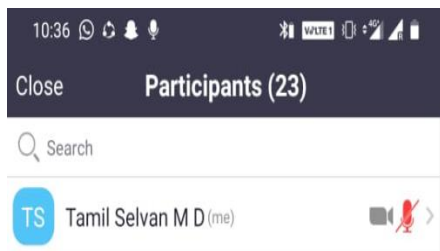
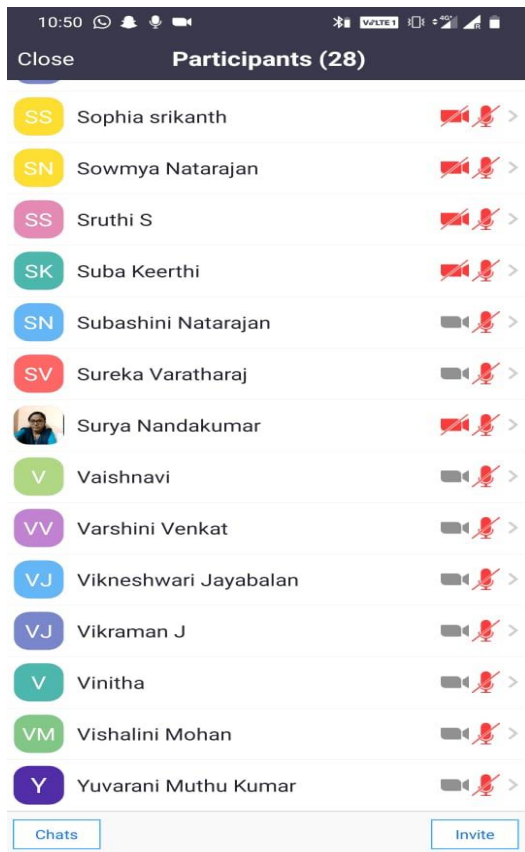
E – Teaching/Learning Sessions for 4th year BDS
Department of ORAL AND MAXILLOFACIAL SURGERY

1-04-2020- THEORY CLASS



1-4-20-PRACTICAL CLASS





E – Teaching/Learning Sessions for 4th year BDS
Department of ORAL AND MAXILLOFACIAL SURGERY

2-04-2020 -THEORY CLASS

28.Impaction_2 - Google Slides

docs.google.com/presentation/d/1TGdo1fjyNtE-90T8L80Xy6fEO4QDKQxpw_a7dJkFUed#slide=id.p23

Search the menus (Alt+/)

18

19

20

21

22

Click to add title

FACTORS COMPLICATING THE REMOVAL OF IMPACTED MANDIBULAR THIRD MOLAR

- 1. Abnormal root curvature.
- 2. Hypercementosis.
- 3. Proximity to the mandibular canal.
- 4. Extreme bone density, especially on elderly patients.
- 5. Follicular space filled with bone, most frequently seen in over 25 years of age.
- 6. Ankylosis.
- 7. Difficult access to the operative field because of
 - a. Small orbicularis oris muscle.
 - b. Inability to open the mouth wide enough.
 - c. A large and Uncontrollable tongue.

Click to add speaker notes

2-4-20-CLINICAL POSTING

Definition:

Direct structural and functional connection between ordered living bone and surface carrying implant.

Definition:

Direct structural and functional connection between ordered living bone and surface carrying implant.

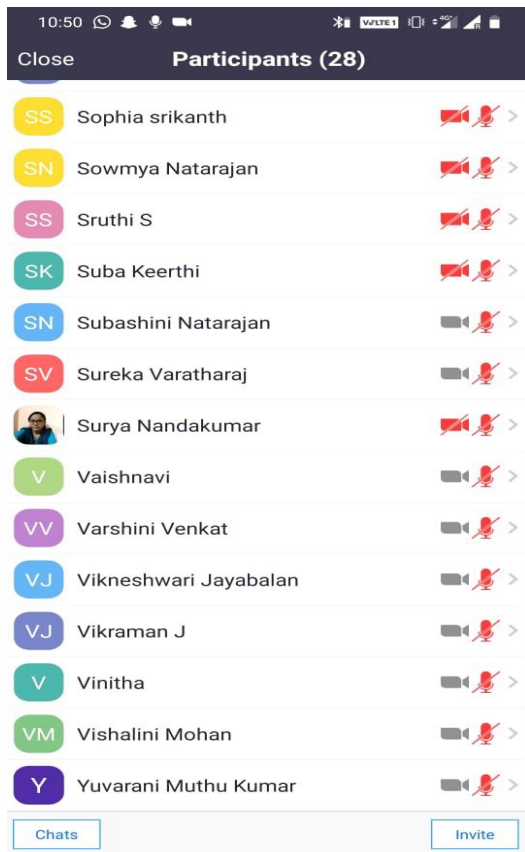
10:36

Close

Participants (23)

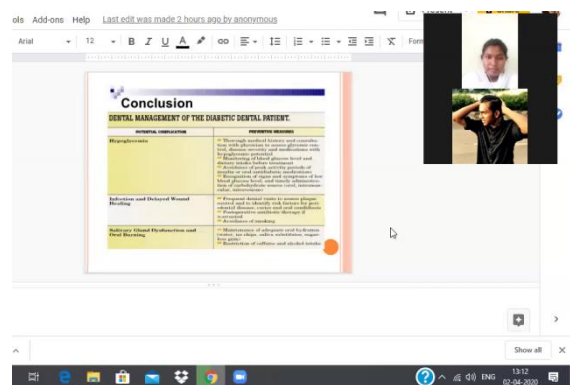
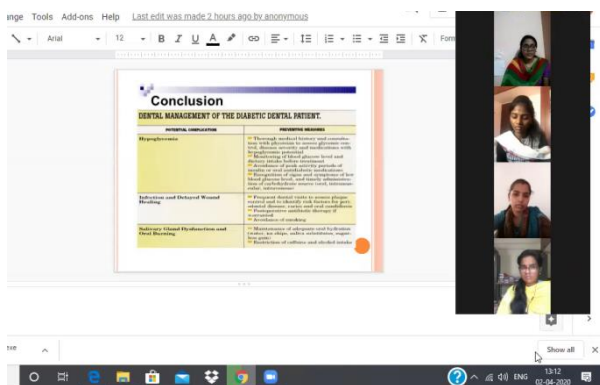
Search

TS Tamil Selvan M D (me)



E – Teaching/Learning Sessions for 4th year BDS Department of ORAL AND MAXILLOFACIAL SURGERY

2-4-2020



10:36

Close Participants (23)

Search

TS Tamil Selvan M D (me)

Conclusion

DENTAL MANAGEMENT OF THE DIABETIC DENTAL PATIENT.

POTENTIAL COMPLICATION	POTENTIAL REASON
Hypoglycaemia	<ul style="list-style-type: none"> Too much insulin given, oral glucose not taken or taken late Too much insulin given, oral glucose not taken or taken late Too much insulin given, oral glucose not taken or taken late
Infection and Delayed Wound Healing	<ul style="list-style-type: none"> High blood glucose levels High blood glucose levels High blood glucose levels
Salivary Gland Dysfunction and Oral Burning	<ul style="list-style-type: none"> High blood glucose levels High blood glucose levels High blood glucose levels

10:50

Close Participants (28)

SS Sophia srikanth

SN Sowmya Natarajan

SS Sruthi S

SK Suba Keerthi

SN Subashini Natarajan

SV Sureka Varatharaj

Surya Nandakumar

V Vaishnavi

VV Varshini Venkat

VJ Vikneshwari Jayabalan

VJ Vikraman J

V Vinitha

VM Vishalini Mohan

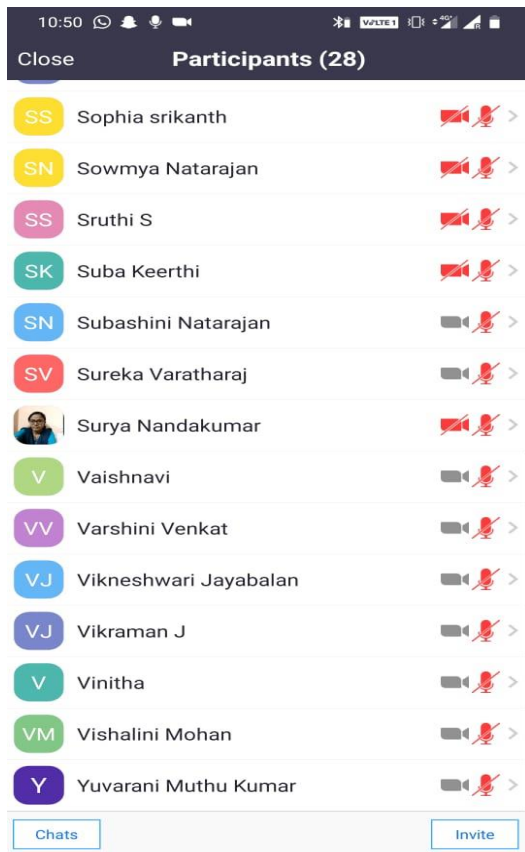
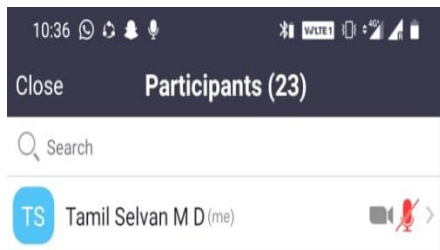
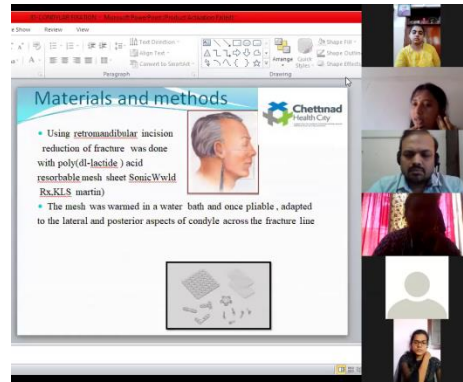
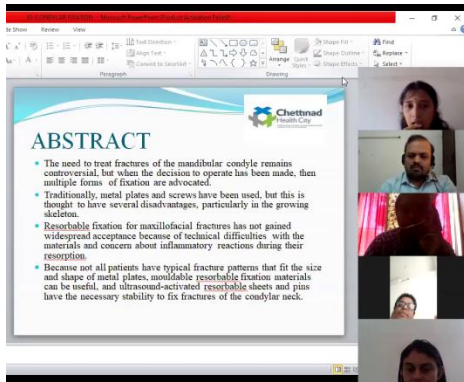
Y Yuvarani Muthu Kumar

Chats Invite



E – Teaching/Learning Sessions for 4th year BDS
Department of ORAL AND MAXILLOFACIAL SURGERY

4-4-2020



4-2-2020

