



DEPARTMENT OF PEDODONTICS & PREVENTIVE DENTISTRY

Final Year BDS 2019-2020


S.NO	DATE	CLINICAL DISCUSSION TOPIC	FACULTY	NO.OF STUDENTS PARTICIPATED
D1 BATCH				
1.	01.04.2020	PULP CAPPING	DR.DIVYA	07
2.	02.04.2020	PULPOTOMY	DR.DIVYA	06
3.	03.04.2020	PULPECTOMY	DR.DIVYA	07
4.	04.04.2020	APEXIFICATION AND APEXOGENESIS	DR.DAYA DR.DIVYA, DR.DEVI	07

NAME OF E-REOSURCE PLATFORM	WEBLINK	USED FOR
ZOOM 	https://zoom.us/	THEORY CLASS CLINICAL CASE DISCUSSIONS ATTENDANCE
GOOGLE CLASSROOM  Google Classroom	https://classroom.google.com/	ASSIGNMENTS QUIZ ASSESSMENT AND GRADING

DEPARTMENT OF PEDODONTICS & PREVENTIVE DENTISTRY

FINAL YEARS E-CLINICS

Topic : Pulp capping
Date : 01.04.2020
Time : 10:30 am
Faculty : Dr. Divya
Students : 7/7
Absentee : Nil
Batch : D1
Platform : ZOOM



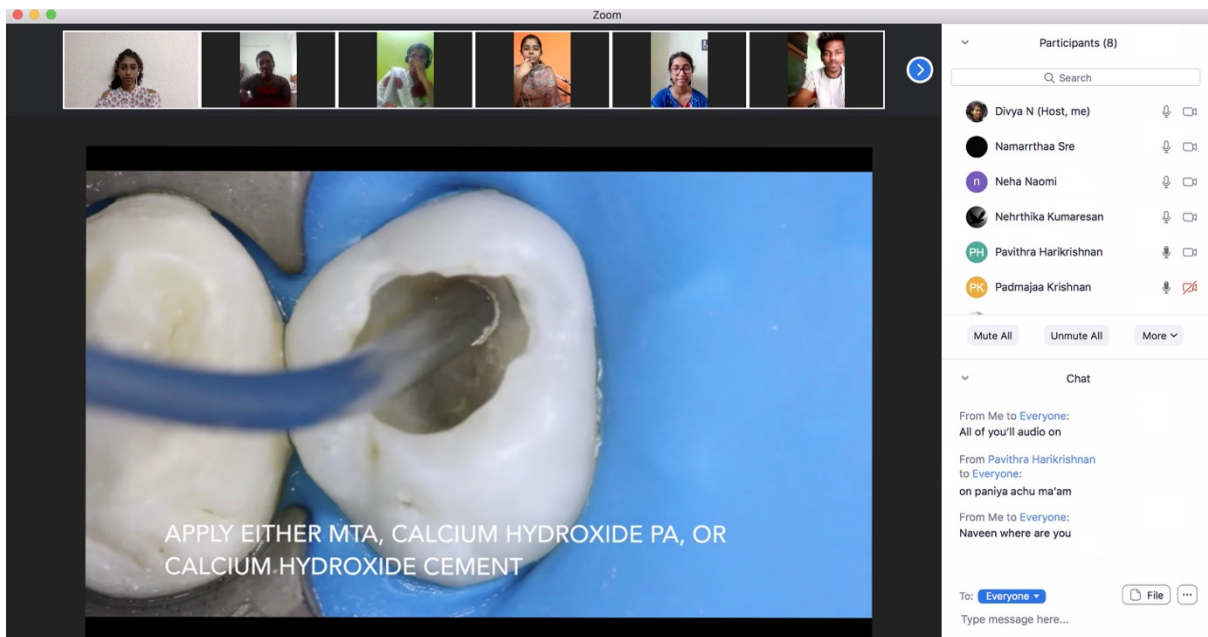
Join our Cloud HD Video Meeting now

Zoom is the leader in modern
us04web.zoom.us

Join Zoom Meeting

[https://us04web.zoom.us/j/825440663?](https://us04web.zoom.us/j/825440663?pwd=bzJiOWtORURpUHM3Z01UeFNmb1NWZz09)
[pwd=bzJiOWtORURpUHM3Z01UeFNmb1NWZz09](https://us04web.zoom.us/j/825440663?pwd=bzJiOWtORURpUHM3Z01UeFNmb1NWZz09)

Meeting ID: 825 440 663



The screenshot shows a Zoom meeting interface. The main window displays a close-up of a dental procedure on a tooth, with a blue instrument being used. Text overlay on the image reads: "APPLY EITHER MTA, CALCIUM HYDROXIDE PA, OR CALCIUM HYDROXIDE CEMENT". The top bar shows the Zoom logo and a row of participant thumbnails. The right sidebar contains a list of participants (8 total) with their names and status icons. Below the list are controls for muting/unmuting all participants and a chat window. The chat window shows messages from the host and participants.

Participants (8)

- Divya N (Host, me)
- Namarrthaa Sre
- Neha Naomi
- Nehrthika Kumaresan
- Pavithra Harikrishnan
- Padmajaa Krishnan

Chat

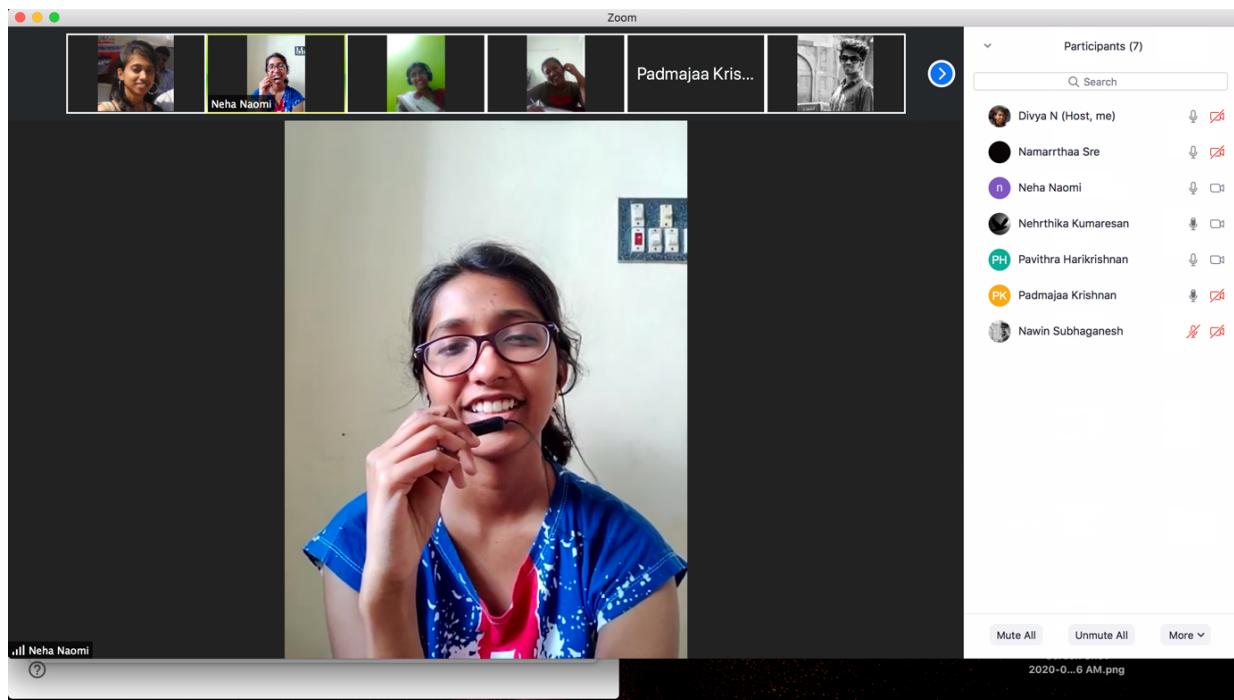
From Me to Everyone:
All of you'll audio on

From Pavithra Harikrishnan to Everyone:
on paniya achu ma'am

From Me to Everyone:
Naveen where are you

To: Everyone

Type message here...



Assignment on Pulp Capping

100 points

Divya N Apr 1

Students should type and submit assignments.

Assignment on Pulp ...
Google Docs

11:39 100% D Black Berry - A... All changes saved

Assignment on Pulp Capping

- Why is Direct Pulp Capping contraindicated in Primary teeth?
Undifferentiated mesenchymal cells may convert into osteoclasts
- What is the ideal remaining dentin thickness and its importance?
thickness of 1 mm or even 0.5 mm to be necessary for pulp protection
- Indications of Direct and Indirect Pulp Capping?
Indirect : Definitive layer of affected dentin after the removal of infected dentin
Direct : traumatic or mechanical exposure with no pain
- List the materials used for Pulp capping in Primary teeth?
calcium hydroxide liner, dentin bonding agents, mineral trioxide aggregate, glass ionomer cement, zinc oxide/eugenol, calcium silicate or medical Portland cement.
- How long does it take for dentin bridge to form after placement of calcium hydroxide?
2-3months



Return



100 points



All students

Sort by status

Turned in

<input type="checkbox"/>	D Black Befry "Thankyou mam 🙏"	80 Draft
<input type="checkbox"/>	Naafia Fathima "Ok"	40 Draft
<input type="checkbox"/>	Pavi H "Only if you find 10 materials you..."	75 Draft
<input type="checkbox"/>	Padmajaa Krishnan "Ok ma'am will read and update ..."	85 Draft
<input type="checkbox"/>	Nehrthika Kumaresan "Yes mam."	90 Draft
<input type="checkbox"/>	M.DURGADEVI MARIMUTHU "Good job. Learn newer materials."	90 Draft
<input type="checkbox"/>	neha naomi	90 Draft

Assignment on Pulp Capping

7
Turned in

0
Assigned

All

D Black Befry
Screenshot_2020040...
Turned in

Naafia Fathima
Naafia Fathima - Assi...
Turned in

Pavi H
Pavi H - Assignment o...
Turned in

Padmajaa Krishnan
2 attachments
Turned in late

Nehrthika Kumaresan
Nehrthika Kumaresan ...
Turned in


M.DURGADEVI MARIMUTHU
M.DURGADEVI MARI...
Turned in

neha naomi
neha naomi - Assignm...
Turned in late

DEPARTMENT OF PEDODONTICS & PREVENTIVE DENTISTRY

FINAL YEARS E-CLINICS

Topic : Pulpotomy
Date : 02.04.2020
Time : 10:30 am
Faculty : Dr. Divya
Students : Final Years 6/7
 Interns 3/3
Batch : D1
Absentee : Ms. Pavithra
Platform : ZOOM

 Join our Cloud HD Video Meeting now
Zoom is the leader in modern
us04web.zoom.us

Join Zoom Meeting
[https://us04web.zoom.us/j/235229324?](https://us04web.zoom.us/j/235229324?pwd=cGpKZlJhV3F3NzRuMU9TVU1kVC8xQT09)
[pwd=cGpKZlJhV3F3NzRuMU9TVU1kVC8xQT09](https://us04web.zoom.us/j/235229324?pwd=cGpKZlJhV3F3NzRuMU9TVU1kVC8xQT09)

Meeting ID: 235 229 324

ID: 235-229-324 Stop Share

Hard tissues

Class I canines
Mesial step molars
Caries in 54,64,74,51,52,61,62

Diagnostic tools

Periapical Radiograph of 51,52,61,62
Bitewing radiograph of right and left quadrant

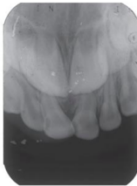


Figure 3.3.2. Periapical radiograph of the maxillary incisor

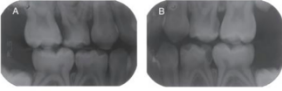
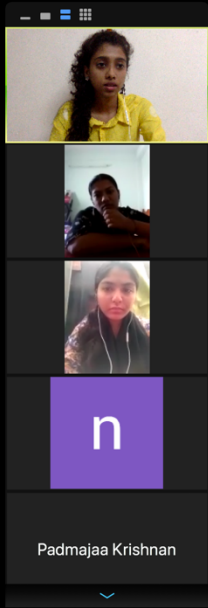
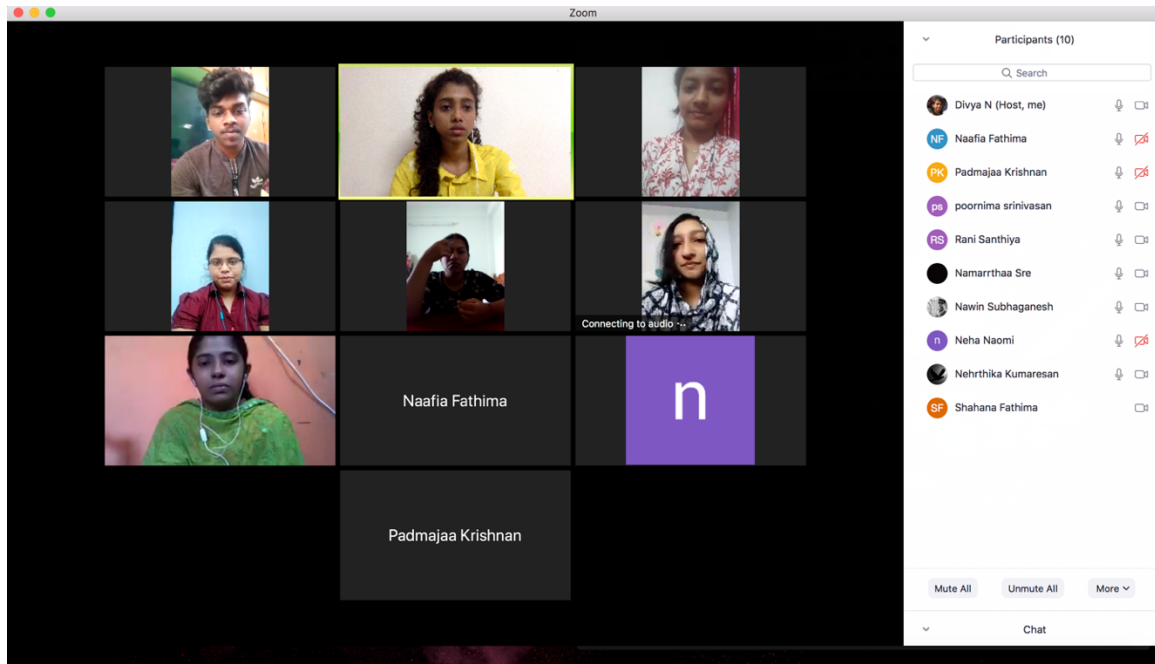


Figure 3.3.3a-b. Bitewing radiographs. A. Right bitewing radiograph, B. Left bitewing radiograph

3







Pulpotomy Quiz

100 points

Divya N Apr 2



Pulpotomy Quiz
Google Forms



Pulpotomy Quiz

* Required

Pulpotomy is based on the rationale *

10 points

☐ Radicular pulp tissue is healthy
☐ Radicular pulp tissue is capable of healing after surgical amputation of infected coronal pulp
☐ Option 1 AND Option 2

% of Ferric Sulfate used in pulpotomy is, *

5 points

☐ 2%
☐ 5%
☐ 10%
☐ 15.5%

Formocresol is not used for the reason, *

10 points

☐ Irritates soft tissue
☐ Causes nasopharyngeal cancer
☐ Causes tooth discoloration
☐ Leukemia
☐ Option 2 and 4
☐ Option 1 and 3

Formocresol pulpotomy technique is *

5 points

☐ Devitalisation
☐ Preservation
☐ Regeneration

Action of formocresol is due to, *

5 points

☐ Protein-binding property
☐ Inhibition of enzyme
☐ Fixative effect
☐ All of the above



Return



100 points



☐ Turned in



D Bläck Befry

85

Draft



Naafia Fathima

43

Draft



Padmajaa Krishnan

70

Draft



Nehrthika Kumaresan

80

Draft



M.DURGADEVI MARIMUTHU

75

Draft



neha naomi

85

Draft

☐ Assigned



Pavi H

0

Draft



Pulpotomy Quiz

6

Turned in

1

Assigned



Pulpotomy Quiz

Google Forms

All



D Bläck Befry

Turned in



Naafia Fathima

Turned in



Padmajaa
Krishnan

Turned in



Nehrthika
Kumaresan

Turned in



M.DURGADEVI
MARIMUTHU

Turned in



neha naomi

Turned in



Pavi H

Assigned

DEPARTMENT OF PEDODONTICS & PREVENTIVE DENTISTRY

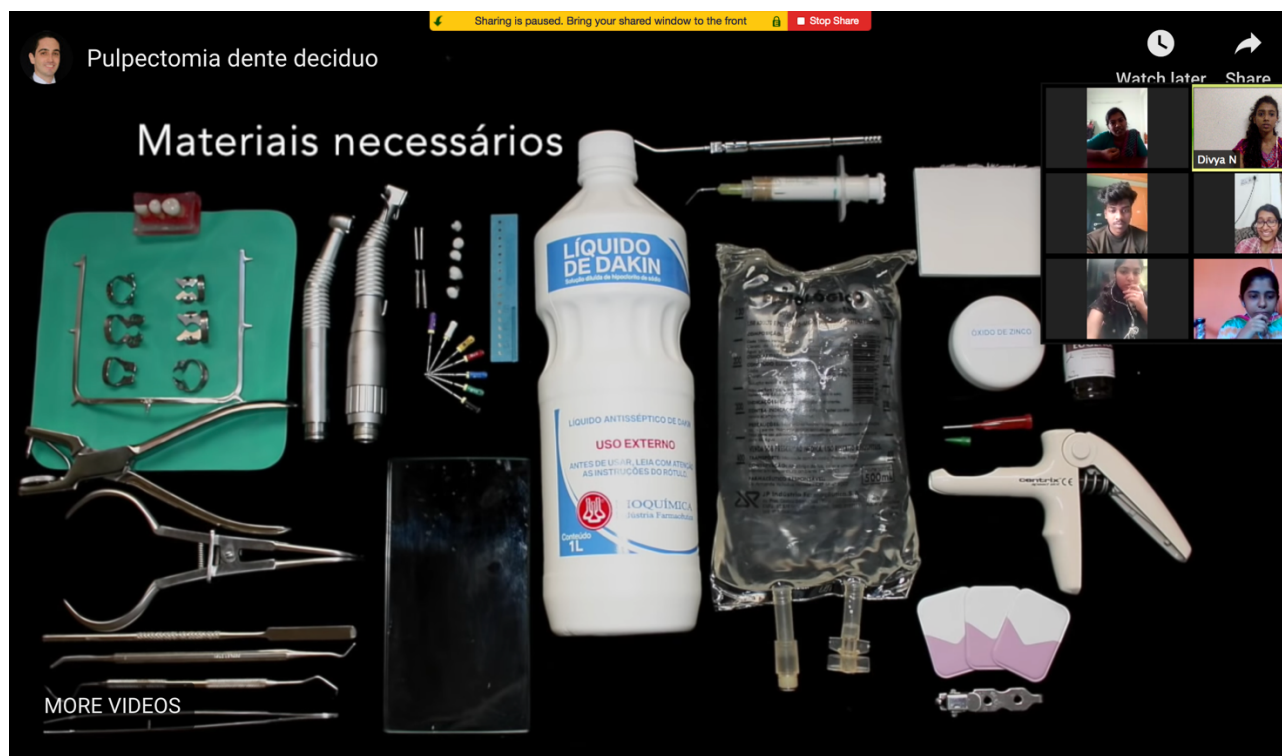FINAL YEARS E-CLINICS

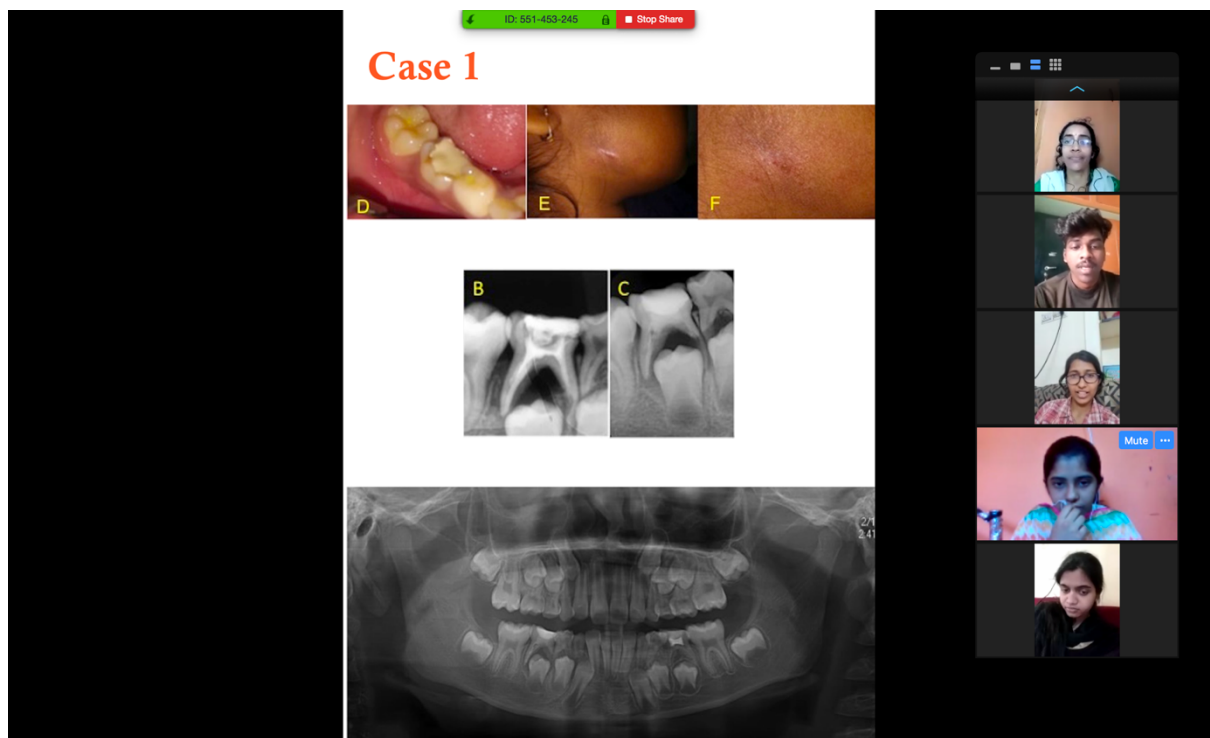
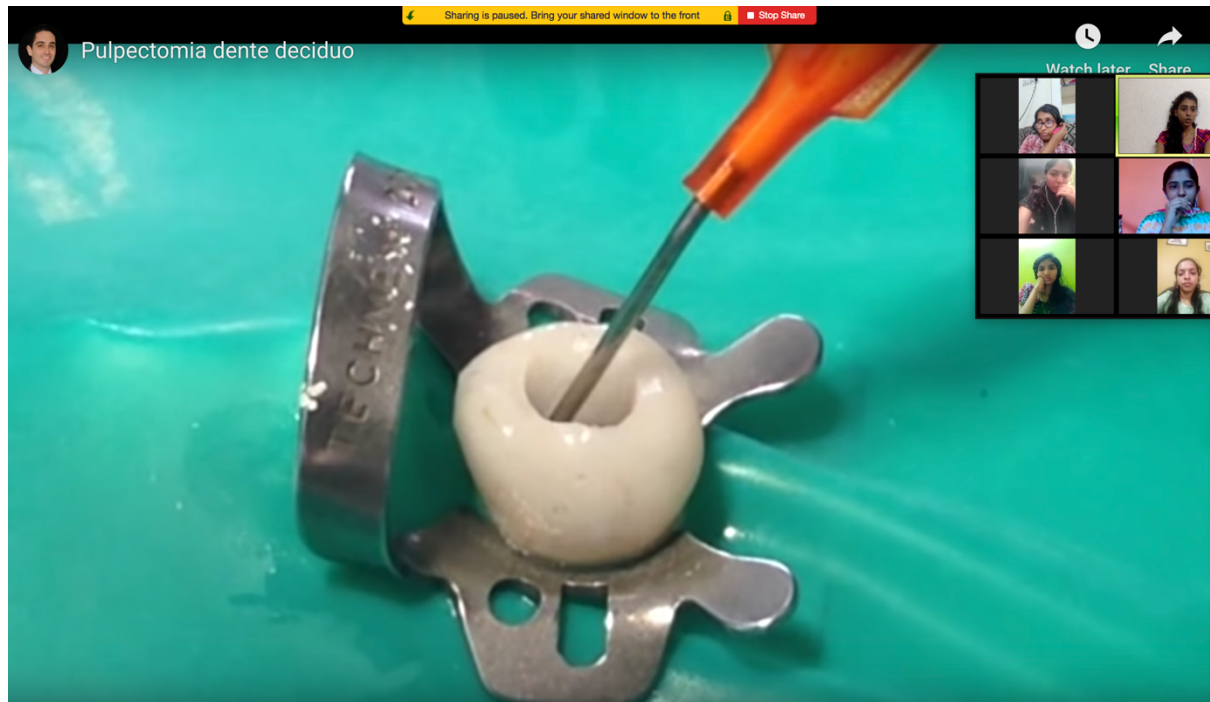
Topic : Pulpectomy
Date : 03.04.2020
Time : 11:00 am
Faculty : Dr. Divya
instructor
Faculty : Dr. Daya and Dr.Devi
attended
Students : Final Years 7/7
Batch : D1
Absentee : Nil
Platform : ZOOM

zoom Join our Cloud HD Video Meeting now
Zoom is the leader in modern
us04web.zoom.us

Join Zoom Meeting
[https://us04web.zoom.us/j/551453245?](https://us04web.zoom.us/j/551453245?pwd=MndMY25NRmJwSEkvc2MyemJ6SIJOUT09)
[pwd=MndMY25NRmJwSEkvc2MyemJ6SIJOUT09](https://us04web.zoom.us/j/551453245?pwd=MndMY25NRmJwSEkvc2MyemJ6SIJOUT09)

Meeting ID: 551 453 245








Pulpectomy Quiz

100 points

Divya N Apr 3



Pulpectomy Quiz

* Required

Name *

Your answer

Pulpectomy is the complete removal of necrotic pulp from root canals of primary teeth and fillin' then with an inert ____ material so as to maintain the tooth in the dental arch 10 points

- ☐ Obturating
- ☐ Resorbable
- ☐ Flowable
- ☐ Biocompatible

Disadvantage of calcium hydroxide as an obturating material 10 points

- ☐ Faster rate of resorption of material
- ☐ Yellowish discoloration
- ☐ Irritation to periapical tissues
- ☐ Nonresorbable

A 3 year old with pain in the mandibular lower right quadrant associated with pain in the night is indicative of, 10 points

- ☐ Reversible pulpitis
- ☐ Pulp necrosis
- ☐ Irreversible Pulpitis
- ☐ Broken tooth

What are the indications for pulpectomy in primary teeth? 10 points

- ☐ Abscess
- ☐ Furcal radiolucency
- ☐ Restorable crown
- ☐ All of the above

Final Year BDS 2019-20 - D1 Batch
Dentistry

Instructions

Student work



Return



100 points



Sort by status

☐ Turned in

☐ D Bläck Befry 70 Draft

☐ Naafia Fathima 90 Draft

☐ Pavi H 90 Draft

☐ Padmajaa Krishnan 80 Draft

☐ Nehrthika Kumaresan 90 Draft

☐ M.DURGADEVI MARIMUTHU 90 Draft

☐ neha naomi 70 Draft

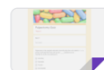Pulpectomy Quiz

7

Turned in

0

Assigned



Pulpectomy Quiz
Google Forms

All

D Bläck Befry
Turned in

Naafia Fathima
Turned in

Pavi H
Turned in

Padmajaa
Krishnan
Turned in

Nehrthika
Kumaresan
Turned in


M.DURGADEVI
MARIMUTHU
Turned in

neha naomi
Turned in

DEPARTMENT OF PEDODONTICS & PREVENTIVE DENTISTRY

FINAL YEARS E-CLINICS

Topic : Apexification and
Apexogenesis
Date : 04.04.2020
Time : 11:00 am
Faculty : Dr. Daya
instructor
Faculty : Dr. Divya and Dr. Devi
attended
Students : Final Years 7/7
Batch : D1
Absentee : Nil
Platform : ZOOM



Dr. Daya

Daya Srinivasan is inviting you to a scheduled Zoom meeting.

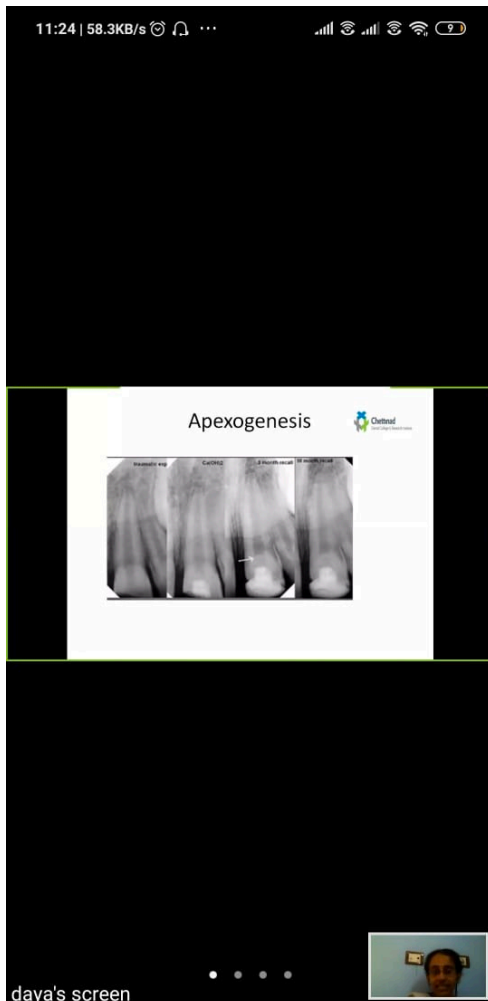
Topic: Daya Srinivasan's Zoom Meeting
Time: Apr 4, 2020 11:15 AM Mumbai, Kolkata, New Delhi

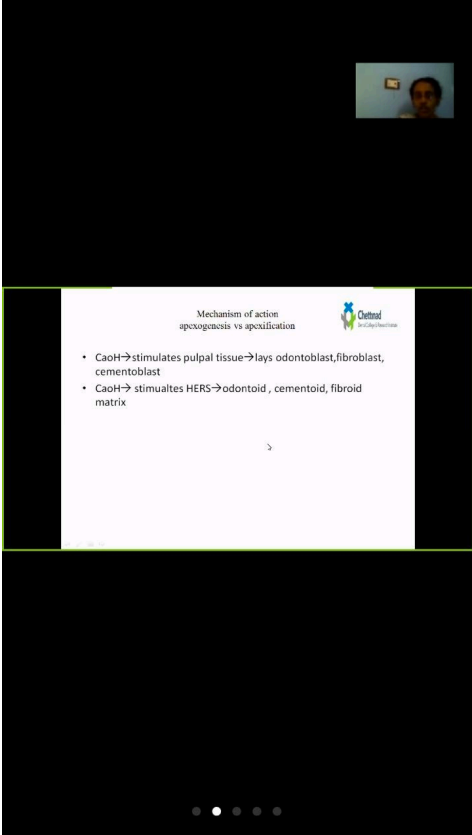
Join Zoom Meeting

[https://us04web.zoom.us/j/167789849?](https://us04web.zoom.us/j/167789849?pwd=UG1WMHBUQjVZYUIQKzVxMnllRHJhbnJQT09)

[pwd=UG1WMHBUQjVZYUIQKzVxMnllRHJhbnJQT09](https://us04web.zoom.us/j/167789849?pwd=UG1WMHBUQjVZYUIQKzVxMnllRHJhbnJQT09)

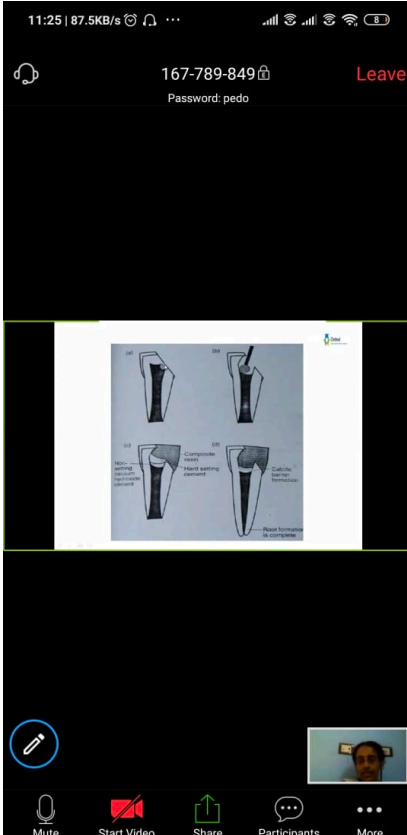
Meeting ID: 167 789 849





Mechanism of action: apoptosis vs apicification

- CaoH → stimulates pulpal tissue → lays odontoblast, fibroblast, cementoblast
- CaoH → stimulates HERS → odontoid, cementoid, fibroid matrix



11:25 | 87.5KB/s | 167-789-849 | Password: pedo | Leave

11:22 | 22.7KB/s | Close | **Participants (10)**

Search

DC	Devi Chandrika (me)		
D	Daya Srinivasan (host)		
D	daya		
NF	Naafia Fathima		
n	Neha Naomi		
	Nehrthika Kumaresan		
PH	Pavithra Harikrishnan		
	Namarrthaa Sre		
	Nawin Subhaganesh		
PK	Padmajaa Krishnan		

Chats | Invite

Airtel | Close | **Participants (10)**

	Divya N (me)		
D	Daya Srinivasan (Host)		
D	daya		
NF	Naafia Fathima		
n	Neha Naomi		
	Nehrthika Kumaresan		
	Namarrthaa Sre		
PH	Pavithra Harikrishnan		
	Nawin Subhaganesh		
PK	Padmajaa Krishnan		

Chat | Invite



Chettinad

Dental College & Research Institute

DEPARTMENT OF PEDIATRIC & PREVENTIVE DENTISTRY

E-clinical test
Topic:Apexogenesis & Apexification
*** Required**

Email address *

Your email

Apexogenesis is done in *

☐ Vital tooth

☐ Non vital tooth

DEPARTMENT OF PEDIATRIC & PREVENTIVE DENTISTRY

E-clinical test Topic:Apexogenesis & Apexification

docs.google.com

DEPARTMENT OF PEDIATRIC & PREVENTIVE DENTISTRY

E-clinical test
Topic:Apexogenesis & Apexification

Email address *

Valid email address

This form is collecting email addresses. [Change settings](#)

Apexogenesis is done in *

☐ Vital tooth

☐ Non vital tooth

An 8-year-old girl comes to you with a broken upper central incisor due to trauma while playing * which happened an hour back. What will be likely treatment?

Short answer text

An 8-year-old boy comes to you with an abscess in 21 with a history of trauma 2 months back. * What will be likely treatment?

Short answer text

What is the material used normally as a medicament in apexogenesis and apexification? *

Short answer text

What material is now used in apical closure? *

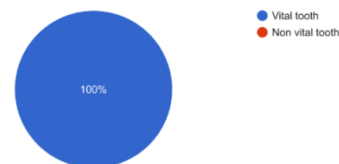
Short answer text

DEPARTMENT OF PEDIATRIC & PREVENTIVE DENTISTRY

DEPARTMENT OF PEDIATRIC & PREVENTIVE DENTISTRY

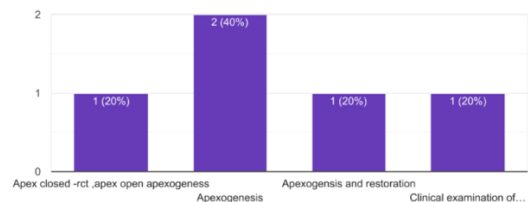
5 responses

Apexogenesis is done in
5 responses



An 8-year-old girl comes to you with a broken upper central incisor due to trauma while playing which happened an hour back. What will be likely treatment?

5 responses



An 8-year-old boy comes to you with an abscess in 21 with a history of