

17.06.2020

CHETTINAD DENTAL COLLEGE
FINAL YEAR WEEKLY REPORT
15-06-2020 TO 20.06.2020

CHETTINAD DENTAL COLLEGE AND RESEARCH INSTITUTE

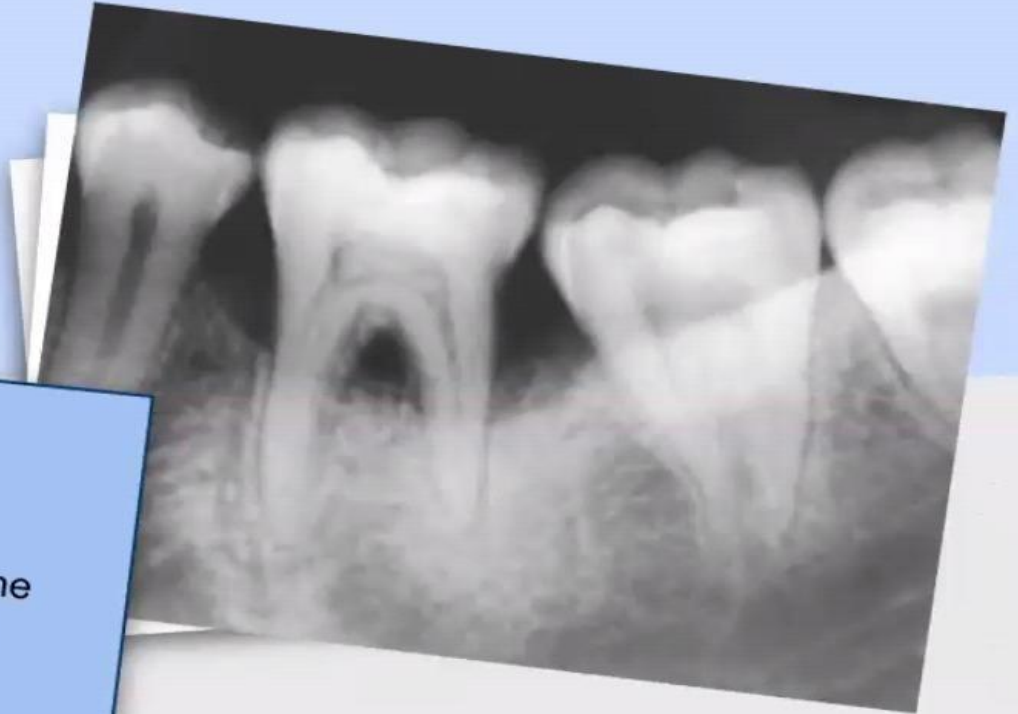
DEPARTMENT OF PERIODONTICS

IV BDS EXAMINATION [Roll No: 1-17]

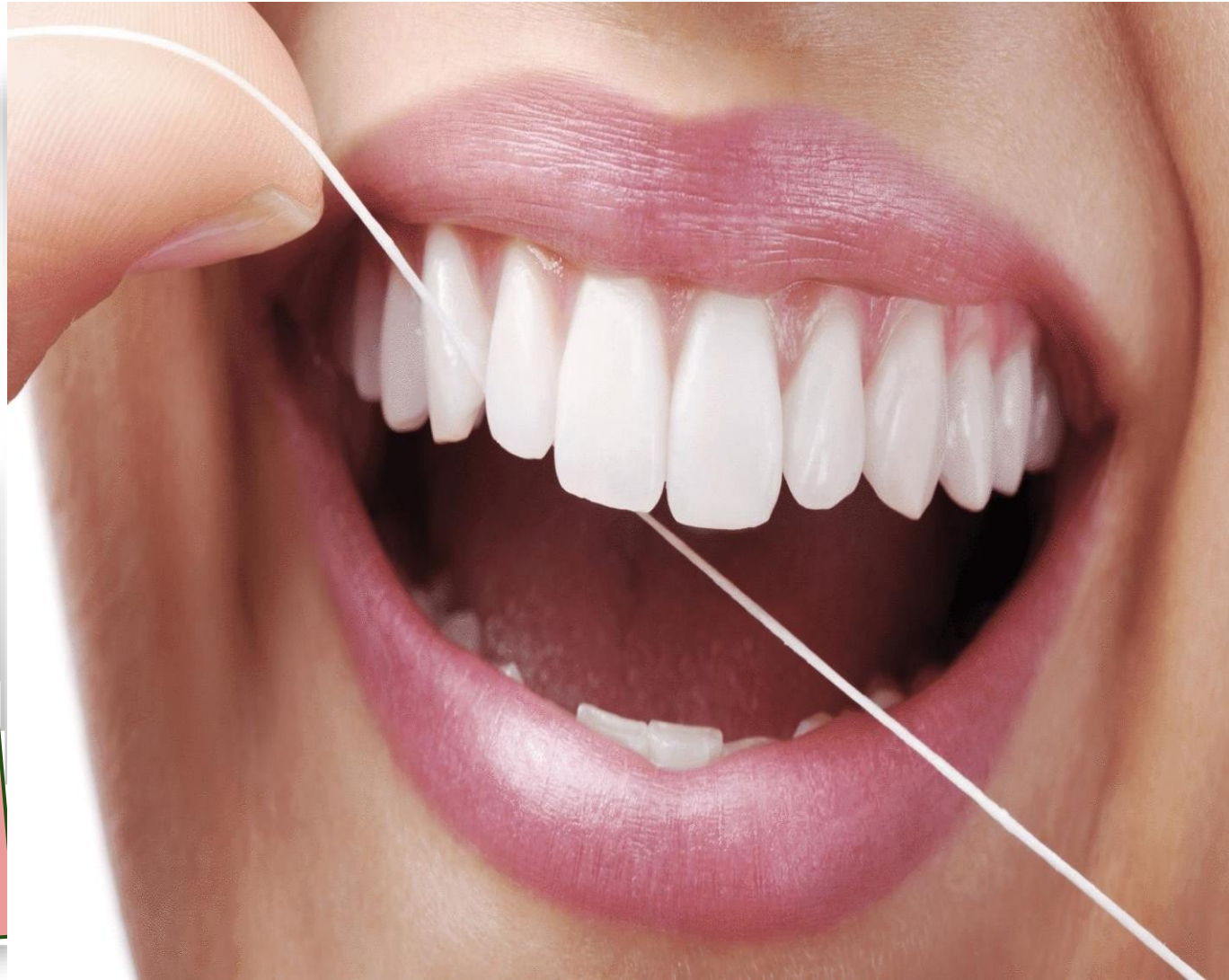FACULTY- Dr.V.Anitha

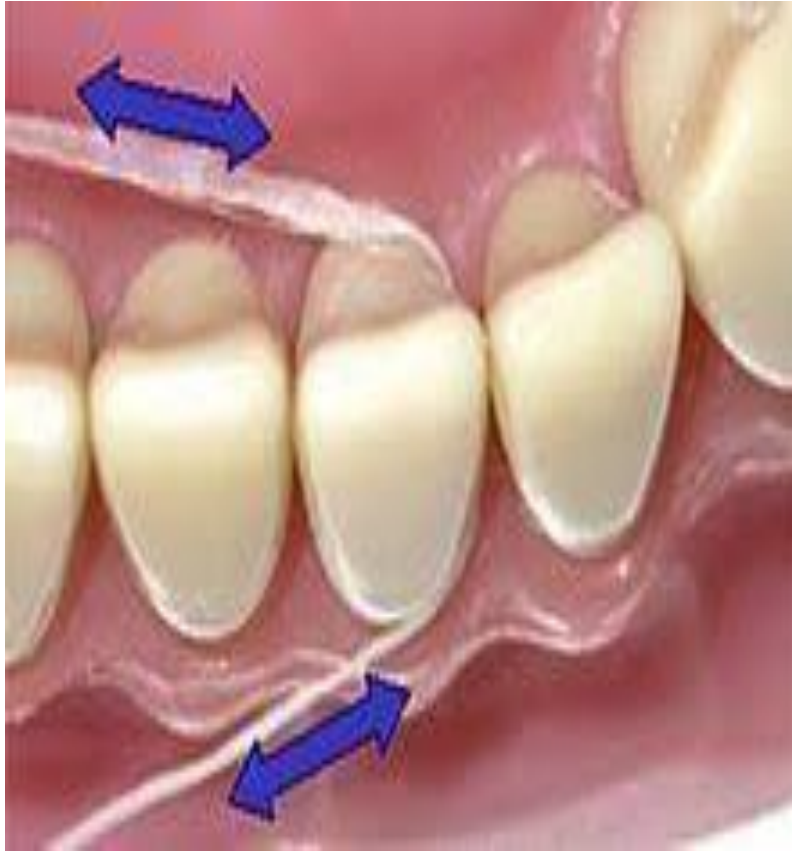7

1. Identify this abnormality
2. 2 points about the salient features



1. Identify the interdental aid
2. Classification





1. Identify the interdental aid
2. Classification

Recording... Speaker View

PM Priyanka M (Host, me)
Agila Elumalai
PL Pavithra lakshmi N
P Prabhavathi.s
P prasanth
P PRIYADARSHINI
Ragavi vijayan
R Rakshanaa Jeevan
Ram Prasath
R Ramu
RS Ranjani Srinivasan
Sai Aditiya
S sanjana
Santra Joseph
SG Sathiya Ganesan
SN Shindhuja N

Mute Stop Video Security Participants Chat Share Screen Pause/Stop Recording Reactions End

Type here to search

Participants (18)

Find a participant

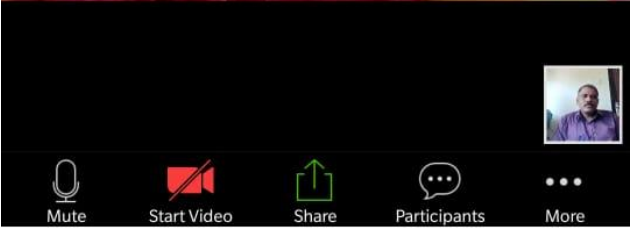
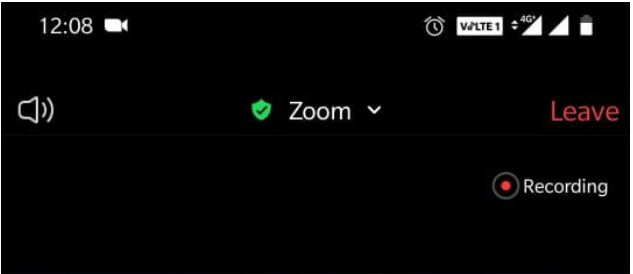
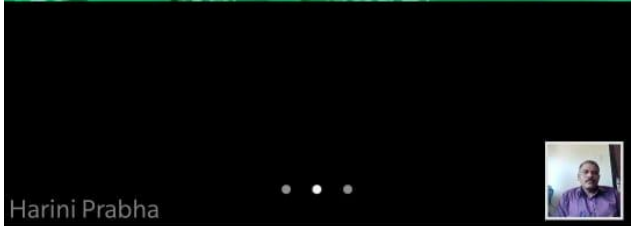

- PM Priyanka M (Host, me)
 - Agila Elumalai
 - PL Pavithra lakshmi N
 - P Prabhavathi.s
 - P prasanth
 - P PRIYADARSHINI
 - Ragavi vijayan
 - R Rakshanaa Jeevan
 - Ram Prasath
 - R Ramu
 - RS Ranjani Srinivasan
 - Sai Aditiya
 - S sanjana
 - Santra Joseph
 - SG Sathiya Ganesan
 - SN Shindhuja N
- Invite Mute All Unmute All

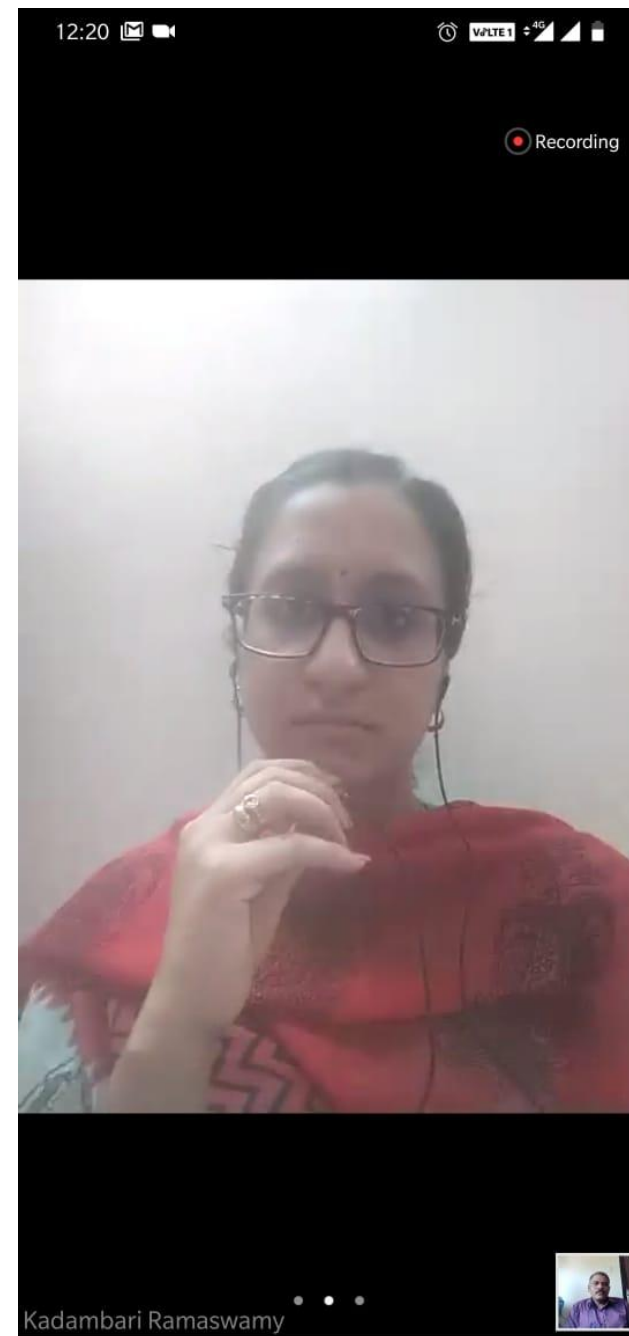
CHETTINAD DENTAL COLLEGE AND RESEARCH INSTITUTE

DEPARTMENT OF PERIODONTICS

IV BDS EXAMINATION [Roll No: 18-32]

FACULTY- Dr.M.Shanmugam





CHETTINAD DENTAL COLLEGE AND RESEARCH INSTITUTE
DEPARTMENT OF PERIODONTICS

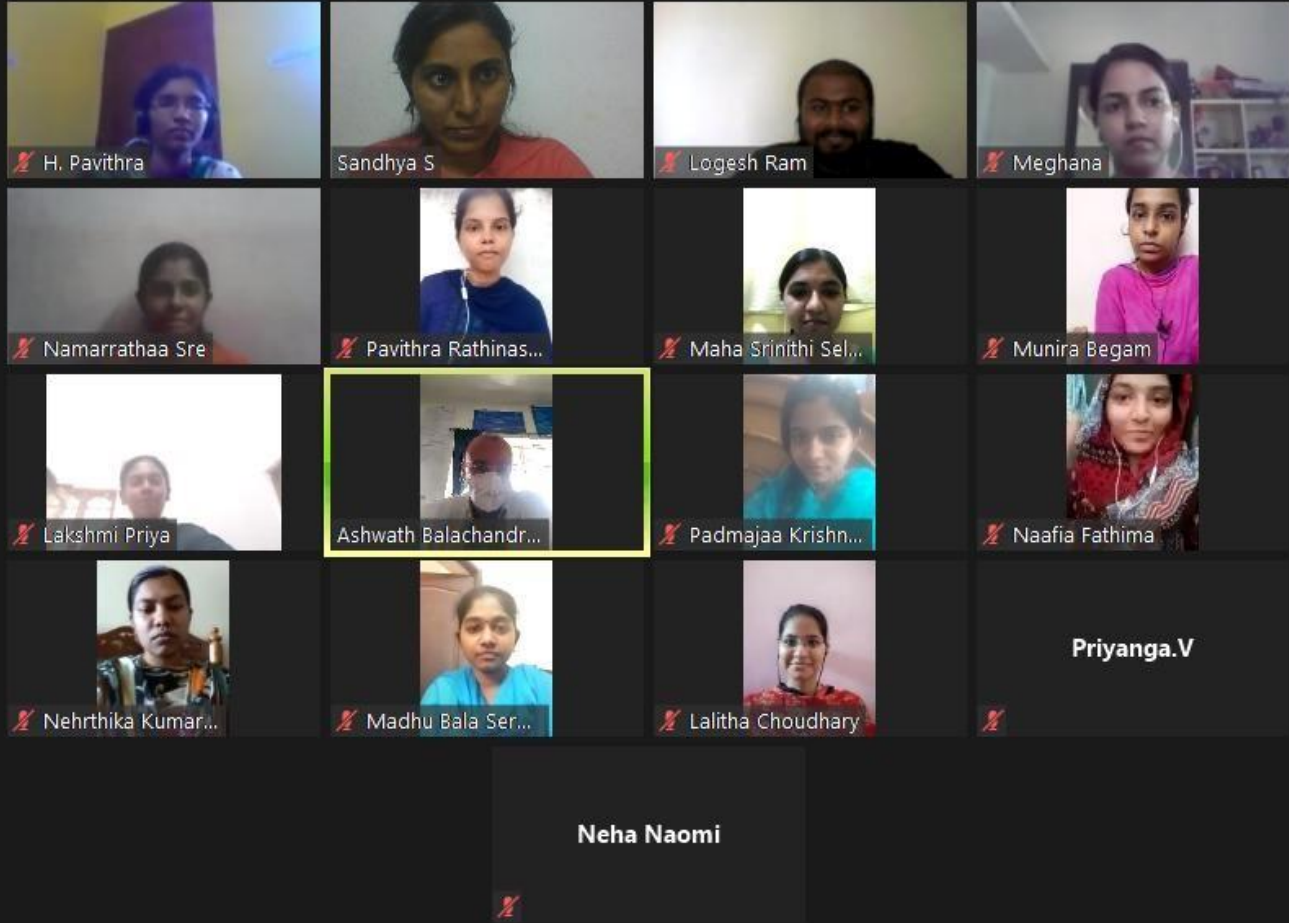
IV BDS EXAMINATION [Roll No: 33-48]

FACULTY- Dr.Ashwath.B

ATTENDANCE

Zoom Meeting

Recording...



The main grid shows 16 video tiles. The first three rows have four tiles each. The fourth row has three tiles, with the last one labeled 'Priyanga.V'. The fifth row has one tile labeled 'Neha Naomi'. Each tile shows a participant's video feed with their name at the bottom. The tile for 'Ashwath Balachandr...' is highlighted with a yellow border.

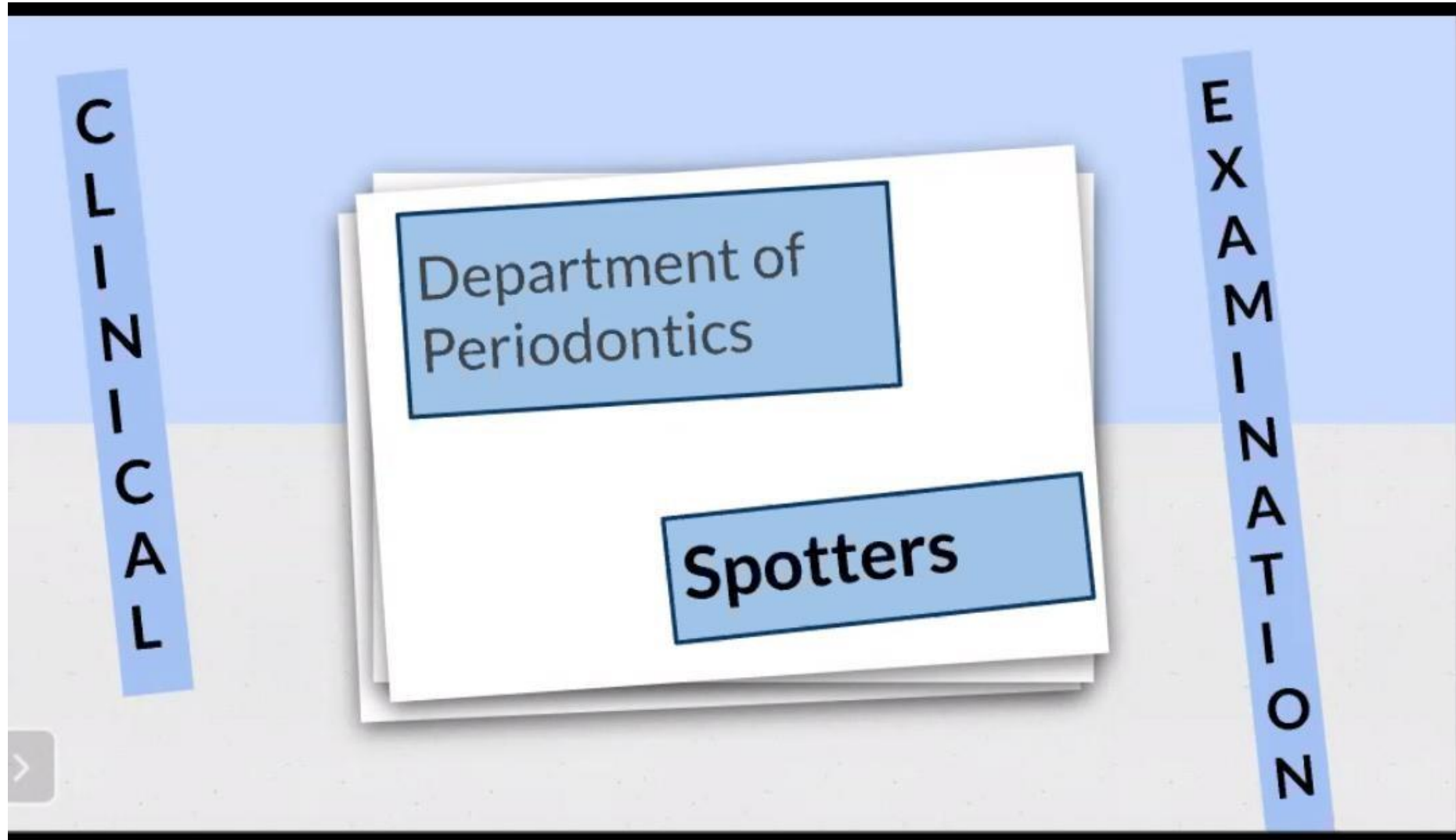
Participants (17)

Find a participant

Participant	Status
SS Sandhya S (Host, me)	On
Ashwath Balachandran	On
H. Pavithra	Off
LP Lakshmi Priya	Off
LC Lalitha Choudhary	Off
LR Logesh Ram	Off
Madhu Bala Sermarajan	Off
Maha Srinithi Selvaraj	Off
M Meghana	Off
Munira Begam	Off
Naafia Fathima	Off
Namarrathaa Sre	Off
NN Neha Naomi	Off
Nehrthika Kumaresan	Off

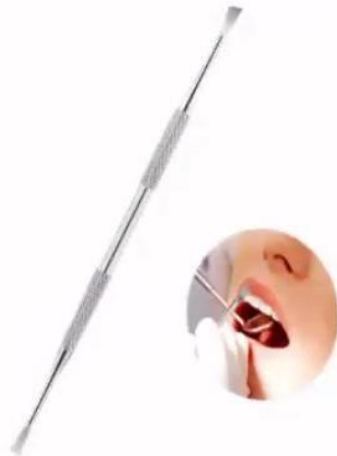Invite Mute All Unmute All ...

SPOTTERS



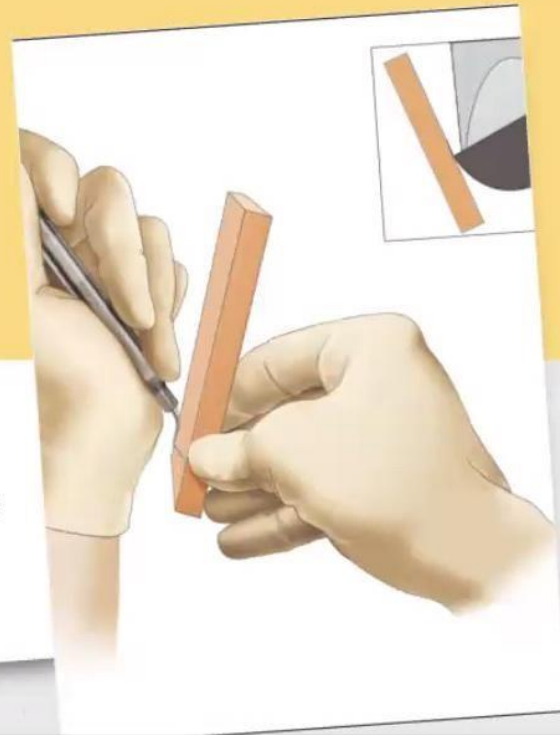
1

1. Identify the instrument
2. 2 points about its uses



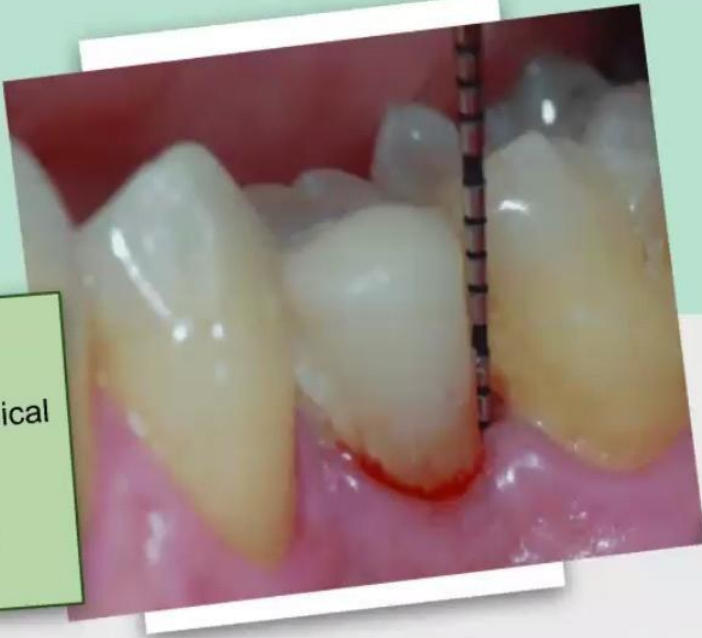2

1. Identify the process
2. 2 points about the materials used



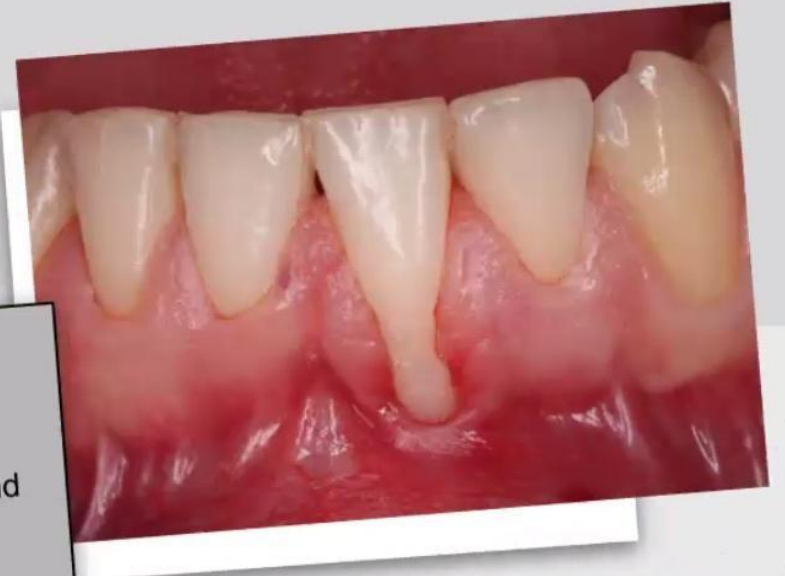3

1. Identify the instrument
2. Explain the clinical situation
3. Describe the clinical finding



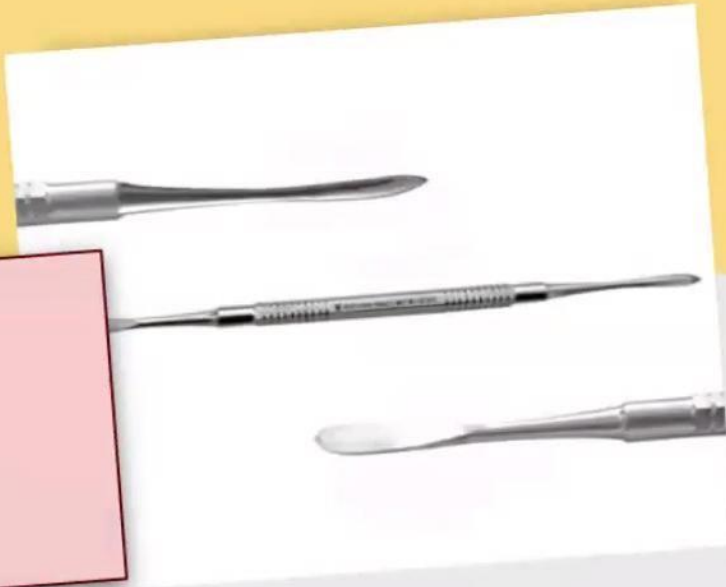4

1. Identify the condition
2. Classification and Etiology



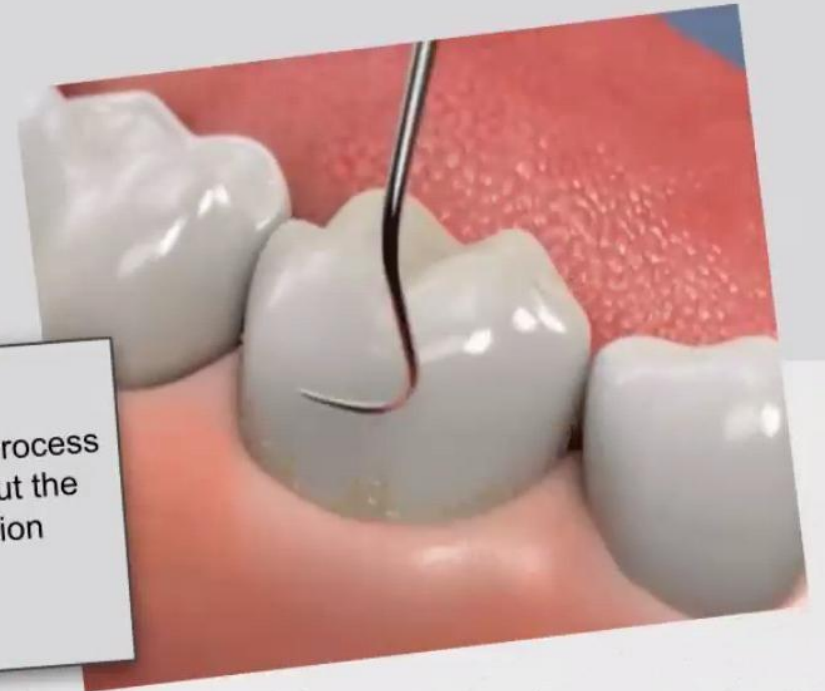5

1. Identify the instrument
2. Its uses and principles

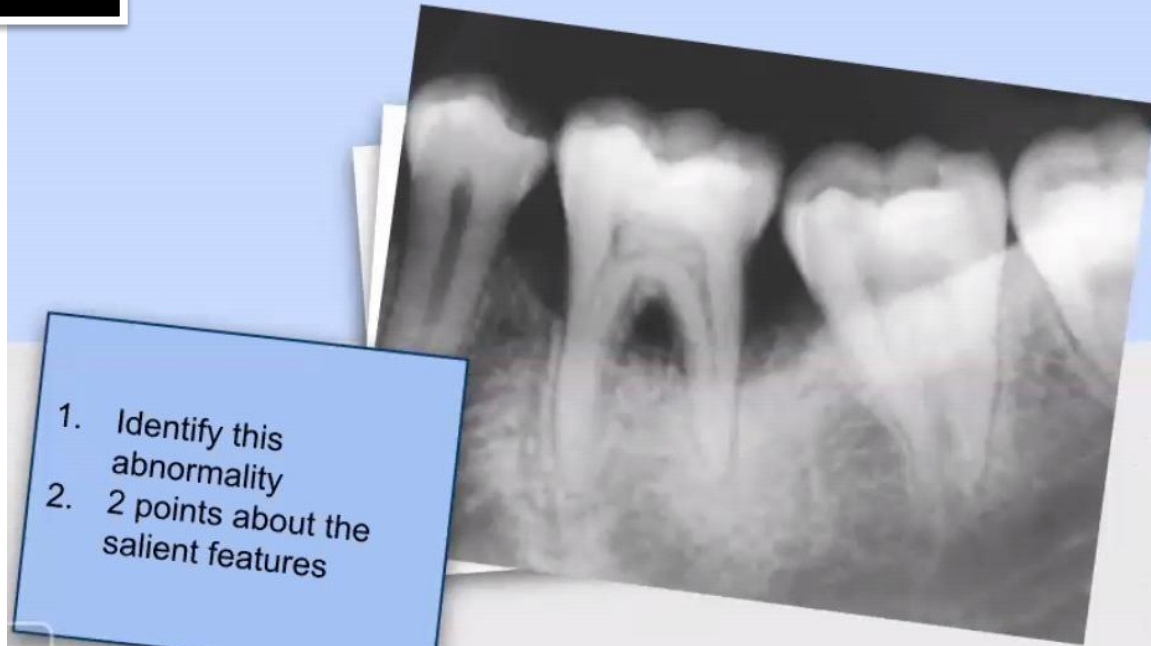

6

1. Identify the process
2. 2 points about the instrumentation process

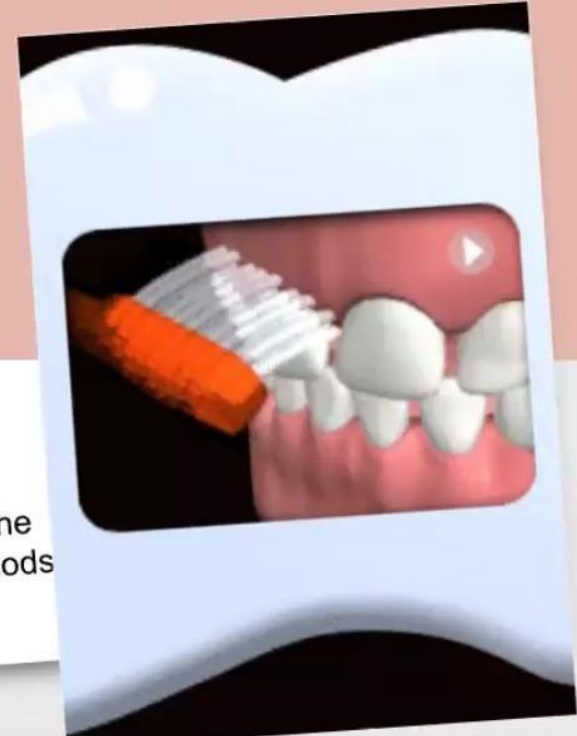

7



1. Identify this abnormality
2. 2 points about the salient features


8



1. Identify the process
2. Ennumerate the different methods

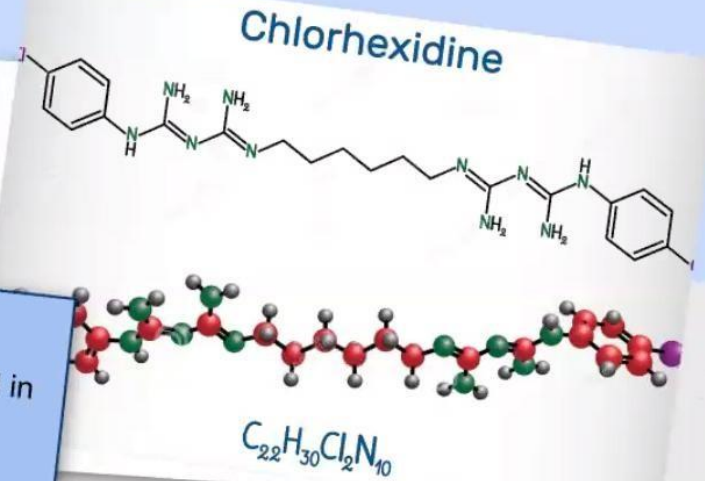9

1. Identify the instrument
2. Explain the clinical situation
3. Classification



10

1. Formulations used in Periodontics
2. 2 points about the side effects



Department of Periodontics

Clinical Case Scenario

June 17, 2020 – Wednesday -- IV BDS Clinical Examination

Roll no – 33 to 48.

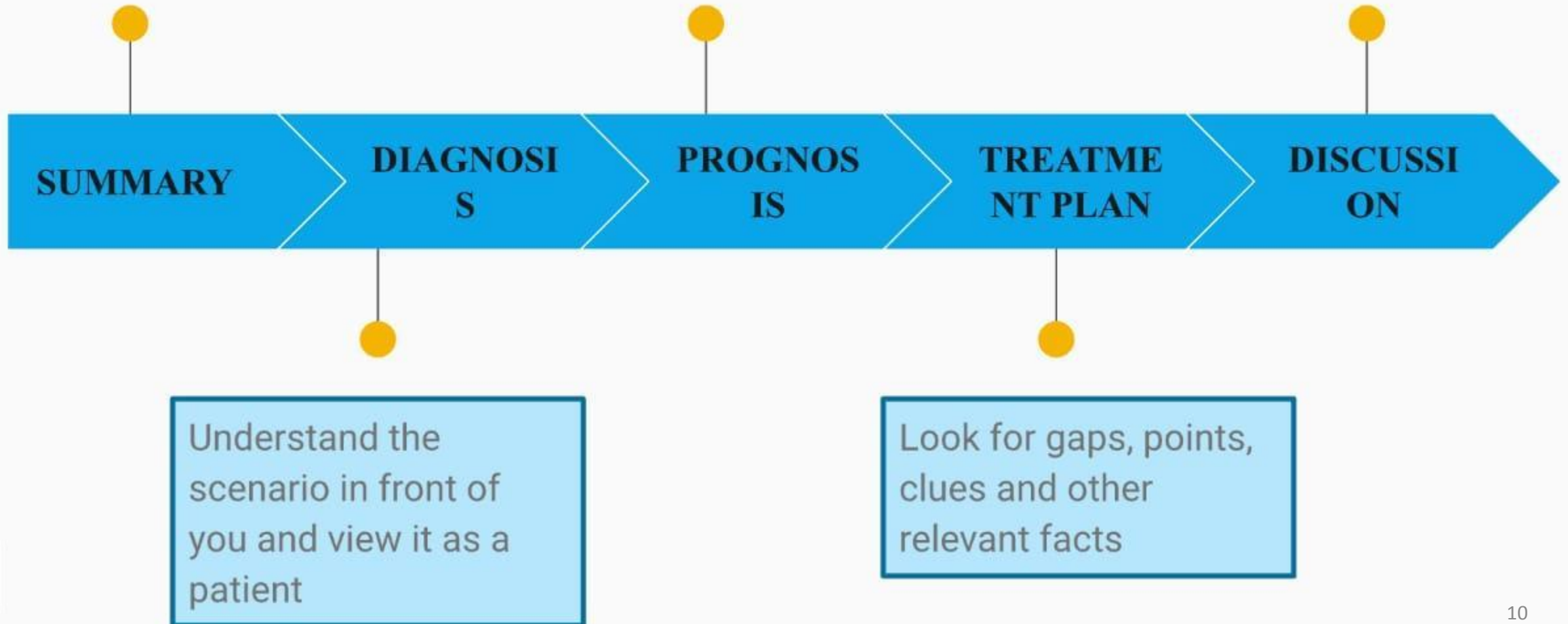
Faculty – B.Ashwath



Think of this as your
Final examination

Note down the key
findings

Assimilate all the data
and express yourself
honestly



Demographic Data

- PATIENT NAME : Ms.Dillikumari
- AGE/SEX : 20/F
- OP NO : 2019082230864
- PHONE NO : 95333132336
- OCCUPATION : Student
- ADDRESS : No 13, Gandhi street,
Manamathi, Kancheepuram – 603 104

<u>CHIEF COMPLAINT</u>	Patient complains of mobile teeth in lower front teeth region for the past 4 months.
<u>PAST MEDICAL HISTORY</u>	Absence of medically related problem
<u>PAST DENTAL HISTORY</u>	First dental visit
<u>FAMILY HISTORY</u>	Patient father had similar history of early exfoliation of teeth

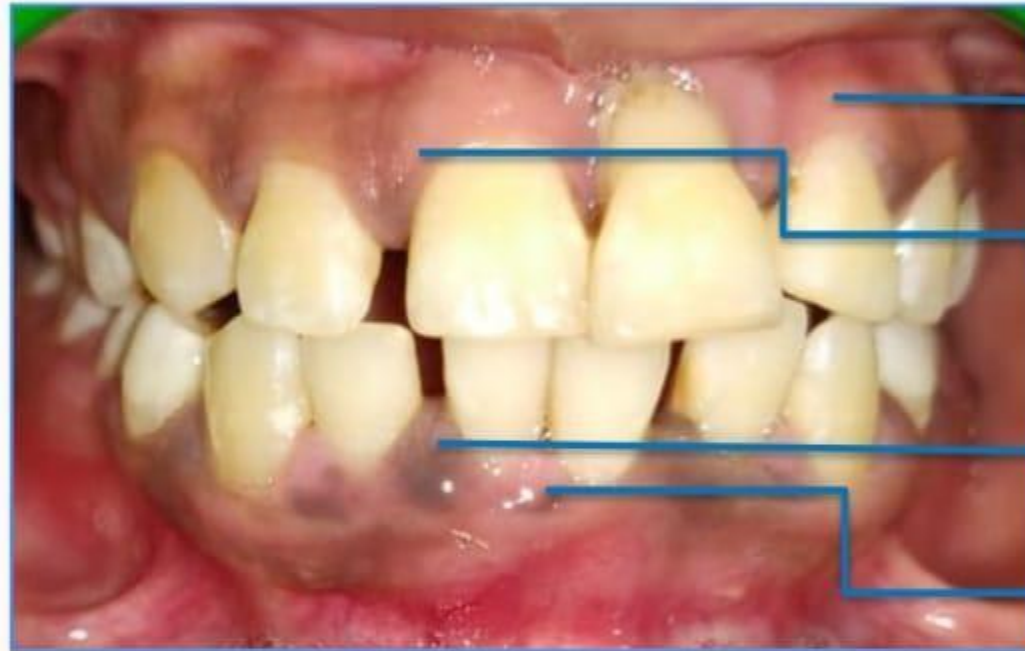
Gingival Findings

COLOR:

CONTOUR:

CONSISTENCY:

SIZE AND SHAPE:



Generalized pink marginal gingiva and interdental papilla

Generalized rolled out marginal gingiva and interdental papilla

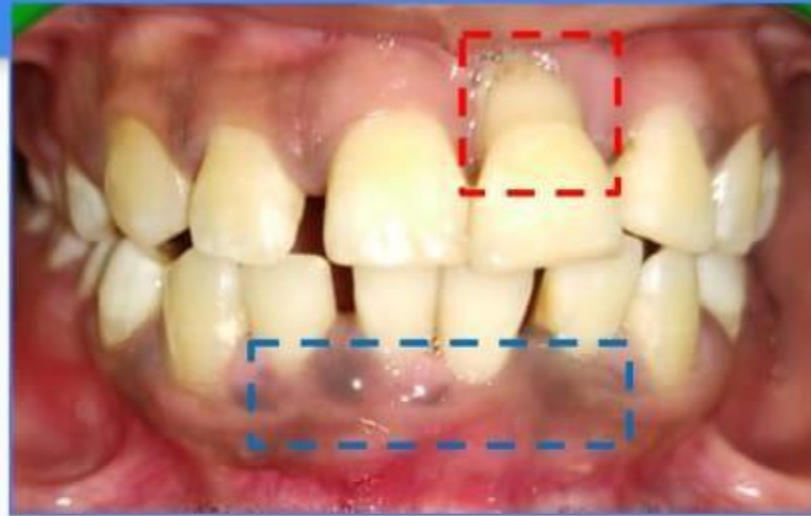
Generalized soft and edematous marginal gingiva and interdental papilla

Generalized Blunt interdental papilla

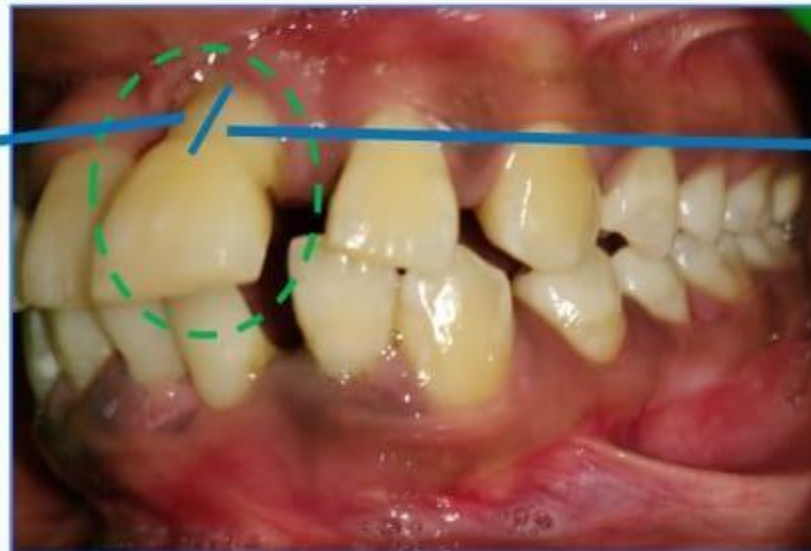Clinical findings of note

Mobility-
Grade III

Mobility-
Grade II



Pathological
tooth
migration

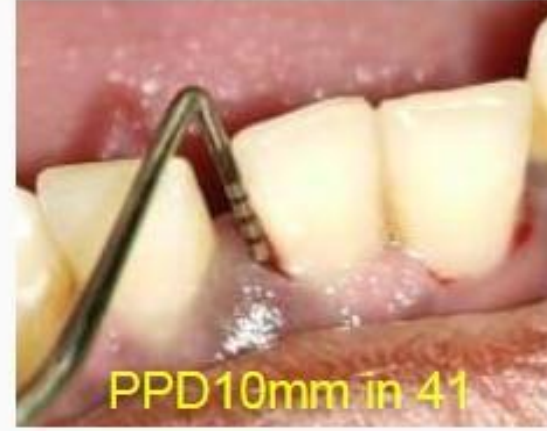
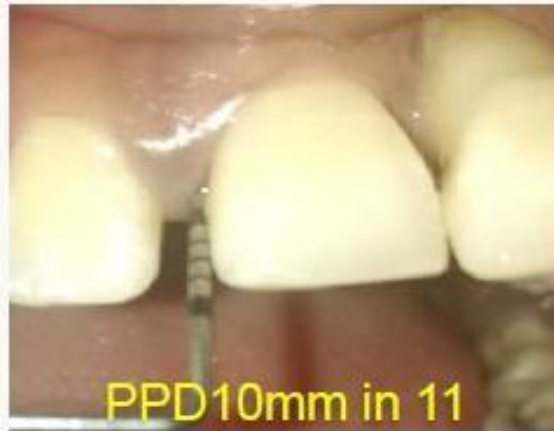

Gingival
Recession

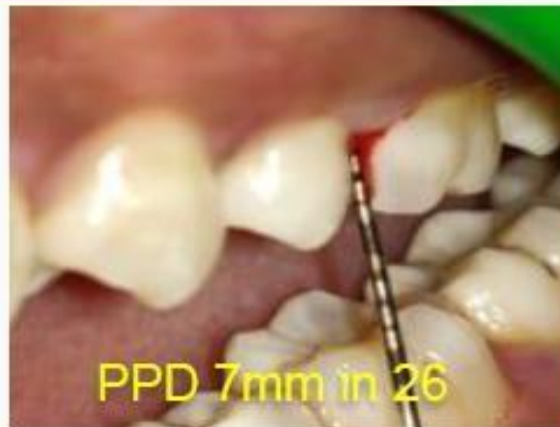PERIODONTAL EXAMINATION

Talking: Ashwath B

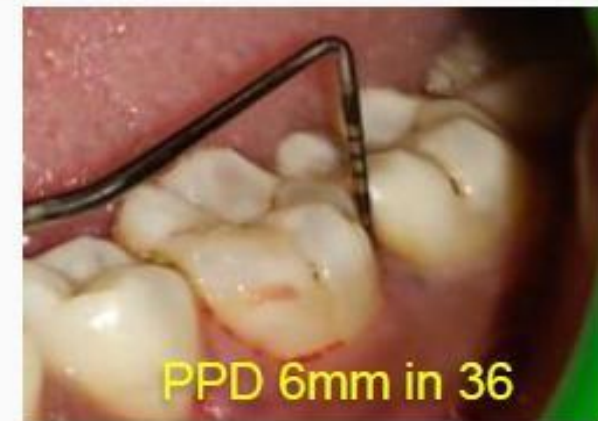PPD (10 MM)- 11,21,41



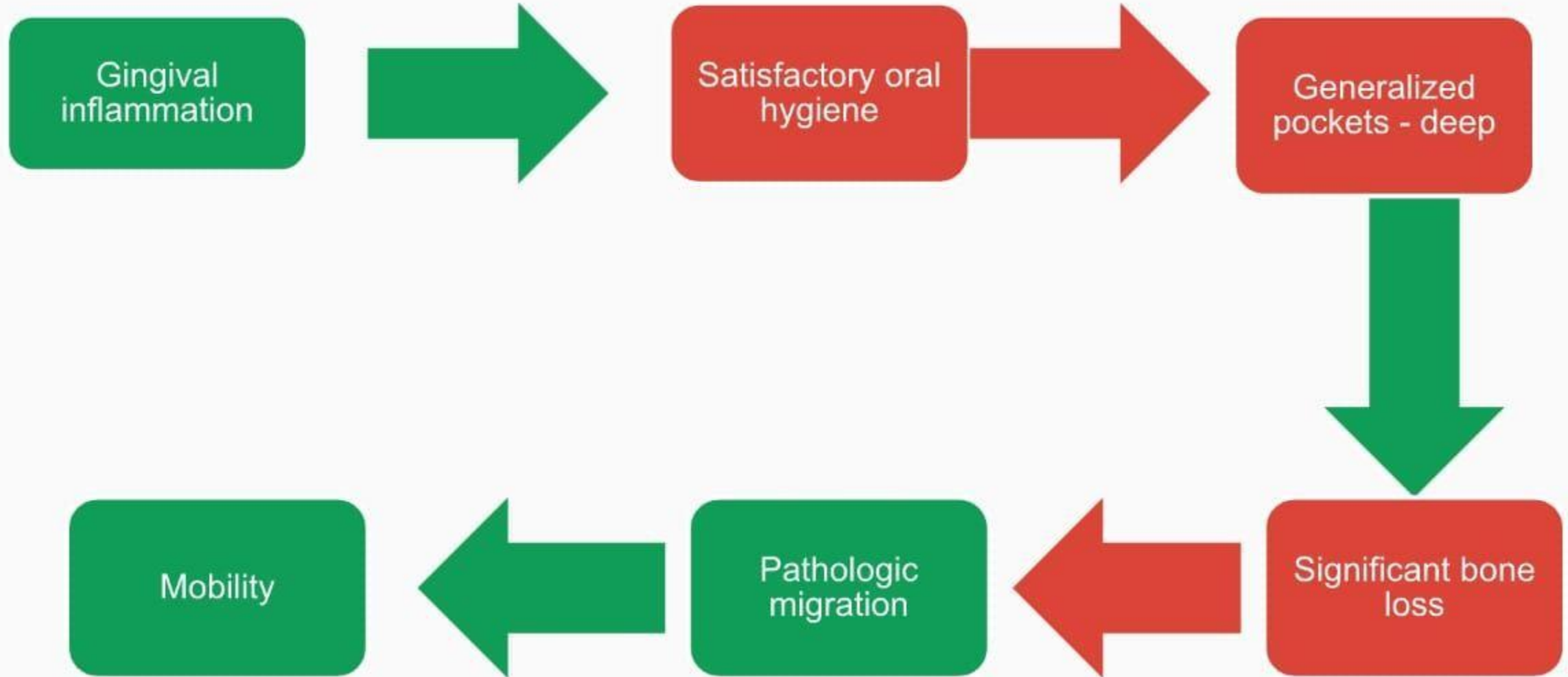
PPD (7 MM)- 12,14,16,24,26,32,34,46,47



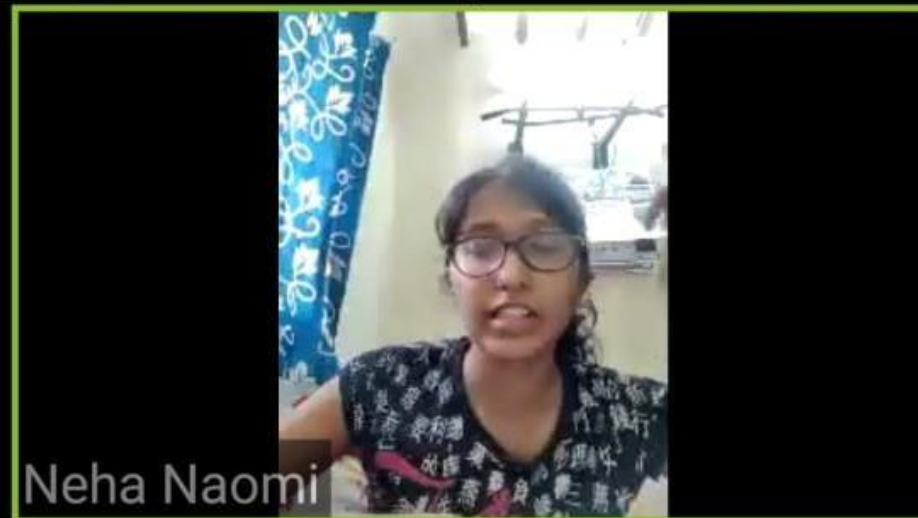PPD (6 MM)-17,25,27,33,35,36,37



Summary of Key Findings



CLINICAL VIVA AND CASE HISTORY DISCUSSION



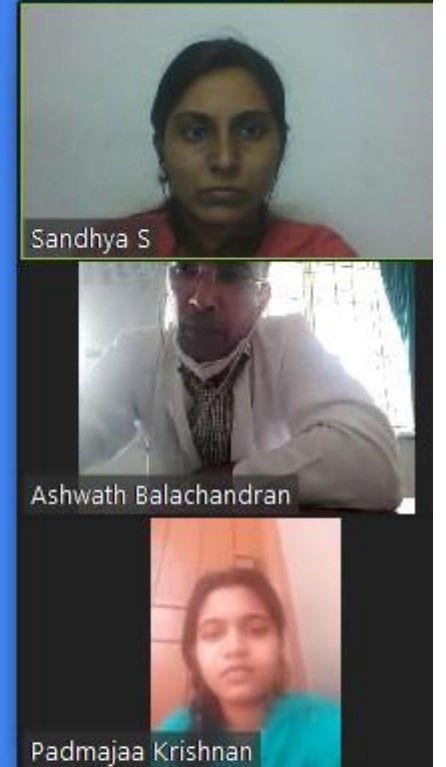CLINICAL VIVA AND CASE HISTORY DISCUSSION

Department of Periodontics Clinical Case Scenario

June 17, 2020 – Wednesday – IV BDS Clinical Examination

Roll no – 33 to 48.

Faculty – B.Ashwath



DEPARTMENT OF PERIODONTOLOGY

CHETTINAD DENTAL COLLEGE AND RESEARCH INSTITUTE

FINAL BDS EXAMINATION 17/06/20 – Roll .No 49-63

SPOTTERS, CASE DISCUSSION AND VIVA

FACULTY – Dr.S.Agila

SPOTTERS

Zoom Meeting 40-Minutes

Recording...

Speaker View

Participants (18)

Find a participant

PM Priyanka M (Host, me)

Agila Elumalai

PL Pavithra lakshmi N

P Prabhavathi.s

P prasanth

P PRIYADARSHINI

Ragavi vijayan

Rakshanaa Jeevan

Ram Prasath

R Ramu

RS Ranjani Srinivasan

Sai Aditiya

S sanjana

Santra Joseph

SG Sathiya Ganesan

SN Shindhuja N

Shivani Sivaramakris...

Prabhavathi.s

Ramu

Sathiya Ganesan

Rakshanaa Jeevan

Shindhuja N

prasanth

sanjana

Santra Joseph

shruthi priya

Mute Stop Video

Security Participants Chat Share Screen Pause/Stop Recording Reactions


End

Invite Mute All Unmute All

Type here to search

09:03 17-06-2020

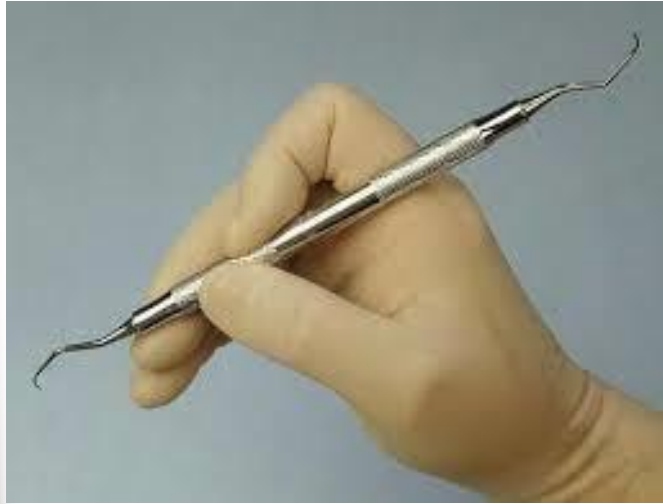1. Identify the instrument
2. 2 points about its uses



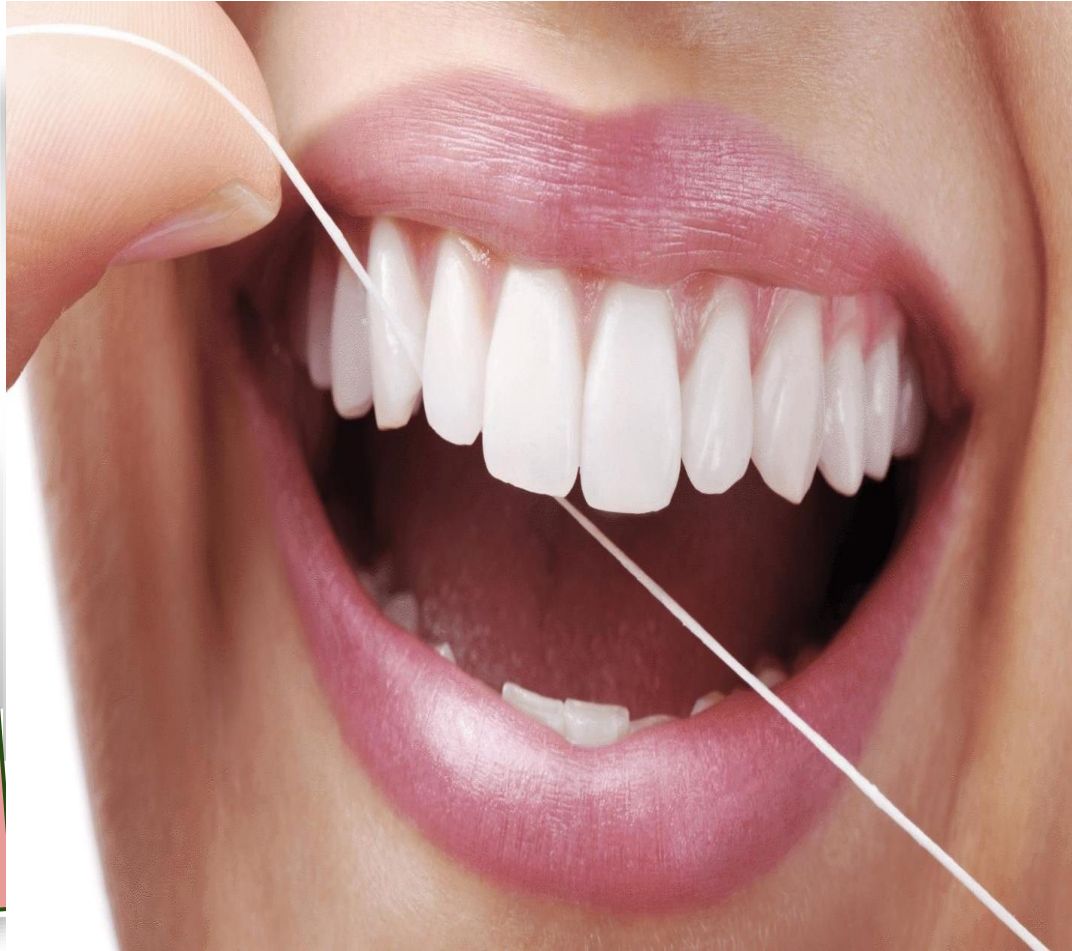1. Identify the instrument
2. Its uses and principles



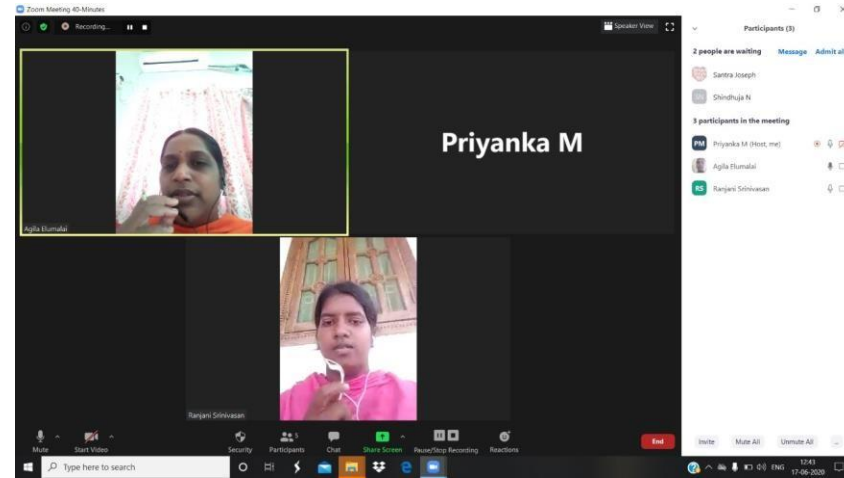
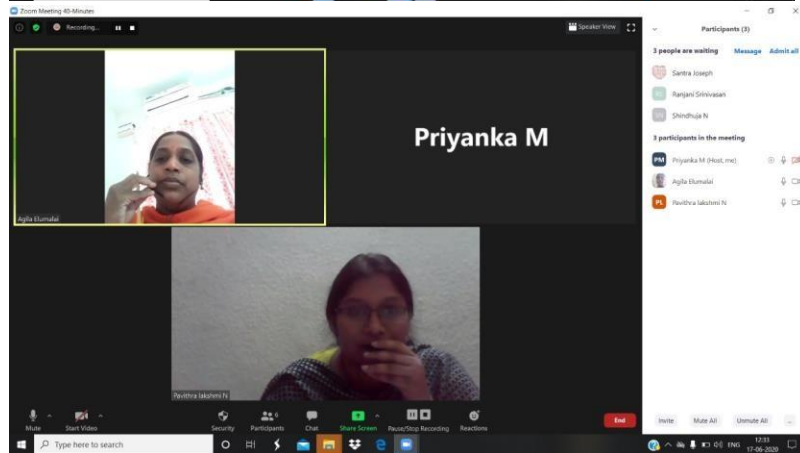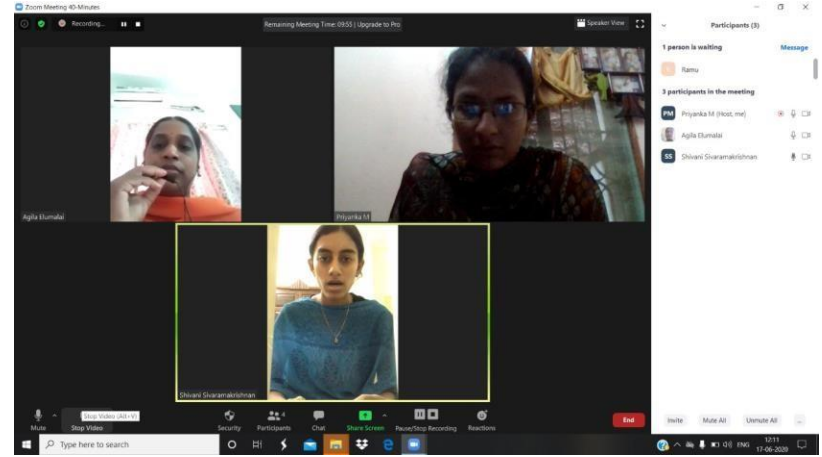
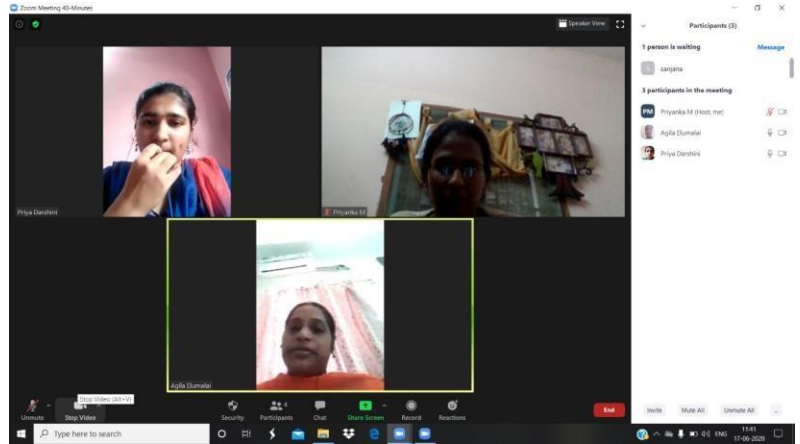
1. Identify the grasp
2. 2 points about the instrumentation process



1. Identify the interdental aid
2. Classification



CLINICAL VIVA AND CASE HISTORY DISCUSSION



**DEPARTMENT OF PERIODONTOLOGY CHETTINAD DENTAL COLLEGE
AND RESEARCH INSTITUTE**

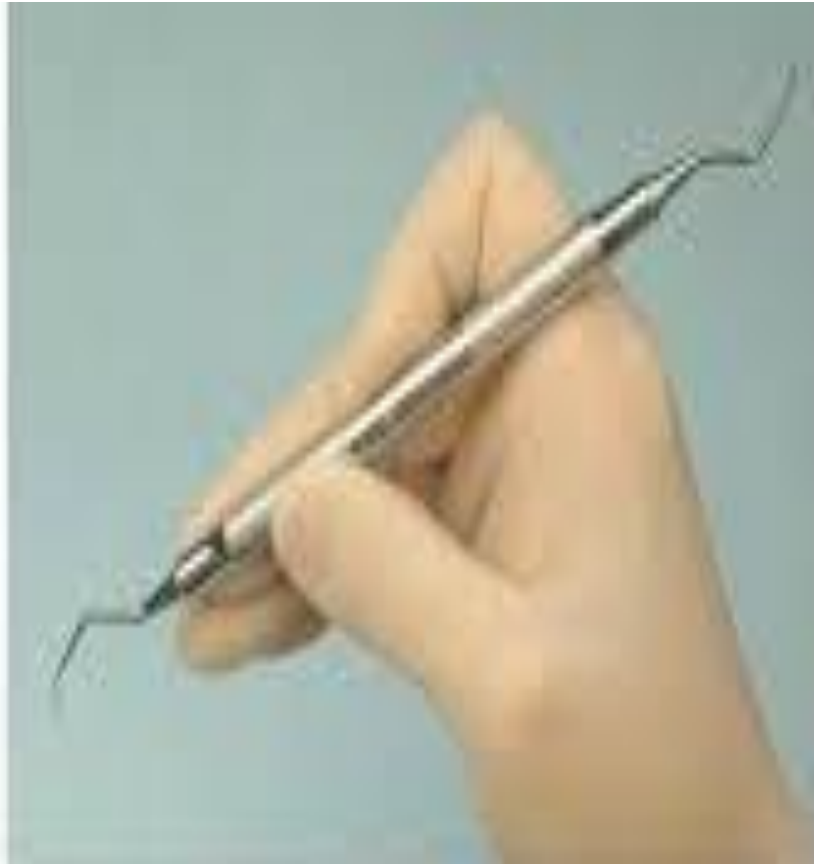FINAL BDS EXAMINATION 17/06/20 – Roll .No SPOTTERS, CASE

DISCUSSION AND VIVA FACULTY – Dr.Aishwarya

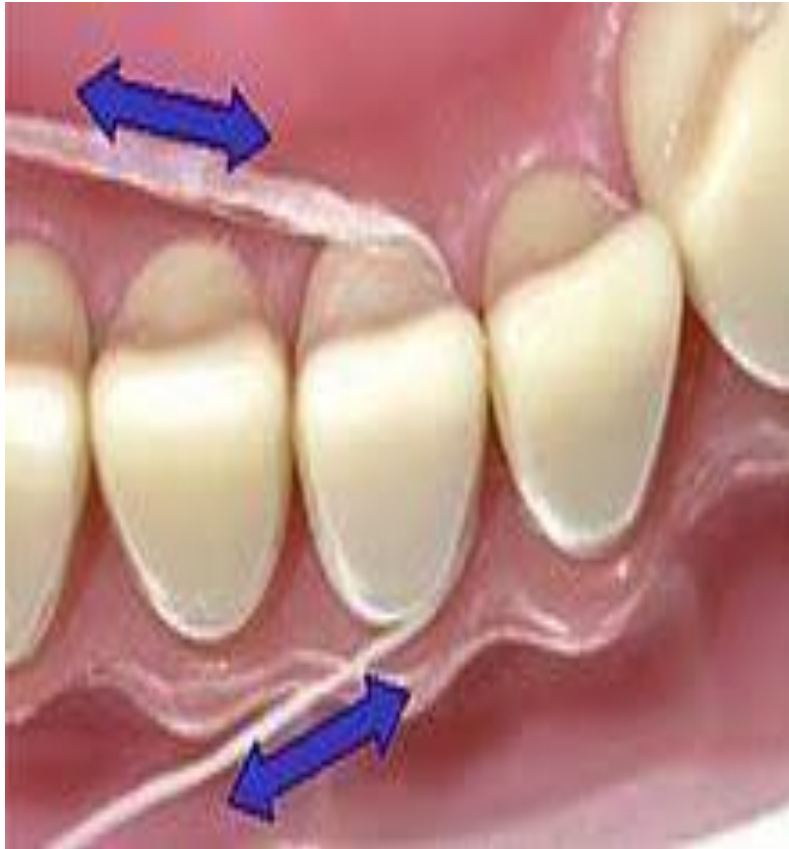SPOTTERS



1. Identify the instrument
2. 2 points about its uses























1. Identify the grasp
2. 2 points about the instrumentation process




1. Identify the interdental aid
2. Classification




CLINICAL VIVA AND CASE HISTORY DISCUSSION




Close	Participants (18)	
SS	Sruthi S	  >
SK	Suba Keerthi	  >
SV	Sureka Varadaraj	  >
	Surya Nandakumar	  >
TS	Tamil Selvan	  >
VV	Varshini Venkat	  >
VP	Vikneshwari P.J	  >
VJ	Vikraman J	  >
VM	Vishalini Mohan	  >
	Yuvarani Muthu Kumar	  >
Invite		




Close




Participants (18)




 Search




 Vikram C (me)  




 Vikram C (host)  




 aishu durai  




 Subashini Natarajan  

 Shweta Ranjith  

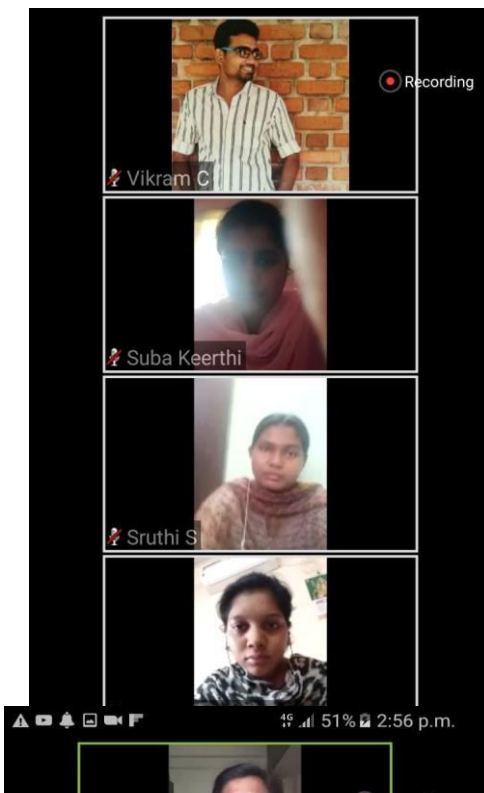 Sneha D  

 Sophia srikanth  

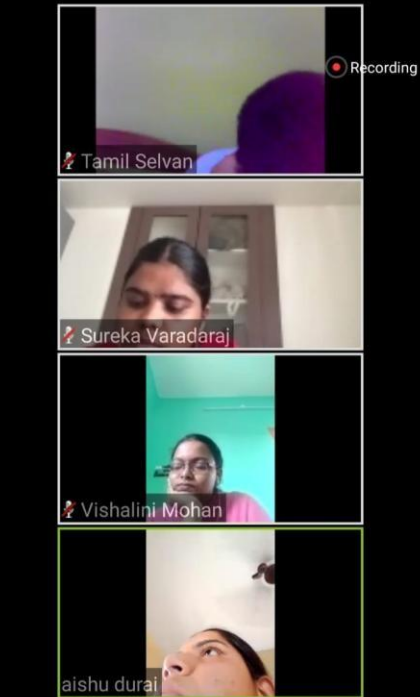
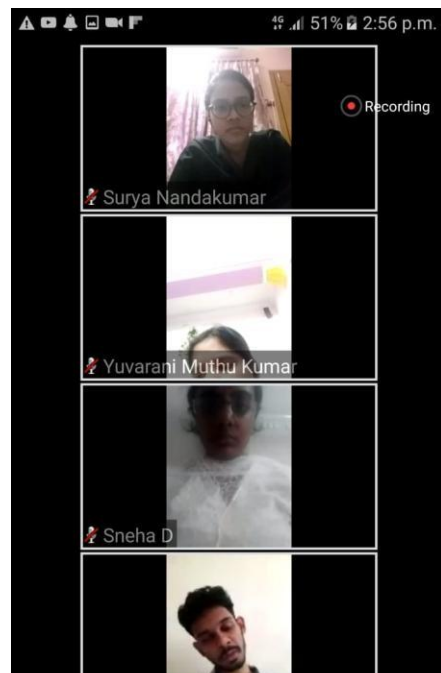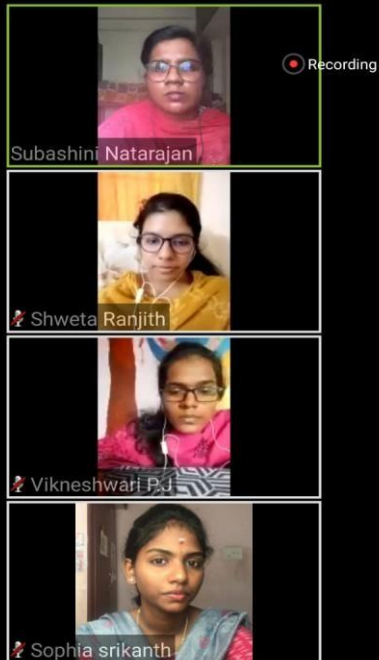 Sowmya Natarajan  

 Sruthi S  




























Invite

































51% 2:56 p.m.





Close Participants (17)		
Search		
	Vikram C (me)	  >
	Vikram C (host)	  >
	aishu durai	  >
	Sruthi S	  >
	Shweta Ranjith	  >
	Sneha D	  >
	Sowmya Natarajan	  >
	Suba Keerthi	  >
	Subashini Natarajan	  >
Invite		

Close Participants (17)		
	Suba Keerthi	  >
	Subashini Natarajan	  >
	Sureka Varadaraj	  >
	Surya Nandakumar	  >
	Tamil Selvan	  >
	Varshini Venkat	  >
	Vikneshwari P.J	  >
	Vikraman J	  >
	Vishalini Mohan	  >
	Yuvarani Muthu Kumar	  >
Invite		