

CHETTINAD DENTAL COLLEGE AND RESEARCH INSTITUTE
DEPARTMENT OF PERIODONTICS AND IMPLANTOLOGY
FINAL YEAR-(29.06.2020 to 04.07.2020)

THEORY E-DISCUSSIONS:

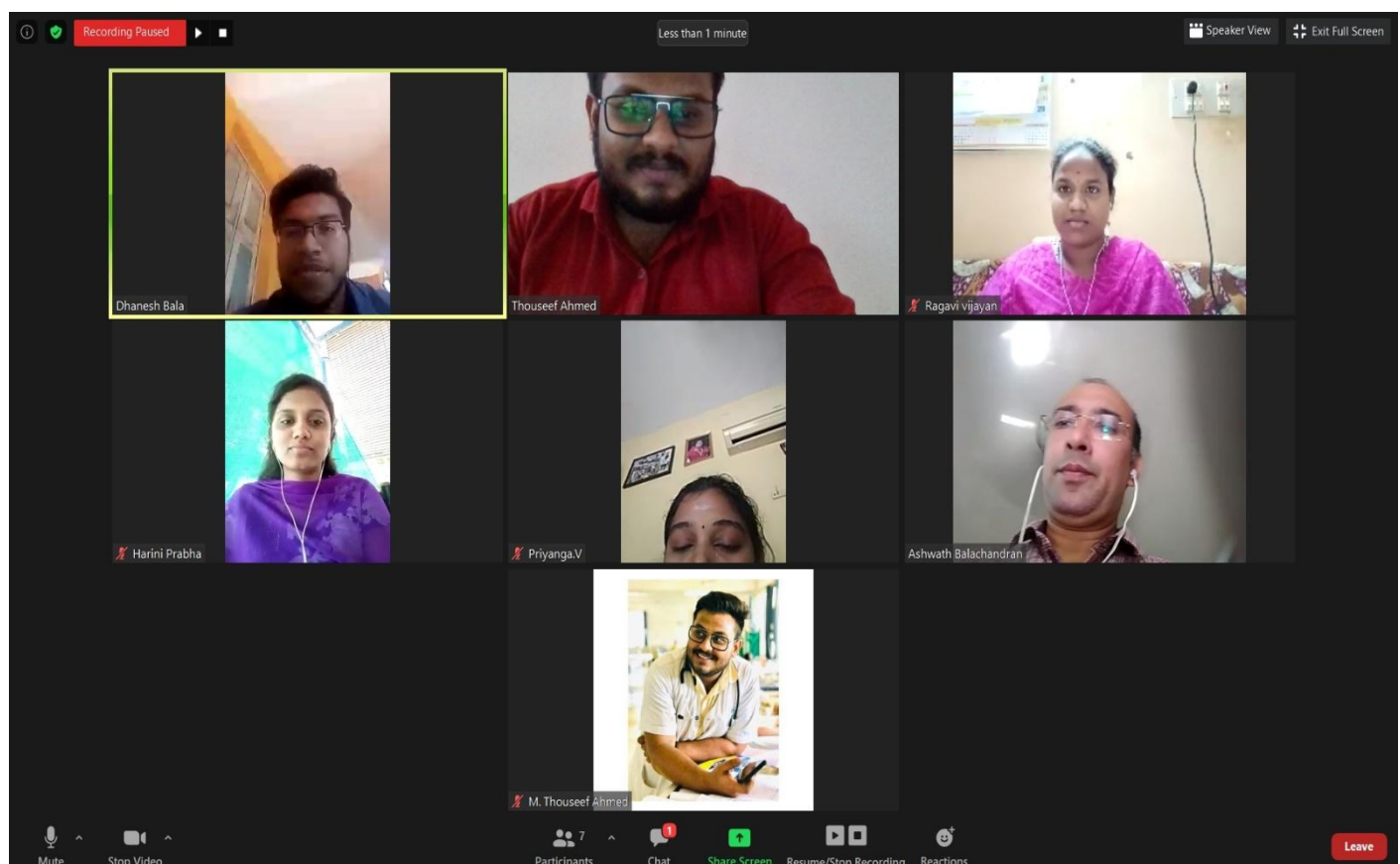
S.No	Date	Lecture topic	Faculty	No.of students participated
1.	03.07.2020	CHRONIC PERIODONTITIS	Dr. ASHWATH	5

CLINICAL E- DISCUSSIONS:








S.No	Date	Lecture topic	Faculty	No.of students participated
1	29/06/2020	SMOKING AND PERIODONTAL DISEASES-AAMINA AFRA	All Faculty	29
2	29/06/2020	ENDO-PERIO LESION - ABINANDHAN	All Faculty	27
3.	30/06/2020	AGGRESSIVE PERIODONITIS-ACHSHAH EVANGELIN RATNA	All Faculty	20
4.	30/06/2020	MECHANICAL PLAQUE CONTROL- THOUSEEF AHAMED	All Faculty	20
5	01/07/2020	TRAUMA FROM OCCLUSION – TAMIL SELVAN	All Faculty	30
6.	03/07/2020	ADVANCED DIAGNOSTIC AIDS-VARSHINI	All Faculty	22
7	03/07/2020	DESQUAMATIVE GINGIVITIS-VIKNESHWARI	All Faculty	22
8.	04/07/2020	CHRONIC PERIODONTITIS-VIKRAMAN	All Faculty	35

THEORY E-DISCUSSION ON 03.07.2020

NAME OF THE TOPIC	CHRONIC PERIODONTITIS
STAFF INCHARGE	Dr.ASHWATH
BATCH	FINAL YEAR SUPPLEMENTARY BATCH



 **Participants (7)**

-  Thouseef Ahmed (Me)
-  M. Thouseef Ahmed (Host)
-  Ashwath Balachandran
-  Dhanesh Bala
-  Harini Prabha
-  Priyanga.V
-  Ragavi vijayan

Recording... You are viewing M. Thouseef Ahmed's screen View Options

CHRONIC PERIODONTITIS

Dhanesh Bala

Unmute Stop Video Participants 7 Chat 1 Share Screen Pause/Stop Recording Reactions Leave

Recording... You are viewing M. Thouseef Ahmed's screen View Options

CLINICAL FEATURES

- Most prevalent in adults but can occur in children and adolescents.(age-35+yrs)
- Supragingival and subgingival plaque accumulation (frequently associated with calculus)
- Gingival inflammation
- Pocket formation
- Loss of periodontal attachment
- Occasional suppuration

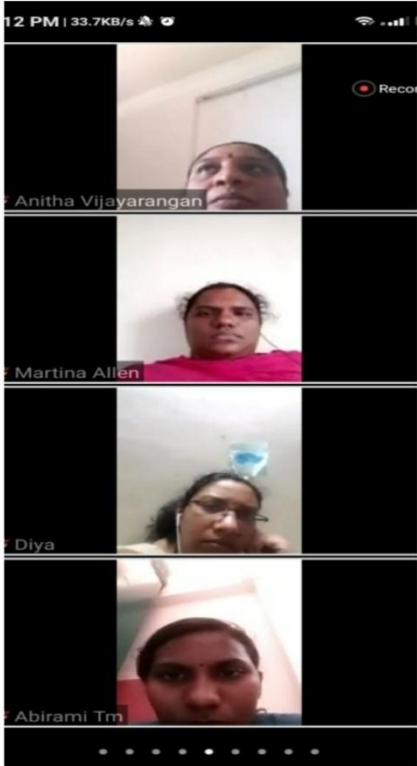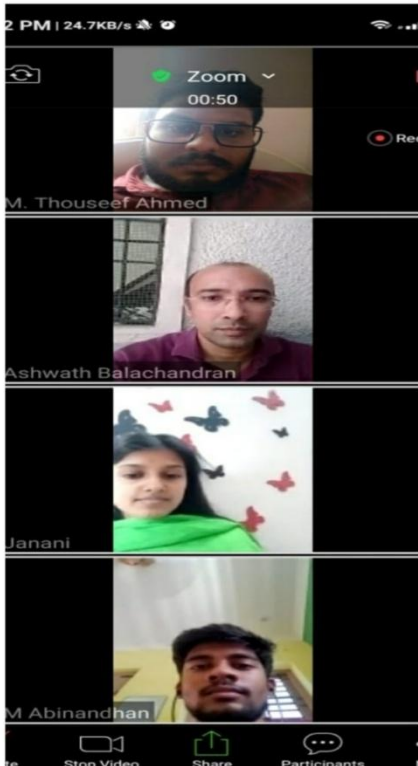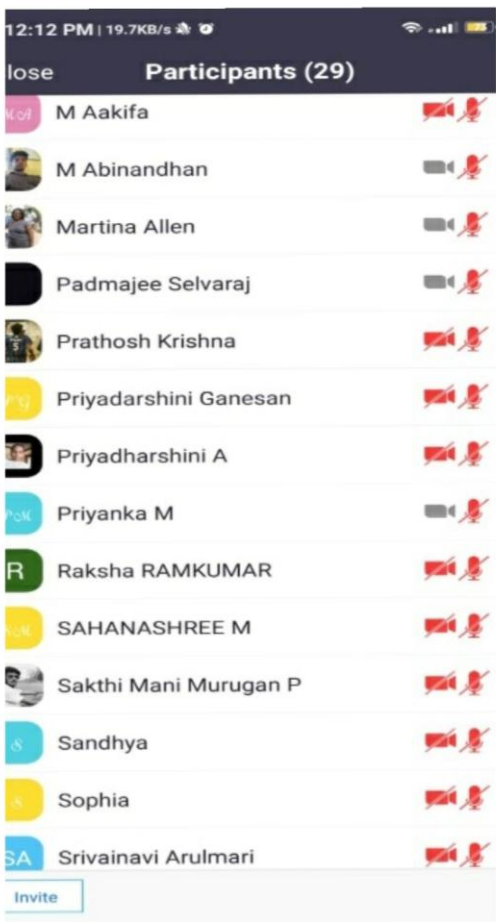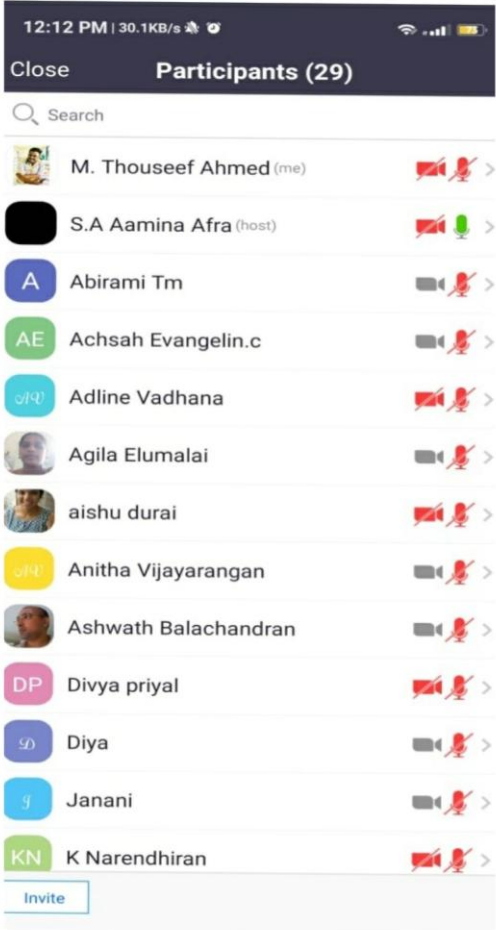


Ashwath Balachandran

Unmute Stop Video Participants 7 Chat 1 Share Screen Pause/Stop Recording Reactions Leave

CLINICAL E-DISCUSSION ON 29.06.2020

NAME OF THE TOPIC	SMOKING AND PERIODONTAL DISEASES-AAMINA
STAFF INCHARGE	ALL FACULTY
BATCH	FINAL YEAR REGULAR& SUPPLEMENTARY BATCH

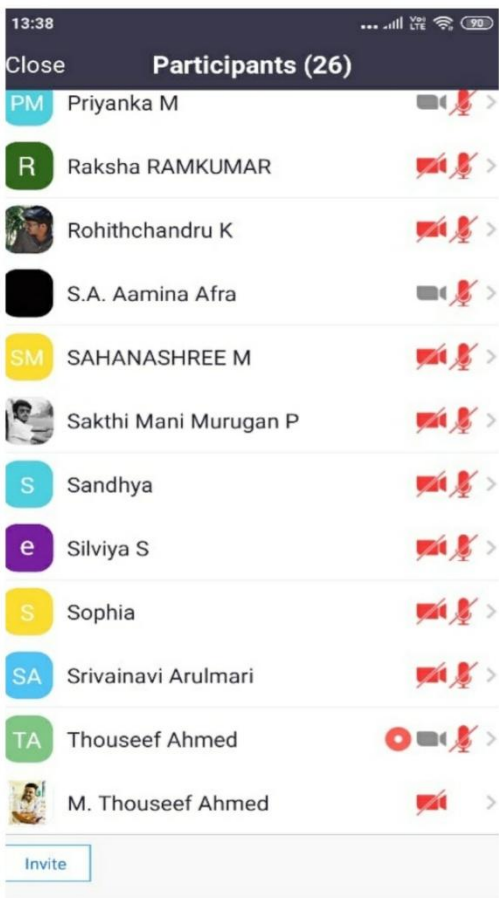
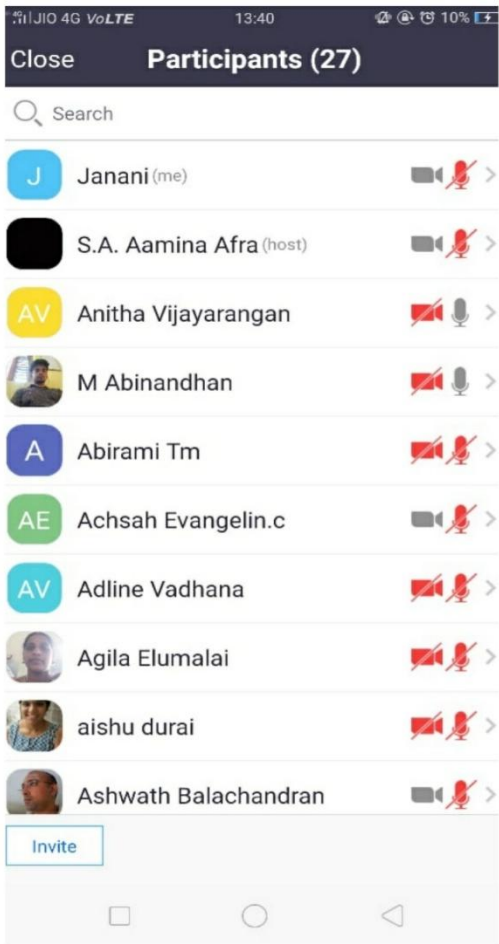



Windows taskbar showing the search bar and several application icons (Edge, File Explorer, Mail, Photos, OneDrive, and Teams).

• • • • • • • • •

CLINICAL E-DISCUSSION ON 29.06.2020

NAME OF THE TOPIC	ENDO-PERIO LESION -ABINANDHAN
STAFF INCHARGE	ALL FACULTY
BATCH	FINAL YEAR REGULAR & SUPPLEMENTARY BATCH





Classification

- By Simon et al 1972
 - primary endodontic lesions,
 - primary endodontic lesions with secondary periodontal involvement,
 - primary periodontal lesions,
 - primary periodontal lesions with secondary endodontic involvement,
 - true combined lesions.

12 PM | 33.5KB/s


Record


Record


Record


Record


Padmajee Selvaraj


Priyanka M


Agila Elumalai


Achsah Evangelin.c

2:12 PM | 33.7KB/s


Record


Record


Record

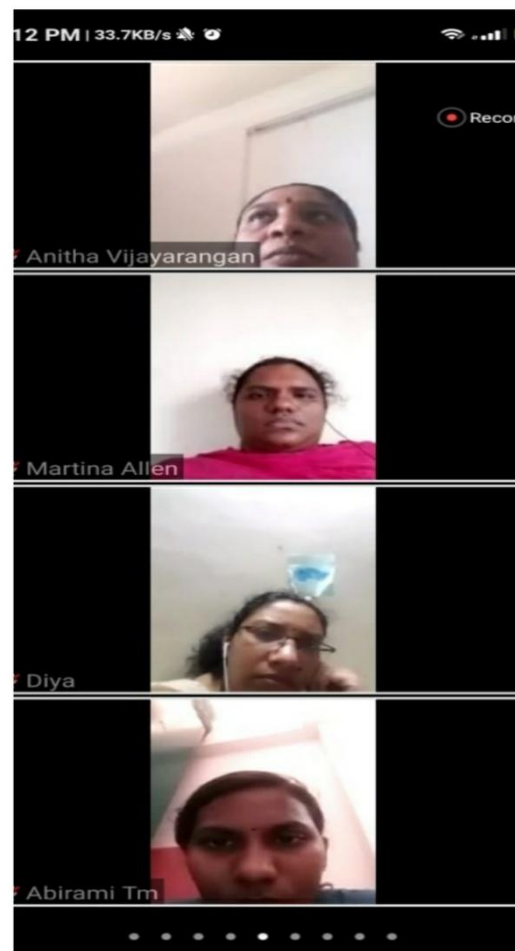
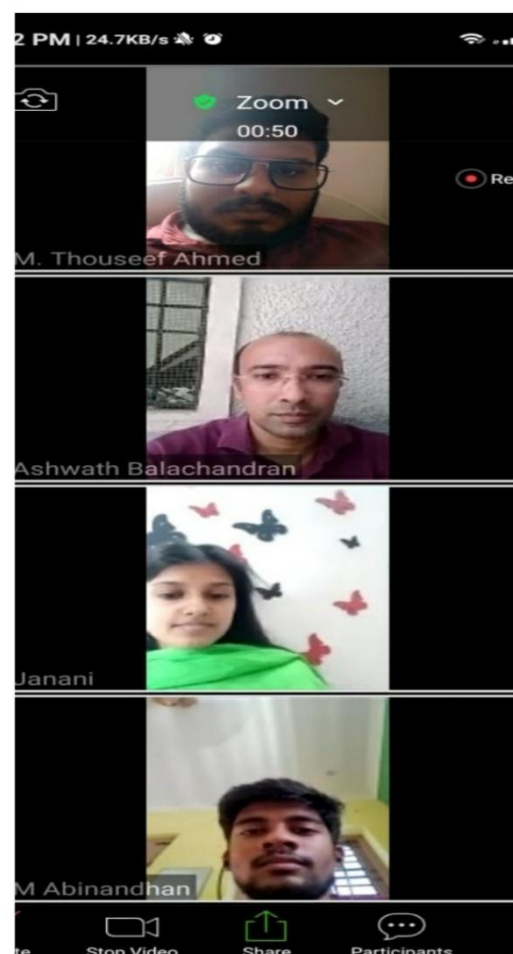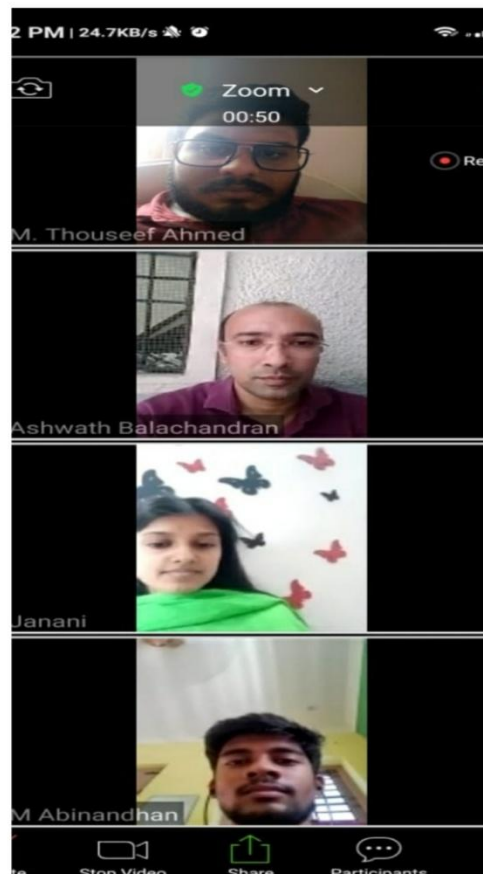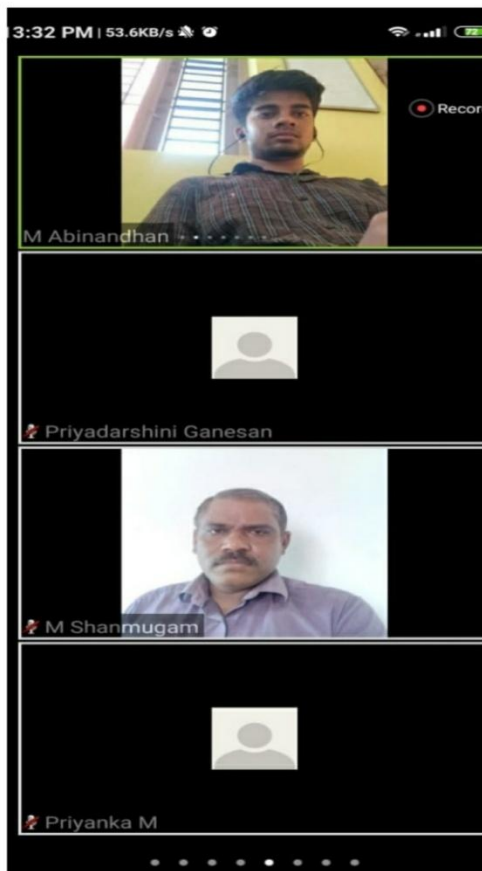Record

S.A Aamina Afra

S.A. Aamina Afra













M Aakifa

Raksha RAMKUMAR



CLINICAL E-DISCUSSION ON 30.06.2020

NAME OF THE TOPIC	AGGRESSIVE PERIODONTITIS- ACHSHAH EVANGELIN RATNA
STAFF INCHARGE	ALL FACULTY
BATCH	FINAL YEAR REGULAR & SUPPLEMENTARY BATCH

 M Abinandhan (me)	 Martina Allen
 Padmajee Selvaraj (host)	 Prathosh Krishna
 Achsah Evangelin.c	 PG Priyadarshini Ganesan
 Abirami Tm	 Priyadarshini A
 AV Adline Vadhana	 PM Priyanka M
 Agila Elumalai	 R Raksha RAMKUMAR
 AV Anitha Vijayarangan	 Rohithchandru K
 Ashwath Balachandran	 S.A. Aamina Afra
 D Diya	 SM SAHANASHREE M
 J Janani	 e Silviya S
 KN K Narendhiran	 S Sophia
 MA M Aakifa	 SA Srivainavi Arulmari
 M Shanmugam	 TA Thouseef Ahmed



Janani




Martina Allen




M. Thouseef Ahmed




Rohithchandru K




Adline Vadhana



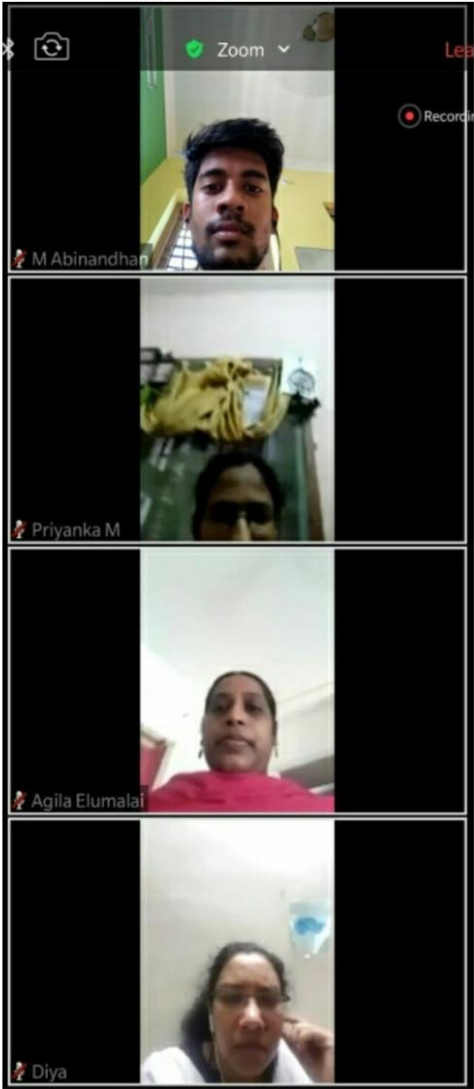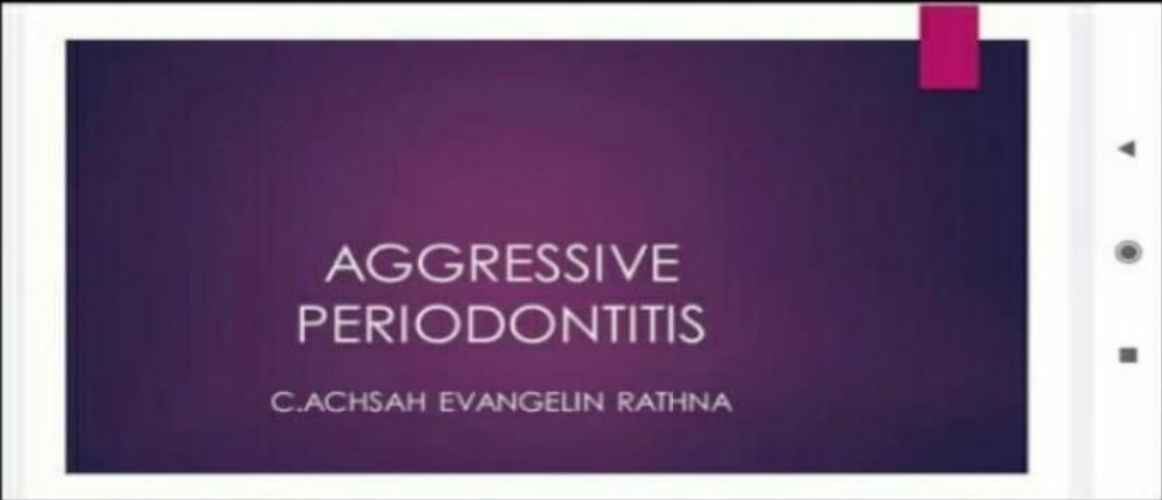
Priyadarshini A



Sophia

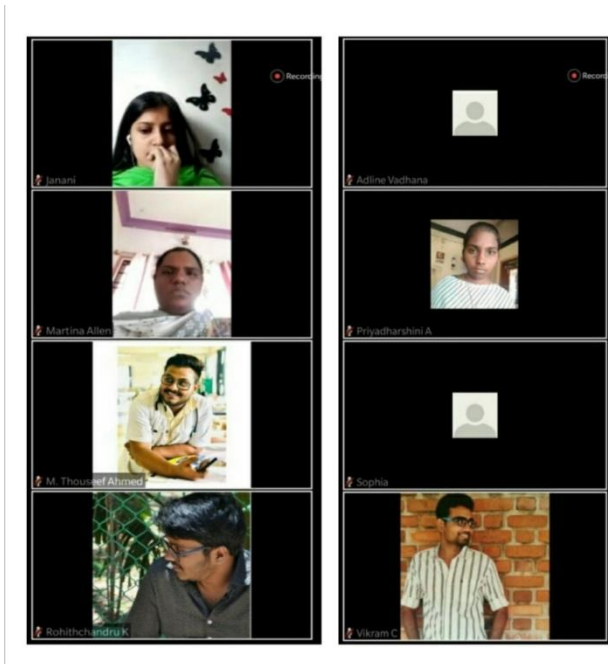
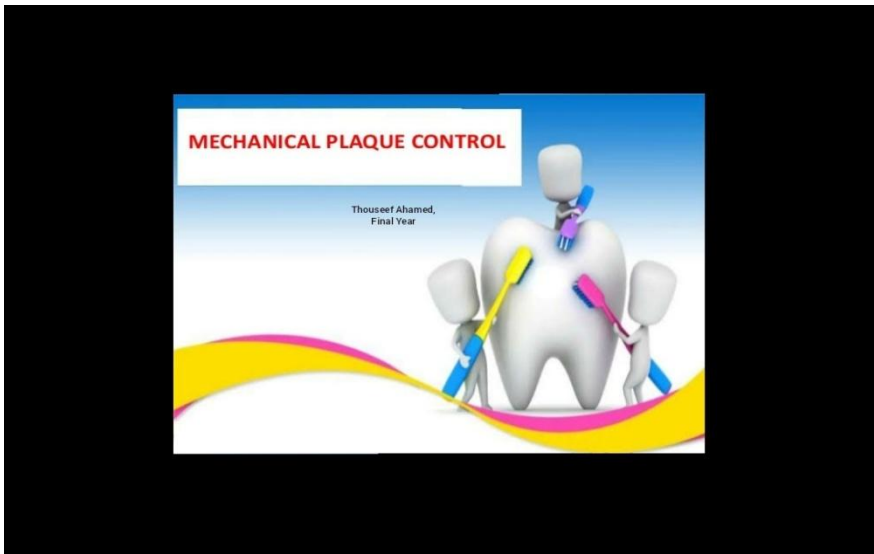
































Vikram C



CLINICAL E-DISCUSSION ON 30.06.2020

NAME OF THE TOPIC	MECHANICAL PLAQUE CONTROL- THOUSEEF AHAMED
STAFF INCHARGE	ALL FACULTY
BATCH	FINAL YEAR REGULAR & SUPPLEMENTARY BATCH



 M Abinandhan (me)	 	 Martina Allen	 
 Padmajee Selvaraj (host)	 	 Prathosh Krishna	 
 Achsah Evangelin.c	 	 PG Priyadarshini Ganesan	 
 A Abirami Tm	 	 Priyadharshini A	 
 AV Adline Vadhana	 	 PM Priyanka M	 
 Agila Elumalai	 	 R Raksha RAMKUMAR	 
 AV Anitha Vijayarangan	 	 Rohithchandru K	 
 Ashwath Balachandran	 	 S.A. Aamina Afra	 
 D Diya	 	 SM SAHANASHREE M	 
 J Janani	 	 e Silviya S	 
 KN K Narendhiran	 	 S Sophia	 
 MA M Aakifa	 	 SA Srivainavi Arulmari	 
 M Shanmugam	 	 TA Thouseef Ahmed	 
 M. Thouseef Ahmed	 	 Vikram C	 

CLINICAL E-DISCUSSION ON 01.07.2020

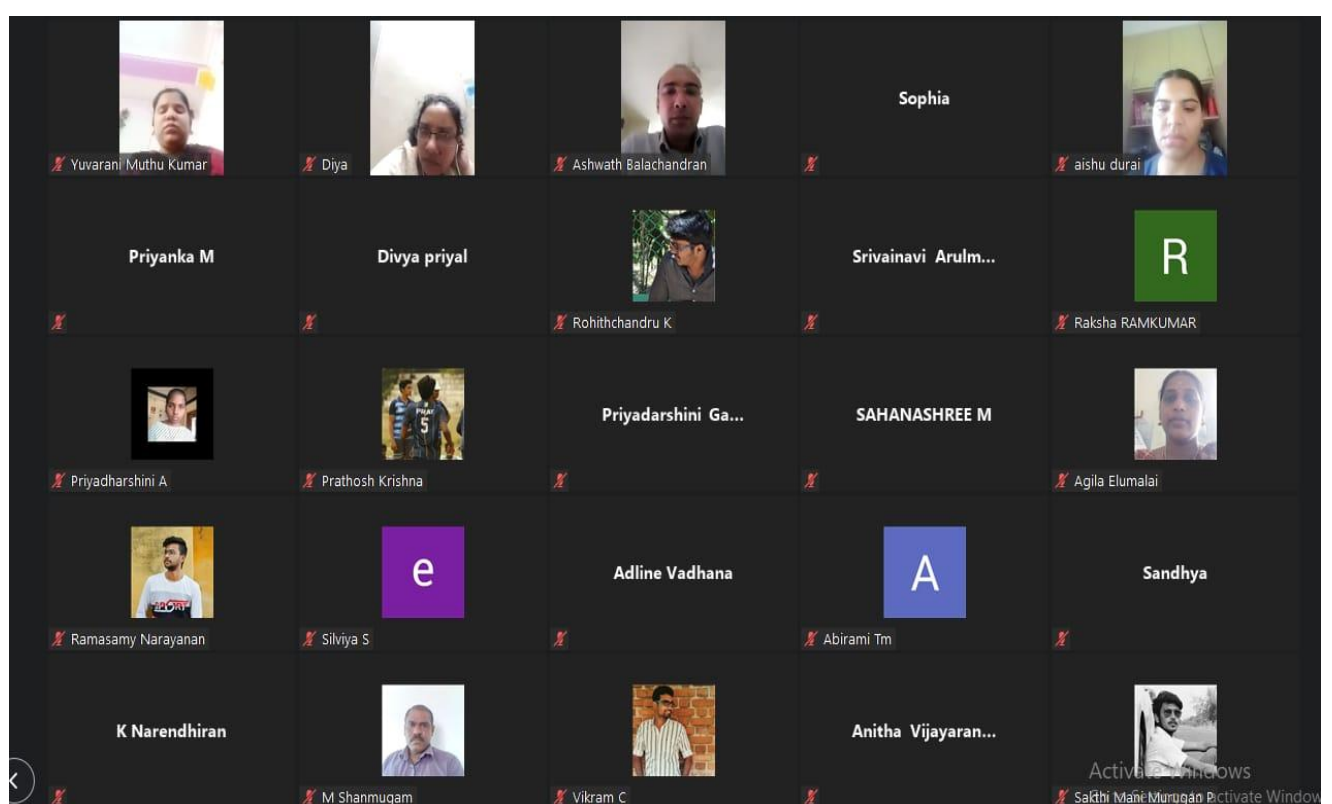
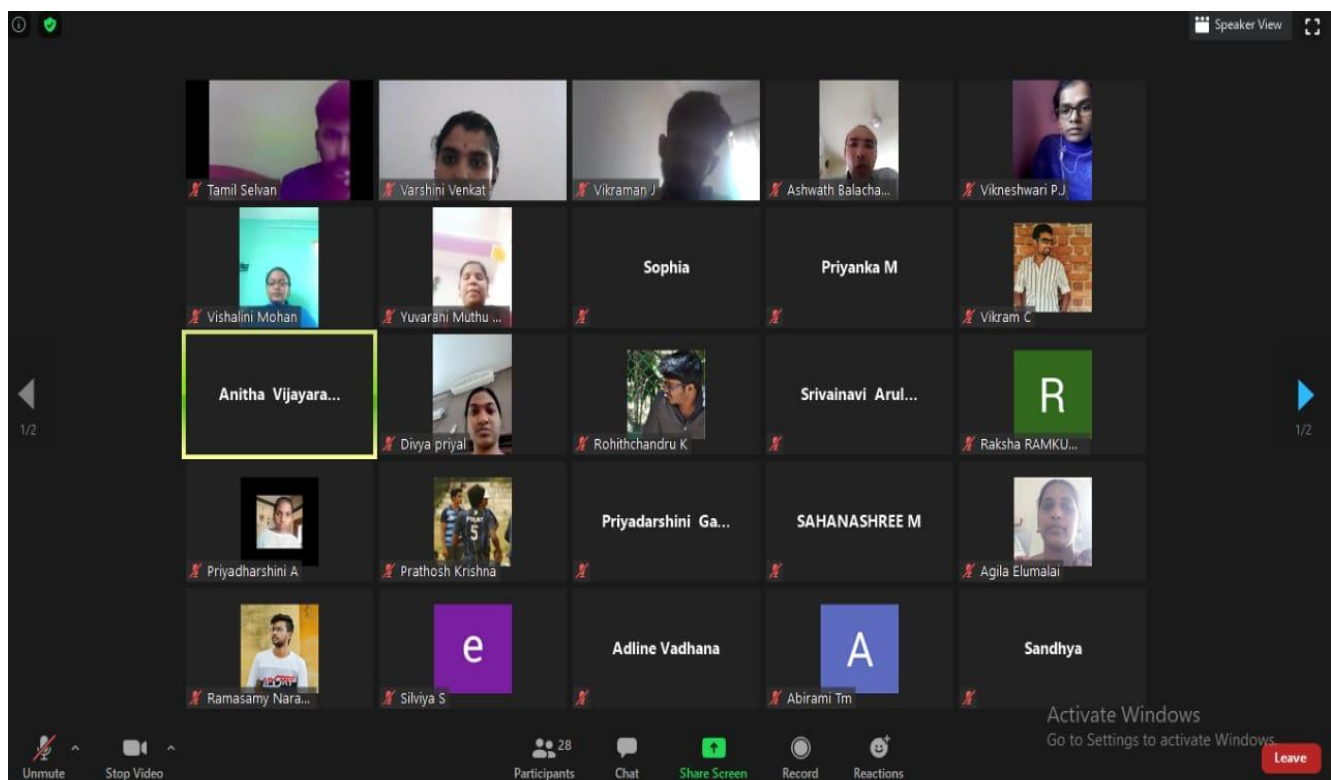
NAME OF THE TOPIC	TRAUMA FROM OCCLUSION – TAMIL SELVAN
STAFF INCHARGE	ALL FACULTY
BATCH	FINAL YEAR REGULAR BATCH

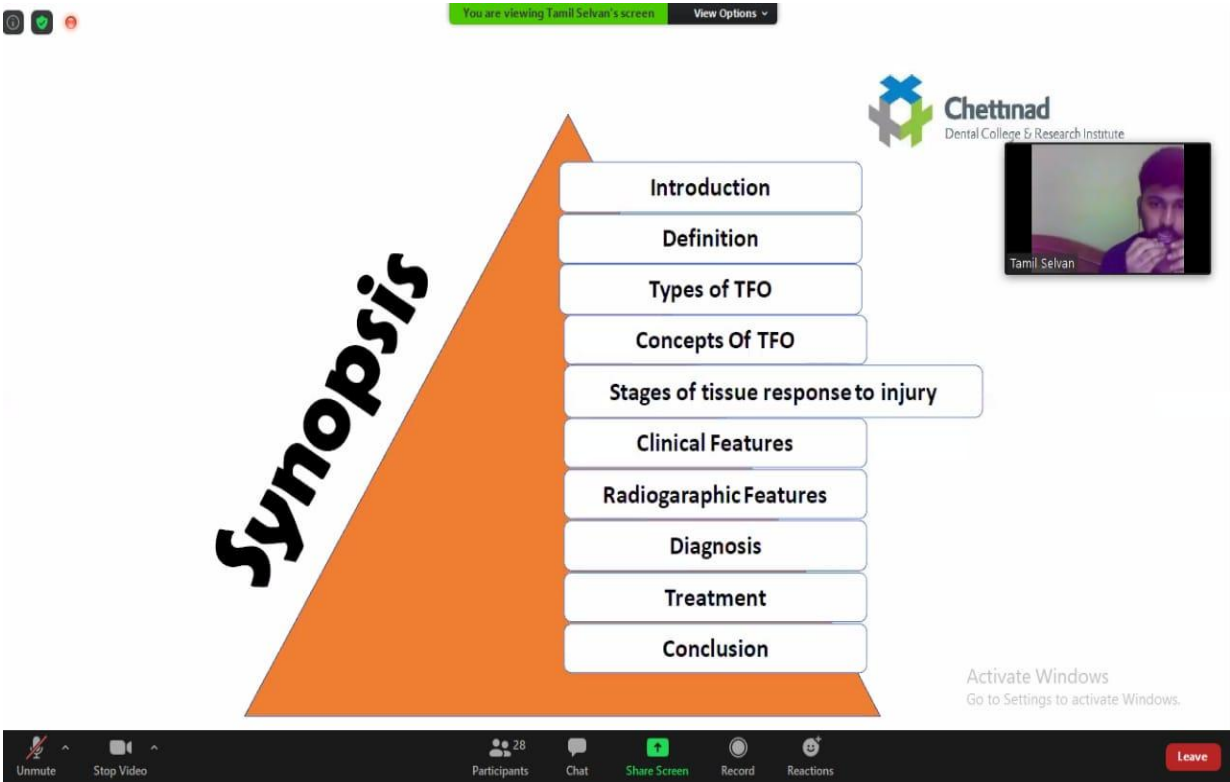
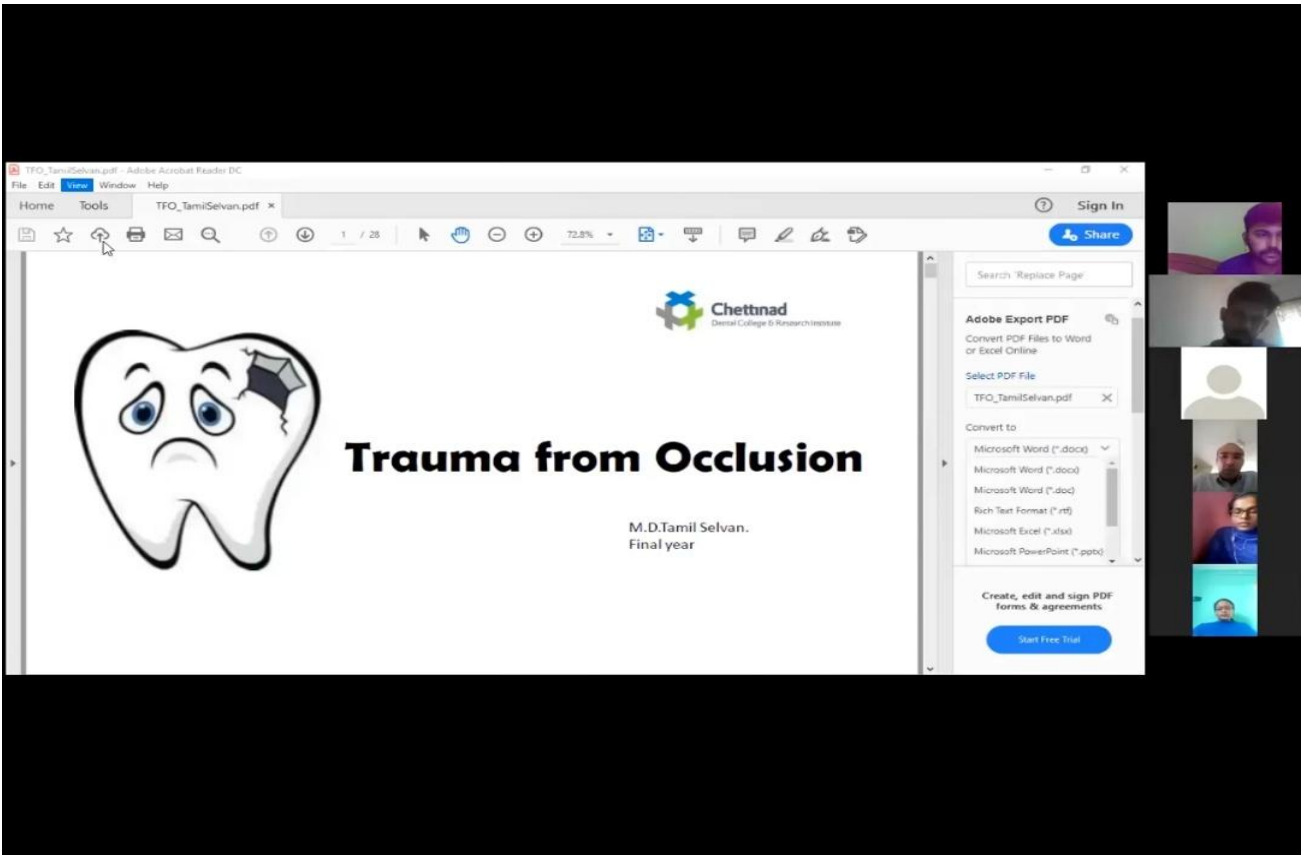
Close	Participants (30)
	Search
VP	Vikneshwari P.J (me)
TS	Tamil Selvan (host)
A	Abirami Tm
AV	Adline Vadhana
	Agila Elumalai
	aishu durai
AV	Anitha Vijayarangan
	Ashwath Balachandran
DP	Divya priyal
D	Diya
KN	K Narendhiran
	M Shanmugam
	Prathosh Krishna
	Invite

Close	Participants (30)
PG	Priyadarshini Ganesan
	Priyadarshini A
PM	Priyanka M
R	Raksha RAMKUMAR
	Ramasamy Narayanan
	Rohithchandru K
SM	SAHANASHREE M
	Sakthi Mani Murugan P
S	Sandhya
e	Silviya S
S	Sophia
SA	Srivainavi Arulmari
VV	Varshini Venkat
	Vikram C
	Invite

Close	Participants (30)
PG	Priyadarshini Ganesan
	Priyadarshini A
PM	Priyanka M
R	Raksha RAMKUMAR
	Ramasamy Narayanan
	Rohithchandru K
SM	SAHANASHREE M
	Sakthi Mani Murugan P
S	Sandhya
e	Silviya S
S	Sophia
SA	Srivainavi Arulmari
VV	Varshini Venkat
	Vikram C
	Invite

Close	Participants (30)
R	Raksha RAMKUMAR
	Ramasamy Narayanan
	Rohithchandru K
SM	SAHANASHREE M
	Sakthi Mani Murugan P
S	Sandhya
e	Silviya S
S	Sophia
SA	Srivainavi Arulmari
VV	Varshini Venkat
	Vikram C
VJ	Vikraman J
VM	Vishalini Mohan
	Yuvarani Muthu Kumar
	Invite





NAME OF THE TOPIC	ADVANCED DIAGNOSTIC AIDS- VARSHINI
STAFF INCHARGE	ALL FACULTY
BATCH	FINAL YEAR REGULAR BATCH

CLINICAL E-DISCUSSION ON 03.07.2020

Close

Participants (22)

Q Search

VP

Vikneshwari P.J (me)

TS

Tamil Selvan (host)

VV

Varshini Venkat

A

Abirami Tm

AV

Adline Vadhana

Agila Elumalai

aishu durai

AV

Anitha Vijayarangan

Ashwath Balachandran

DP

Divya priyal

D

Diya

KN

K Narendhiran

M Shanmugam

Invite

Close

Participants (22)

Ashwath Balachandran

DP

Divya priyal

D

Diya

KN

K Narendhiran

M Shanmugam

Pavithra G

PM

Priyanka M

e

Silviya S

S

Sophia

SA

Srivainavi Arulmari

Vikram C

VJ

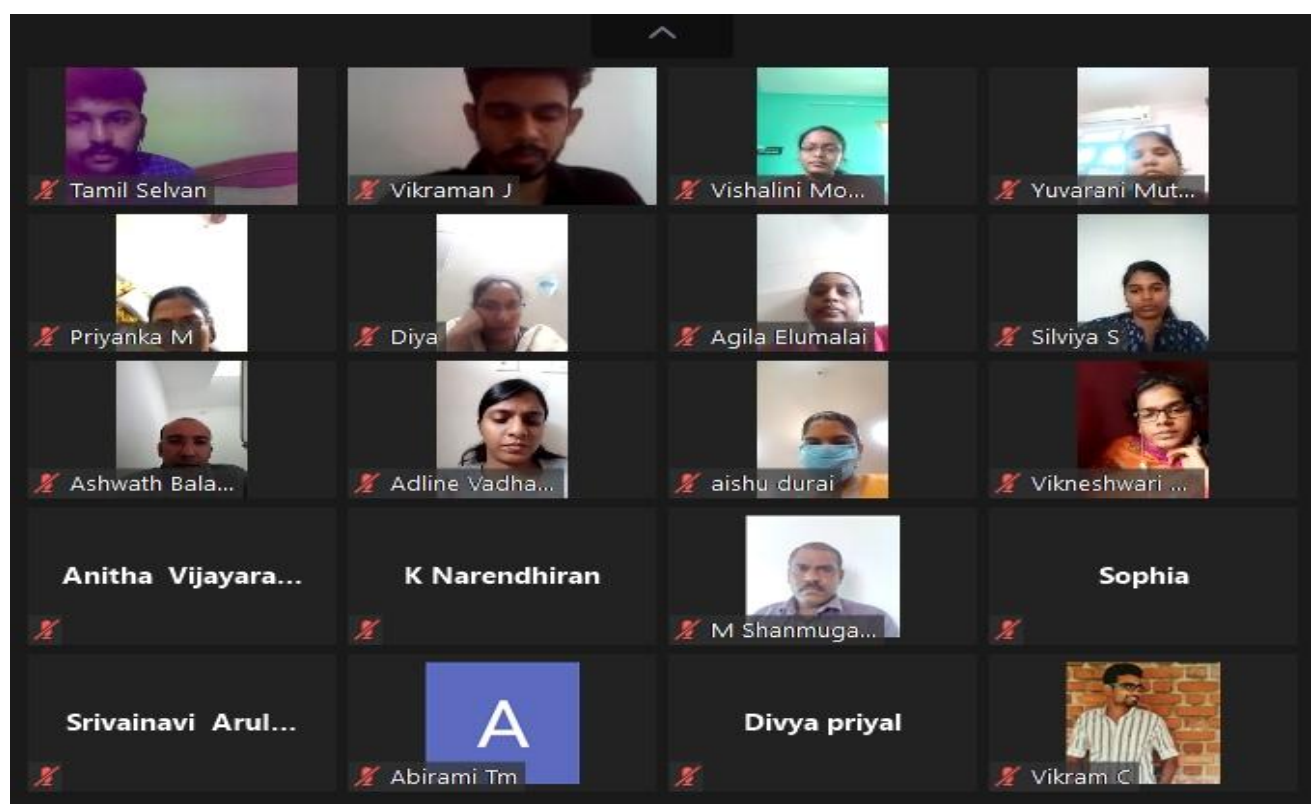
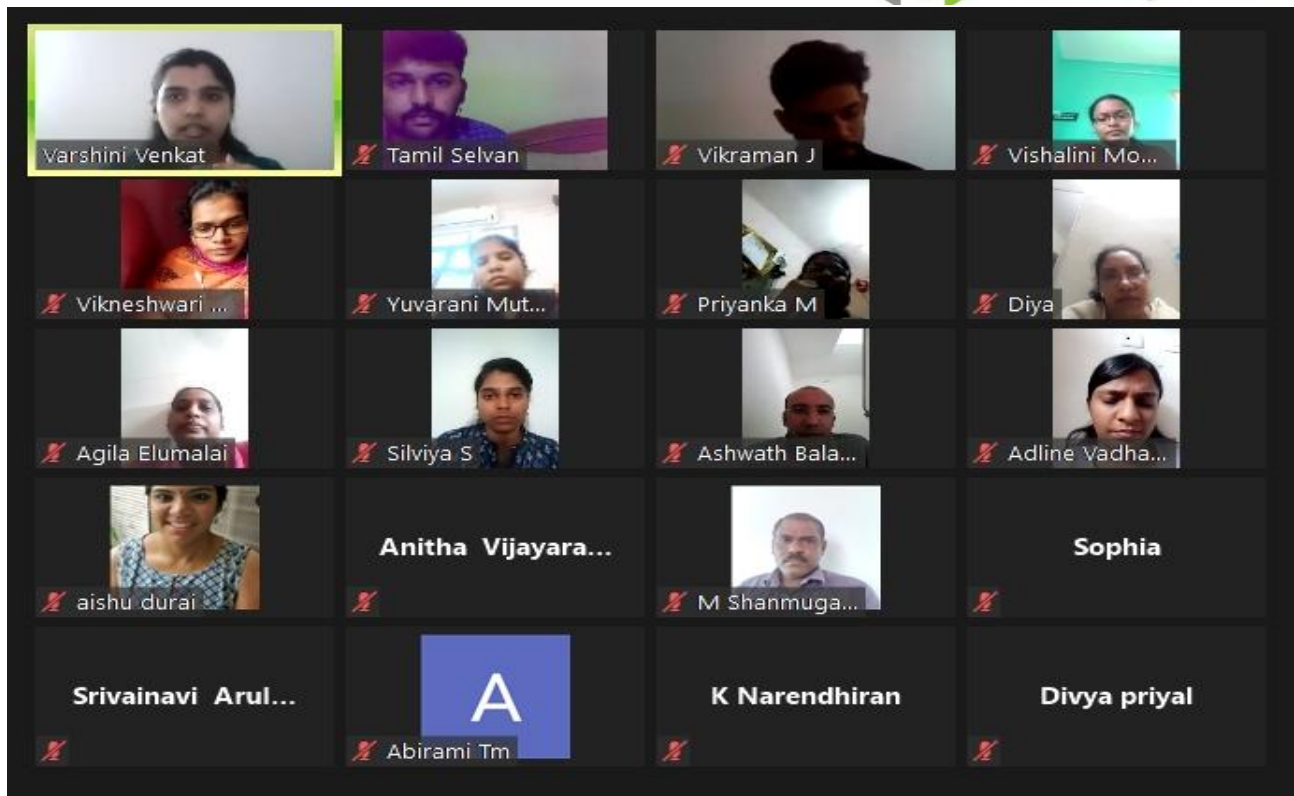
Vikraman J

VM

Vishalini Mohan

Yuvarani Muthu Kumar

Invite



Zoom Meeting 40-Minutes

You are viewing Varshini Venkat's screen

View Options

00:04:22

Speaker View

institute

ADVANCED DIAGNOSTIC TECHNIQUES IN PERIODONTICS

V.VARSHINI, IV YR BDS

HEALTHY GUM

GINGIVITIS

PERIODONTITIS

Chettinad Dental College & Research Institute

Varshini Venkat

Tamil Selvan

Vikraman J

Vishalini Mohan

Unmute

Stop Video

Security

Participants 9

Chat

Share Screen

Record

Reactions

End

Zoom Meeting 40-Minutes


You are viewing Varshini Venkat's screen

View Options


00:14:26

Speaker View

FLORIDA PROBE



FP Handpiece tip as it enters the sulcus



Tip of probe with constant force at the bottom of sulcus and sleeve properly positioned at the top of gingival margin allowing the computer to detect the difference

Varshini Venkat

Tamil Selvan

Vikraman J

Vishalini Mo...

Vikneshwari ...

Unmute

Stop Video

Security

Participants 21

Chat

Share Screen

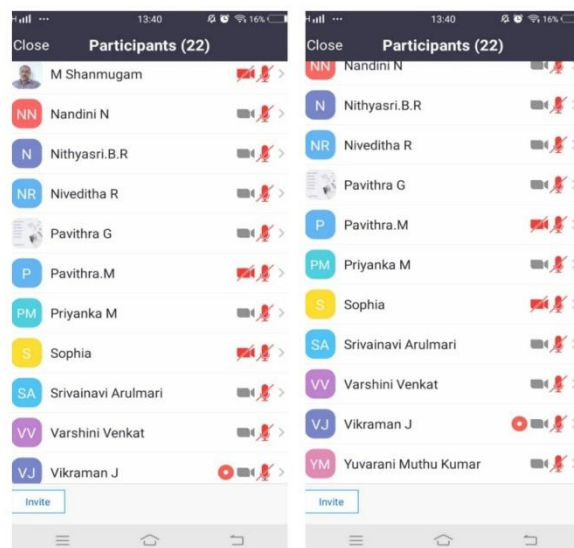
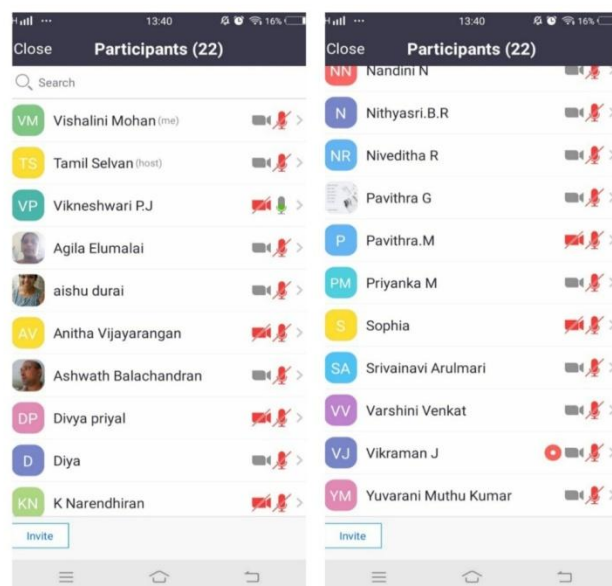
Record













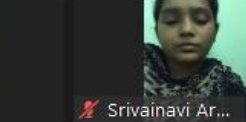



Reactions















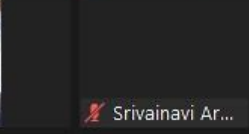
End

CLINICAL E-DISCUSSION ON 03.07.2020

NAME OF THE TOPIC	DESQUAMATIVE GINGIVITIS- VIKNESHWARI
STAFF INCHARGE	ALL FACULTY
BATCH	FINAL YEAR REGULAR BATCH



 Vikraman J	 Tamil Selvan	 Varshini Venk...	 Vishalini Mo...	 Agila Elumalai
 Yuvarani Mut...	 Diya	 Pavithra G	 Priyanka M	 Ashwath Bala...
 Niveditha R	 aishu durai	 Srivainavi Ar...	 Nandini N	 Nithyasri.B.R
Vikneshwari P.J	Pavithra.M	K Narendhiran	Anitha Vijayara...	Divya priyal
Sophia		 M Shanmuga...		

 Vikraman J	 Tamil Selvan	 Varshini Venk...	 Vishalini Mo...	 Agila Elumalai
 Yuvarani Mut...	 Diya	 Pavithra G	 Priyanka M	 Ashwath Bala...
 Niveditha R	 Nandini N	 Nithyasri.B.R	 aishu durai	 Srivainavi Ar...
Vikneshwari P.J	Pavithra.M	K Narendhiran	Anitha Vijayara...	Divya priyal
Sophia				

Zoom Meeting 40-Minutes

You are viewing Varshini Venkat's screen

View Options

00:05:43

Speaker View


Institute

DESQUAMATIVE GINGIVITIS

P.J.VIKNESHWARI
FINAL YEAR

Chettinad

Dental College & Research Institute



Unmute

Stop Video

Security

Participants 13

Chat

Share Screen

Record

Reactions

End

Anitha Vijayara...

Tamil Selvan

Varshini Venk...

Vishalini Mo...

Vikneshwari...

Zoom Meeting 40-Minutes

You are viewing Varshini Venkat's screen


View Options

00:09:32

Speaker View

3 forms of Desquamative gingivitis

- Glickman and smulow



Unmute

Stop Video

Security

Participants 19

Chat

Share Screen

Record

Reactions

End

Vikneshwari P.J

Tamil Selvan

Varshini Venk...

Vishalini Mo...

Agila Elumalai

CLINICAL E-DISCUSSION ON 03.07.2020

NAME OF THE TOPIC	CHRONIC PERIODONTITIS- VIKRAMAN
STAFF INCHARGE	ALL FACULTY
BATCH	FINAL YEAR REGULAR BATCH

Close

Participants (35)

Search

VP

Vikneshwari P.J (me)

TS

Tamil Selvan (host)

VJ

Vikraman J

A

Abirami Tm

AV

Adline Vadhana

Agila Elumalai

aishu durai

AV

Anitha Vijayarangan

Ashwath Balachandran

DP

Divya priyal

D

Diya

KN

K Narendhiran

M Shanmugam

Invite

Close

Participants (35)

NN

Nandini N

Narendhar Sreedharan

N

Nithyasri.B.R

NR

Niveditha R

PV

P vishanth

Pavithra G

P

Pavithra.M

PM

Priyanka M

Ramasamy Narayanan

Revanth Kumar

Sidhaarth R

e

Silviya S

SB

Sonu Bantiya

S

Sophia

Invite

Close

Participants (35)

NN

Nandini N

Narendhar Sreedharan

N

Nithyasri.B.R

NR

Niveditha R

PV

P vishanth

Pavithra G

P

Pavithra.M

PM

Priyanka M

Ramasamy Narayanan

Revanth Kumar

Sidhaarth R

e

Silviya S

SB

Sonu Bantiya

S

Sophia

Invite

Close

Participants (35)

Ramasamy Narayanan

Revanth Kumar

Sidhaarth R

e

Silviya S

SB

Sonu Bantiya

S

Sophia

SR

Sriharika Raavi

SA

Srivainavi Arulmari

SS

Sruthi S

Subhashini Raju

VV

Varshini Venkat

VR

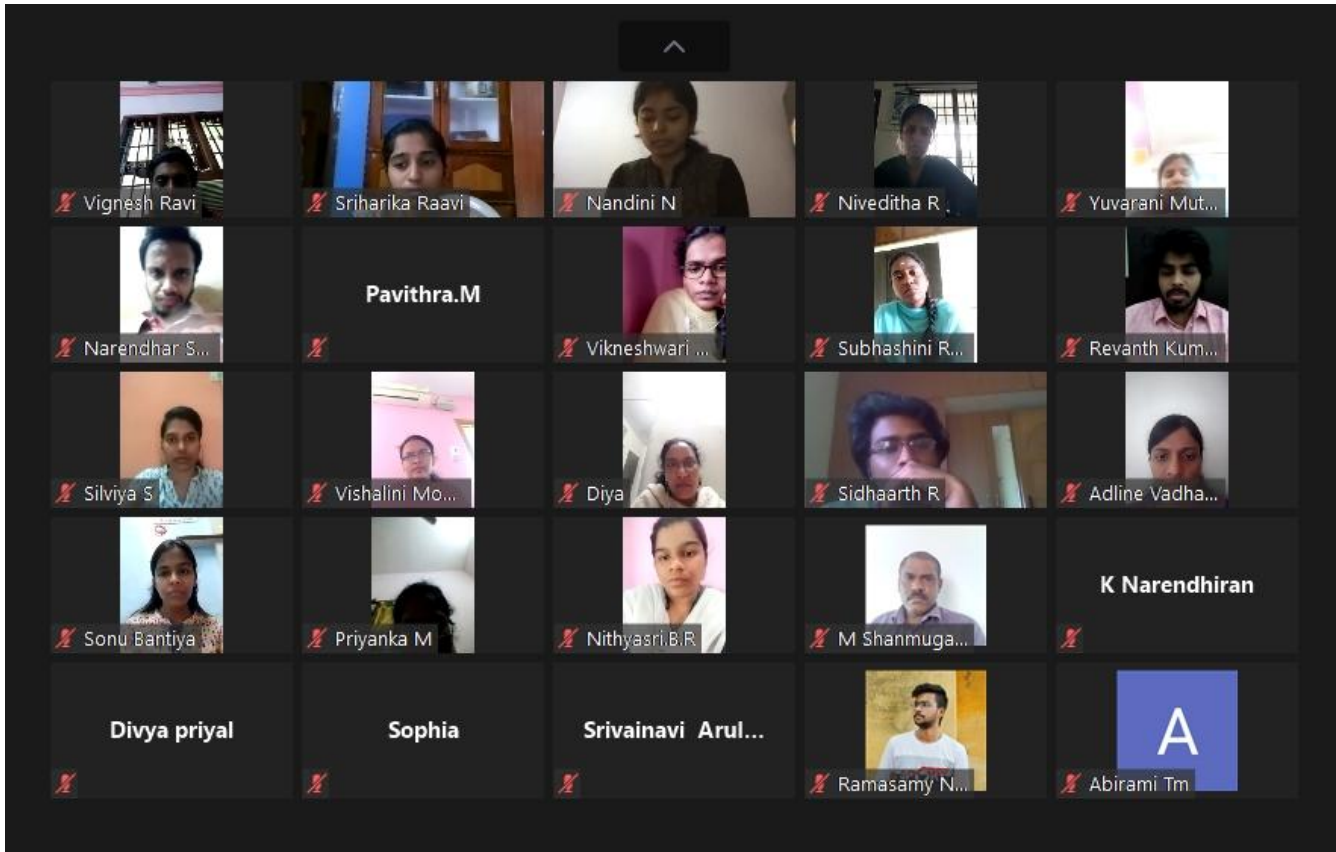
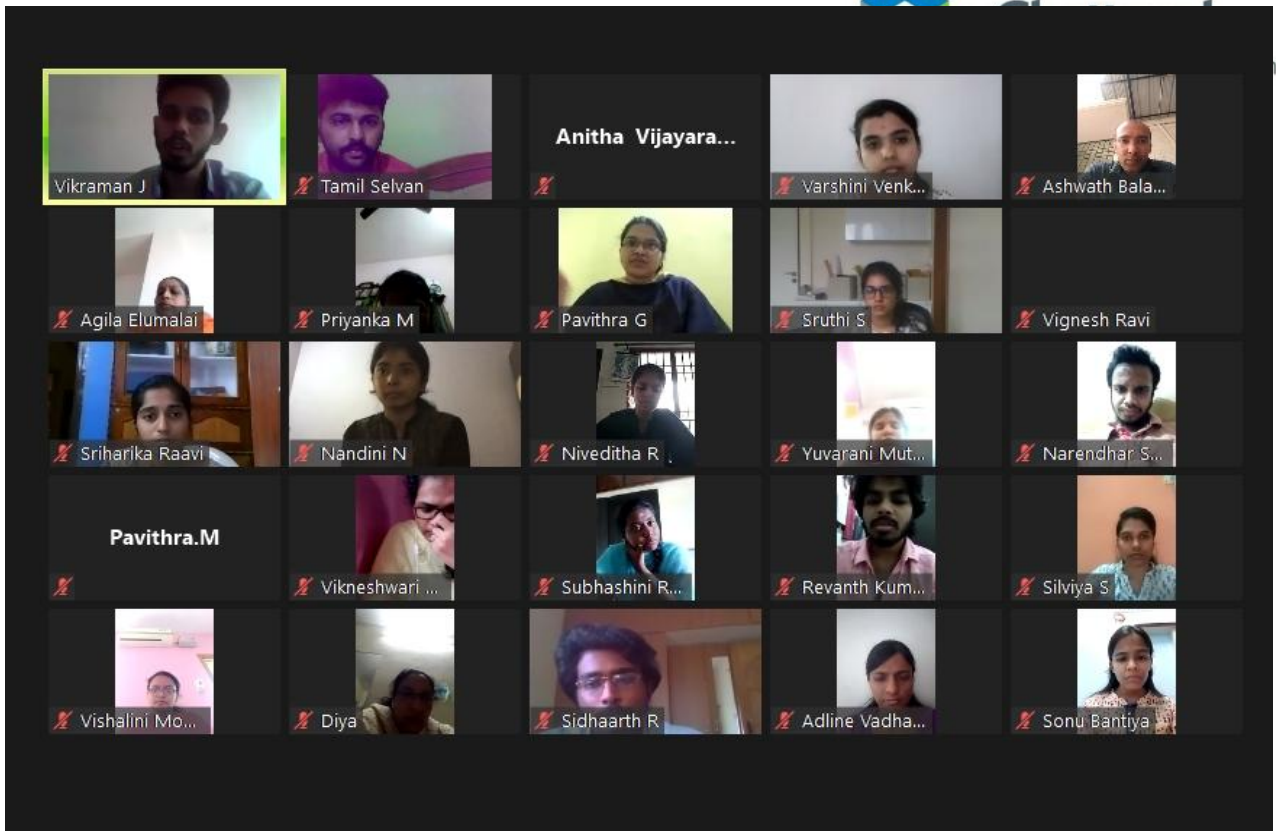
Vignesh Ravi

VM

Vishalini Mohan

Yuvarani Muthu Kumar

Invite



Zoom Meeting 40-Minutes

You are viewing Vikraman J's screen

View Options

00:00:54

Speaker View

Chettinad
Dental College & Research Institute

CHRONIC PERIODONTITIS

J.Vikraman
IV-BDS

Vikraman J

Tamil Selvan

Pavithra G

Narendhar Sre...

Unmute

Stop Video

Security

Participants 5

Chat

Share Screen

Record

Reactions

End

Zoom Meeting 40-Minutes

You are viewing Vikraman J's screen

View Options

00:11:25

Speaker View

Chettinad
Dental College & Research Institute

BASED ON DISEASE SEVERITY

MILD PERIODONTITIS
CAL < 2 mm
Usually generalised involvement
Bone loss is minimal (< 20 % of total attachment)
Minimal furcation invasions with little or no mobility

MODERATE PERIODONTITIS
CAL ~ 3-4mm
Bone loss upto 40% of total attachment
Early to moderate furcation involvement with slight to moderate tooth mobility

SEVERE PERIODONTITIS
CAL > 7mm
Bone loss more than 40 % - horizontal and vertical bone defects observed
Furcation involvement upto grade III
Excessive tooth mobility

Vikraman J

Tamil Selvan

Anitha Vijayara...

Varshini Venk...

Ashwath Bala...

Unmute

Stop Video

Security

Participants 35

Chat

Share Screen

Record

Reactions

End