



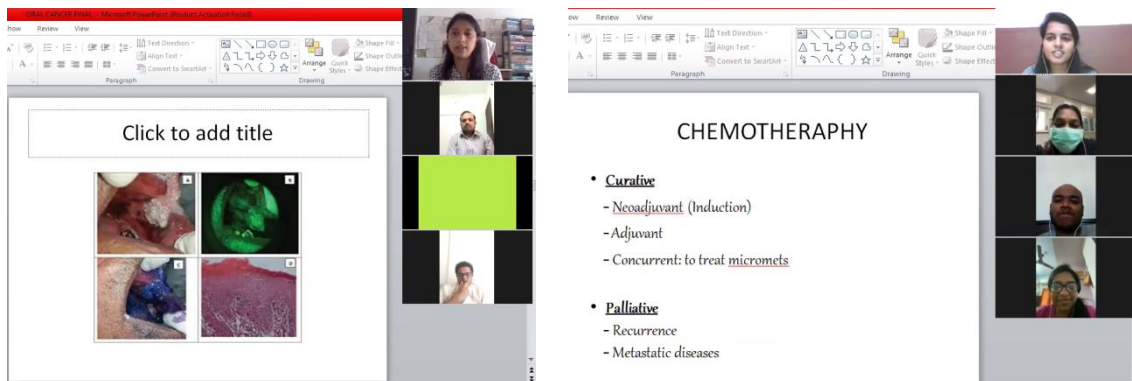
Chettinad
Dental College & Research Institute

E – Teaching/Learning Sessions for PG's
Department of ORAL AND MAXILLOFACIAL SURGERY

S.no	DATE	LECTURE TOPIC	FACULTY	PARTICIPATED STUDENTS
1	1-4-20	ORAL CANCER	DR.Rajesh,Dr.Alagappan, DR,Ramya,DR.Neethu	4
2	2-4-20	OSEOINTEGRATION	DR.Rajesh,Dr.Alagappan, DR.Semmia DR,Ramya,DR.Neethu	5
3	3-4-20	ARMAMENTARIUM IN EXODONTIA	DR.Rajesh,Dr.Alagappan, DR.Semmia DR,Ramya,DR.Neethu	4
4	3-4-20	TMJ AND ITS DISORDERS.	DR.Rajesh,Dr.Alagappan, DR.Semmia,DR.Ramya, DR.Neethu	4
4	4-4-20	Use of ultrasonic activated resorbable sheets and pins for the management of condylar neck fracture –case series	DR.Rajesh,Dr.Alagappan, DR.Semmia,DR.Ramya, DR.Neethu	4
5	4-4-20	CASE DISCUSSION- BSSO, GENIOPLASTY, MALAR AUGMENTATION	DR.Rajesh,Dr.Alagappan, DR.Semmia,DR.Ramya, DR.Neethu	4

6	5-4-20	CASE DISCUSSION,CONDYLAR FRACTURE	DR.Rajesh,Dr.Alagappan, DR.Semmia,DR.Ramya, DR.Neethu	5
---	--------	-----------------------------------	---	---

1-4-20



The screenshot shows a Zoom meeting interface. On the left, a presentation slide titled "CHEMOTHERAPY" is displayed. The slide content includes:

- Curative
 - Neoadjuvant (Induction)
 - Adjuvant
 - Concurrent: to treat micromets
- Palliative
 - Recurrence
 - Metastatic diseases

On the right side of the screen, there is a grid of video feeds for participants. The top feed shows a woman, and below it are three smaller feeds showing other participants.

PARTICIPANTS:

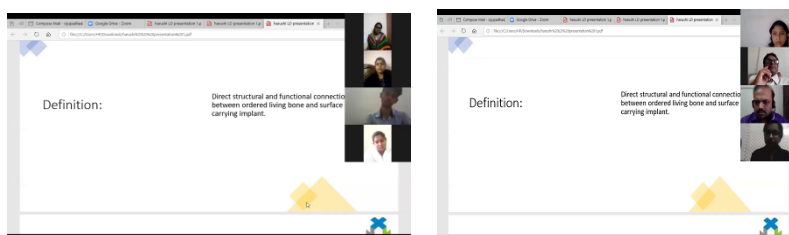
DR.VIJAYALAKSHMI.P

DR.HARSHNE

DR.VAISHALI

DR.HARUSHI

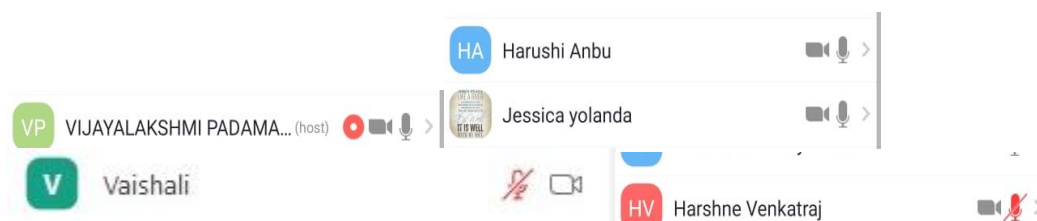
2-4-20



The screenshot shows a Zoom meeting interface. On the left, a presentation slide titled "Definition:" is displayed. The slide content includes:

Definition: Direct structural and functional connection between ordered living bone and surface carrying implant.

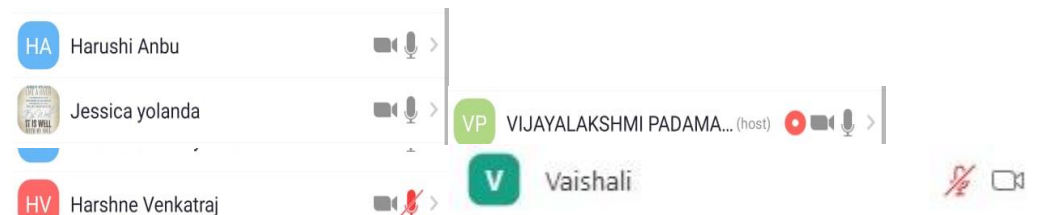
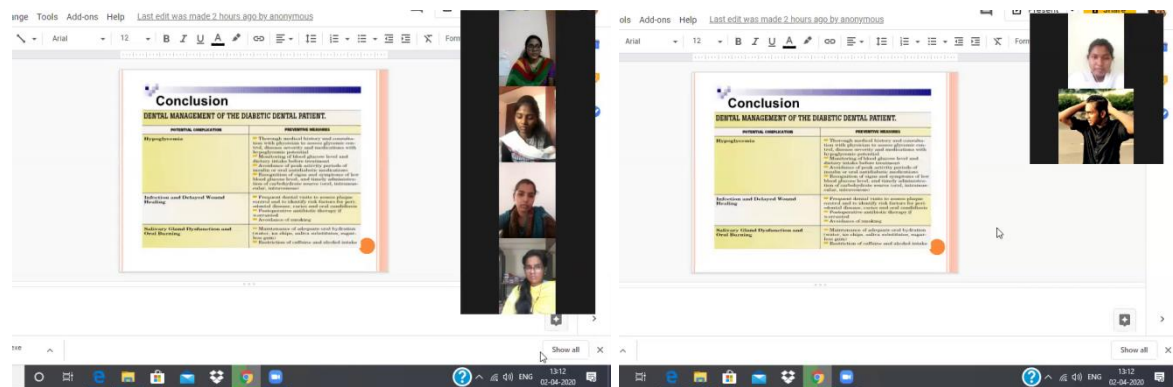
On the right side of the screen, there is a grid of video feeds for participants. The top feed shows a woman, and below it are three smaller feeds showing other participants.



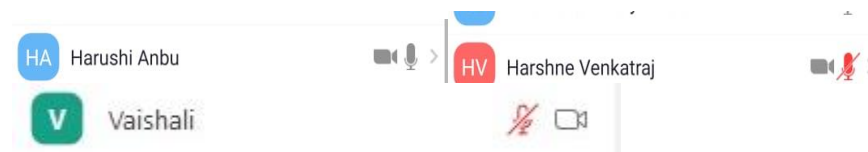
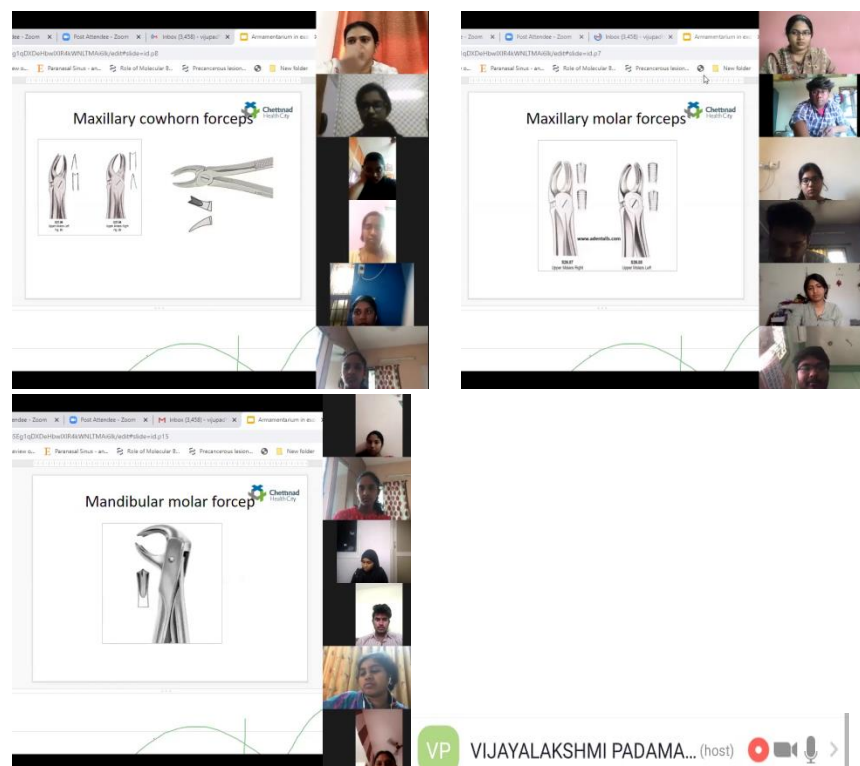
The screenshot shows a Zoom meeting interface. At the bottom of the screen, there is a list of participants:

- HA Harushi Anbu
- VP VIJAYALAKSHMI PADAMA... (host)
- V Vaishali
- Jessica yolanda
- HV Harshne Venkatraj

2-4-2020






3-4-20



4-4-20

VP



VIJAYALAKSHMI PADAMA... (host)




>

HA



Harushi Anbu




>






Jessica yolanda



>



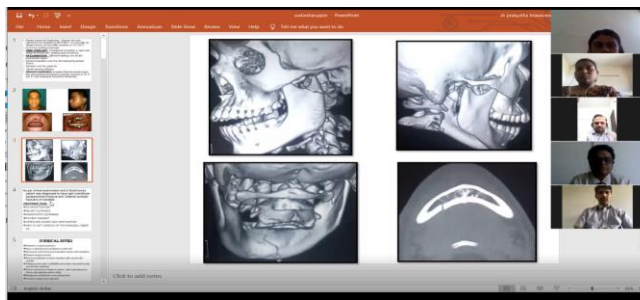
Dr praktyatha Brasanna Sh... (host)



>

[illegible]

5-4-20



SURGICAL NOTES

- ✦ Patient in supine position
- ✦ Naso endotracheal intubation under GA
- ✦ Extraoral and intraoral preparation done with betadine
- ✦ Patient draped sterile
- ✦ Retromandibular incision marked with sterile skin marker
- ✦ 2% lignocaine with 1:200000 adrenaline injected locally around the marking
- ✦ Extra oral Incision made in layers –skin subcutaneous tissue, pterigomasseteric sling
- ✦ Marginal mandibular nerve protected
- ✦ Fracture fragments exposed

Dr prakyatha Brasanna Sh... (host)

HA Harushi Anbu

Jessica yolanda

VP VIJAYALAKSHMI PADAMA... (host)

V Vaishali