

CHETTINAD DENTAL COLLEGE AND RESEARCH INSTITUTE

DEPARTMENT OF PERIODONTICS AND IMPLANTOLOGY

POST GRADUATES -(6.7.2020-11.7.2020)

POST GRADUATE DISCUSSION

DATE	Discussion TOPIC	Name of the presenter
6/7/2020	Trauma from occlusion	Dr. M.Priyanka
7/7/2020	Dentine hypersensitivity	Dr. K Narendhiran
8/7/2020	Alveolar bone	Dr. M.Priyanka
11/7/2020	Diabetic and periodontics	Dr. Abirami TM

JOURNAL DISCUSSION

DATE	Journal discussion	Name of the presenter
9/7/2020	Photoactivated disinfection in periodontal treatment – a RCT split-mouth trial	Dr. Adline Vadhana D
10/7/2020	Accuracy of conebeam computed tomography in evaluation of palatal mucosa thickness	Dr. Easu Kani Silviya

CASE DISCUSSION


DATE	Name of the presenter
6/7/2020	Case presentation – Dr. Vikram C
7/7/2020	Case presentation - Dr. M.Priyanka
9/7/2020	Case presentation – Dr. Abirami TM
10/7/2020	Case presentation – Dr. Diya B
11/7/2020	Case presentation - Dr. Adline Vadhana D

VIVA DISCUSSION

DATE	TOPIC
6/7/2020	Miscellaneous
7/7/2020	Miscellaneous
8/7/2020	Miscellaneous
9/7/2020	Miscellaneous
10/7/2020	Miscellaneous
11/7/2020	Miscellaneous

CLINICAL E--DISCUSSION ON 6/07/2020

NAME OF THE FACULTY	ALL FACULTY
TOPIC	Trauma Froum Occlusion – Dr.M Priyanka Case presentation – Dr. Vikram.C Viva session
BATCH	POST GRADUATES



Join our Cloud HD Video Meeting
Zoom is the leader in modern enterprise video communication...
us04web.zoom.us


Priyanka M is inviting you to a scheduled Zoom meeting.

Topic: case discussion
Time: Jul 6, 2020 12:30 PM Mumbai, Kolkata, New Delhi

Join Zoom Meeting
<https://us04web.zoom.us/j/3204866446?pwd=b0tBWnRNaWV0WFVwaTN2clk0VVNTZz09>

Meeting ID: **320 486 6446**
Password: 12345

7:29 pm ✓✓



Join our Cloud HD Video Meeting
Zoom is the leader in modern enterprise video communication...
us04web.zoom.us


Priyanka M is inviting you to a scheduled Zoom meeting.

Topic: pg discussion
Time: Jul 6, 2020 11:00 AM Mumbai, Kolkata, New Delhi

Join Zoom Meeting
<https://us04web.zoom.us/j/3204866446?pwd=b0tBWnRNaWV0WFVwaTN2clk0VVNTZz09>

Meeting ID: **320 486 6446**
Password: 12345

7:29 pm ✓✓



Join our Cloud HD Video Meeting
Zoom is the leader in modern enterprise video communication...
us04web.zoom.us

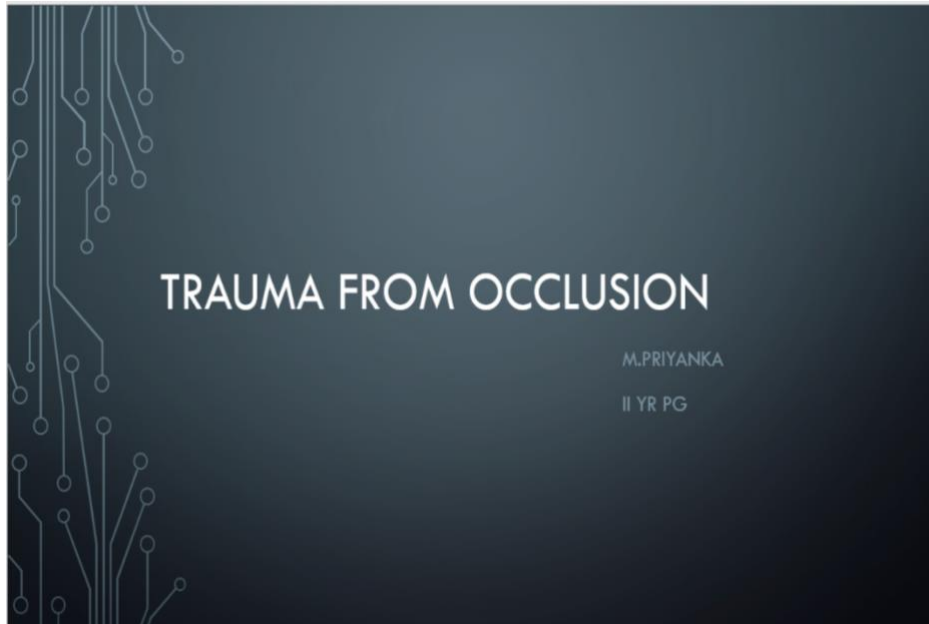
Priyanka M is inviting you to a scheduled Zoom meeting.

Topic: viva discussion
Time: Jul 6, 2020 02:00 PM Mumbai, Kolkata, New Delhi

Join Zoom Meeting
<https://us04web.zoom.us/j/3204866446?pwd=b0tBWnRNaWV0WFVwaTN2clk0VVNTZz09>

Meeting ID: **320 486 6446**
Password: 12345

7:30 pm ✓✓





	<u>ACUTE TRAUMA FROM OCCLUSION</u>	<u>CHRONIC TRAUMA FROM OCCLUSION</u>
	Less common	More common
<u>Definition:-</u>	Result from abrupt change in occlusal force	Result from gradual change in occlusion
<u>Cause:-</u>	<ul style="list-style-type: none">●Biting on a hard object●Restoration●Prosthetic appliances	<ul style="list-style-type: none">●Tooth wear●Drifting movement
<u>Clinical Features:-</u>	<ul style="list-style-type: none">●Tooth pain●Sensitivity to percussion●Increased tooth mobility●Cementum tears.	<ul style="list-style-type: none">●Tooth mobility
<u>Management:-</u>	<ul style="list-style-type: none">●Dissipate the force by shift in the position of tooth●By wearing away or correction of restoration.	<ul style="list-style-type: none">●Removal of cause
<u>Complications:-</u>	<ul style="list-style-type: none">●Periodontal injury may worsen & develop into necrosis accompanied by periodontal abscess.	<ul style="list-style-type: none">●Periodontal injury may worsen & develop into necrosis accompanied by periodontal abscess.

CASE PRESENTATION

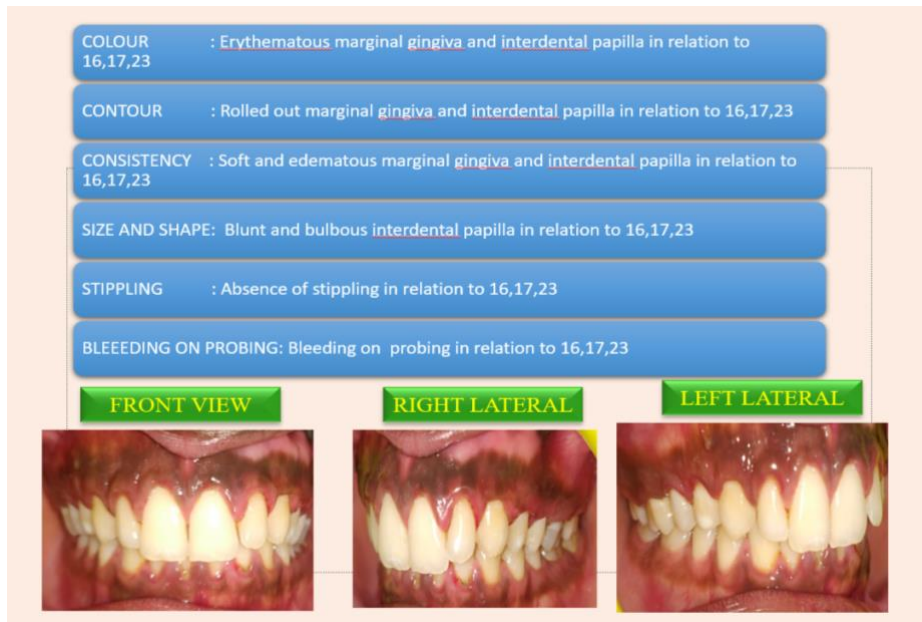MR.SARAVANAN

By
C.VIKRAM



Chettinad

Dental College & Research Institute



6/7/2020

16. Desquamative gingivitis
17. Pathogenesis of periodontal pocket
18. Transgingival probing
19. Circumferential probing
20. Antibiotic prophylaxis for Medically compromised patients
21. Host modulation agents
22. Methods of elimination of pocket therapy
23. Analgesics in periodontics

CLINICAL E--DISCUSSION ON 7/07/2020

NAME OF THE FACULTY	ALL FACULTY
TOPIC	Dentine hypersensitivity Dr. K Narendhiran Case presentation – Dr.M Priyanka Viva session
BATCH	POST GRADUATES

Priyanka M is inviting you to a scheduled Zoom meeting.

Topic: pg discussion
Time: Jul 7, 2020 11:00 AM Mumbai, Kolkata, New Delhi

Join Zoom Meeting
<https://us04web.zoom.us/j/3204866446?pwd=b0tBWnRNaWV0WFVwaTN2clk0VVNTZz09>

Meeting ID: **320 486 6446**
Password: 12345

9:59 pm ✓✓

zoom Join our Cloud HD Video Meeting
Zoom is the leader in modern enterprise video communication...
us04web.zoom.us

Priyanka M is inviting you to a scheduled Zoom meeting.

Topic: case discussion
Time: Jul 7, 2020 12:30 PM Mumbai, Kolkata, New Delhi

Join Zoom Meeting
<https://us04web.zoom.us/j/3204866446?pwd=b0tBWnRNaWV0WFVwaTN2clk0VVNTZz09>

Meeting ID: **320 486 6446**
Password: 12345

10:00 pm ✓✓

zoom Join our Cloud HD Video Meeting
Zoom is the leader in modern enterprise video communication...
us04web.zoom.us

Priyanka M is inviting you to a scheduled Zoom meeting.

Topic: viva discussion
Time: Jul 7, 2020 02:00 PM Mumbai, Kolkata, New Delhi

Join Zoom Meeting
<https://us04web.zoom.us/j/3204866446?pwd=b0tBWnRNaWV0WFVwaTN2clk0VVNTZz09>

Meeting ID: **320 486 6446**
Password: 12345

10:00 pm ✓✓



11:15 AM

Close

Participants (14)

PM

Priyanka M (me)

Vikram C (host)

KN

K Narendhiran

A

Abirami Tm

AV

Adline Vadhana

Agila Elumalai

aishu durai

AV

Anitha Vijayarangan

DP

Divya priyal

D

Diya

M Shanmugam

e

Silviya S

S

Sophia

Invite

11:15 AM

Close

Participants (14)

Vikram C (host)

KN

K Narendhiran

A

Abirami Tm

AV

Adline Vadhana

Agila Elumalai

aishu durai

AV

Anitha Vijayarangan

DP

Divya priyal

D

Diya

M Shanmugam

e

Silviya S

S

Sophia

Srivainavi Arulmari

Invite



DENTIN HYPERSENSITIVITY

K NARENDHIRAN
MDS II YEAR

HYDRODYANAMIC THEORY

Recording

The trigeminal nerve supplies the pulp, with innervation from myelinated fibres (A- β and A- δ) and nonmyelinated C fibres (Matthews, 2000).

It is proposed that the larger myelinated fibres (A- β and some A- δ) can respond to stimuli that displace the fluid in the dentinal tubule through a hydrodynamic mechanism, such as tactile, evaporative, osmotic or thermal challenges, to elicit short, sharp, stabbing pain that typically lasts for only a few seconds.

K Narendhiran's screen



Chettinad

Dental College & Research Institute

CASE PRESENTATION MR.KUMAR

M.PRIYANKA
II PG
DEPARTMENT OF PERIODONTICS

GINGIVAL EXAMINATION

Color: erythematous marginal and attached gingiva with diffuse melanin pigmentation 31, 32, 42, 41,

Contour: Rolledout margins 31, 32, 42, 41,

Consistency: Soft and oedematous marginal relation to 31, 32, 42, 41,

Size and shape: Bulbous interdental papilla in relation to 31, 32, 42, 41, and blunt interdental papilla in relation to 22, 23, 11,12,

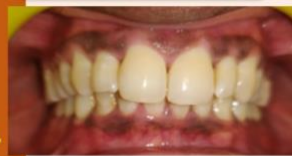Bleeding on probing: Generalised bleeding on probing in relation to 47, 34, 22, 16, 36, 37

Frenal attachment: Papillary (Placek et al in 1974)

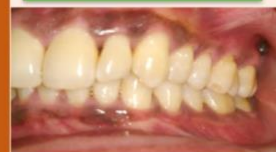Surface texture : Absence of stippling in relation to 31, 32, 33, 41, 42, 43,

Width of attached gingiva : Adequate

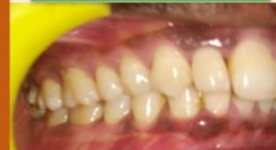FRONTAL VIEW



LEFT LATERAL VIEW



RIGHT LATERAL VIEW





Chettinad


Dental College & Research Institute

7/7/2020

1. What is clinical attachment loss (CAL)?
2. What is Ante's law?
3. What are the characteristics of healthy gingiva?
4. What are the five types of gingival fibers?
5. What is the composition of the oral mucosa (the tissue lining the oral cavity)?
6. Describe the four layers of cells that comprise the masticatory epithelium.
7. What is the composition of the gingival epithelium?
8. What is the composition of connective tissue?
9. keratinized or nonkeratinized?
10. Where is the average width of the PDL greatest and where is it narrowest?

CLINICAL E--DISCUSSION ON 8/07/2020

NAME OF THE FACULTY	ALL FACULTY
TOPIC	Alveolar bone – Dr.M Priyanka Viva session
BATCH	POST GRADUATES

Join our Cloud HD Video Meeting
Zoom is the leader in modern
enterprise video communication...
us04web.zoom.us


Priyanka M is inviting you to a scheduled
Zoom meeting.

Topic: pg discussion
Time: Jul 8, 2020 11:00 AM Mumbai,
Kolkata, New Delhi

Join Zoom Meeting
[https://us04web.zoom.us/j/3204866446
?pwd=b0tBWnRNaWV0WFVwaTN2clk0VV
NTZz09](https://us04web.zoom.us/j/3204866446?pwd=b0tBWnRNaWV0WFVwaTN2clk0VVNTZz09)

Meeting ID: **320 486 6446**
Password: 12345

8:19 pm ✓✓

Join our Cloud HD Video Meeting
Zoom is the leader in modern
enterprise video communication...
us04web.zoom.us

Priyanka M is inviting you to a scheduled
Zoom meeting.

Topic: viva discussion
Time: Jul 8, 2020 02:00 PM Mumbai,
Kolkata, New Delhi

Join Zoom Meeting
[https://us04web.zoom.us/j/3204866446
?pwd=b0tBWnRNaWV0WFVwaTN2clk0VV
NTZz09](https://us04web.zoom.us/j/3204866446?pwd=b0tBWnRNaWV0WFVwaTN2clk0VVNTZz09)

Meeting ID: **320 486 6446**
Password: 12345

8:20 pm ✓✓



11:10 AM

Close

Participants (15)

PM

Priyanka M (me)

>

Vikram C (host)

>

D

diya

>

A

Abirami Tm

>

AV

Adline Vadhana

>

Agila Elumalai

>

aishu durai

>

AV

Anitha Vijayarangan

>

Ashwath Balachandran

>

DP

Divya priyal

>

KN

K Narendhiran

>

M Shanmugam

>

e

Silviya S

>

Invite

11:10 AM

Close

Participants (15)

D

diya

>

A

Abirami Tm

>

AV

Adline Vadhana

>

Agila Elumalai

>

aishu durai

>

AV

Anitha Vijayarangan

>

Ashwath Balachandran

>

DP

Divya priyal

>

KN

K Narendhiran

>

M Shanmugam

>

e

Silviya S

>

S

Sophia

>

SA

Srivainavi Arulmari

>

Invite

ALVEOLAR BONE

M.PRIYANKA
II YEAR PG



OSTEOBLAST

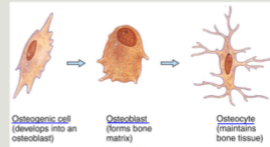
Osteoblasts are mononuclear cells responsible for the synthesis and secretion of the macromolecular organic constituents of bone matrix

MORPHOLOGY

Osteoblasts are basophilic, plump cuboidal or slightly elongated cells

They exhibit abundant and well developed protein synthetic organelles

Ultra structure is characteristic of any actively secreting cell with prominent Golgi apparatus, Rough endoplasmic reticulum, mitochondria, nucleoli and many secretory vesicles & vacuoles



G S KUMAR, ORBAN'S ORAL HISTOLOGY
AND EMBRYOLOGY; 13TH EDITION

8/7/2020

1. risk indicators for periodontitis
2. What are the treatment options for furcation defects
3. Composition and functions of alveolar bone
4. CEJ
5. Types of collagen
6. Biologic width
7. Muscles of masticating
8. Various Gingival Index
9. Periodontal Index.
10. Bleeding index

CLINICAL E--DISCUSSION ON 9/07/2020

NAME OF THE FACULTY	ALL FACULTY
TOPIC	Photoactivated disinfection in periodontal treatment – a RCT split-mouth trial -Dr.Adline Vadhana D Case presentation – Dr. Abirami TM Viva session
BATCH	POST GRADUATES

Priyanka M is inviting you to a scheduled Zoom meeting.

Topic: journal discussion - Adline vadhana D

Time: Jul 9, 2020 11:00 AM Mumbai, Kolkata, New Delhi

Join Zoom Meeting

<https://us04web.zoom.us/j/3204866446?pwd=b0tBWnRNaWV0WFVwaTN2clk0VVNTZz09>

Meeting ID: 320 486 6446

Password: 12345

10:59 am ✓

zoom

Join our Cloud HD Video Meeting

Zoom is the leader in modern enterprise video communication...
us04web.zoom.us

Priyanka M is inviting you to a scheduled Zoom meeting.

Topic: case discussion

Time: Jul 9, 2020 12:30 PM Mumbai, Kolkata, New Delhi

Join Zoom Meeting

<https://us04web.zoom.us/j/3204866446?pwd=b0tBWnRNaWV0WFVwaTN2clk0VVNTZz09>

Meeting ID: 320 486 6446

Password: 12345

11:33 pm ✓

zoom

Join our Cloud HD Video Meeting

Zoom is the leader in modern enterprise video communication...
us04web.zoom.us

Priyanka M is inviting you to a scheduled Zoom meeting.

Topic: viva discussion

Time: Jul 9, 2020 02:00 PM Mumbai, Kolkata, New Delhi

Join Zoom Meeting

<https://us04web.zoom.us/j/3204866446?pwd=b0tBWnRNaWV0WFVwaTN2clk0VVNTZz09>

Meeting ID: 320 486 6446

Password: 12345

11:33 pm ✓



11:08 AM			11:08 AM		
Close			Close		
Participants (15)			Participants (15)		
PM	Priyanka M (me)	>	AV	Adline Vadhana	>
	Vikram C (host)	>	A	Abirami Tm	>
AV	Adline Vadhana	>		Agila Elumalai	>
A	Abirami Tm	>		aishu durai	>
	Agila Elumalai	>	AV	Anitha Vijayarangan	>
	aishu durai	>		Ashwath Balachandran	>
AV	Anitha Vijayarangan	>	DP	Divya priyal	>
	Ashwath Balachandran	>	D	Diya	>
DP	Divya priyal	>	KN	K Narendhiran	>
D	Diya	>		M Shanmugam	>
KN	K Narendhiran	>	SS	Silviya S	>
	M Shanmugam	>	S	Sophia	>
SS	Silviya S	>		Srivainavi Arulmari	>
Invite			Invite		

PHOTOACTIVATED DISINFECTION IN PERIODONTAL
TREATMENT-A RANDOMIZED CONTROLLED CLINICAL
SPLIT-MOUTH TRIAL

Selma Husejnagic, J Periodontol. 2019;00:1-10

D. ADLINE VADHANA
III- MDS



PHOTOACTIVATED DISINFECTION

	Photoactivated disinfection (PAD) in periodontal treatment is based on the concept of photodynamic therapy (PDT)
	PDT is a treatment method that is associated with the use of a light source and a photosensitizer- Dougherty in 1993
	PDT was first successfully applied 100 years ago but the development of antibiotics led to a stagnation in the use of PDT for infectious diseases.
	However, due to an increase in antibiotic resistance, this treatment method is re-emerging as a possible alternative for treating infection

DEMOGRAPHIC DATA

PATIENT NAME	Mr. Abraham sunderasan
AGE/SEX	52/M
OP NO	CSSH 193548
PHONE NO	9500005532
OCCUPATION	Business man
ADDRESS	F1104, Manthy synergy, 1/1 24B, OMR road, Padur, Chennai



CLINICAL FINDINGS	
WIDTH OF ATTACHED GINGIVA	Inadequate width of attached gingiva in relation to 17, 27, 12, 13, 14, 15, 16, 22, 24, 26, 26, 27, 34, 36, 37, 44, 45, 46, 47
POSITION OF GINGIVA TO CEJ	Marginal gingiva is apical to cemento-enamel junction of about 2mm- 12, 13, 15, 44 3mm- 14
FRENAL ATTACHMENT	Maxillary labial frenum- Mucosal [Placek et al 1974] Mandibular labial frenum- Mucosal
GINGIVAL RECESSION	Class I gingival recession – 13, 14, 15, 44 Class III gingival recession – 12



Frontal view Right lateral view

9/7/2020

- PERIODONTAL DISEASE AND RESPIRATORY DISEASES
- CVS And periodontal diseases
- Pregnancy and periodontal disease
- Osteoporosis and periodontal
- Biologic mediators of furcation
- Specific and nonspecific plaque
- Role of bacteria and periodontitis
- Viruse and periodontitis
- Fungi and periodontitis
- Habits and periodontal diseases

CLINICAL E--DISCUSSION ON 10/07/2020

NAME OF THE FACULTY	ALL FACULTY
TOPIC	Accuracy of conebeam computed tomography in evaluation of palatal mucosa thickness – Dr. Easu Kani Silviya Case presentation – Dr. Diya B Viva session
BATCH	POST GRADUATES

zoom Join our Cloud HD Video Meeting
Zoom is the leader in modern enterprise video communication...
us04web.zoom.us

Priyanka M is inviting you to a scheduled Zoom meeting.

Topic: journal discussion - Easu kani silviya
Time: Jul 10, 2020 11:00 AM Mumbai, Kolkata, New Delhi

Join Zoom Meeting
<https://us04web.zoom.us/j/3204866446?pwd=b0tBWnRNaWV0WFVwaTN2clk0VVNTZz09>

Meeting ID: **320 486 6446**
Password: 12345

11:04 pm ✓✓

zoom Join our Cloud HD Video Meeting
Zoom is the leader in modern enterprise video communication...
us04web.zoom.us

Priyanka M is inviting you to a scheduled Zoom meeting.

Topic: case discussion
Time: Jul 10, 2020 12:30 PM Mumbai, Kolkata, New Delhi

Join Zoom Meeting
<https://us04web.zoom.us/j/3204866446?pwd=b0tBWnRNaWV0WFVwaTN2clk0VVNTZz09>

Meeting ID: **320 486 6446**
Password: 12345

11:04 pm ✓✓

zoom Join our Cloud HD Video Meeting
Zoom is the leader in modern enterprise video communication...
us04web.zoom.us

Priyanka M is inviting you to a scheduled Zoom meeting.

Topic: viva discussion
Time: Jul 10, 2020 02:00 PM Mumbai, Kolkata, New Delhi

Join Zoom Meeting
<https://us04web.zoom.us/j/3204866446?pwd=b0tBWnRNaWV0WFVwaTN2clk0VVNTZz09>

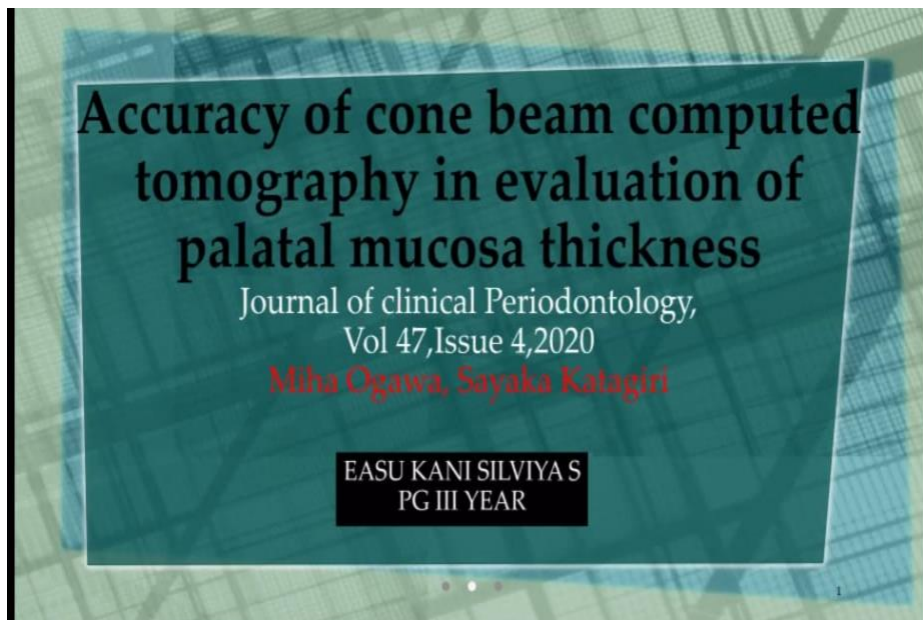
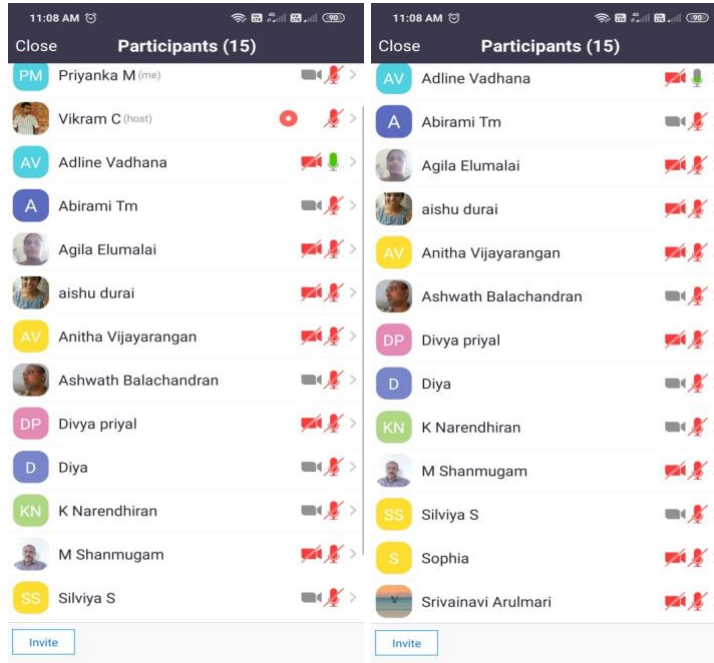
Meeting ID: **320 486 6446**
Password: 12345

11:05 pm ✓✓



Chettinad

Dental College & Research Institute

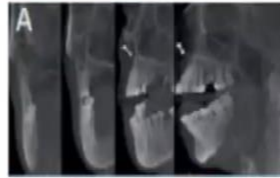




BASIC PRINCIPLES

The captured 2D images are instantaneously conveyed to the computer, which reconstructs them, using modified Feldkamp algorithm into the anatomical volume for viewing at 1:1 ratio in axial, coronal, and sagittal planes.

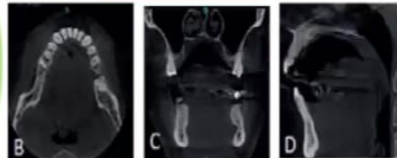
The data is in the Digital Imaging and Communications in Medicine (DICOM) format, which enables ease of telecommunication and usage with other third party imaging software.



Acquired 2D Basis images



Recording



Secondary reconstructions – orthogonal view

e

CLINICAL CASE PRESENTATION

Presented By :
Balakrishnan Diya Ranjit
III Yr PG



CLINICAL CASE HISTORY

NAME : Mr. Vinayaga Moorthi

AGE/SEX : 32/M

OP NO : 201804210038

OCCUPATION : Medical coding, Ayuba solutions

ADDRESS : 1/226, Rajiv Gandhi street, Shollinganallur, Chennai-80

MOBILE NO : 9600179070 , 8248218205

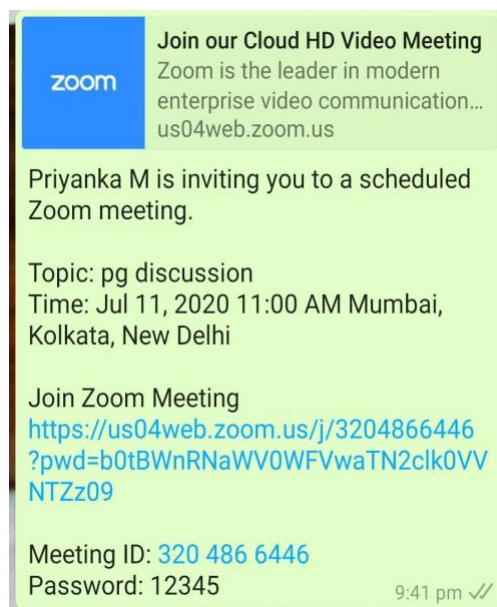
RMCT : 255415

11/7/2020

- Splinting
- stages of tissue response to trauma from occlusion
- supragingival and subgingival irrigation
- root surface modification
- Gingivectomy
- indication for periodontal flap surgery
- osseous surgery
- osteoplasty
- Ostectomy
- Wound healing

CLINICAL E--DISCUSSION ON 11/07/2020

NAME OF THE FACULTY	ALL FACULTY
TOPIC	Diabetic and periodontics – Dr. Abirami TM Case presentation – Dr. Adline Vadhana Viva session
BATCH	POST GRADUATES



Join our Cloud HD Video Meeting
Zoom is the leader in modern enterprise video communication...
us04web.zoom.us

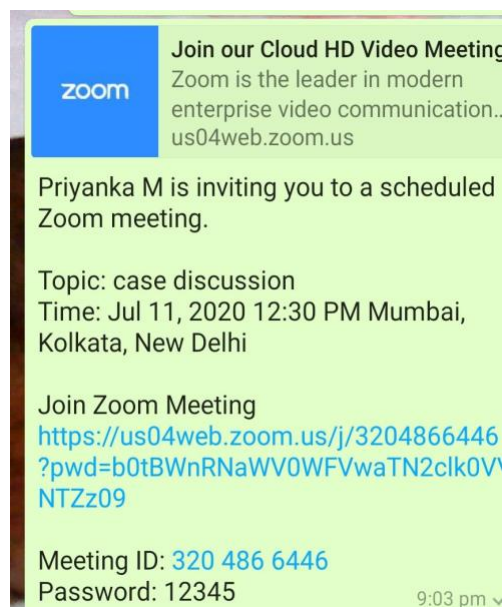
Priyanka M is inviting you to a scheduled Zoom meeting.

Topic: pg discussion
Time: Jul 11, 2020 11:00 AM Mumbai, Kolkata, New Delhi

Join Zoom Meeting
<https://us04web.zoom.us/j/3204866446?pwd=b0tBWnRNaWV0WFVwaTN2clk0VVNTZz09>

Meeting ID: **320 486 6446**
Password: 12345

9:41 pm ✓



Join our Cloud HD Video Meeting
Zoom is the leader in modern enterprise video communication...
us04web.zoom.us

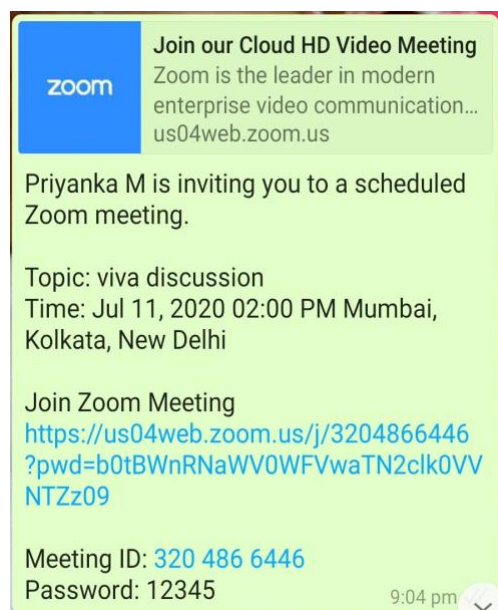
Priyanka M is inviting you to a scheduled Zoom meeting.

Topic: case discussion
Time: Jul 11, 2020 12:30 PM Mumbai, Kolkata, New Delhi

Join Zoom Meeting
<https://us04web.zoom.us/j/3204866446?pwd=b0tBWnRNaWV0WFVwaTN2clk0VVNTZz09>

Meeting ID: **320 486 6446**
Password: 12345

9:03 pm ✓



Join our Cloud HD Video Meeting
Zoom is the leader in modern enterprise video communication...
us04web.zoom.us

Priyanka M is inviting you to a scheduled Zoom meeting.

Topic: viva discussion
Time: Jul 11, 2020 02:00 PM Mumbai, Kolkata, New Delhi

Join Zoom Meeting
<https://us04web.zoom.us/j/3204866446?pwd=b0tBWnRNaWV0WFVwaTN2clk0VVNTZz09>

Meeting ID: **320 486 6446**
Password: 12345

9:04 pm ✓



11:15 AM			11:15 AM		
Close			Close		
Participants (14)			Participants (14)		
PM	Priyanka M (me)	>	Vikram C (host)	>	>
	Vikram C (host)	>	KN	K Narendhiran	>
KN	K Narendhiran	>	A	Abirami Tm	>
A	Abirami Tm	>	AV	Adline Vadhana	>
AV	Adline Vadhana	>		Agila Elumalai	>
	Agila Elumalai	>		aishu durai	>
	aishu durai	>	AV	Anitha Vijayarangan	>
AV	Anitha Vijayarangan	>	DP	Divya priyal	>
DP	Divya priyal	>	D	Diya	>
D	Diya	>		M Shanmugam	>
	M Shanmugam	>	e	Silviya S	>
e	Silviya S	>	S	Sophia	>
S	Sophia	>		Srivainavi Arulmari	>
Invite			Invite		

DIABETES AND PERIODONTAL DISEASE



PERIODONTITIS- TYPE I

Poplawska -Kita 2014	Type 1 diabetes mellitus increases the prevalence of periodontitis 4-fold compared with normoglycemic controls.
Meenawat 2013- JCP	The mean clinical attachment loss was greater in type 1 diabetes mellitus, 4.3 mm compared with 2.3 mm in nondiabetics.
Kim 2014	Animal studies have shown that periodontal bone loss in type 1 diabetes mellitus rats increased ~3-fold compared with normal rats.

DEMOGRAPHIC DATA

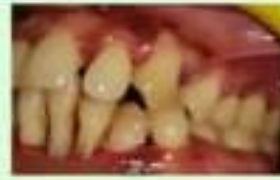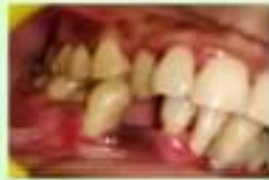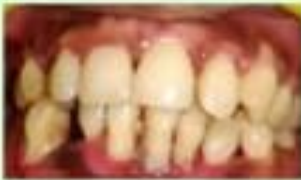• PATIENT NAME : MRS. SHEEBA
• AGE/SEX : 34F
• OP NO : 201911290002
• PHONE NO : 9842579812
• OCCUPATION : House wife
• ADDRESS : No 145 Mathura Nagar,
Thaayur,
Chennai- 603 110



INTRA- ORAL EXAMINATION

GINGIVAL EXAMINATION:-

COLOR	Erythematous marginal gingiva, attached gingiva and interdental papilla in relation to 13,12,22,23,43,42,41,31,32,34
CURTURE	Rollad-out margin in relation to 17,16,15,14,13,12,11,21,22,23,24,26,27,36,35,34,33,32,31,41,42,44,45,46,47
CONSISTENCY	Soft and edematous in consistency in relation to 17,16,15,14,13,12,11,21,22,23,24,26,27,36,35,34,33,32,31,41,42,44,45,46,47



11/7/2020

- AAP & EFP 2017 CLASSIFICATION
- Splinting
- Classification of Cementum
- Bmp
- Incisions
- Osteoplasty and Ostectomy
- Wound healing
- Decision tree for gingivectomy
- Indications of periodontal flap
- T cells